BRITISH HEART JOURNAL

Volume X
1948

LONDON
Reprinted by offset litho for
WM DAWSON & SONS LTD
4 Duke Street, Manchester Square, London, W 1
By permission of the British Medical Association
1958

EDITOR

MAURICE CAMPBELL

EDITORIAL BOARD

CRIGHTON BRAMWELL, MANCHESTER
A N DRURY, LONDON
TERENCE EAST, LONDON
A R GILCHRIST, EDINBURGH
JOHN PARKINSON, LONDON
EDITOR OF *British Medical Journal*
WILLIAM EVANS, LONDON

APPOINTED BY

THE BRITISH CARDIAC SOCIETY

CONTENTS OF VOLUME X

Number 1

		Page
John Cowan	By W E Hume	1
Angina in Women	By V K Summers	4
Clinical Value of Unipolar Chest and Limb Leads	By C W Curtis Bain and E McV Redfern	9
Two Cases of Temporal Arteritis One with Angina of Effort	By Leslie Cole	26
Hypertension Due to Syphilitic Occlusion of the Main Renal Arteries	By R Kemball Price and R Skelton	29
Ball Thrombus of the Heart	By M E Evans	34
Mass Thrombus of the Left Auricle	By William Evans and Robert Benson	39
The Variation of Casual, Basal, and Supplemental Blood Pressures in Health and in Essential Hypertension	By J A Kilpatrick	48
Cardiovascular Changes following Electro-Convulsive Therapy	By Ralph Kauntze and Gerald Parsons-Smith	57
Abstracts of Cardiology		63

Number 2

International Conference of Physicians		
The Surgery of Congenital Heart Diseases		65
Pulmonary Heart Disease Acute and Chronic		80
The Clinical Value of Chest Leads		88
The Use of the Phonocardiograph in Clinical Cardiology		92
Shorter Communications		99
Rapid Digitalization	By William Evans, Peter Dick, and Byron Evans	103
The Relative Value of Digitaline Preparations in Heart Failure with Auricular Fibrillation	By Peter Dick	122
The Heart in Rheumatoid Arthritis	By E J Fischmann and F J Gwynne	125
Abstracts of Cardiology		135

CONTENTS OF VOLUME X (*continued*)

Number 3

Page

PATHOGENESIS OF LEFT BUNDLE BRANCH BLOCK
By Håkon Rasmussen and Torjus Moe 141

EROSION OF RIBS IN COARCTATION OF THE AORTA A NOTE ON THE HISTORY OF A PATHOGNOMONIC SIGN By William Dock 148

COARCTATION OF THE AORTA By Maurice Newman 150

THE RIGHT PRÆCORDIAL LEAD
By Harry Vesell and Benjamin Shorr 158

CORONARY ARTERY ANEURYSM WITH OCCLUSION DUE TO A CALCIFIED THROMBUS By Norman Ashton and Mary Munro 165

HEART BLOCK IN OSTEITIS DEFORMANS
By C V Harrison and Bernard Lennox 167

VENTRICULAR COMPLEXES IN HEART BLOCK By H B Kay 177

THE REGENERATIVE CAPACITY OF MAMMALIAN HEART MUSCLE
By E W Walls 188

INCIPIENT SYMMETRICAL PERIPHERAL GANGRENE COMPLICATING PAROXYSMAL TACHYCARDIA By D Gordon Abrahams 191

TUBERCULOUS PERICARDITIS By A A Fitzgerald Peel 195

ABSTRACTS OF CARDIOLOGY 208

Number 4

ASCULTATION OF THE HEART By Samuel A Levine 213

HEART-VECTOR AND LEADS PART III, GEOMETRICAL REPRESENTATION
By H C Burger and J B van Milaan 229

VENTRICULAR ESCAPE IN ACUTE RHEUMATISM By Alan C Kirby 234

DISSECTING ANEURYSM OF THE INTERVENTRICULAR SEPTUM
By A A Fitzgerald Peel 239

LONG SURVIVAL WITH A CARDIAC ANEURYSM By A Codounis 244

U WAVE INVERSION By J H Palmer 247

CARDIAC LESIONS IN THIAMIN DEFICIENCY By J Frank Pantridge 252

CARDIAC PAIN WITH RECOVERY OF THE T WAVE
By Terence East and Samuel Oram 263

THE HEART IN THE PNEUMOCONIOSIS OF COALMINERS
By Arthur J. Thomas 282

PROCEEDINGS OF THE BRITISH CARDIAC SOCIETY 293

ABSTRACTS OF CARDIOLOGY 301

INDEX 305

JOHN COWAN

JOHN COWAN

John Cowan sprang from a long line of Glasgow doctors many of whom had held posts in the University His father, J B Cowan, had been Regius Professor of Materia Medica, and his grandfather, Robert Cowan, had been Professor of Medical Jurisprudence, and both had been Physicians to the Glasgow Royal Infirmary

Born in 1870 he was educated at Fettes, King's College (Cambridge), and Glasgow University He qualified at Cambridge in 1895 and held resident appointments in the Western Infirmary, the Children's Hospital, and the Glasgow Fever Hospital

In 1900 he served in the South African War as physician to the Scottish National Red Cross Hospital On his return to Glasgow he joined the junior clinical staff of the Western Infirmary and was assistant to Professor Samson Gemmell At the same time he worked with Robert Muir in the pathological department and published papers in the *Journal of Pathology* on fibrosis of the heart

In 1906 he was appointed Physician to the Royal Infirmary and finding much to be done to raise the standard of work in that hospital he spent most of his day in the wards All through his term of office as physician, Cowan attended almost daily at 9 a m and spent most of the morning in the wards He was a slow worker, but every case was investigated with meticulous care and he exacted the same care and industry from his house physicians and assistants

Stimulated by the work of Wenckebach and Mackenzie, and with the pathological knowledge culled from Robert Muir, Cowan acquired one of the first polygraphs, and from 1909 onwards he published papers on the arrhythmias in the *Quarterly Journal of Medicine* and *Heart*

Then came the 1914–18 War, and Cowan served in the Egyptian Expeditionary Force as consulting physician (1916–19)

After the war Cowan returned to his work in the Royal Infirmary and to consulting practice in the West of Scotland At this time the Ministry of Pensions appointed consultants in cardiovascular diseases in various regions in the British Isles, and Cowan was appointed to the West of Scotland These consultants held conferences twice a year in London, and these gatherings of men interested in the same cardiovascular problems were the forerunners of the Cardiac Club

In the first volume of the *British Heart Journal* Cowan has given an account of the birth of the Cardiac Club, and he was the first secretary (1922–5) and was chiefly instrumental in formulating our simple rules and regulations Up to the last war he was most regular in attendance and "just before his death he had received the current list of members and perused it thoroughly" (Miss Cowan) Though chiefly interested in cardiovascular disease a full list of his publications would show the variety of his clinical interests His *Diseases of the Heart* was a notable contribution based on personal experience, and was expanded in later editions when he had the collaboration of his friend, Willie Ritchie

He gave the George Gibson Lecture at the R C P , Edinburgh, in 1926, and the St Cyres Lecture at the National Hospital for Diseases of the Heart in 1930

He was Physician in Scotland to King George V, King Edward VIII, and King George VI (1925–40) In 1923 he was appointed Gentleman, the King's Body Guard for Scotland, and this select and honourable post pleased him immensely

At the beginning of the last war he began to do less work, and eventually retired to Kilmalcolm, Renfrewshire, where he died on August 15, 1947, aged 77 years His latter years had been much saddened by the sudden death of his wife and the tragic deaths of his two sons His only daughter had always been a great friend and was a constant solace to him in his declining years

His two friends, Geoffrey B Fleming and Archibald Harrington have sent us sympathetic and appreciative impressions of Cowan and his work in Glasgow

Fleming says "Cowan soon became recognized as one of the leading 'heart men' in Glasgow I think he was the first to install an electrocardiograph in his house Although he made full use of this instrumental method he always insisted that they could not replace clinical examination No one was more thorough in his examination of his patients and his case records show the extraordinary conscientiousness of his work Every case in his wards, whether of particular interest to him or not,

had to be most carefully examined and recorded He was the most conscientious man I have ever known

"As a teacher I think he was at his best with a small number of students at the bedside His systematic lectures owing to his rather peculiar mannerisms, would have been difficult to follow had it not been for his admirable printed notes

"As a man he was extremely reserved and on this account it was only those who knew him well who appreciated his true worth His loyalty to his friends was sometimes quixotic He never spoke hardly of those he disliked, I think he disregarded or avoided them He had many interests outside medicine—a keen and expert angler and an ardent philatelist He was very interested in modern history At the time of his death he had just completed a monograph on the Glasgow School of Medicine, largely based on the records he had of his medical ancestors I think he undertook this work in order to keep his mind active after his retirement from practice He could never be idle"

Harrington says "When he came to the Royal, much required to be done, and he did it in the face of a good deal of opposition He spent most of the day in the wards, exhausting most of his staff! He got things done in the end, as he always did, and put the wards on sound and modern lines

"In his earlier days he was not a very popular teacher His delivery was difficult to follow at times, but he gradually overcame this, and by the better type of student was soon recognized as an excellent teacher In his latter years he spoke well, and always concisely

"I have always greatly regretted that he did not get a University Chair He would have devoted himself to it, and been of immense value to the School

"Cowan was a slow worker, and spent a very long time in meticulous examination of his cases His industry was tireless He showed remarkable honesty in all his work and his criticism of it He welcomed the opinion of his juniors even when it directly countered his own, and was always prepared to discuss the differences It was our custom to write such opinions in the case sheets and initial them

"In addition to his sterling honesty and loyalty, he was absolutely devoid of professional jealousy and would do anything to help on his juniors Nearly all his later publications were 'joint' ones, to give the associated junior or juniors a chance

"I shall never forget the times we had with the polygraph In addition to Mackenzie's instrument, he and I devised a large three-lever one which was built by Kelvin and White, and ran on smoked papers I do not think any of us enjoyed it but Cowan himself, but we did lots of work In the wards were also investigated (1) insulin, (2) serum treatment and pneumonia, (3) liver extract Cowan loved charts and never wearied of them

"He was Principal Medical Officer to the Scottish Amicable Life Assurance Society, and did most excellent work there This work interested him greatly

"He was only mildly interested in sport—fished and shot, and in his earlier days, played a little cricket and golf He was also interested in philately He was always very keen that we should all have hobbies In fact he was always ready to advise you in any difficulty of life"

Dr J L Cochrane, an H P of Cowan's of forty years ago, testifies to the zeal that his Chief inspired in his assistants and the loyalty and affection with which they served him "When you served him he served you He discussed your future and told you that although he would not give you a roving testimonial he would always write what he thought of you for any appointment you applied for A grand Chief!"

The original Cardiac Club owed much to Cowan's enthusiasm As a physician he was already ripe in wisdom and experience, and had the youthful enthusiasm to practise and master the newer methods of cardiovascular investigation

In spite of his natural reserve and a certain shyness Cowan became a trusted friend of all of us Anything like push or self-advertisement was abhorrent to him and his only ambition was to search out and teach the truth

The Cardiac Club were lucky to have him at its inception and the British Cardiac Society benefited by his wise and steady counsel

W E Hume

SOME CARDIOLOGICAL CONTRIBUTIONS TO MEDICAL JOURNALS

BY

JOHN COWAN

On the presystolic murmur *Glas med J* (1898), **11**, 166

A case of acute endocarditis *Trans Path Clin Soc* (1899), 7, 237

Notes on empyemata in childhood *Glas Hosp Rep* (1900), 314

On obstruction of the coronary arteries *Trans Path Clin Soc* (1902), **9**, 49

Fatty degeneration of the myocardium *J Path* (1902), **8**, 177

The heart in acute disease *Ibid* (1903), **9**, 87

The fibroses of the heart *Ibid* (1903), **9**, 209

(with A R Ferguson) Five cases of congenital heart disease *Lancet* (1903), **2**, 952

The cardiac muscle *Edinb med J* (1904), 127

The influence of the acute infections upon the arteries *Glas med J* (1906), **66**, 88

On anæmia with enlargement of the spleen *Quart J med* (1907), **1**, 11

(with L Storey) the bruit de Roger *Glas med J* (1909), **72**, 425

(with D Macdonald and R J Binning) The venous pulse in paroxysmal tachycardia *Quart J med* (1909), **2**, 146

(with J Macleod and A R Paterson) A case of partial heart block. *Ibid* (1910), **3**, 115

(with W T Ritchie) Coupled rhythms of the heart *Ibid* (1910), **4**, 55

(with G B Fleming and A M Kennedy) Heart block and nodal rhythm in the acute infections *Lancet* (1912), **1**, 277

(with G B Fleming) The association between mitral stenosis and renal fibrosis *Quart J med* (1912), **5**, 309

Diseases of the heart 1st ed Arnold, London American ed Lea and Febiger, Philadelphia and New York

Auricular flutter *Glas med J* (1914), **1**, 128

(with D Macdonald) Chronic valvular disease of the heart *Ibid* (1914), **1**, 12

(with A W Harrington) A case of patent ductus arteriosus *Ibid* (1914), **1**, 101

(with W T Ritchie) The duration of ventricular systole *Lancet* (1920), **2**, 743

(with J K Rennie) Syphilis of the heart *Brit med J* (1921), **2**, 184

(with J C Bramwell) The clinical aspect of bundle branch block *Quart J med* (1925), **19**, 95

The causes of auricular fibrillation *Ibid* (1929), **22**, 237

(with J S Faulds) Syphilis of the heart and aorta *Brit med J* (1929), **2**, 285

St Cyres lectures The fibroses of the heart *Lancet* (1930), **2**, 1

Some observations on angina pectoris *Brit med J* (1931), **1**, 879

(with W T Ritchie) Diseases of the heart 3rd ed. London (1935)

The prognosis after infarct of the heart *Lancet* (1936), **1**, 356

Some disturbances of the rhythm of the heart *Brit Heart J* (1939), **1**, 3

ANGINA IN WOMEN

BY

V K SUMMERS

From the Walton Hospital, Liverpool

Received December 22, 1947

The relatively infrequent occurrence of angina of effort in women has been noted since Heberden (1772) first gave an account of this disorder Heberden observed in a lecture before the Royal College of Physicians of London, that he had seen the disease in 20 men and only 1 woman, and in a later publication (1786) wrote "I have seen nearly a hundred people with the disorder out of which number there have been 3 women" Mackenzie (1923) reported 40 women with angina of effort in a series of 280 cases, which gives a sex incidence of 7 to 1 in favour of men In more recent years, most investigators have found a sex incidence of 3–4 males to 1 female (White and Bland, 1931, White and Sharber, 1935, Levy and Boas, 1936, Bedford, 1936, Riseman and Brown, 1937, Gallavardin, 1938, and White, 1944) although Bourne and Scott (1938) found a predominance in males of 7 to 1 in 112 cases

In this paper, a series of 87 cases of angina of effort occurring in women will be analysed in an attempt to discover what ætiological factors are responsible for such a striking sex predominance The diagnosis of angina of effort, particularly in women, is fraught with many pitfalls, and to avoid these it was decided that only those who complained of substernal pain of constricting quality, with a quantitative relation to exercise and relieved by rest or nitroglycerin, would be included

TABLE I

AGE DISTRIBUTION

Age	*No of cases*
20–30	2
30–40	1
40–50	18
50–60	29
60–70	25
70–80	12

Although three quarters of all cases of angina of effort occur over the age of 50 (White, 1944), there is a considerable incidence in men under this age Only 3 cases occurred under 40 in women in this series, 2 had severe anæmia and the third had aortic regurgitation Glendy, Levine, and White (1937) in a 100 cases of coronary disease in young people found only 4 women under 40 and 3 of these had severe hypertension White and Mudd (1927) reported 8 patients with angina under 30, all had aortic incompetence The age incidence in this series corresponds closely with that given by other observers, Eppinger and Levine (1934) in 141 cases found the usual range of the age at onset to be 36–71 years

The rather high incidence (14 per cent) in patients over 70 years is unusual Foti (1937) in 20 cases over 70 found no women and Lian (1932) found only 17 occurring between the ages of 70–75 years in 638 cases of angina

THE EFFECT OF PREGNANCY AND THE MENOPAUSE

The effect of pregnancy on the incidence of angina was investigated and the results were as follows

No child, 12 cases, one child, 16 cases, two children, 22 cases, three children, 14 cases, four children, 9 cases, five children, 4 cases, six children, 6 cases, seven children, 4 cases

The inference to be drawn from the above data is that no close association between parity and the incidence of angina can be shown Moreover if pregnancy were of ætiological importance in the production of coronary atheroma, then it might be expected that deaths due to the consequence of this condition would occur with appreciable frequency in multigravida Sheehan and Sutherland (1940), in an analysis of 813 autopsy records of patients who died during pregnancy, failed to find atheromatous changes in the hearts of any of these

Menopause The first symptoms of angina of effort in 5 of these patients occurred at the time of the menopause , all had systolic blood pressures over 200 mm Most patients (76 per cent) experienced their first symptoms many years after the menopause

Hypertension

The incidence of hypertension, which for the purpose of this paper was assumed to be present if the systolic pressure was above 150 or the diastolic above 90 is shown in table II, an incidence of 84 per cent was found The blood-pressure readings recorded here are an average of several readings for each patient

TABLE II

Patients with High Blood Pressure

Systolic B P	No of cases	Diastolic B P	No of cases
150–160	4	90–100	14
160–170	6	100–110	26
170–180	4	110–120	18
180–190	12	120–130	8
190–200	7	130–140	2
200–210	12	140–150	4
210–220	10	150–160	4

Davis and Klainer (1940) in 61 cases of angina of effort found that 90 per cent of the women had hypertension compared with 60 per cent of the men The incidence of hypertension in reported cases of angina of effort varies (Riseman and Brown, 1937, 50 per cent, White and Bland 1931, 36 per cent, Kahn, 1926, 34 per cent)

In women a higher incidence of hypertension is reported (Davis and Klainer, 1940, 90 per cent, Levy and Boas, 1936, 92 per cent, and Eppinger and Levine, 1934, 100 per cent)

The frequent occurrence of hypertension in women suffering from angina of effort suggests a possible ætiological relationship, especially since most investigators record a much lower incidence in men

Coronary Artery Disease and Coronary Infarction

There were 34 patients with a history of one or more attacks of coronary infarction and a less certain history was obtained in 14 others A total of 57 patients showed cardiographic evidence, e g changes in the Q and T waves or in the S–T segment, suggestive of coronary artery disease and in 6 of this group necropsy revealed severe coronary atheroma The highest incidence of coronary disease occurred in the sixth and seventh decades in which 83 per cent of the patients gave, either a history of previous coronary infarction or showed suggestive cardiographic changes Willius and Smith (1932) reported moderately severe coronary atheroma in all cases in an autopsy study of 381 patients over 70 years and this no doubt is the explanation of the high incidence of coronary disease in the sixth and seventh decades in this series.

The incidence of previous coronary infarction varies in reported cases of angina of effort (Bland and White, 1931, 26 per cent, Riseman and Brown, 1937, 37 per cent, Bourne and Scott, 1938, 28 per cent, and Pazzanese and Montenegro, 1945, 72 per cent)

The incidence of evidence of coronary artery disease is high (65 per cent) in this series, but is lower than that reported by Harrison (1944) of 83 per cent

Other Diseases or Pathological States

Syphilis One woman of 23 had angina of effort with syphilitic aortic incompetence Jones and Bedford (1943) reported on 103 patients who had angina of effort of syphilitic ætiology and stated that all their patients under 40 had aortic incompetence They gave the incidence of aortic incompetence in angina as 5 per cent and this figure closely agrees with those given by Brooks (1927) and Warthin (1930)

Mitral Stenosis No case of mitral stenosis and angina was seen during the course of this investigation Blackford (1940) reported 2 cases of mitral stenosis and angina of effort and found no coronary lesions port-mortem in either case Levine and Kauvar (1942) found only 17 cases of mitral stenosis in 2832 cases of angina and coronary thrombosis, the average age of onset of anginal symptoms in these cases was 56 years

Myxœdema Two patients had myxœdema and angina of effort, both were over 50 and had hypertension The cardiogram of one showed a left bundle branch block, and of the other a Wilson type of branch block In both, the symptoms of angina were aggravated by thyroid therapy

Beaumont and Robertson (1939) suggested that two types of angina occurred in myxœdema, the first occurring during treatment with thyroid extract, whilst the second type occurred prior to treatment and improved following the administration of thyroid extract Hertoghe (1914) suggested that angina occurring in myxœdema and improving with treatment might be due to involvement of cardiac nerve fibres by myxœdematous infiltration Cases of this type have been reported by Peel (1943), Benestad (1937), Beach (1935), Ziskin (1930), and Sturgis (1926)

The majority of reported cases of angina of effort occurring in association with myxœdema appear to be due to independent heart disease Peel (1943) reported 12 cases of myxœdema and angina of effort, 10 had evidence of independent heart disease Aggravation of anginal pain during thyroid therapy has been noted by d'Abrami *et al* (1925), Sturgis and Whiting (1925), Means *et al* (1926), Fahr (1932),

Mussio-Fournier and Fisher (1940) and Mussio-Fournier (1942)

There is no evidence to suggest that myxœdema is an important ætiological factor in the majority of cases of angina

Hyperthyroidism No instances of hyperthyroidism and angina were observed in this series and most observers are agreed that there is no direct causal relationship between the two conditions and that there is usually some underlying cause for the angina Females usually predominate (Lev and Hamburger, 1928 and 1932, Haines and Kepler, 1930)

Diabetes Four patients were suffering from diabetes mellitus, all were over 55 and had hypertension In two it was known that diabetes had preceded the onset of angina of effort by at least 5 years Root and Graybiel (1931) noted that on the average diabetes preceded the angina by 9 years and that diabetic angina occurred most often in the seventh decade They found only 210 cases of angina in 7000 diabetics Nathanson (1932) who examined the coronary vessels of 100 diabetic patients post-mortem, found the greatest incidence of coronary atheroma occurred over 50, and Hepburn and Graham (1928) found cardiographic changes suggestive of coronary artery disease in 45 per cent of 123 diabetics Of the four patients observed in the present series, two had a negative T I and one negative T waves in the standard leads and in lead IV F

It is clear that diabetes mellitus is not an important ætiological factor in the majority of cases of angina occurring in women

Obesity The state of nutrition was observed in all cases and patients were grouped as thin, normal, and fat The results were as follows thin, 27 cases, normal, 37 cases, and fat, 13 cases

Obesity would not appear to be a significant factor in the ætiology, a finding that confirms those of Eppinger and Levine (1934)

Anæmia Herrick and Nusim (1918), were the first observers to draw attention to the occurrence of angina of effort in severe anæmia, but since this time frequent reports of its occurrence have appeared (Hunter, 1942, Stalker, 1937, Elliot, 1934, and Pickering and Wayne, 1943)

Wilkinson (1933), found only 3 cases of angina in 270 cases of anæmia and Willius and Giffin (1927) found only 43 patients with anginal symptoms in 1560 cases of pernicious anæmia A higher incidence has been reported by Coombs (1930), Pickering and Wayne (1943), and Hunter (1946),

In the present series 6 patients had anæmia and angina of effort Two were under 40 and had normal blood pressure, their anginal symptoms disappeared when their anæmia had been cured Three of the remaining patients had angina of effort after their blood had been restored to normal, the cardiogram of one showed a left bundle branch block and of the others inversion of T waves in leads I and II all 3 patients whose anginal symptoms persisted following cure of their anæmia had hypertension Lewis and Drury (1923) suggested that anginal pain accurring in anæmia was due to anoxæmia, but it has been shown that there is a raised cardiac output in anæmia and a raised venous pressure (Dautebrande, 1925, Stewart, Crane, and Deitrick, 1937, and Sharpey-Schafer, 1944) and this is the more probable explanation of the occurrence of anginal symptoms

Sometimes no coronary artery lesions have been demonstrated at necropsy in cases of anæmia presenting anginal symptoms (Elliot, 1934) and in spite of this many observers doubt if anæmia alone can cause cardiac pain It is difficult to avoid the conclusion in the two cases occurring in women under 40, whose cardiac pain was abolished when their anæmias were cured, that their anginal symptoms were solely due to anæmia There seems little doubt also that the 3 patients who retained symptoms of angina of effort even with normal blood pictures, had coronary artery disease

Tobacco and Alcohol In this group of patients, smoking was an infrequent habit Only 17 patients smoked regularly and a careful history in each case failed to reveal any relationship between tobacco smoking and the anginal attacks White and Sharber (1934–5) in 750 patients found a higher percentage of sufferers amongst teetotallers than amongst those who were not Pickering and Sanderson (1945) suggested that smoking precipitated an attack of angina only when an attack previously provoked by exertion had just subsided, and they concluded that tobacco did not cause constriction of the coronary vessels Nevertheless it has been shown by Short and Johnson (1939) that tobacco induces arteriolar constriction and an elevated blood pressure Bryant and Wood (1947) also demonstrated cardiographic changes of coronary ischæmia that were induced by tobacco smoking

There is, however, no evidence to suggest in the present investigations that tobacco smoking is of ætiological importance in the production of angina in women, whatever be its relation to the wider problem of this disease in males

Alcohol did not appear to be an important ætiological factor in the present series of cases

Cholecystitis The incidence of gall-bladder disease was very low Two patients had gall stones, 3 gave a history suggestive of chronic

cholecystitis and in 2 of these a Graham's cholecystogram revealed non-functioning gall bladders Bourne and Scott (1938) found 8 cases of cholecystitis in 112 cases of angina, in only 3 cases, however, was the presence of gall-bladder disease proved beyond doubt

Occupation and Environment These patients were studied during the past four years, 23 had undertaken factory work in addition to their household duties during the war years, but 7 had carried out such duties for a short time only All were hospital outpatients, but the incidence of angina amongst the large numbers of patients of this class seen during the period of those observations was very small, and it does not seem likely that there is any relationship between work in addition to household duties and the increased incidence of angina to-day, compared with fifty years ago It has not been practicable to take into account environmental influences in the earlier years of these patients' lives and to compare them with those obtaining in a woman's life of fifty years ago Such a comparison might give a clue to the increased frequency with which angina is encountered in women nowadays

SUMMARY

A series of 87 cases of angina of effort occurring in women has been analysed The highest incidence of the disease was in the sixth and seventh decades and the occurrence of the disease below the age of 40 was rare A high incidence of hypertension (84 per cent) was found and this observation is in accord with those of other observers Hypertension would appear to be an important factor in the ætiology of angina of effort in women, moreover the importance of hypertension in the diagnosis of this condition in women should be stressed The frequent occurrence of previous coronary infarction and of evidence of coronary artery disease suggest that coronary sclerosis is the most important factor in the ætiology of angina of effort in women Other factors, e g myxœdema, anæmia, cholecystitis, pregnancy, tobacco, alcohol and occupation appear to be of minor importance only in the ætiology

I should like to thank Dr H Wallace-Jones for his helpful criticism and advice and for permission to include in this series cases seen at the Heart Department of the Liverpool Royal Infirmary I should like also to thank Dr E Noble Chamberlain for his valuable criticism and advice, and Dr H H MacWilliam for permission to include cases seen at Walton Hospital, Liverpool

REFERENCES

d'Abrami, P, Buite, M, and Heitz, J (1925) *Bull Mem Soc méd Hôp Paris*, **47**, 172
Beach, C H (1935) *J Amer med Ass*, **105**, 871
Beaumont, G E, and Robertson, J D (1939) *Lancet*, **1**, 682
Bedford, D E (1936) *Brit Encyclop med Pract*, vol 1, Lond.
Benestad, G (1937) *Nord med Tydskr*, **14**, 1741
Bernstein, S S, and Ginzburg, L (1942) *J Mt Sinai Hosp, N Y*, 9, 142
Blackford, L M (1940) *Amer Heart J*, **20**, 492
Bourne, G, and Scott, R B (1938) *Brit med J*, **1**, 55.
Brooks, H. (1927) *Trans Ass Amer Phys*, **42**, 31
Bryant, J M, and Wood, J E (1947) *Amer Heart J*, **34**, 20
Coombs, C F (1930) *Quart J Med*, **23**, 233
Dautebrande, L (1925) *Compt rend Soc Biol*, **93**, 1029
Davis, D, and Klainer, M J (1940) *Amer Heart J*, **19**, 198
Elliot, A H (1934) *Amer J med Sci*, **187**, 185
Eppinger, E C, and Levine, S A (1934) *Arch intern Med*, **53**, 120
Fahr, G (1932–3) *Amer Heart J*, **8**, 91
Foti, A. (1937) *N Y St J Med*, 37, 2018
Gallavardin, L (1938) *J Méd Lyon*, **19**, 527
Glendy, R. E, Levine, S A., and White, P D (1937) *J Amer med Ass*, **109**, 1775
Haines, S F, and Kepler, E J (1930) *Med Clin N Amer*, **13**, 1317
Harrison, T (1944) *Amer J med Sci*, **27**, 322
Heberden, W (1772) *Med Trans roy col Phys Lond*, **2**, 59
—— (1786) *Commentaries on History and Cure of Disease*, p 366
Hepburn, J, and Graham, D (1928) *Amer J med Sci*, **176**, 782
Herrick, J B, and Nuzim, F R (1918) *J Amer med Ass*, **70**, 67
Hertoghe, E (1914) *Med Rec N Y*, **86**, 489
Hunter, A. (1946) *Quart J Med*, **15**, n s, 107
Jones, E, and Bedford, D E (1943) *Brit Heart J*, **5**, 107
Kahn, M H (1926) *Amer J med Sci*, **172**, 195
Lev, M W, and Hamburger, W W (1928) *Amer Heart J*, **3**, 672
——, —— (1932) *Ibid*, **8**, 109
Levine, S A (1930) *Ann intern Med*, **4**, 67
—, and Kauvar, A J (1942) *J Mt Sinai Hosp N Y*, **8**, 754
Levy, H, and Boas, E P (1936) *J Amer med Ass*, **107**, 97
Lewis, T, and Drury, A N (1923) *Heart*, **10**, 301
Lian, C (1932) *L'Angine de Poitrine*, Masson, Cie, Paris
Mackenzie, J (1923) *Angina Pectoris*, Oxford Med. Publ, p 118
Means, J H, White, P D, and Krantz, C I (1926) *Boston med surg J*, **195**, 455
Mussio-Fournier, J C, and Fischer, J T (1940) *Presse méd*, **48**, 364
—— (1942) *Proc Mayo Clin*, **17**, 212

Nathanson, M H (1932) *Amer J med Sci*, **183**, 495
Pazzanese, D, and Montenegro, O (1945) *Amer Heart J*, **30**, 599
Peel, A A F (1943) *Brit Heart J*, **5**, 89
Pickering, G W, and Wayne, E J (1943) *Clin Sci*, **1**, 305
——, and Sanderson, P H (1945) *Ibid*, **5**, 275
Riseman, J E, and Brown, M G (1937) *Amer Heart J*, **37**, 209
Root, H F, and Graybiel, A (1931) *J Amer med Ass*, **86**, 925
Sharpey-Schafer, E P (1944) *Clin Sci*, **5**, 125
Sheehan, H L, and Sutherland, A M (1940) *J Obstet Gynæc Brit Emp*, **47**, 597
Short, J J, and Johnson, H J (1939) *J Lab clin Med*, **24**, 590
Stalker, H (1937) *Ann intern Med*, **10**, 1172
Stewart, H J, Crane, N F, and Deitrick, J E (1937) *J clin Invest*, **16**, 431
Sturgis, C C, and Whiting, W B (1925) *J Amer med Ass*, **85**, 2013
—— (1926) *Boston med surg J*, **195**, 351
Warthin, A S (1930) *Amer Heart J*, **6**, 163
White, P D, and Bland, E F (1931) *Amer Heart J*, **7**, 1
——, and Mudd, S G (1927) *Ibid*, *J*, **3**, 1
——, and Sharber, T (1935) *J Amer med Ass*, **102**, 655
—— (1944) *Heart Disease*, Macmillan & Co, p 816
Wilkinson, J F (1933) *Quart J Med*, **26**, 281
Willius, F A, and Giffin, H Z (1927) *Amer J med Sci*, **174**, 30
——, and Smith, H L (1932–3) *Amer Heart J*, **8**, 170
Zimmerman, S L, and Barnett, R (1944) *Ann intern Med*, **21**, 1045
Ziskin, T (1930) *U S Veterans Bur med Bull*, **6**, 24

CLINICAL VALUE OF UNIPOLAR CHEST AND LIMB LEADS

BY

C W CURTIS BAIN AND E McV REDFERN

From the Harrogate General Hospital

Received December 30, 1947

Chest leads were first employed in myocardial infarction by Wood and Wolferth in 1932 Before that time their use was limited to the elucidation of the auricular arrhythmias The original lead IV was an antero-posterior lead since it was hoped that this would register changes in a plane at right angles to the standard leads In 1933 Wood and others found that the best results were obtained when the exploring electrode was placed either on or just internal to the apex, and they also used a lead in which the remote electrode was placed on the left leg Later this apical lead came to be known as lead IV F, or IV R when the right arm was used as the remote electrode In 1934 Wilson and others, seeking to reproduce as nearly as possible the same conditions as in animal experiments when the electrode can be placed directly on the epicardium, devised their central terminal method of obtaining a remote electrode approximately at zero potential They called leads taken in this way V leads (V for voltage) They also chose six positions on the chest for the exploring electrode, extending from the fourth intercostal space to the right of the sternum (V 1) to the mid-axillary line at the level of the apex (V 6), as subsequently recommended by the American Heart Association (1938) These methods were not generally accepted at first, and leads IV R and F are still widely used We have tried to determine what advantages may be gained from the use of multiple unipolar chest leads

The principles underlying the unipolar method are based upon the equilateral triangle hypothesis which was propounded by Einthoven, Fahr, and de Waart in 1913 They stated that, having regard to the comparative remoteness of the extremities, the heart might be regarded as being in the centre of an equilateral triangle, and that, therefore, the algebraic sum of the potentials at the three points of the triangle at any given moment in the cardiac cycle was zero for all forces parallel to the plane of the triangle So if the three limbs were used as the remote electrode, instead of one, a remote electrode at zero potential would be obtained, and such a lead would be unipolar since it would record only the changes in potential of the præcordial electrode The Einthoven hypothesis is only applicable to forces parallel to the plane of the triangle, and the cardiac vector moves in three dimensions, but Wilson *et al* (1944) have adduced considerable evidence to the effect that the perpendicular forces are small and do not exceed 0 3 mv For practical purposes these leads can be considered to be unipolar

Unipolar and Bipolar Leads

Technique The apparatus required to take V leads consists of three limb terminals which are brought together at a central terminal The right arm electrode from the galvanometer is attached to the central terminal, the three limb terminals are attached to the limbs The left arm electrode from the galvanometer is used in the ordinary way as the exploring electrode on the chest Wilson *et al* (1934) interposed resistances of 5000 ohms on each limb terminal, but Goldberger (1942) published curves taken with and without the resistances and they were identical We have followed the Goldberger method and have not interposed resistances

Unipolar Limb Leads When using a unipolar technique it is possible to obtain the potentials at any point on the surface of the body The original method of taking unipolar limb leads was to attach the exploring electrode on to the limb to be examined, having two electrodes on that limb But the deflections by this method were sometimes small and difficult to measure Goldberger (1942) introduced a modification that increased the size of the deflections by a half while their form was left unaltered He substituted the exploring electrode for the V terminal on the limb to be examined, allowing that V terminal to hang loose To take VR (the right arm unipolar lead) the exploring electrode is attached to the right arm and a V

terminal to the left arm and left leg In taking VL (the left arm lead) and VF (the left leg lead) the exploring electrode is attached to the left arm, and the left leg respectively, with V terminals on the other two limbs

Bipolar Leads—In the standard leads the two points are connected and the galvanometer, which is interposed, records the difference in potential between the two points When the two points are equidistant from the heart, the effect of each upon the cardiogram is approximately equal In lead I the galvanometer is arranged—or the polarity is such—that a state of relative positivity at the left arm is represented by an upward movement of the fibre Since it is the difference between the potentials at the two arms which is recorded in lead I, the potentials at the right arm must be subtracted algebraically from those at the left arm Thus, if the T deflections at the right arm are −2 mm (which equals a potential of −0 2 mv) and are +1 mm at the left arm, the deflections in lead I will be +3 mm Since the potentials at the right arm are usually negative, the deflections in lead I will generally be more positive than at those at the left arm This is the reason why an upright T is sometimes found in lead I in anterior infarcts although T is negative in lead VL, the left arm unipolar lead In lead III a relative state of positivity at the left leg results in an upward movement of the fibre Thus, if T at the left leg equals +2 mm and is +1 mm at the left arm, in lead III it will be +1 mm

The chest leads CR and CF are also bipolar leads, but since the extremity, or remote, electrode is so much farther from the heart than the chest electrode, the influence it exercises is much less Wilson (1944) has estimated that the size of the deflections at the præcordia is from three to five times that at an extremity The influence of the extremity electrode is, therefore, about one-quarter that of the chest electrode But, when multiple chest leads are used, and the potentials at one point of the chest compared with those at another, any influence at all from the remote electrode is undesirable since it may distort the curve

It has recently been suggested (Wallace and Grossman, 1946, Hoyos and Tomayo, 1947) that in practice the differences between CR, CF, and V leads are so slight as to be negligible Since a CR lead equals approximately C−VR/4, and a CF lead equals C−VF/4, the distortion to be expected in any given case can be estimated if the VR and VF leads are available If the Goldberger augmented method of obtaining the unipolar limb leads has been used, the deflections must be reduced by one-third the equation then is CR (or CF)=C−VR (or VF)/6

A series of 300 unipolar limb leads were examined with regard to this point The T waves were flat in 49 cases in VR and 47 in VF They were ±1 mm in 111 and 117 respectively, ±2 in 62 an 65, ±3 in 44 and 40 Thus in 89 per cent the T deflections were 3 mm or less, which should give a distortion of not more than 0 5 mm, and this is negligible In the remaining 11 per cent, however, the distortion is appreciable Fig 1 was taken from a patient with mitral and aortic disease Standard leads show left axis deviation, the T waves are

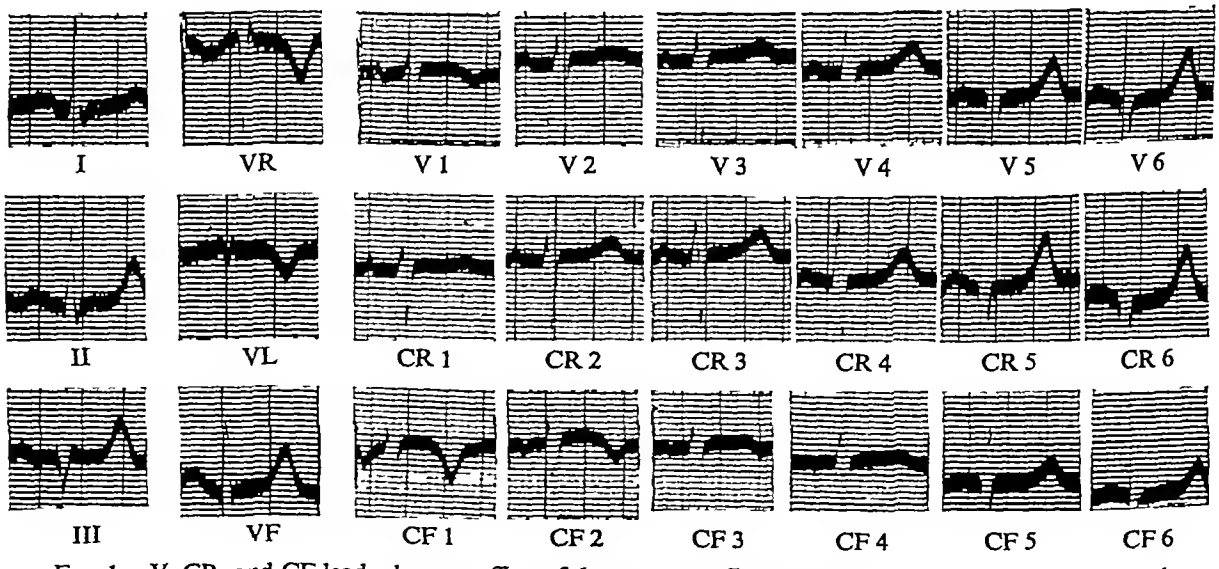

FIG 1 —V, CR, and CF leads showing effect of distortion on CR and CF leads from the right arm and left leg respectively For details see text.

prominent in leads II and III Unipolar limb leads show that the heart is semi-vertical T in VR measures −6 mm in VF, T measures + 6 mm V, CR, and CF leads were taken with the exploring electrode on position I The exploring electrode was then moved to the second position and the process repeated The CR leads are everywhere more positive than the V leads, CF leads are more negative T in V 1 is negative, as it frequently is in health In CR it is positive T is negative in CF 1, 2, and 3, and just upright in CF 4 R waves are more positive and S waves less negative in CR leads than in V leads This destroys the balance of the series While the V leads show slight, but definite, left ventricular hypertrophy, the CR series is within normal limits

Fig 2 was taken from a patient recovering from an anterior infarct The position of the heart was semi-vertical Six months previously there was bowed inversion of T in leads V 1–V 4 Now V 1 and V 2 have negative T waves, T in V 3 is diphasic, T in V 4–V 6 is positive but not much so In the CR series T is positive from 1–6 In the CF series it is negative from 1–6 The CR leads are, therefore, normal while the CF leads suggest an anterior infarct, and the difference between them is due to distortion from the right arm and left leg respectively

Fig 3 shows the type of distortion that may be expected in the different positions of the heart in CR and CF leads In CR leads the distortion is positive in all positions of the heart except in very horizontal or very vertical hearts (extreme left and right axis deviation) when it is negligible It is greatest in the semi-horizontal or semi-vertical positions In CF leads the distortion varies with the position of the heart With a normal position the deflections in lead VF are sufficiently small to make CF leads accurate enough for ordinary purposes In the semi-horizontal position the deflections are so small as to make CF leads in that position possibly the most accurate of any With horizontal hearts there is increasing positive distortion, but in general CF leads are good in all these positions When the heart is vertical, however, large R waves and upright T waves are seen in VF leads, causing a negative distortion, which may lead to the recording of negative T waves in CF leads due only to the influence of the left leg Nor is it possible to be sure that the heart does not lie vertically unless unipolar limb leads are taken, since standard curves may show left axis deviation in such cases if there is left ventricular hypertrophy, as in Fig 1

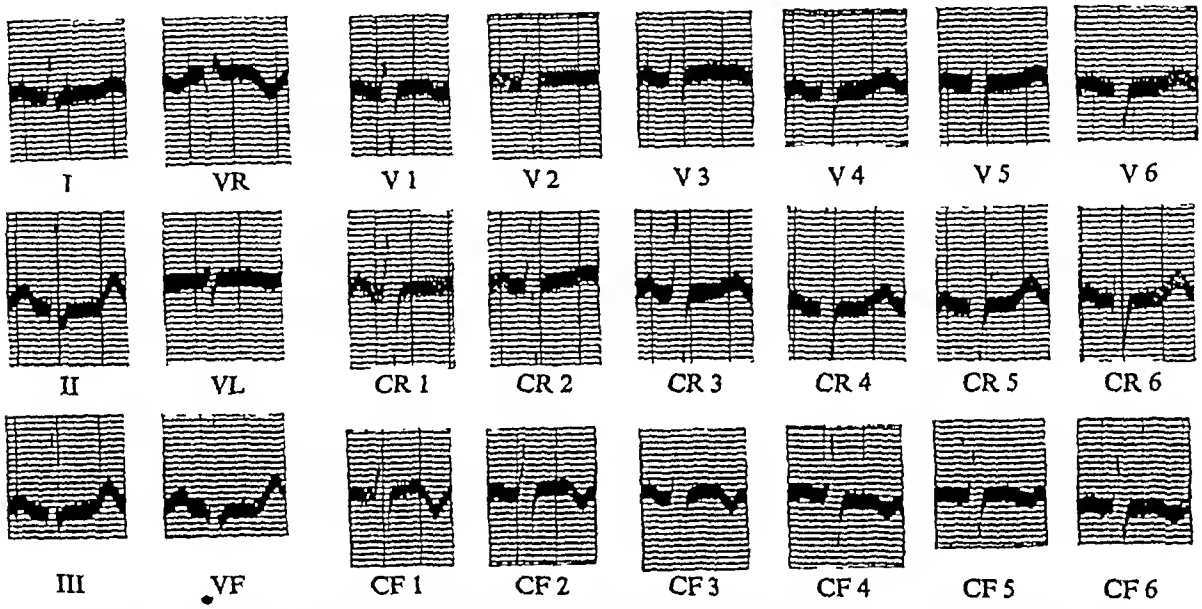

Fig 2—V, CR, and CF leads from a patient with previous anterior infarction CR leads are normal CF leads have negative T waves from 1–6

Principles underlying Chest Lead Interpretation Active heart muscle is electrically negative to inactive muscle The impulse for contraction passes down the Purkinje tissue in the subendocardial zone and reaches the ventricular cavities almost at once The ventricular cavities are, therefore, negative throughout the whole of the QRS The impulse then spreads outwards through the ventricular muscle, and, as it does so, the muscle which has been activated will be negative, while in front of the

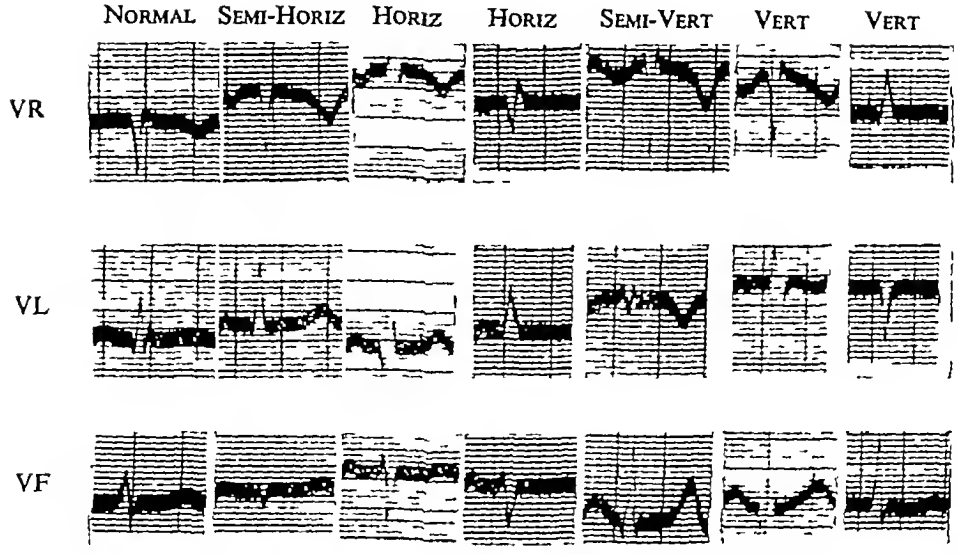

FIG 3 —Unipolar limb leads showing changes in different positions of the heart

advancing head of the wave there will be a zone of positivity This zone of positivity is reflected to the surface of body and causes the positive R to be the main initial deflection to be recorded in health When the impulse reaches the surface of the ventricle, a negative charge is reflected to the surface of the body, and a negative downward deflection, called the intrinsic deflection by Lewis, occurs Whether or not this downward deflection is prolonged into an S wave depends on whether that part of the heart muscle under the exploring electrode has been activated early or late in relation to other parts of the ventricular muscle By the time the impulse reaches the surface of the right ventricle, the left ventricle will not be fully activated The right ventricle will then become negative to the left and an S wave will be recorded in leads to the right of the præcordia such as V 1 or V 2 When, however, the impulse reaches the epicardium over the thickest part of the left ventricle (lead V 5 or V 6), the whole heart will be in systole No current flows, since the QRS phase is over, and the fibre comes to rest at zero potential, S being absent *As the electrode is moved over the præcordia from right to left, an R followed by a deeper S in leads V 1 and V 2 gives place to an R without S in V 5 and V 6 Changes in this normal sequence of events enables the diagnosis of unilateral ventricular hypertrophy to be made, and the side of the lesion in bundle branch block to be determined*

Unipolar Limb Leads and the Position of the Heart When the position of the heart is normal, the aorta and the pulmonary artery, as they arise, point upwards towards the right shoulder Lead VR which enters the chest, so to speak, through the right shoulder will face these vessels and so reflect to a great extent the state of the ventricular cavities Since these are negative throughout the whole of the QRS, lead VR, except in extreme rotation of the heart, has negative deflections VL, the left arm lead, reflects the potentials on the anterior surface of the left ventricle, while VF, which enters the chest through the left dome of the diaphragm, reflects the potentials of the diaphragmatic or posterior surface of the left ventricle When the position of the heart is normal, both these leads have positive deflections

If the heart rotates clockwise, becoming more vertical, the aorta and pulmonary artery, as they arise, will tend to point directly upward or midway between the two shoulders Lead VL will then become similar to VR, or to leads to the right of the præcordia, and have negative deflections An S wave in lead VL shows that the heart is vertical When R and S are small and equal, the position is semi-vertical A vertical position of the heart occurs in long narrow chests, in emphysema, and in right-sided hypertrophy

If an anti-clockwise rotation occurs, the heart becomes horizontal A horizontal position is found in left-sided hypertrophy or when the left diaphragm is high as in obesity or in sthenic types An S wave then appears in lead VF, or, if the position is semi-horizontal, the deflections are small For this there are two explanations According to Wilson *et al* (1944) the aorta, issuing more horizontally to the right, comes to face almost midway between the right shoulder and the diaphragm, and consequently lead VF will resemble VR, or V 1 and V 2, and have negative deflections In this view if the

deflections in VF resemble those on the right side of the præcordia (V 1 and V 2) while VL resembles those on the left (V 5 and V 6) the position of the heart is horizontal, if VF resembles V 5 and V 6, while VL is like V 1 and V 2, the heart is vertical In this interpretation an S wave in lead VF means that the heart is horizontal except in certain cases of right branch block (see Fig 11)

Goldberger (1944) in his explanation points out that the voltage of the negative potentials in each ventricular cavity will depend on the mass of muscle involved Since the left ventricle has nearly always a greater mass than the right, the potentials in the cavity of the left ventricle will be more negative than those on the right, and, should the two sets of potentials oppose each other, the stronger potentials on the left side will overcome those on the right

When the heart is normal in position, lead VF, which enters the chest through the left diaphragm, will face about equally the advancing wave in each ventricle As a result the potentials will be positive When the heart is placed vertically lead VF will face more of the left ventricle than of the right, and the potentials will become correspondingly more positive still When, however, the heart is horizontal lead VF will face more of the right ventricle, but it will also face the negative potentials at the tail of the wave in the left ventricle which has now come to lie more superiorly These stronger negative potentials from the left ventricle overcome the positive potentials in the head of the wave in the right ventricle, with the result that small but negative waves occur in lead VF In this view an S wave in lead VF always means that the heart is horizontal

Present Series

Cases with cardiac enlargement were specially selected at first since the intention was to try to establish more satisfactory criteria for unilateral ventricular hypertrophy than was afforded by axis deviation Normal subjects of differing habitus

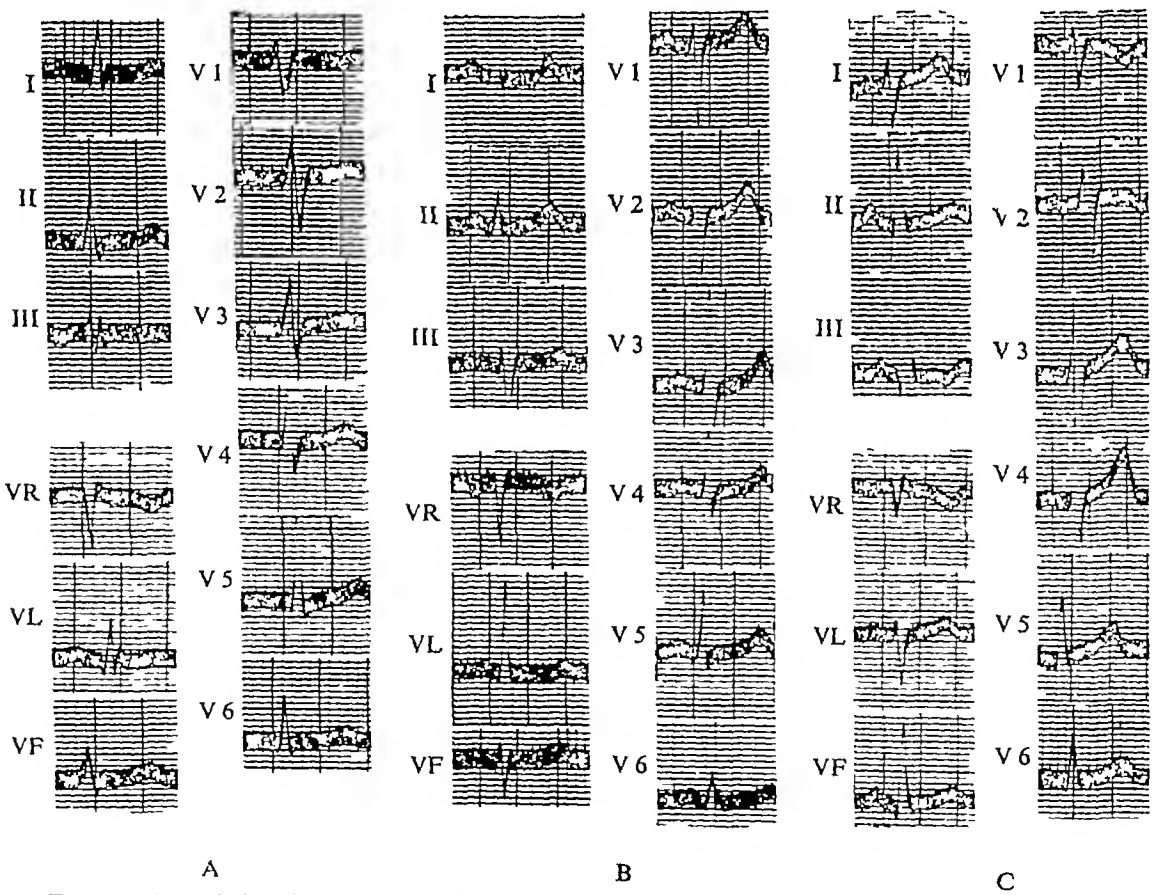

Fig 4 —Normal chest leads (A) Heart in normal position Chest leads show S to have twice the amplitude of R in V 1 and V 2 while S is diminutive in V 5 and V 6 VL and VF are positive (B) Heart horizontal Left axis deviation Note S in VF (C) Heart vertical Right axis deviation Note S in VL T is inverted in V 1 and V 2

were also examined to find the effect of varying positions of the heart upon the electrocardiogram Later complete 12 lead electrocardiograms were taken on all patients with infarcts and bundle branch block

Normal Præcordial Leads

In leads V 1 and V 2 an R wave is followed by an S wave of about double the amplitude (Fig 4A) In leads to the left of the præcordia (V 5 and V 6) an R only is seen, S being absent or diminutive The point where the complexes change from a predominant S to a predominant R is called the transitional point, and is situated about the level of V 3, which is placed approximately over the interventricular septum

The T wave in V 1 is frequently inverted in health, and this has no significance It may also be inverted in V 2 if the heart is placed vertically In children inversion of T may also involve V 3, but this is exceedingly rare in adults

Normal præcordial leads were found in 49 cases in whom ventricular hypertrophy was judged to be absent on clinical grounds

In 33 cases the heart was normal In these the heart was in normal position in 9 (Fig 4A), horizontal or semi-horizontal in 9 (Fig 4B), and vertical or semi-vertical in 15 (Fig 4C) Both left and right axis deviation were frequent, the electrical axes varying from +110 to −70 The high proportion of abnormal positions was due in part to the selection of cases for the purpose of the investigation, but it is undoubtedly more common to find a vertical heart in a normal subject than a horizontal

In 16 cases some clinical abnormality was present In 9 there was moderate elevation of the blood pressure but no cardiac enlargement could be made out on screen examination The remainder were made up of patients with angina pectoris (3), heart block (2), auricular fibrillation (1), goitre (1)

The position of the heart in these patients was normal in 11, horizontal in 4, and semi-vertical in 1

Left Ventricular Hypertrophy

There are five criteria of left ventricular hypertrophy (Fig 5)

(1) The R wave in leads to the right (V 1, V 2, and V 3 and occasionally V 4) becomes diminutive We have adopted as a minimum requirement that the R wave should have an amplitude of no more than one quarter that of the S wave which should measure at least 12 mm in any one of these leads

(2) Inverted T waves are seen in V 4, V 5, or V 6 Similar changes occur in lead I, but not so frequently as in the chest leads They must be distinguished from inversion due to digitalis (Fig 6A)

(3) The transitional point swings to the left Minor changes in the transitional point are without significance This criterion was judged to be present when the transitional point reached V 4 or further to the left

(4) An increase in voltage of the deflections may be seen

(5) The QRS increases to 0 09 secs or more

Left ventricular hypertrophy was judged to be present on clinical grounds in 120 cases Most of the patients had hypertension, and cardiac enlargement was seen on screen examination Others had aortic disease Congenital heart lesions were present in a few Those showing bundle branch block or evidence of infarction are not included in this group

Diminution in the R wave and increase in the S wave in leads over the right side The R waves had an amplitude of not more than one quarter that of the S wave, which measured 12 mm or more in either V 1, 2, 3, or 4 in 103 of these cases, or 86 per cent

Left axis deviation was present in 59 of this group or 57 per cent The electrical axes varied from +18 to −80, with one exception in a bizarre curve in a boy with a congenital lesion in whom it was +58 The position of the heart was horizontal in 23 of the cases, semi-horizontal in 19, and normal in 17

Left axis deviation was not present in 44 cases, or 43 per cent The electrical axis in this group varied from +80 to +12 The standard leads in some of these showed right axis deviation (Fig 6B) In only two was the heart semi-horizontal it was semi-vertical in 13 and vertical in 6, the remainder being normal in position The position of the heart had, therefore, a material influence upon the appearance of left axis deviation, which was present in only 57 per cent of those in whom left-sided hypertrophy could be diagnosed from the chest leads

Inversion of the T wave in V 4, 5, and 6 The T waves were inverted in leads over the left side in 39 cases or 32 per cent A corresponding inversion of the T wave was found in lead I in 16 patients, and in lead VL in 18 Digitalis was a factor in a further 22 cases In 9 cases inversion of the T wave was found in the absence of the first criterion 3 of these had anasarca which lowers the voltage of the chest leads R waves were not present in V 1 or V 2, but the S waves were less than 12 mm , 2 of these subsequently showed characteristic deep S waves One other patient had kypho-scoliosis with considerable distortion of the chest In the remaining five cases no cause could be found for the absence of the first criterion

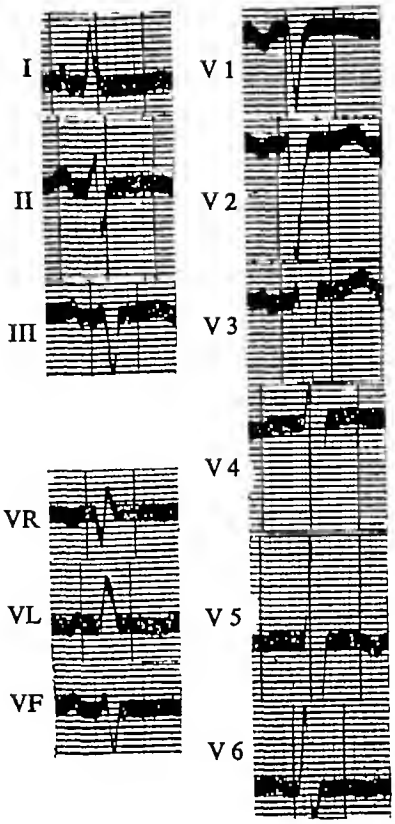

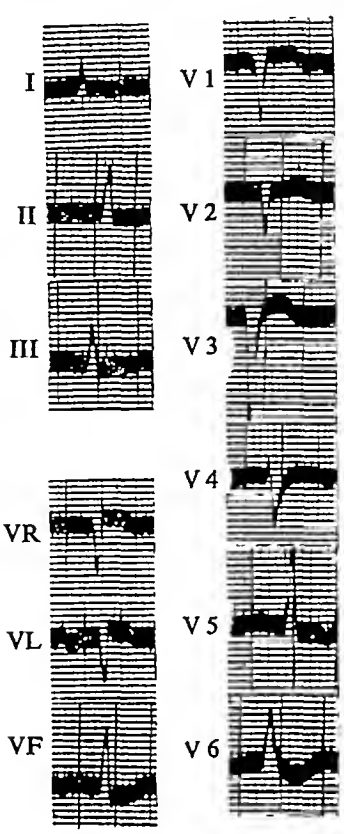

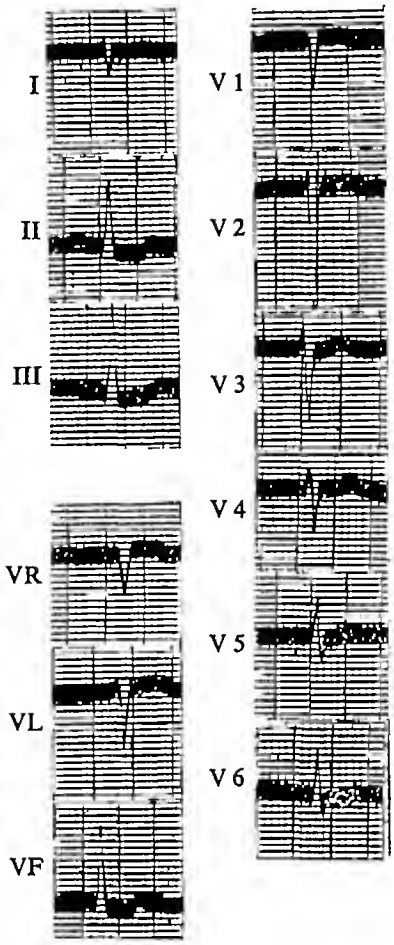

FIG 5 A FIG 6 B

FIG 5 —Left ventricular hypertrophy Left axis deviation Horizontal heart Diminutive R waves V 1, V 2, V 3, with S over 12 mm Inversion of T in V 5 and V 6 Transitional point between V 4 and V 5 Large complexes QRS 0 10 second. From a patient with chronic interstitial nephritis Left ventricle much thickened at autopsy

FIG 6 —Left ventricular hypertrophy (A) With a normal electrical axis Auricular fibrillation Absent R waves in V 1, V 2, V 3 with deep S in V 3 Transitional point between V 4–V 5 Inversion of T in V 4 and V 5 Inversion in V 6 is due to digitalis The heart is vertical From a patient with hypertension and congestive failure At autopsy both ventricles much hypertrophied Numerous pulmonary infarcts (B) With right axis deviation Mitral stenosis, auricular fibrillation, and hypertension Heart enlarged to left and right Congestive failure Diminutive R waves in V 1 and V 2 with deep S in V 2 Transitional point between V 4–V 5 The heart is vertical

Taking the two criteria together, evidence of left ventricular hypertrophy was present in 112 of the 120 cases or 93 per cent Excluding those who had received digitalis they were both present together in 30 cardiograms or 25 per cent

Shift in the Transitional Point to V 4 or further to the left This occurred in 69 records, but it was also found in 14 patients in whom there was no clinical evidence of left-sided hypertrophy More than any of the other criteria, the transitional point depends upon the correct positioning of the electrodes A transitional point to the left of V 4, which occurred in 26 cases is almost always evidence of considerable left ventricular hypertrophy, but other criteria will then be present By itself a shift in the transitional point is unreliable, and is not acceptable alone as evidence of left-sided hypertrophy

Increase in Voltage of the Complexes In left-sided hypertrophy the voltage of the S wave in leads to the right and of the R wave in leads to the left may be very large But this sign is variable, and depends upon many factors, which affect the

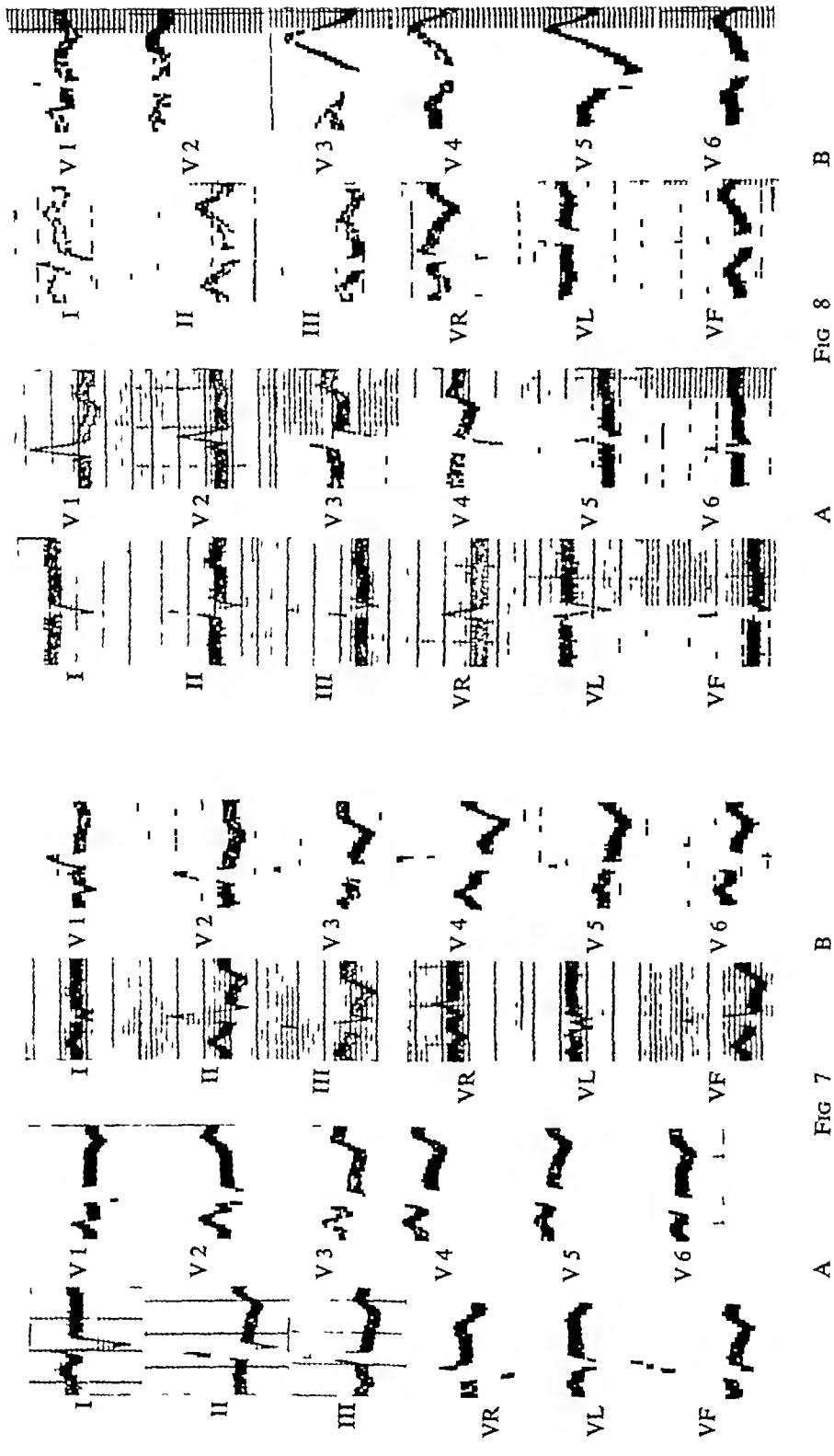

FIG 7 —Right ventricular hypertrophy (A) Diminutive primary R and primary S in V 1, followed by large secondary R from the down-stroke of which arises the T wave S waves in V 4, V 5, and V 6 T is inverted in V 1, V 3, V 4, V 5, and V 6 The heart is vertical From a case of auricular septal defect (B) Small Q waves in V 1, V 2, V 3, and V 4 followed by a large R An S wave seen in V 6 T is inverted from V 1–V 6 due to digitalis The heart is vertical From a patient with Lutembacher's disease and congestive failure

FIG 8 —Right ventricular hypertrophy (A) Small primary R followed by large secondary R in V 1 and V 2 S waves appear in V 3 and V 4 and are diminutive in V 5 and V 6 T is inverted in V 1, V 2, V 3, and V 4 A digitalis effect is seen in lead II, III, V 5, and V 6 The heart is vertical From a case of mitral and tricuspid disease with auricular fibrillation and congestive failure (B) Small Q followed by large R with a small S in V 1 only T is inverted in V 1 The heart is vertical From a girl of 10 with recurrent rheumatic fever and mitral stenosis

distance between the epicardium and the electrode Anasarca, pulmonary œdema, or a thick chest wall will tend to diminish the size of the deflections (Lapin, 1947) Dilatation of the ventricle, bringing the epicardium nearer to the chest wall, may increase them (Bayley, 1947) Large complexes may occur in health, and as a criterion of ventricular hypertrophy, we have found it of no value

Increase in the QRS Breadth The QRS was increased to 0 09 second, or more, in 9 advanced cases only, where it was also prolonged in the standard leads (Fig 5)

In 9 patients with left ventricular enlargement no criteria of hypertrophy were found in the chest leads In one the record was taken during a paroxysm of auricular tachycardia Although the R waves were absent in V 1, the S waves were only 9 mm Two days later the paroxysm had stopped and deep S waves were then present Two more cases developed characteristic changes in a later record Four had hypertension with slight to moderate cardiac enlargement, and no reason could be found why the chest leads were normal In all, the R waves were small in leads V 1 and V 2, varying from 1 to 2 mm , but the S waves were from 9 to 11 mm In two patients the chest leads were quite normal, but both had considerable displacement of the heart, one from an old empyema, one from kypho-scoliosis

In 9 cases the first criterion was present without clinical evidence of left ventricular enlargement In 5 of these some hypertrophy may in fact have been present One was a young woman admitted to hospital with acute pulmonary œdema, who gave a history of two similar attacks for which she had been kept in bed a month and 6 weeks respectively her lung roots were prominent but the heart appeared to be normal in size Another was a soldier with a history of acute nephritis three years previously and a relapse a month before when the blood urea was 72 The third had myxœdema with a B M R of −35 per cent, the heart did not seem to be enlarged, but the pulsations were feeble Two cases were seen in surgical wards and skiagrams were not taken The first had gangrene of a toe with moderate elevation of the blood pressure, and the second was very obese and had had a pulmonary embolism after the removal of an umbilical hernia

Of the remaining 4 cases, one had angina pectoris, 2 had moderate hypertension, but the heart was not enlarged In the last patient it is possible that an error in standardization may have been made Coronary occlusion had been suspected but the pain was due to gall stones and the heart was normal Two years later the chest leads were normal

Right Ventricular Hypertrophy

The characteristic changes of right ventricular hypertrophy are seen in lead V 1 The intrinsic deflection is delayed owing to the time taken by the impulse to reach the surface of the thickened right ventricle A late R wave is seen S is either absent or diminutive There may be a small primary R followed by a primary S (Fig 7A) or else a small Q (Fig 7B) Sometimes these small primary deflections appear as a notch on the upstroke of R (Fig 8A) These features may be limited to V 1 (Fig 8B) or may be seen also in V 2, V 3, and V 4 (Fig 7B) In leads to the left of the præcordia S waves are usually seen, but there is no abrupt transitional point as occurs in left ventricular hypertrophy The T waves may be inverted in any of the præcordial leads

Although the changes in V 1 are characteristic, a considerable amount of right ventricular hypertrophy must be present before they appear, since they indicate that the thickness of the right ventricular wall approaches that of the left The position of the heart is always vertical when the præcordial leads show right ventricular hypertrophy

In some cases where V 1 was normal, evidence of right ventricular hypertrophy was found in lead V3R, in which the electrode is placed on a point midway between the right sternal border and the right mid-clavicular line (Myers, Klein, and Stofer, 1948)

Nineteen cases showed the changes of right ventricular hypertrophy 10 had advanced mitral stenosis 8 had congenital heart disease, comprising 6 cases of auricular septal defect, and 2 of pulmonary stenosis One case with old standing Pott's disease is included since the R wave in V 1 was greater than the S, but the curve was bizarre from the gross distortion of the chest

Eight cases had clinical evidence of right ventricular hypertrophy but the præcordial leads were normal 3 of these had mitral stenosis, 4 had asthma or severe bronchitis, 1 had an auricular septal defect, but the heart was displaced to the left, and probably rotated, by scoliosis In two patients with mitral stenosis, the heart was normal in position In the remainder it was vertical

Bundle Branch Block

In bundle branch block the intrinsic deflection is delayed on the side of the lesion, but occurs early on the healthy side The QRS has usually a slightly longer duration than in standard leads

In *left branch block* R is diminutive or absent in V 1 and V 2 and a deep broad S wave occurs (Fig 9A) In leads over the left side such as V 5 and V 6 a

large broad notched R is seen The position of the transitional point is very variable and the R wave may not appear until V 6 (Fig 9B) This seems to happen particularly when the heart is vertical Discordant types of standard leads occur when the heart is normal or horizontal concordant when the heart is vertical These terms no longer serve any purpose since they signify changes that are confined to the standard leads and are due merely to differing positions of the heart Occasionally standard leads may suggest a right branch block, when the chest leads are characteristic of a left-sided lesion (Fig 10)

Out of 17 cases of left branch block, the heart was horizontal in 14 (Fig 9A) and was vertical in 3 (Fig 9B)

In *right branch block* a broad notched R occurs in V 1, and often in V 2 as well (Fig 11A) Occasionally the R is preceded by a small Q, more often there is a diminutive primary R with a succeeding S which is followed by a large secondary R (Fig 11B). A deep Q in V 1 and V 2 in right branch block is due usually to the involvement of the septum in an antero-septal infarct, and will be described later In leads to the left of the præcordia a slender R wave is followed by a broad S (Fig 11B) The R wave is not small or absent as in leads over the right side in left branch block because the impulse takes longer to pass through the thicker left ventricular wall to reach the epicardium

Some curves do not conform either to a right- or left-sided lesion In these cases the disease is probably bilateral (Fig 12)

Right branch block was present in 14 patients Of these the heart was in a normal or horizontal position in 6 and in a vertical position in 8 according

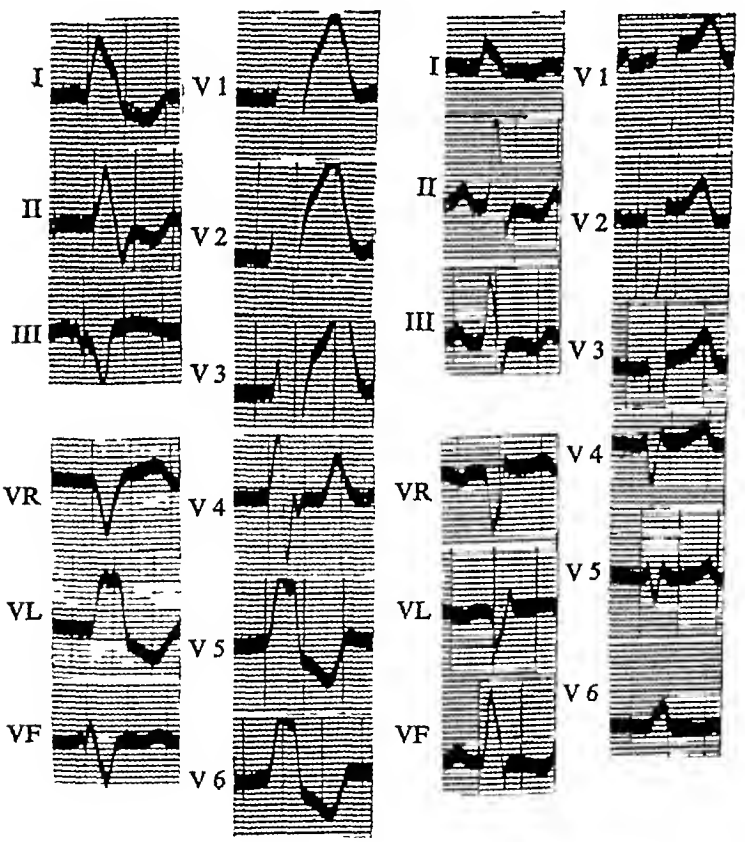

A FIG 9 B

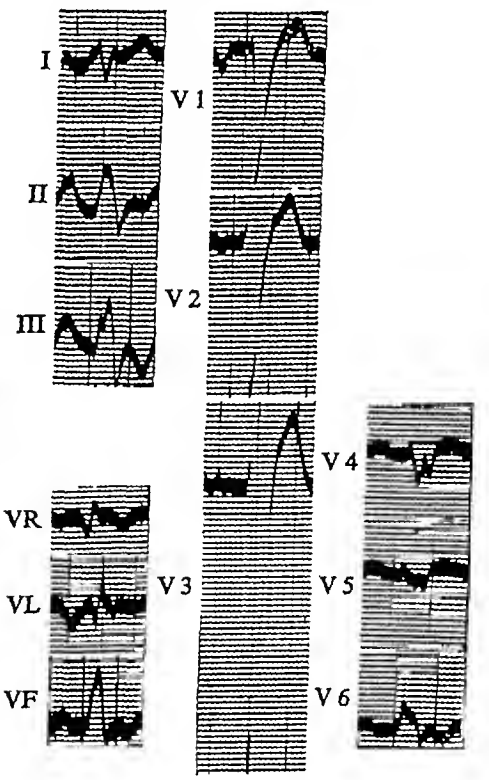

FIG 10

FIG 9 —Left bundle branch block (A) Discordant. QRS 0 18 second Small R with deep S in V 1, V 2, and V 3 Large notched R in V 5 and V 6 Transitional point see The heart is horizontal (B) Concordant QRS 0 12 second V 1, V 2, V 3 diminutive R p S At V 6 notched R S absent The heart is vertical

FIG 10 —Left bundle branch block QRS 0 16 second Standard lead nch block V 3 have small R waves with very deep S waves V 4–V 5 are transit but notch S diminutive The heart is vertical

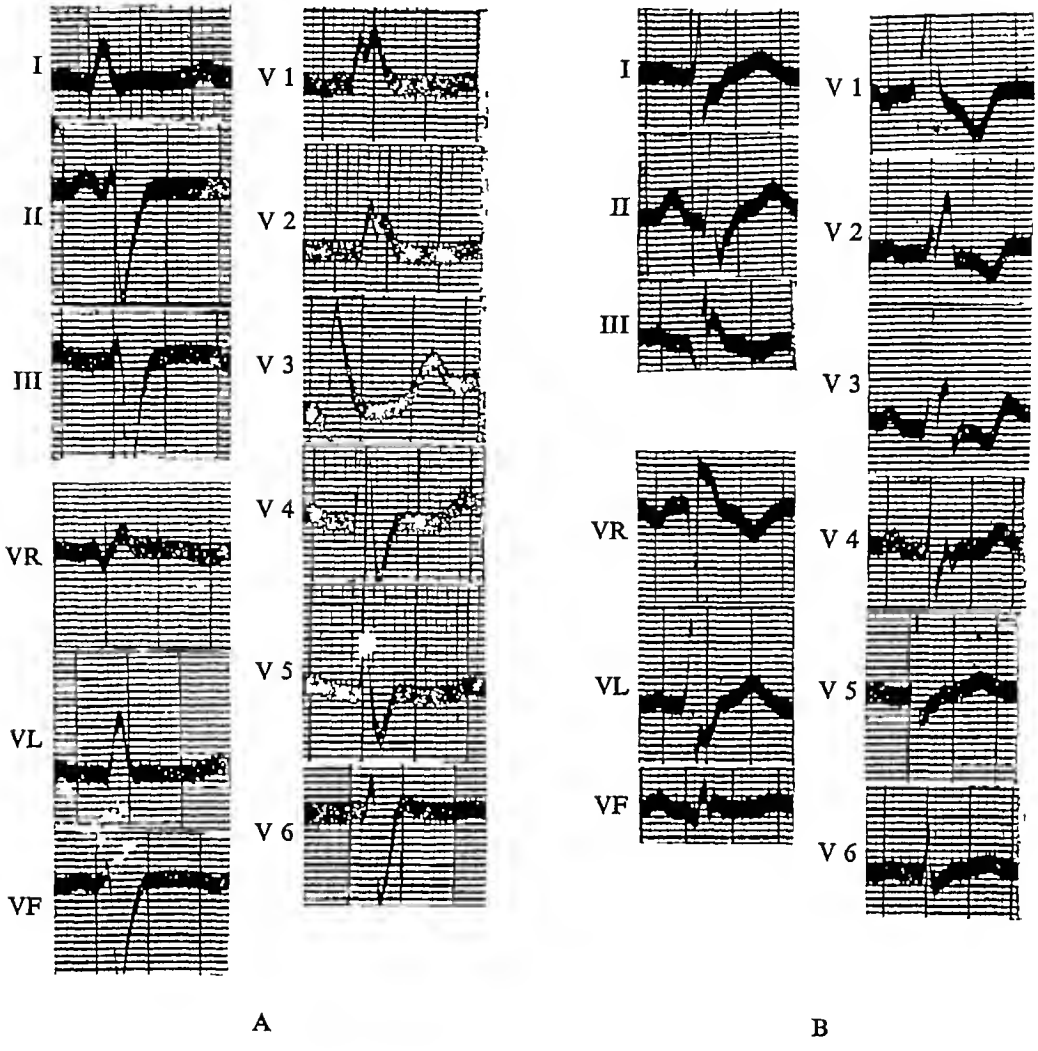

FIG 11 —Right bundle branch block (A) QRS 0 15 second Complete heart block V 1 and V 2 have a large notched R without an S V 5 and V 6 a slender R followed by a broad S The heart is vertical according to Wilson but horizontal according to Goldberger (B) QRS 0 14 second V 1 has small R with S followed by large secondary R V 2 has notching of upstroke of R V 5 and V 6 have tall but slender R followed by broad S The heart is semi-horizontal

to the Wilson *et al* (1944) explanation According to the Goldberger (1944) explanation it was normal or horizontal in all Seven of the cases were of the antero-septal infarction type

Incomplete Bundle Branch Block Incomplete right branch block may be diagnosed when embryonic R waves appear in V 1 in conjunction with increased duration of the QRS (Wilson *et al* 1944) A diminutive R is followed by a small S, and a small secondary R (Fig 13)

Incomplete left branch block is impossible to distinguish from left ventricular hypertrophy with prolongation of the QRS

CARDIAC INFARCTION

Since præcordial leads face the part of the advancing wave that is activating the anterior surface of the left ventricle, they show characteristic changes only in anterior infarcts In posterior infarction they face the tail of the wave and may have some depression of the S–T interval Otherwise they are normal, although signs of left ventricular hypertrophy may be seen in cases of hypertension

In anterior infarcts involving the whole thickness of the ventricular wall, deep QS waves are seen in the præcordial leads When the muscle is dead or

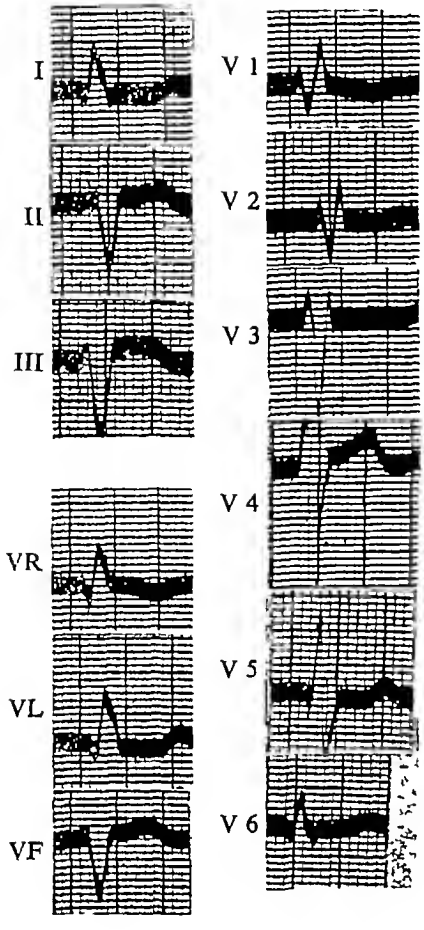

FIG 12

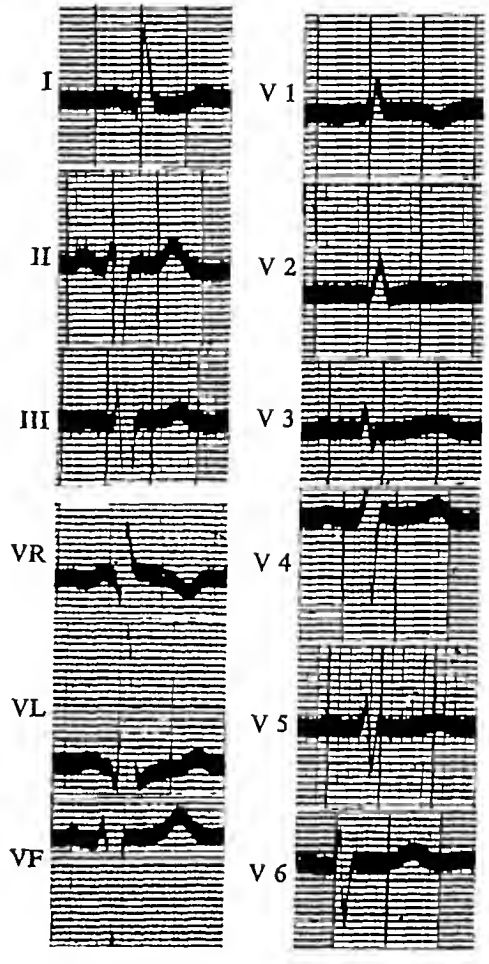

FIG 13

FIG 12 —Bundle branch block, predominantly right sided. QRS 0 14 second. V 1 has small R followed by broad S with larger secondary R. V 5, V 6 the R and S are approximately equal in duration

FIG 13 —Incomplete right branch block QRS 0 10 second. V 1 has a diminutive R and S followed by a small secondary R V 5 and V 6 slender R followed by broader S From a patient with hypertension and left ventricular enlargement The heart is horizontal

irresponsive there is nothing to prevent the initial negativity of the ventricular cavity passing straight through to the chest electrode As Wilson *et al* (1944) points out, it is as if a window had been cut in the ventricular wall Elevation of the RS–T junction and sharply pointed negative T waves are also present In antero-septal infarction the præcordial leads chiefly affected are those to the right—V 1, V 2 and V 3 In this type lead I is often normal If the infarct involves the septum, the bundle branches may be cut The combination of the changes due to anterior infarction and to right branch block gives a characteristic picture If the left branch is cut, signs of infarction seldom appear This is partly because the large diphasic complexes of left branch block engulf the RS–T deviation and negative T waves, and partly because in left branch block the left ventricular cavity does not become negative until the impulse crosses the septum Only if the whole thickness of the septum is involved in the infarct, will the negative potentials of the right ventricular cavity be transmitted through the dead muscle to the left, and allow Q waves to appear

If the infarct is situated towards the lateral wall—the antero-lateral infarct—leads V 4, V 5, and V 6 will show the maximal changes In small subendocardial infarcts not involving the whole thickness of the wall, Q waves may be absent Bowed

inversion of T may be the only evidence found This must be distinguished from inversion due to hypertrophy or digitalis The height of the R wave in the præcordial leads may help In health the R increases as the electrode is moved from right to left, and this tendency is more pronounced in left ventricular hypertrophy A diminution in the height of the R as the electrode is moved to the left is valuable corroborative evidence of infarction Or in some cases of left ventricular hypertrophy, the R wave may remain diminutive in V 5 and V 6 (Fig 14) Occasionally the chest leads may be normal, and yet leads I and VL may be typical of infarction In cases of this kind Wilson (1946) has found that the præcordial lead changes were present at a higher level of the chest, and he places the electrode at the usual positions but along the third interspace

Extensive Anterior Infarction In extensive anterior infarction QS waves with elevation of the RS–T junction and deep inversion of T appear in all the chest leads (Fig 15) In 7 cases of this type 2 died and 2 developed a cardiac aneurysm In all T was inverted in lead VL and in all but 1 in lead I, when it was flat In 3 cases T was negative in lead II as well as in lead I

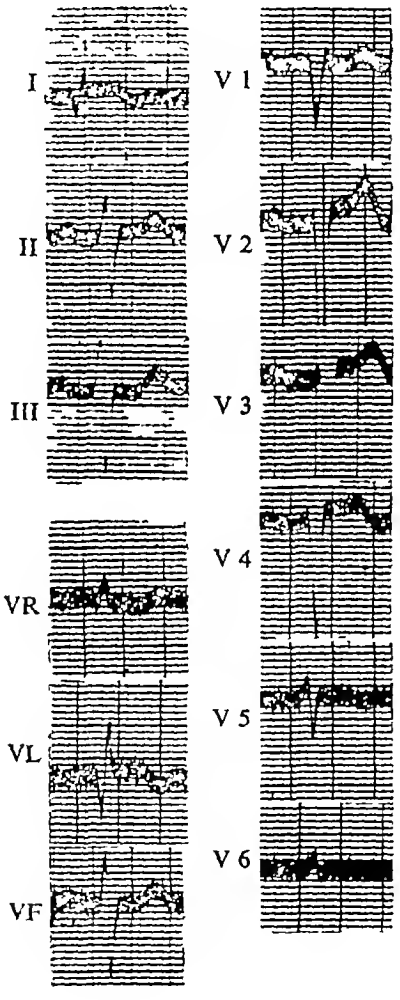

FIG 14

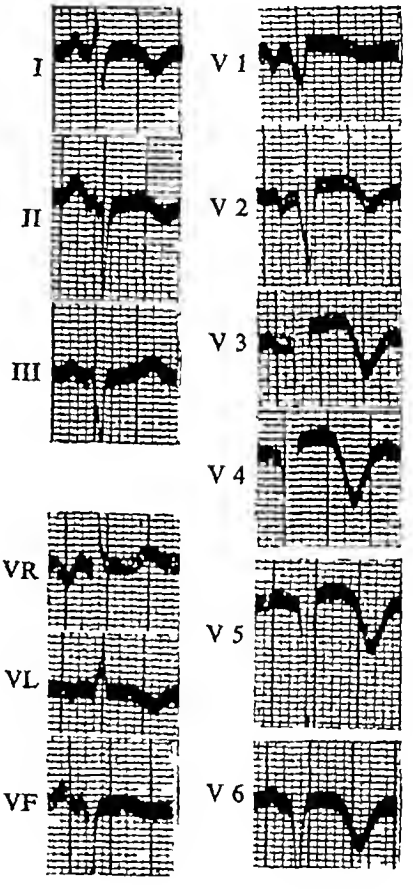

FIG 15

FIG 14 —Anterior infarction Q waves, elevation of the RS–T junction and bowed inversion of T in leads I and VL Chest leads show only left ventricular hypertrophy, but the R wave is unusually small in V 5 and V 6 The heart is horizontal

FIG 15 —Extensive anterior infarction QS waves are seen from V 1–V 6, with bowed inversion of T

Antero-septal Infarct The changes affect especially leads to the right, such as V 1, V 2 and V 3 T is upright in V 6, and usually in V 5 (Fig 16) There were 10 cases of this type In 8 there was bowed inversion of T in V 1, V 2, V 3, and V 4 in the others V 3–V 5 were affected In 7 of these cases T was also just inverted in VL, but in two only was it inverted in lead I though in two more it was flat

Antero-septal Infarct with Right Bundle Branch Block When an antero-septal infarct involves the septum, the right branch may be cut A deep Q is then seen in V 1, V 2, and V 3 (Fig 17A) This is followed by a late R, from the descending limb of which arises the bowed T wave, with considerable elevation of the RS–T junction The QRS is widened In leads to the left a slender R wave is seen and the T waves may be normal (Fig 17B) Standard leads may show little more than widening of the QRS (Fig 17A), though the T wave may be bowed in lead I

There were 6 cases with this combination In 5 there was complete right branch block, the duration of the QRS varying from 0 12 to 0 14 second Three of these patients died, in another the block was temporary only, disappearing in a week The right branch block was incomplete in 1 case, the QRS being 0 11 second (Fig 16)

Antero- and Postero-lateral Infarct Here the changes are seen in leads to the left of the præcordia

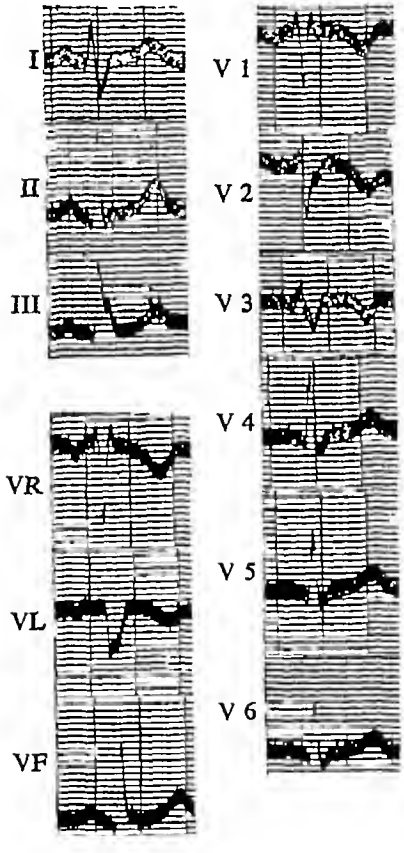

FIG 16

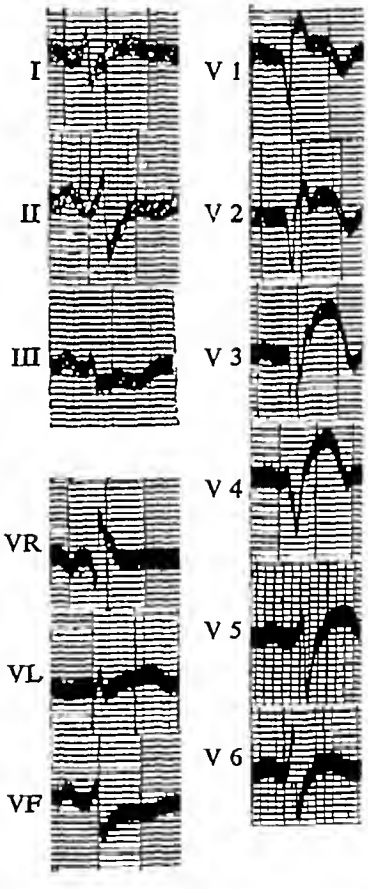

A

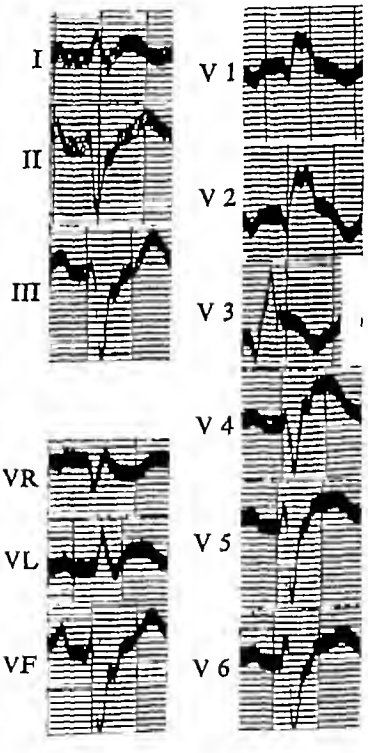

FIG 17 B

FIG 16 —Antero-septal infarction with incomplete right branch block Bowed inversion of T in V 1, V 2, and V 3 The T wave in V 4 and lead I is normal QRS 0 11 second Diminutive primary and secondary R waves in V 1 The patient gave a history of recent short attacks of angina at rest

FIG 17 —Antero-septal infarction with right bundle branch block (A) Deep Q waves present in V 1, V 2, and V 3 with elevation of the RS–T junction and bowed inversion of T from V 1–V 5 QRS 0 12 second Delayed intrinsic deflection in V 1, with slender R and broad S in V 6 (B) Q waves present with inversion of T in V 1, V 2, and V 3 QRS 0 14 second V 1 and V 2 have broad R waves with a delayed intrinsic deflection The R wave is small in V 5 and V 6 At autopsy the infarct was anterior and apical, and involved the upper part of the septum

(V 5 and V 6) and also in lead I and in VL There were 12 patients in this group of whom 6 had inversion of T in V 4, V 5, and V 6, and 6 in V 5 and V 6 only In 11 of these 12 patients T was inverted in lead I and in VL in the twelfth it was flat in both In 6 of the 12 T was also inverted in lead II and in 5 it was inverted in VF, being flat in a sixth

Posterior Infarct In posterior infarction the counterpart of the præcordial leads is the œsophageal lead since this lead faces the wave as it advances through the infarcted area But lead VF also reflects the changes over the diaphragmatic or posterior surface of the left ventricle Lead III is VF–VL, and VL faces the tail of the wave in posterior infarction To the depth of Q in VF will be added in lead III the reversed R of VL, to the upward deviation of the RS–T junction, the reversed depression of the RS–T junction in VL, to the negative T of VF, the reversed positive T of VL Lead III, therefore, always shows more pronounced changes than VF but in a sense these are spurious, being due to the subtraction of opposite values in VL (Fig 18A)

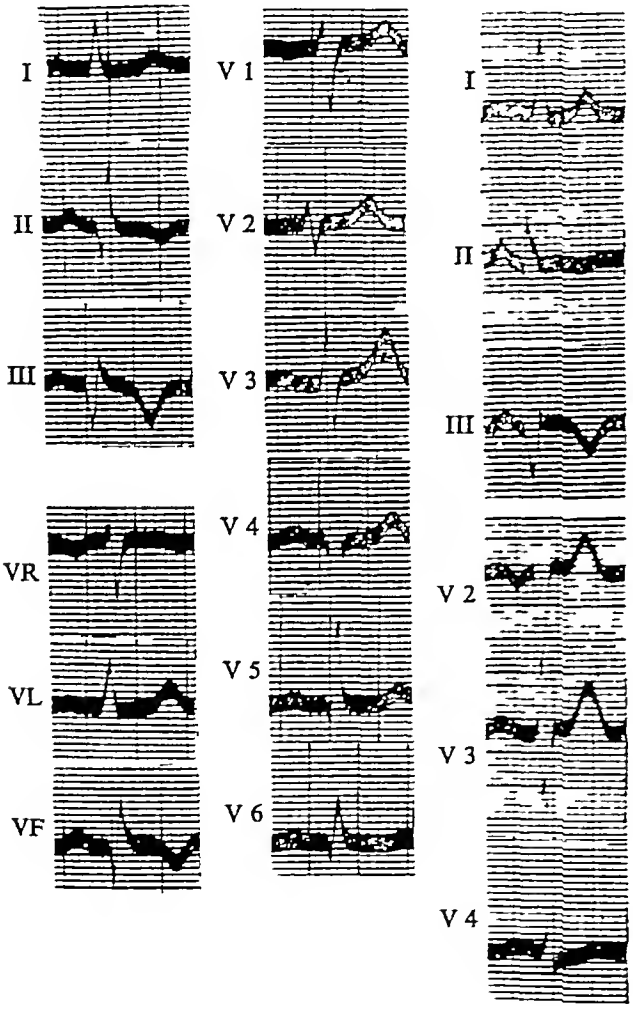

A FIG 18 B

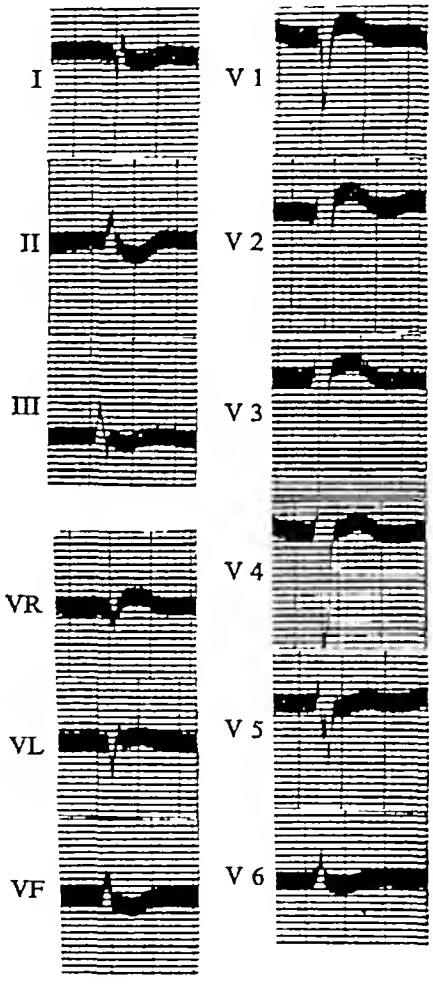

FIG 19

FIG 18 —Posterior infarction (A) Q waves and negative T waves in leads II, III, and VF Chest leads are normal (B) Chest leads show left ventricular hypertrophy, with deep QS in V 2

FIG 19 —Left ventricular hypertrophy with right axis deviation and a vertical heart. Concave depression of S–T interval due to digitalis seen in leads I, II, III, VF, and V 6 Convex elevation of S–T interval seen in leads VR, VL, V 1, V 2, V 3, and V 4 From a patient with mitral stenosis, aortic incompetence, hypertension, auricular fibrillation, and congestive failure

Præcordial leads may show some depression of the RS–T junction Sometimes the infarct may encroach upon the lateral wall of the left ventricle, and inversion of T may be present in V 6 In other cases inversion of T in the præcordial leads may be due to left ventricular hypertrophy, or to a previous anterior infarct

There were only 8 patients in this group All had Q waves and deep inversion of T in VF as well as in lead III, and to a less degree in lead II In one case T was inverted in V 6 One patient with considerable hypertension and another with aortic incompetence had evidence of left ventricular hypertrophy in the chest leads (Fig 18B) Inversion of T in V 4, V 5, and V 6 in one case was probably due to a previous anterior infarct

Congenital Heart Disease

In a small miscellaneous group of congenital heart lesions comprising cases of dextrocardia (4), pulmonary stenosis (1), and aortic stenosis (1), the curves were either bizarre or within normal limits

Effect of Digitalis

Digitalis causes the same depression of the RS–T junction, and negative T waves, in leads to the left of the præcordia such as V 5 and V 6, as it does in the standard leads The inversion due to digitalis may be difficult to distinguish from that of left ventricular hypertrophy and both may be present in the same record The negative T due to hypertrophy is usually convex, while the T wave of digitalis saturation is concave A considerable digitalis effect may involve all the præcordial leads When this occurs in advanced left ventricular hypertrophy with deep QS waves from V 1–V 4, convex elevation of the S–T interval takes the place of depression in these leads (Fig 19) This is due to the fact that leads to the right of the præcordia have the same characteristics as lead VR Since VR is in effect an intracardiac lead, the deflections are altered by digitalis, as also by anterior infarction (Fig 17B), in an opposite direction to those of lead I, VL, and the leads to the left of the præcordia In right ventricular hypertrophy, inversion of T can occur in all the præcordial leads in the absence of digitalis, and a digitalis effect can seldom be distinguished

Discussion

Multiple præcordial leads have given an accurate picture of left ventricular hypertrophy in 90 per cent of the cases in whom it was judged to be present on other grounds The most satisfactory criterion has been a diminution in the height of the R wave and an increase in the depth of the S wave in leads to the right of the præcordia Left axis deviation was present in only half those who showed this change In some of the cases with a normal electrical axis, and in all those with right axis deviation, unipolar limb leads showed that the heart was vertical In autopsies performed on such cases the right ventricle has always been found to be hypertrophied as well as the left The combination of signs of left ventricular hypertrophy in the chest leads and a vertical heart would seem to indicate hypertrophy of both ventricles

In right ventricular hypertrophy chest leads are not so successful since lesser grades of hypertrophy do not alter the curves The heart is always in a vertical or semi-vertical position when the characteristic changes are present in lead V 1

In bundle branch block it is nearly always possible to determine the side of the lesion The form of the standard leads varies greatly with the position of the heart and curves are concordant when the position is vertical Occasionally the standard leads may suggest a right branch block, when in fact the lesion is on the left side The reverse has not been seen

Although in general the maximal changes in infarction are usually to be found in the region of the apex, localization is more exact when multiple leads are taken A clearer picture is given of the extent of infarction Antero-septal and antero-lateral types can be distinguished The combination of anterior infarction and right bundle branch block, due to involvement of the septum, is clearly seen

The information given by the apical lead IV is inadequate in many respects Ventricular hypertrophy is not shown by it at all Indeed, it often lies in the transitional zone which is under the influence of both ventricles The lead does not assist in determining the side of the lesion in bundle branch block In antero-septal infarction the changes may be limited to leads to the right of the præcordia and the apical lead may be normal

When several points on the chest wall are to be explored, it is important that all extraneous influence should be eliminated as far as possible Since CR and CF leads are bipolar, the extremity used has some effect upon the curve Although in 90 per cent of cases these leads were found to be sufficiently accurate as regards the T waves, distortion was appreciable in the remaining 10 per cent Inverted T waves may be recorded in CF leads, if the heart is vertical, owing to negative distortion from the left leg Negative T waves may be made positive in CR leads by distortion from the right arm The distortion is not, however, confined to the T waves R waves will be more positive in CR leads and S waves will be more negative in CF leads, with the result that the balance of a series may be altered

and left ventricular hypertrophy may be missed or diagnosed wrongly The unipolar method of Wilson appears to be accurate within narrow limits The leads are simple and easy to apply If they become, as we believe they will become, the standard method of taking chest leads, instrument makers will have no difficulty in introducing a switch that will obviate the need for any additional connections

Unipolar limb leads enable the position of the heart to be ascertained Axis deviation is a compound of positional changes and hypertrophy, whereas the unipolar limb leads vary, as regards the R and S waves, with position only When the position is normal, lead VL reflects the potentials of the anterior surface of the left ventricle, and lead VF of the posterior surface, more accurately than do leads I and III In lead I a state of negativity at the left arm may be obscured by the subtraction of a greater state of negativity at the right arm The T wave is, therefore, inverted in lead VL in anterior infarction more often than in lead I In lead III the reverse occurs VL, facing the tail of the wave, will have positive deflections and this, when subtracted from the negative deflections obtaining at the left leg, will cause lead III to have more pronounced changes than VF

The difficulty with the unipolar method is the time required to take a twelve lead electrocardiogram It is hardly practicable for general use We have found that three chest leads give a reasonably accurate picture if they are varied according to circumstances Thus, V 2, V 3, and V 4 will register the changes of infarction if the heart is not enlarged If enlargement is present, it is better to bracket the apex thus V 4 and V 5 may be used or, if enlargement is gross, V 5 and V 6 When right-sided hypertrophy or right branch block is suspected, V 1 is more appropriate than V 2 In left-sided hypertrophy the S wave is usually deeper in V 2 than in V 1 Further experience will probably suggest better combinations of leads It has been suggested (Goldberger, 1942) that unipolar limb leads may come to supplant the standard leads Although this is possible, it seems certain that it must be a long time before the knowledge which has been accumulated regarding the standard leads can be safely discarded

Conclusions

A series of 300 twelve lead electrocardiograms taken with the unipolar method devised by Wilson have been analysed

Left ventricular hypertrophy has been diagnosed from the præcordial leads in 90 per cent of those in whom it was judged to be present on other grounds Left axis deviation was present in half of these cases

Right ventricular hypertrophy causes characteristic changes in leads to the right of the præcordia, but a considerable amount of hypertrophy is needed to produce them

In bundle branch block it is almost always possible to determine the side of the lesion Left branch block has sometimes been shown to be present by the præcordial leads, although the standard leads suggested a right-sided lesion

Anterior infarction can be divided into antero-septal and antero-lateral types The combination of anterior infarction and a right branch block, due to involvement of the septum, is clearly shown

The unipolar method avoids the distortion that occurs in a proportion of cases when bipolar leads such as CR and CF are used Unipolar leads are preferable when multiple præcordial leads are employed

We wish to thank Mrs Glynton, formerly cardiographer to the hospital, for help in the preparation of this paper

REFERENCES

Einthoven, W, Fahr, G, and de Waart, A (1913) *Arch ges Physiol*, **150**, 308
First, S R, Stickle, A W, and Bayley, R. H. (1947) *Amer Heart J*, 33, 1
Goldberger, E, (1942) *Ibid*, **24**, 378
—— (1944) *Ibid*, **28**, 621
Hoyos, Tomayo (1947) *Ibid*, 33, 698
Lapin, A W (1947) *Ibid*, 33, 747
Myers, G B, Klein, H A, and Stofer, B E (1948) *Ibid*, **35**, 1
Standardization of Precordial Leads (1938) *Ibid*, **15**, 235
Wallace, L, and Grossman, N (1946) *Brit Heart J*, **8**, 83
Wilson, F N, Johnston, F D, MacLeod, A C, and Barker, P S (1934) *Amer Heart J*, 9, 447
——, ——, Rosenbaum, F F, Erlanger, H, Kossman, C E, Hecht, H, Cotrim, N, de Oliveira, R M, Scarsi, R., and Barker, P S (1944) *Ibid*, **27**, 19
——, ——, ——, and Barker, P S (1946) *Ibid*, **32**, 277
Wood, F C, and Wolferth, C C (1932) *Amer J med Sci*, **183**, 30
——, Bellet, S, McMillan, T M, and Wolferth, C C (1933) *Arch intern Med*, **52**, 752

TWO CASES OF TEMPORAL ARTERITIS ONE WITH ANGINA OF EFFORT

BY

LESLIE COLE

From Addenbrooke's Hospital, Cambridge

Received December 14, 1947

Temporal arteritis was first described as a separate syndrome by Horton, Magath, and Brown in 1932 The clinical features of headache associated with inflamed and tender temporal arteries, the histological appearance of excised portions of these arteries, and the apparently self-limited course of the disease led them to suggest that this was a new clinical entity Since then about forty cases have been recorded and in an excellent résumé of these, which included seven of their own, Cooke, Cloake, Govan, and Colbeck (1946) have produced clinical and pathological evidence to support their view that temporal arteritis is a generalized vascular disease that is distinct clinically and pathologically from thrombo-angiitis obliterans and periarteritis nodosa They point out that the characteristic clinical features are anorexia, loss of weight, joint and muscle pains, pyrexia, painful arterial thrombosis, and severe headaches occurring in elderly patients, and that at least half so far reported have had visual disturbances leading in many instances to complete loss of sight In two cases a characteristic histological picture was noted in all the main arteries of the body including the aorta and coronaries

Since 1931 I have had three patients with the disease, under observation Details of the first were published previously in a paper by Jennings (1938) Of the other two described here, one suffered from severe angina of effort in addition to characteristic signs and symptoms, and died in a typical attack of coronary thrombosis In other respects all three were remarkably similar

Case Notes

Case 1 —A man, aged 68, who until the age of 65 had worked as a farmer, was sent to me on December 4, 1945, for severe temporal headache

In 1942 he began to suffer from pain in the middle of the chest on exertion which passed off when he rested This gradually grew more severe so that he was forced to give up work, and by October 1945 he could not walk more than 200 yards without resting The pain was gripping in character and when severe tended to radiate all over the chest and up into the neck It was worse in cold weather but did not come on apart from effort At the end of October he developed a pain in the left temple This was stabbing in character and in a few days became extremely severe At the same time he noticed that the "veins" in his temple got quite thick and his head felt "wooden" The pain came on in bouts which would sometimes last all day or night, and was at times "almost unbearable" At the end of a week the same trouble came on in the right temple with similar severe pain and the "veins" there became swollen The condition in both temples continued with varying severity until I saw him on December 4, when the frequency and duration of the attacks had somewhat lessened

In the past he had had no serious illnesses but had suffered from "rheumatism" in the shoulders, back, and thighs, for some years which had become worse He had lived a strenuous life as a farmer in the Fens and smoked and drank moderately His father died suddenly at the age of 56 and his mother died in her sleep at 70 He thought that his grandparents had lived to a good age and there was nothing else significant in the family history

On examination, the temporal arteries on both sides appeared swollen, tender and tortuous, and there appeared to be a good deal of periarterial swelling There was some redness of the skin in places over the right temporal artery The occipital arteries were not affected Pulsation in the arteries was very slight or absent The radial and brachial

arteries showed very slight thickening and tortuosity The optic discs did not show any abnormality A localized systolic murmur was audible at the apex, in all positions, but the heart sounds were otherwise normal Cardioscopy did not show any enlargement The cardiogram was normal and the Wassermann reaction on the blood negative The urine was normal The blood count did not show any change except a leucocytosis of 10,500 with 76 per cent polymorphs The movements of the back and joints were fairly free for a man of his age and type, and the other systems appeared normal

Progress—During the next fortnight the attacks of pain in the head gradually became less severe and frequent, the swelling of the temporal arteries almost subsided and the tenderness and redness disappeared but pulsation was still difficult to detect By May, his headache had completely gone but the pain in his chest was more severe and brought on even by shaving His general condition had deteriorated and he had lost 16 pounds in weight in four months Some tortuosity and periarterial thickening of the temporal arteries remained but the tenderness had gone The cardiogram was unchanged During the summer of 1946 his general condition improved considerably, he gained weight and the pain in his chest grew less severe and he was able to walk about a little He died in September a few hours after what appeared to be a typical attack of coronary thrombosis

Case 2—A man, aged 64, was admitted to Addenbrooke's Hospital on January 18, 1938, for pain in the head and fever In October 1937 he developed pains in the back of the neck, shoulders, left elbow and legs, which he attributed to working in a damp place These pains persisted intermittently and especially affected his left hand so that he found he had difficulty in holding his tools A few weeks after the onset, pains in his forehead came on, gnawing and aching in character, lasting for 4–5 hours at a time, and made worse by movement He also found that he could not see clearly to read and that a bright light would bring on a throbbing pain behind the eyes These symptoms persisted until he was admitted

In the past he had pleurisy and pneumonia about 1920 and an attack of bronchitis in 1935 He had been subject to winter cough and attacks of bronchitis almost all his life Born and bred in Cambridge, he had worked as a joiner, was teetotal and smoked about four ounces of tobacco a week His father and mother both died of "old age" at the ages of 65 and 70 respectively Two sisters and one brother were alive and well and there was nothing significant in the family history

He was rather thin (weight 8 st 3 lb) and looked his age His temperature was 99° F and his pulse rate 100 He complained of severe gnawing pain in both temporal regions and to a lesser extent in the shoulders, left arm, back, and legs

The temporal arteries on both sides appeared swollen, tender, and tortuous, with small nodules along their course Palpation gave a sensation of periarterial thickening and in places there was actual reddening of the skin over the line of the artery The occipital arteries on both sides were similarly affected He said that the swelling of his arteries had developed since his illness began The rest of the cardiovascular system did not show any gross abnormality There was slight tortuosity of the radial and brachial and slight narrowing of the retinal arteries The blood pressure was 130/90 Radiologically the heart was not enlarged No evidence of disease was found in the other systems Movements of the spine were free The urine was normal X-ray of the cervical region showed some osteoarthritis of the spine X-ray of the skull did not show any abnormality The blood urea was normal, the Wassermann reaction negative and the blood count normal but for a leucocytosis of 13,800

Progress—After admission he ran in intermittent temperature of 100–101 occasionally rising to 102 for four weeks which then gradually settled At the same time the pains in the head, the eye symptoms, and the redness of the skin and swelling around the arteries gradually subsided and his other pains also cleared up On discharge his general condition also was very much better In February 1939 he was seen again and all his symptoms and signs had disappeared except for slight tachycardia He remained in fair health until the following December when he developed a severe attack of bronchitis from which he died in January 1940

Case 3—An unmarried woman, aged 72, was under my care in Addenbrooke's Hospital in 1931 and was reported by Jennings (1938) She showed identical asymmetrical signs and symptoms in the temporal arteries, which lasted for about four months and then cleared up While she was in hospital for five days her temperature varied between 99–100 She had a moderate degree of arteriosclerosis but no other evidence of disease After she had recovered, she was able to live a quiet life at home appropriate to her age for two years until she collapsed suddenly one afternoon and died in a few hours

No autopsies could be obtained

Comment

These three patients all presented a strikingly

similar clinical picture which agrees in all essential points with other descriptions of the disease The age of onset was between 65 and 72, and the symptoms and signs produced by involvement of the temporal arteries were almost identical and ran a similar course lasting from four to six months All three showed evidence of arteriosclerosis in the radial and brachial arteries and two died suddenly from cardiovascular accidents In addition to the severe symptoms arising from the temporal arteries in all three and from the occipital arteries in one, the following symptoms were also noted Pain in the back and limbs in 2, fever in 2, weakness of the arm in 1, blurring of vision in 1 and marked loss of weight in 1 The association with angina of effort may have been a coincidence but Cooke found changes in the aorta and coronary arteries similar to those in the temporals

In the majority of cases the key to the diagnosis has been severe headache leading to the discovery of involvement of the temporal arteries If the characteristic picture is known, the diagnosis can be made on clinical grounds alone in the more obvious examples In those that are more obscure it is important to remember the less obtrusive symptoms and signs so that they will be recognized even when the arteries of the scalp are not signally involved

More cases should be published in order that the condition may be widely recognized and more may be learned about its protean manifestations Robertson (1947) has recently described four more which he has observed in a single year The fact that so many have been described since it was first noted and that some observers in different countries have each been able to collect several, suggests that it may be a good deal less rare than is supposed More, too, has to be learned about prognosis which is difficult to assess in patients of this age At present the general verdict is that it is good as far as the local condition in the temporal arteries is concerned, for this tends to clear up in about a year whatever treatment is given It is not yet so clear how far extension of the process to other more vital arteries may be responsible for deaths such as occurred in these three patients and a follow-up of more cases is needed, supported by full post-mortem examination

REFERENCES

Cooke, W T, Cloake, P C P, Govan, A D T, and Colbeck, J C (1946) *Quart J Med*, **15**, 47
Horton, B T, Magath, T B, and Brown, G E (1932) *Proc Mayo Clin*, **7**, 700
Jennings, G H (1938) *Lancet*, **1**, 424
Robertson, K (1947) *Brit med J*, **2**, 168

HYPERTENSION DUE TO SYPHILITIC OCCLUSION OF THE MAIN RENAL ARTERIES

BY

R KEMBALL PRICE AND R SKELTON

From the Cardiac Department of the Royal Sussex County Hospital

Received November 20 1947

This is the record of a case of hypertension starting in childhood and leading to death from heart failure at the age of 24 There is strong presumptive evidence that the hypertension was preceded by occlusion of the main renal arteries

Case Report

Irene H , single, aged 24 years, was admitted to hospital on January 1, 1947, with severe heart failure

Family History —Her father suffered from asthma and was killed at the age of 26 One brother was killed in the Second World War The mother and three sisters are alive and well

Past History —When aged 4, she had an operation for intussusception, a gland was removed and a diagnosis of mesenteric tuberculosis was made When 8, she had diphtheria with no complications

Present History —At the age of 13, when running in a race, she became unduly breathless and on examination was said to have an " enlarged heart " Soon after this she was diagnosed as having pulmonary tuberculosis on some shadowing in the lung fields, and was treated in a sanatorium for six months An X-ray taken at this time showed cardiac enlargement and pulmonary œdema (Fig 1) She remained afebrile throughout and the sputum was never positive for tubercle An X-ray four months later showed lungs much clearer", the heart was unchanged She remained under observation by the Tuberculosis Officer for the next four years On several occasions heart sounds were noted as loud and ringing but there was no record of the blood pressure Her doctor states that for the last six years he has treated her for recurrent attacks of left ventricular failure and recently for congestive failure as well Ten days before admission to hospital she developed a " cold," followed by increasing dyspnœa

Examination —Pale and orthopnœic, venous pulsation in the neck and visible pulsation in the brachial arteries No clubbing of the fingers Pulse 120, regular, very small volume Apex beat 16 cm from the mid-line, heaving First sound at the apex loud, aortic second sound very loud and an aortic diastolic murmur audible at the second right costal cartilage Triple rhythm present due to the addition of a fourth heart sound Blood pressure 210/100 mm Harsh breath sounds with diffuse rhonchi over the right lower lobe, and coarse crepitations at both bases Liver enlarged 5 cm below costal margin, moderate œdema of the ankles and over the sacrum Retinal arteries narrow and bright, no hæmorrhages or exudate The urine contained a trace of albumin and the deposit showed occasional epithelial cells only

A radiograph showed considerable enlargement of the left ventricle, diffuse dilatation of the aorta with some calcification in the aortic knuckle, and patchy pulmonary œdema (Fig 2)

An electrocardiogram showed left ventricular preponderance with R–T depression and T wave inversion in leads I and CR7, a diphasic T wave in lead II and R–T elevation in lead III, and a biphasic P wave in lead III

Renal function blood urea, 70 mg per 100 ml , urea clearance (1) 37 ml 3 3 per cent urea, standard clearance 68 per cent, (2) 12 ml 3 4 per cent urea, standard clearance 40 per cent

Blood count R B C , 3 99 million per c mm Hæmoglobin 82 per cent, colour index 1 0, W B C , 12,000 per c mm Wassermann reaction (±)

Progress —Under treatment by complete rest, oxygen, digitalis, and mercurial diuretics she showed some temporary improvement, and the œdema of the legs disappeared Twelve days after admission she died suddenly

Necropsy Report

The body of a thin, but not emaciated, young woman of medium height showing engorgement of

FIG 1 —Radiograph at age of 13 showing left ventricular enlargement and pulmonary œdema involving upper and mid zones (August 23, 1936)



FIG 2 —Radiograph at age of 24 showing left ventricular enlargement, aortic dilatation, and patchy pulmonary œdema (January 9, 1947)

the veins of the neck and cyanosis of lips and ears Slight œdema at the ankles, no ascites, no jaundice or clubbing of fingers Nothing in the facies to suggest congenital syphilis

The abdominal cavity contains about 100 ml of clear straw-coloured fluid Both pleural cavities contain about 200 ml of clear fluid, no adhesions The pericardial cavity contains about 20 ml of clear yellow fluid, and there are fine adhesions between the anterior aspect of the left ventricle and the parietal pericardium, of fairly recent origin

The mouth shows no noteworthy change, tonsils not enlarged, no abnormalities of the teeth The trachea and bronchi contain frothy œdema fluid, œsophagus appears normal

The heart (Fig 3) is much enlarged and weighs 890 grams There is great left ventricular hypertrophy, and moderate hypertrophy with considerable dilatation of the other chambers Thickness of right auricle, 2 mm , right ventricle, 8 mm , left auricle, 4 mm , left ventricle, 24 mm , circumference of orifice of pulmonary artery, 7 5 cm , of tricuspid valve, 12 cm , of mitral valve, 8 5 cm , of aorta at origin, 12 5 cm The right heart showed the greater dilatation Both auriculo-ventricular valve rings are dilated, valve cusps normal The pulmonary valve cusps appear normal The pulmonary artery shows a few small atheromatous patches The left auricle is dilated The left ventricle is greatly hypertrophied, there are a number of old fibrous scars in the myocardium, and an area of fibrous infarction lying anteriorly towards the apex The aortic valve cusps show slight rolling of the free margins of the cusps and some fibrous thickening, without separation of the commissures The coronary arteries are considerably dilated, tortuous, thickened, and show intimal calcification The first part of aorta is generally dilated beyond the sinuses of Valsalva, where the diameter is 12 5 cm Throughout its length, the aorta shows patchy intimal thickening, with calcification, and linear scarring associated with atherosclerosis, the whole intima being covered by plaques, some calcified and many ulcerated with small thrombi upon them In addition to these generalized lesions of the intima, there are two curious lesions that appear to have arisen as dissecting aneurysms The first of these is situated in the thoracic portion, 4 5 cm distal to the origin of the innominate artery, and consists of a crescentic fold in the wall,

concavity downwards, lined by intima There appears to have been a cleavage in the wall of the aorta occurring after the manner of a dissecting aneurysm, which has become arrested and subsequently lined by intima

The second lesion, situated 4 cm below the diaphragm in the abdominal aorta, is an aneurysmal swelling 4 5 cm in length and 3 cm in diameter, presenting anteriorly, and communicating with the aortic lumen by two orifices, separated from one another by a bridge of aortic tissue The appearance is that of a dissecting aneurysm which has re-entered the aorta just below its origin Just above the bifurcation, the aorta shows a gross fusiform aneurysmal dilatation The common iliac vessels are both much dilated to form fusiform aneurysms the walls of which are lined by adherent laminated blood clot

At the orifices of the renal arteries, the aorta is grossly distorted by scar tissue, so that the renal vessels appear to be lying in small funnel-shaped depressions (Fig 4) Both renal vessels are fibrous throughout the greater part of their length, and their lumina are reduced to a pinpoint or small slit lying to the side of the vessel, so that there must have been extreme reduction of renal blood flow during life The carotids, innominate, cœliac axis and its main branches, and superior mesenteric artery all show great intimal thickening and scarring with general dilatation of the lumina

The lungs show considerable œdema and chronic pulmonary congestion There is no evidence of tuberculosis The liver is slightly enlarged, dark red on section and shows acute venous congestion The gall bladder and bile ducts are normal The pancreas is healthy and the adrenals are normal

The left kidney is smaller and narrower than the right, weight 150 g, length 11 cm, width 5 5 cm, thickness 3 5 cm, cortex 4 mm, medulla 16 mm Right kidney, weight 180 g, length 10 5 cm, width 7 cm, thickness 4 cm, cortex 6 mm, medulla 16 mm In both kidneys the capsules strip readily, leaving a perfectly smooth surface There is no undue prominence of the intra-renal vessels The main renal arteries show occlusive lesions as already described

The renal pelves, ureters, and bladder appear normal The uterus and adnexæ are normal The stomach and intestines show no macroscopic lesions Cranial cavity not examined

FIG 3 —Necropsy specimen showing left ventricular hypertrophy, severe syphilitic aortitis, and iliac aneurysms

HISTOLOGY

Aorta —The adventitia shows a diffuse plasma cell and lymphocyte infiltration, with cellular cuffing of the vasa vasorum The media shows much fibrosis and interruption of the elastic fibres The intima is thickened, and calcified in places A similar appearance of syphilitic arteritis is seen in the carotid artery on section

Renal Arteries The right renal artery shows great intimal thickening at its origin without active changes in the media of adventitia and there is no atheroma at this point, the lumen is stenosed for a distance of 1 cm and then widens

The left renal artery at its origin shows great thickening of the intima which reduces the lumen to minute proportions The intimal tissue is loose and cellular and infiltrated with lymphocytes and a few plasma cells There is no active arteritis of the media or adventitia, and no evident atheroma in either of the sections

Kidneys —Right glomeruli appear normal, no arteriolar hyalinization and no post-hypertensive changes in the interlobular vessels Tubules show post-mortem changes only Left similar to the

FIG 4 —Necropsy specimen showing severe aortitis with healed dissection marked by arrow, involvement of orifices of renal arteries, and iliac aneurysms containing laminated thrombi

right, but there are a very few scattered fibrosed glomeruli surrounded by small groups of plasma cells and lymphocytes, no arteriolar lesions

Pancreas is autolysed and shows conspicuous post-hypertensive arteriolar lesions Lung shows chronic venous congestion, with "heart failure cells" in the alveoli, no vascular lesions Liver shows acute venous congestion, no arteriolar lesions Adrenals, normal, no arteriolar lesions

DISCUSSION

Several cases showing occlusive lesions of the renal arteries associated with essential hypertension have been reported, and hypertensive arteriolar changes occurred in all organs except the kidneys in which the arterioles are protected from the blast of high blood pressure by occlusion of the main renal arteries The occlusion was usually atheromatous, but occasionally due to other causes Blatt and Page (1939) recorded obstruction of the renal arteries by sarcomatous tissue, in a man aged 38 with hypertension Leiter (1938) described syphilitic occlusion of the renal artery in a woman aged 46, and thrombosis of the renal arteries, usually secondary to atheroma, has also been described (Wolffe and Donnelly, 1942) In our case, both renal arteries were almost occluded by intimal proliferation from extensive syphilitic arteritis, and though atheroma was also present, it was probably a secondary lesion

It is tempting to explain hypertension associated with atheroma of the renal arteries in terms of a reduced blood supply to the kidneys, but such a conclusion must be accepted with caution Atheroma of the renal arteries is by no means uncommon, occurring in about 10 per cent of necropsies in subjects without hypertension, and it is possible that hypertension merely aggravates pre-existing atherosclerotic lesions When renal arterial occlusion is syphilitic, there is more reason to regard it as the cause of the hypertension, and in our case this supposition is supported by the fact that the renal arterioles showed no hypertensive changes whereas the pancreatic arterioles showed them in high degree Hypertension evidently began at least 11 years before death, for cardiac enlargement

and pulmonary congestion were shown in radiographs taken at that time The aneurysmal dilatation of the common iliac vessels and the two aneurysmal lesions of the aorta may have been due to hypertension superimposed on arteries already weakened by syphilitic inflammation

SUMMARY

A case of syphilitic aortitis with aneurysmal lesions of the aorta and common iliac vessels, and occlusion of the renal arteries by syphilitic arteritis is described Hypertension was known to have been present for many years, and it is suggested that it was secondary to renal arterial occlusion

We wish to thank Sir John Parkinson for reading this report and for his helpful criticism

REFERENCES

Blatt, E , and Page, I H (1939) *Ann intern Med*, **12**, 1690

Leiter, L (1938) *J Amer med Ass*, **111**, 507

Wolffe, J B , and Donnelly, D J (1942) *Ibid*, **119**, 27

BALL THROMBUS OF THE HEART

BY

M E EVANS

From Joyce Green Hospital, Dartford, Kent

Received December 10, 1947

Although ball thrombus of the heart has always been of considerable interest, Abramson in 1924 was able to collect only 19 reported cases and added 1 of his own The condition was first reported in 1814 by William Wood of Edinburgh in a delicate girl of 15 for three years she had been subject to progressive dyspnœa on exertion, and began to suffer from fainting spells three or four times a day, and eventually died in a state of exhaustion Post-mortem, there was a round, firm mass lying completely free in the left auricle, the mitral valve was greatly thickened and the orifice too small to admit the tip of the little finger In the succeeding 110 years a further 19 cases were reported, of which 6 occurred in the British Isles In the 15 cases in which the sex was given, 11 were females and 4 males, an incidence corresponding to the sex distribution of mitral stenosis Most were in the fifth decade of life Eight of these 20 cases showed either transient or permanent disturbance of the peripheral vascular system The site of the thrombus was in the left auricle, except in the case described by French (1912) where it was in the right ventricle Since Abramson's review, a further 12 cases have been recorded, 11 associated with mitral stenosis and 1 with a normal mitral valve The thrombi have been found in the left auricle, except in the case reported by Wright, Flynn, and Druet (1944) of a thrombus in the right auricle Ten of these 12 patients had interference with the circulation in the lower limbs The details of these cases are shown in the table

During the same period 4 cases were described resembling the condition reported here, but not due to ball thrombi Kaplan and Hollingsworth (1935) recorded a case of pedunculated thrombus of the left auricle simulating mitral stenosis, post-mortem the thrombus occluded a normal mitral valve, there was no interference with the peripheral circulation Schiller (1935) reported two cases of subacute bacterial endocarditis in which the exuberant vegetations on the mitral valve attained a size sufficient to produce transient circulatory disturbances in the limbs Perry and Davie (1939) described a case of symmetrical peripheral gangrene in a man, aged 64, with cardiac failure and a blood pressure of 175/85 Post-mortem, no valvular disease of the heart could be found, there was a moderate degree of atheroma of the aorta, but no evidence of thrombosis, embolus, or atheroma of the iliac, femoral, or popliteal arteries They quote this case in support of Fishberg's (1938) theory that in severe congestive cardiac failure a selective vaso-constriction occurs (? reflexly) because of extreme diminution in the cardiac output, a small amount of blood being distributed to the limbs and a large amount to the brain and other important centres In support of his theory, Fishberg quotes a case in which, on inserting a cannula into the antecubital vein, the venous pressure was under 1 cm , whereas at the same time the jugular pressure was over 20 cm As the patient improved the pressures became equalized In his view, peripheral gangrene in general circulatory failure is an unfortunate side effect of a valuable compensating mechanism

The term *ball thrombus of the heart* is applied to a form of ante-mortem thrombus, and the criteria for calling a given ante-mortem clot a ball thrombus have been variously stated According to Hewitt (1916) " the term ball or oval thrombus of the heart should be restricted to those thrombi found on post-mortem examination, loose in the heart cavities, which are of a round or oval shape and whose surface is everywhere smooth and shows no sign of a former attachment " Abramson and most other observers prefer to substitute for the last part the criteria of Welch (1899), viz , (a) entire absence of attachment with consequent free mobility, (b) imprisonment in consequence of an excess of the diameter of the thrombus over that of the first narrowing in the circulatory passage ahead of it, (c) such consistency and shape that the thrombus must not of necessity lodge as an embolus in the

TABLE OF SOME DETAILS OF REPORTED CASES OF BALL THROMBUS

Sex, age, and author	Clinical course and symptoms	Thrombus localization, size, and weight	Peripheral vascular disturbance	Other disturbances of circulation and B P	Final anatomical diagnosis
F, 53, Potter	2½ years dyspnœa. Thyrotoxicosis A F	L A Spherical 48 g	Gangrene of both legs	Infarcts of spleen and kidneys 160/100	M S (buttonhole) Ball thrombus
F, 55, Covey, Crook, and Rogers	4 years dyspnœa, 6 months swelling of ankles A F	L A Spherical 16 g	Gangrene R. leg	Infarcts of kidneys 165/90	M S (buttonhole) Ball thrombus
F, 44, Schwartz, and Biloon, Case 1	Palpitation 10 years A.F	L A Pyramidal	Gangrene R leg	? 190/90	M S Ball thrombus
F, 42, Schwartz and Biloon, Case 2	Cardiac failure 2 years A.F one month	L A Spherical	Attacks of pallor in R leg—gangrene	Nil 190/110	M S Ball thrombus
M, 62, Schwartz and Biloon, Case 3	Cardiac failure 2 months A F	L A Cylindrical	Gangrene of both legs Attacks of cyanosis leading to gangrene of R hand	? 140/80	Ball thrombus No M S
F, 52, Elson	Præcordial pain 8 years A F 3 years	L A Oval 4×0 5 cm	Attacks of pallor and coldness of both lower limbs Weakness of R. radial pulse	Old infarcts in spleen and kidneys 230/80	Buttonhole M S Ball thrombus
F, 43, Aronstein and Neuman	Dizzy spells 5 years Dyspnœa and cyanosis of face 2 days	L A Spherical 3 5 cm in diameter	Nil	Infarcts in spleen B P ?	Ball thrombus M S
F, 48, Garvin, Case 1	Faints for several years After D and C developed A.F and gangrene of R foot and calf No pulse in L foot	L A Spherical 3 cm in diameter	Gangrene of both legs	Infarcts of spleen and kidneys B P ?	M S Tricuspid stenosis Ball thrombus Embolism
F, 86, Garvin, Case 2	Faints 2 years A F Blackening of R foot for 2 days	L A Spherical 2 2 cm diameter	Gangrene of R foot	Thrombosis of R femoral and popliteal arteries B P ?	Coronary sclerosis M S Ball thrombus
M, 46, Garvin, Case 3	Hemiplegia and cardiac failure Sudden death A F	L A Oval 2 cm in diameter	Nil	Infarcts in spleen, kidneys, lungs, and brain B P ?	M S Ball thrombus
F, 33, Spain	Cardiac asthma Transient vascular phenomena in limbs leading to gangrene Regular rhythm	L A. Spherical 3 cm in diameter	Gangrene of limbs	Infarcts of R lung and both kidneys	M S Ball thrombus
M, 47, Wright, Flynn, and Druet	Dyspnœa 24 years Failure for 6/12 Hemiplegia	R auricle Spherical 6 8 cm in diameter	Pulsation of neck veins, occasionally of saphenous veins	Infarcts of left kidney, spleen, and mesenteric artery Pontine hæmorrhage 100/90	M S Tricuspid regurgitation Ball thrombus in R auricle

ABBREVIATIONS —
A F =Auricular fibrillation L A =Left auricle M S =Mitral stenosis

passage The cases reported by Abramson and those described in the table all appear to fulfil the criteria laid down by Welch

In view of its rarity and the comparative paucity of cases recorded in England, the case described below was considered worth recording Although presenting most of the characteristics of the syndrome, it also showed certain unusual features

Case History

A woman, aged 50 years, was admitted to hospital on December 29, 1946, her chief complaints being blueness and coldness of the legs and an inability to move them She had chorea at the age of 13, and was in bed for about a year, but never had acute rheumatic fever Subsequently, she led an extremely active life, played outdoor games and, during the late war, worked hard in a canteen She was married, but had no children A fortnight before admission, after a long day out, she noticed for the first time that she was a little short of breath and had slight swelling of her ankles She stayed in bed and was digitalized by her doctor Her dyspnœa and œdema subsided and on Christmas Day she was allowed up for lunch In the afternoon she walked upstairs and was suddenly seized with a violent pain around her umbilicus She was sick once and later passed several tarry motions The abdominal pain gradually disappeared Shortly after vomiting she had severe pain in both legs, the right worse than the left, with the pain the legs became numb and cold At first they were white, but later they turned blue The blueness and numbness persisted but the pain gradually disappeared

On admission her lips and cheeks were slightly cyanosed and a little dyspnœa was present The cervical veins were distended to a height of two inches above the clavicle with the patient upright Clinically, there was no enlargement of the heart, which was fibrillating at a rate of 60 , an apical systolic murmur was heard, but no diastolic murmur The blood pressure in the right arm was 170/110, it could not be recorded in the left Examination of the lungs revealed no abnormality The central part of the abdomen was tender on palpation, but there was no rigidity Her hands were blue and cold, although the pulses were palpable and of fairly good volume The right leg was blue and cold to just above the knee, where a sharp line of demarcation was present, but above this level it was pink and warm The toes showed dry gangrene The femoral pulse was palpable, popliteal pulsation was absent and pressure over the origin of the profunda femoris artery was painful No voluntary movement was possible and the affected part of the leg was anæsthetic The left leg was blue and cold to just above the ankle and gangrene of the toes was commencing Again the femoral, but not the popliteal, pulse was palpable Slight voluntary movement of the foot and toes was possible and there was no anæsthesia Half-an-hour after admission the circulation in the hands had returned to normal—they were quite pink and warm—but there was no change in the legs The following day she again developed a transient cyanosis and numbness of the hands The upper margin of the cyanosis of the right leg had decreased to just below the knee The patient was seen at this stage by my colleague, Dr Goldstein, who suggested that she might be suffering from a ball thrombus of the left auricle The urinary output was very difficult to estimate because of incontinence, a catheter specimen showed a heavy trace of protein, occasional pus cells and red cells, occasional hyaline casts, and amorphous phosphates Unfortunately, an electrocardiograph could not be performed as the apparatus was being repaired On December 31 she was becoming very drowsy and passing practically no urine The blood urea was 300 mg per 100 ml The following day her condition continued to deteriorate and she died in the evening

Post-Mortem Examination

This was performed on January 2, by Dr A M Bodoano There was gangrene of the right foot which spread up the leg to just below the knee as a reddish-purple discoloration This discoloration was also present in the left foot and extended about three inches above the ankle

Thorax There was no free fluid in the pleural cavities or pericardium The heart was greatly enlarged, and weighed about 500 g As the left auricle was opened, a firm ovoid mass fell out , it was covered by velvety fibrin which, when washed off, left behind a perfectly smooth ovoid clot There was no sign of any point of attachment to the auricular wall and it appeared to be quite free in the auricle (Fig 1 and 2) It weighed 23 g after fixation in formol saline Section of the clot showed it to be of uniform structure and unlaminated The right auricle was dilated and its wall thinned The right ventricle was hypertrophied, its wall being 1 0 cm in thickness The wall of the left auricle was stretched and thinned and was everywhere smooth, showing no sign of any previous attachment of the thrombus The wall of the left ventricle showed a concentric hypertrophy, the average thickness of muscle being 1 8 cm The mitral orifice was stenosed, just admitting the tip of the index finger and had the " button-hole " type of deformity, the orifice was 2 5 cm in length and a mere slit in breadth The cusps were greatly thickened and partially calcified, the chordæ tendiniæ were adherent The tricuspid, pulmonary, and aortic valves, and the coronary arteries were normal The wall of the thoracic aorta was perfectly smooth The lungs were œdematous but showed no sign of infarction There were no thrombi in the pulmonary vessels

Abdomen The peritoneal cavity contained a



FIG 1 — Photograph of the heart showing mitral valve and the ball thrombus

FIG 2 —Ball thrombus *in situ*

FIG 3 —Dissection of abdominal aorta, renal arteries and kidneys and spleen, to show thrombi *in situ* and infarction of viscera.

little blood-stained fluid and there was a patchy discoloration of the surface of the intestine The stomach was normal There was an acute ulcer in the duodenum with attached blood clot, one inch from the pylorus The small intestine was filled with old blood The superior mesenteric artery was thrombosed and had infarcted the jejunum and proximal ileum The liver showed slight chronic passive venous congestion The spleen had numerous recent infarcts The pancreas was normal The right kidney showed a number of large infarcts, and a small clot was present at the mouth of the renal artery The left kidney was almost completely infarcted by a large ante-mortem clot extending from the mouth of the renal artery into the kidney substance (Fig 3)

The descending aorta, right iliac, femoral, and left profunda femoris arteries contained ante-mortem clot these adequately explained the gangrene of the legs The brachial arteries were tightly contracted and on longitudinal section showed a *sand-papery* appearance of the intima No thrombi were found in the arteries of the upper limb Histological examination of the subclavian artery showed intimal fibrosis and atheroma There was no sign of any infarction of the brain

The anatomical diagnosis was therefore chronic rheumatic endocarditis leading to mitral stenosis and auricular fibrillation, free ball thrombus of the left auricle, embolic phenomena in the spleen, and thrombosis of the renal, superior mesenteric, left profunda femoris, and right common iliac and femoral arteries, acute duodenal ulcer, and melæna

Discussion

The case described differs from most of those previously recorded in several aspects Firstly, in the short history, only three weeks, of any symptoms referable to the cardiovascular system The majority of cases had several years history of dyspnœa and palpitation Secondly, in the occurrence of an acute duodenal ulcer and melæna It is interesting to speculate how long a ball thrombus could be present in the auricle without producing symptoms This clot, although not laminated on section, must have been present for a period considerably longer than three weeks In only one of the later cases of Abramson's series is the occurrence of auricular fibrillation specifically mentioned In cases subsequently reported, however, auricular fibrillation was present in all but one Unfortunately, the date of onset of auricular fibrillation in this patient is not known, but it is likely to have been at the onset of her dyspnœa and slight œdema The onset of auricular fibrillation may therefore act as a precipitating factor for the development of symptoms from a ball thrombus

The criteria for the diagnosis during life of a ball thrombus of the heart are still the same as those laid down by Battistini (1908), who based the diagnosis on the following sequence of symptoms signs of mitral stenosis, disturbance of the general circulation, entire debility of the pulse, and the presence of gangrene of the lower extremities It is noteworthy that in the series analysed here gangrene of the extremities was present in 8 of the 13 patients with ball thrombi, one of whom had a clot in the right auricle

Summary

A case is described of ball thrombus of the left auricle associated with mitral stenosis, disturbance of the peripheral circulation leading to gangrene of the legs, and acute duodenal ulcer

The cases occurring since Abramson's paper in 1924 are reviewed

I am grateful to Dr M Mitman, Medical Superintendent of the River Hospitals, Dartford, for much help and criticism in the preparation of this article and for permission to publish the case

REFERENCES

Abramson, J L (1924) *Ann clin Med*, **3**, 327
Aronstein, C G, and Newman, L (1939) *Arch Path*, **27**, 907
Battistini (1908–9) *G Accad Med Torina*, **14–15**, 313
Covey, G W, Crook, R, and Rogers, F L (1928) *Amer J med Sci*, **175**, 60
Elson, J (1934) *Amer Heart J*, **15**, 120
Fishberg, A M (1938) *J clin Invest*, **17**, 510
French, H (1912) *Guy's Hosp Rep*, **66**, 353
Garvin, C F (1941) *Amer Heart J*, **21**, 371
Hewitt, J H (1916) *Johns Hopk Hosp Rep*, **17**, 1–80
Kaplan, D, and Hollingsworth, E W (1935) *J Amer med Ass*, **105**, 1264
Perry, C B, and Davie, T B (1939) *Brit med J*, **1**, 15
Potter, E B (1926) *Ann clin Med*, **4**, 736
Schiller, I A (1935) *J Mt Sinai Hosp*, **2**, 153
Schwartz, S P, and Biloon, S (1931) *Amer Heart J*, **7**, 84
Spain, D M (1943) *Ann intern Med*, **19**, 144
Welch, W H (1899) Albutt's *System of Medicine*, 7, 185
Wood, W (1814) *Edinb Med and Surg J*, **10**, 50
Wright, I S, Flynn, J E, and Druet, K L (1944) *Amer Heart J*, **27**, 858

MASS THROMBUS OF THE LEFT AURICLE

BY

WILLIAM EVANS AND ROBERT BENSON

From the Cardiac Department of the London Hospital

Received February 12 1948

We have used the term *mass thrombus* to describe a clot that forms in the left auricle during life and by reason of its large size or its peculiar location impedes the flow of blood through the mitral orifice In this paper we examine the clinical and pathological findings in six cases of mass thrombus with the object of discovering a symptom or sign that would simplify the diagnosis

Case Reports

Case 1 *Female, aged* 45 Two months before admission and while in bed she was suddenly seized with a gripping pain across the front of the chest and shoulders, she felt a sense of constriction of the chest with shortness of breath which lasted an hour Since then she had complained of retrosternal pain on exertion such as walking, and it abated on resting Besides the pain there was dyspnœa and swelling of the ankles on occasion

On examination there was slight cyanosis, distension of cervical veins, crepitations over the lung bases, and œdema of the ankles The pulse was irregular from auricular fibrillation, and the blood pressure was 110/80 The apex beat was displaced to the left, and a mid-diastolic murmur was heard Response to digitalis was satisfactory, but three weeks after admission to hospital there was sudden severe breathlessness and she died within a few minutes

At necropsy the right ventricle was slightly hypertrophied and the left auricle moderately dilated There was severe mitral stenosis, and a spherical and unattached thrombus was found to have lodged in the mitral orifice (Fig 1) The thrombus measured 3 cm in diameter, and it had undergone central liquefaction The other valves were normal Atheroma of the coronary arteries was slight and insignificant There was slight atheroma of the pulmonary arteries, and pulmonary embolism was excluded as a cause of sudden death There was old and recent infarction of the spleen and the left kidney

Case 2 *Female, aged* 40 Mitral stenosis had been discovered during pregnancy twelve years before For ten years she had been short of breath on exertion Femoral embolism had occurred seven years before, and the following year she began to have pain in the chest The first attack happened at rest after a day of heavy work, she was suddenly seized with severe retrosternal pain which radiated into the left arm as far as the elbow and lasted until an injection of morphine was given five hours later Cardiac infarction was suspected, but the electrocardiogram was normal Since then there had been four similar episodes at rest, the pain lasting up to twenty-four hours on each occasion and requiring morphine In addition to these unexpected attacks she complained of retrosternal pain which sometimes spread into both arms and came on during exertion, it was relieved instantly by rest For five years there had been palpitation on occasion as well as shortness of breath, while embolism of the right foot had also occurred During the past twelve months her general condition had become worse, and four months before she died it had been necessary to admit her into hospital on account of heart failure

On examination she was short of breath, the neck veins were distended, but there was only slight cyanosis Enlargement of the liver was accompanied by ascites and much œdema of the ankles The pulse was irregular from auricular fibrillation, and the blood pressure was 190/105 Systolic and mid-diastolic murmurs were heard in the mitral area Response to digitalis and a mercurial diuretic was unsatisfactory, and her condition gradually deteriorated with increasing dyspnœa She died suddenly whilst writing a letter

At necropsy there was moderate hypertrophy of the right ventricle and none of the left ventricle There was severe mitral stenosis, and the other valves were healthy The left auricle was moderately dilated, and it contained a slightly adherent thrombus measuring 7 by 6 by 2 5 cm

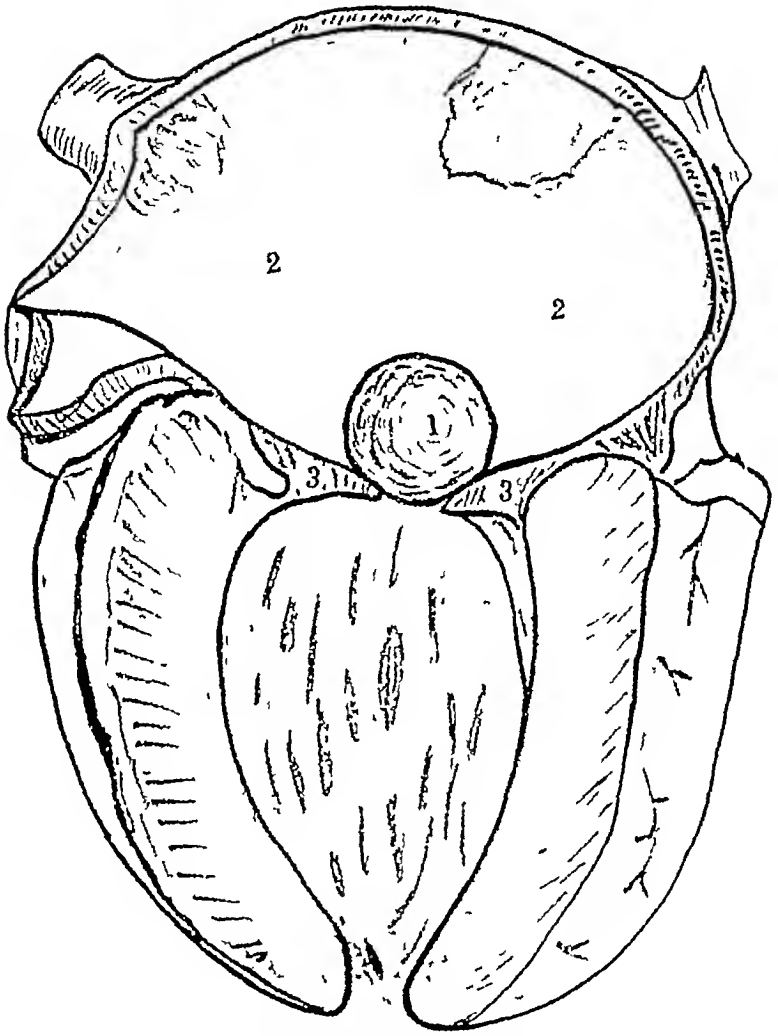

FIG 1 —Mass thrombus (1) in the left auricle (2) occluding the stenosed mitral orifice (3) From Case 1

There were ante-mortem clots in both auricular appendages The coronary arteries were normal, and there was no cardiac infarction The pulmonary arteries showed moderate atheroma An old thrombus was found in the abdominal aorta, and there were infarcts in both the spleen and the kidneys

Case 3 *Female, aged* 48 For some years she had suffered from attacks of palpitation which would start and stop abruptly, and which were unaffected by quinidine For the past nine years she had complained of retrosternal pain on exertion which frequently spread down the left arm and was relieved by resting Occasionally, however, the pain might start while at rest and might last two days One such attack had occurred five years before when she was in bed, and she was admitted to hospital where an electrocardiogram showed paroxysmal auricular tachycardia with 2 to 1 A-V dissociation She showed systolic and diastolic murmurs from mitral stenosis Digitalis changed the rhythm to auricular fibrillation and she remained relatively well for the next four years, though still subject to retrosternal pain on exertion During the last twelve months of her illness, however, the symptoms of heart failure gradually increased, and ultimately necessitated her admission to hospital

On examination there was slight cyanosis, dyspnœa, œdema of the back and ankles, and distension of the liver There were crepitations over the lung bases, and auricular fibrillation was associated with signs of mitral stenosis The blood pressure was 100/70 On the following day she suddenly became worse with cold and pulseless extremities, and died a few hours later

At necropsy there was great dilatation of both

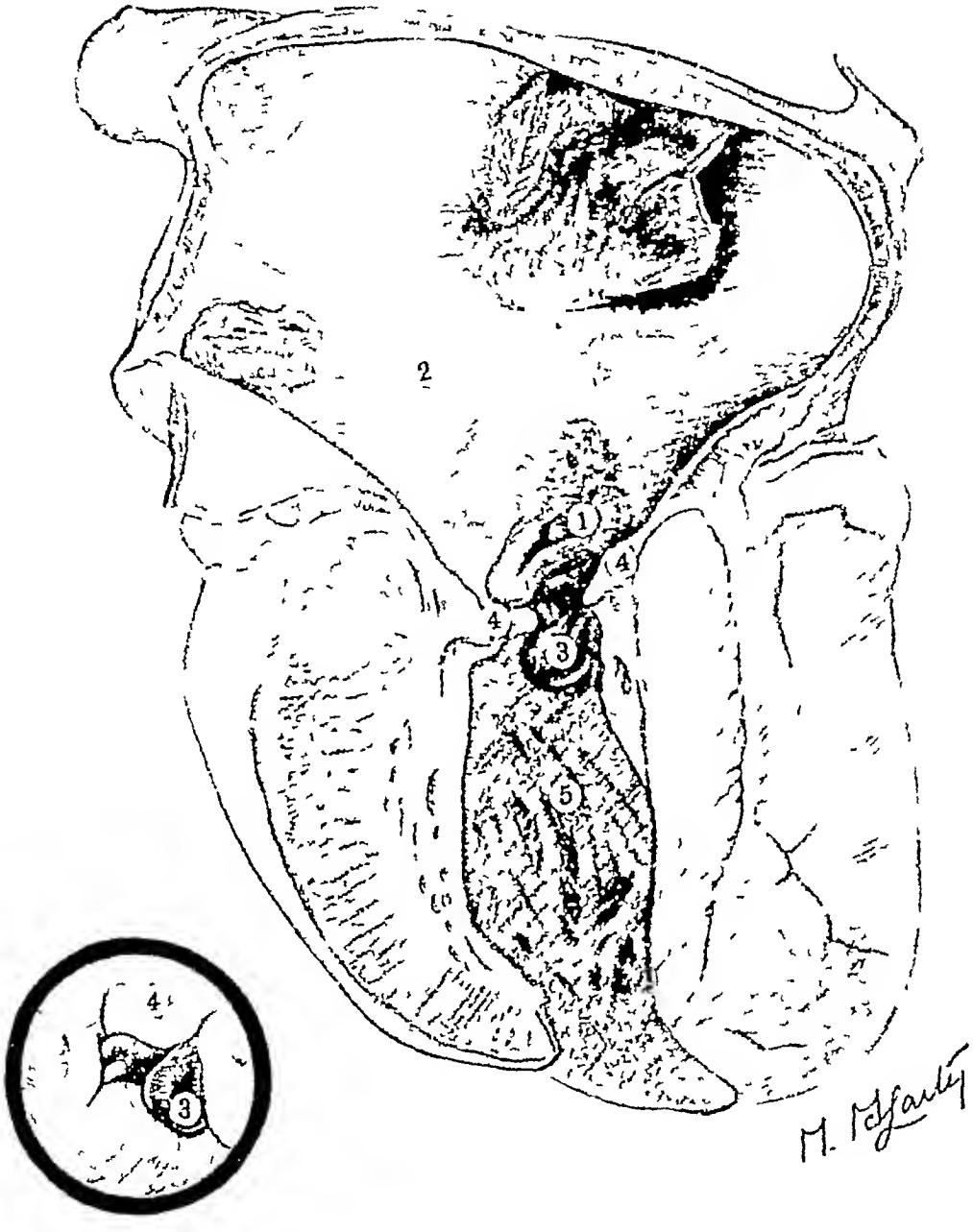

FIG 2 —Mass thrombus (1) in the left auricle (2) in a patient (Case 3) with mitral stenosis The lower end of the thrombus (3) projects through the stenosed mitral valve (4) into the left ventricle (5) Lower figure shows the valve from below

auricles from severe mitral and tricuspid stenosis The mitral orifice was almost completely occluded by a large thrombus (Fig 2) measuring 4 6 by 2 0 by 0 8 cm which was adherent to the auricular aspect of the valve The lower end of the mass was spherical with a smooth surface and central softening, and projected into the left ventricle The upper end was flat and lay partly free in the left auricle A firmly laminated and partly gelatinous thrombus of about the same dimensions was attached to the auricular septum over a small area, and a similar mass lay in the left auricular appendage The coronary arteries showed only slight atheroma, and there was no evidence of cardiac infarction The pulmonary arteries were moderately hypertrophied, and showed slight atheroma Areas of infarction were found in the spleen and the kidneys

Case 4 *Male, aged* 31 He had been short of

breath on exertion for many years, with swelling of the ankles for the past year During the last two months his symptoms had increased, and shortly before his admission to hospital he had suffered from nocturnal dyspnœa with hæmoptysis on one occasion, the dyspnœa was relieved by sitting up He had not specially complained of pain in the chest

On examination there was moderate dyspnœa with slight cyanosis and œdema, and crepitations were present over the lung bases The liver was moderately distended, but there was no ascites The urine contained one-third volume of albumin The pulse was regular, but auricular fibrillation supervened on the sixth day The pulse was less readily felt in the right arm The blood pressure was 155/95 The apex beat was displaced as far as the anterior axillary line, and both systolic and mid-diastolic murmurs were heard in the mitral area He had an irregular pyrexia from the start and developed a right-sided empyema He died six weeks after admission

At necropsy there was great hypertrophy of the right ventricle, and moderate dilatation of the left auricle as the result of severe mitral stenosis The left auricle contained a large free thrombus with a wavy surface, measuring 8 by 5 5 by 3 cm In addition there were three smaller thrombi, diameters 0 8 to 1 cm , which were attached to the left auricular wall The coronary arteries showed very slight atheroma Old and recent infarcts were found in the lungs, one of which had become purulent, resulting in empyema

Case 5 *Male, aged* 39 Breathlessness had been present for many years Auricular fibrillation with transient aphasia had set in six years before, and shortly afterwards severe heart failure symptoms had supervened Response to digitalis had been satisfactory and he had remained comparatively well until his symptoms again increased a few days before his admission to hospital He had not complained of chest pain

On examination he presented the signs of heart failure with auricular fibrillation The blood pressure was 140/95 A mid-diastolic murmur was heard in the mitral area He responded well to treatment by rest in bed, digitalis and a mercurial diuretic, and after seven weeks he was beginning to be allowed out of bed when he suddenly sat up, became extremely cyanosed and died in a few minutes

At necropsy there was moderate hypertrophy of both ventricles, and great dilatation of the left auricle from severe mitral stenosis The other valves were normal A laminated thrombus was found occupying two-thirds of the left auricle, and it was firmly attached to the endocardium over a large area There was moderate but incidental atheroma of the coronary arteries

Case 6 *Female, aged* 41 She had complained of palpitation and shortness of breath for five years and a year later she had heart failure with auricular fibrillation She improved and remained comparatively well on a maintenance dose of digitalis until a few months before her last admission, when, in spite of treatment, her symptoms had returned with greater severity She had not complained of pain in the chest

On examination there was slight dyspnœa, moderate œdema of the ankles, coldness and marked cyanosis of the hands and fingers, and a blotchy discolouration of the feet The pulse was irregular from auricular fibrillation, and was less easily felt on the right side The blood pressure was 170/120 in the right arm, and 270/120 in the left arm The apex beat was displaced to the left, and loud systolic and mid-diastolic murmurs were heard in the mitral area A few crepitations were heard at both lung bases The liver was moderately enlarged There was bilateral papillœdema with retinal hæmorrhages, and the urine, which had a low specific gravity, contained a large amount of albumin Digitalis and a mercurial diuretic were given but there was no improvement During the fourth week cerebral embolism occurred, followed by hæmaturia, oliguria, increasing drowsiness and Cheyne-Stokes respiration, the blood urea rose to 210 mg per 100 ml and she died six weeks after admission

At necropsy there was slight and moderate hypertrophy of the right and left ventricle respectively Both auricles were moderately dilated, and there was severe mitral stenosis The other valves were healthy On opening the left auricle a spherical thrombus fell out, the clot was quite unattached and measured 4 cm in diameter, and it had undergone cystic degeneration The left auricular appendage contained a few small fragments of ante-mortem thrombus There was slight incidental atheroma of the coronary arteries The right subclavian artery contained an old embolus, and infarction was present in the brain, the spleen and the kidneys Histological examination of the kidneys showed acute focal interstitial nephritis

Definition

The term "ball thrombus" was used by Wood (1814) who described for it the following criteria absence of attachment to the auricular wall, a diameter exceeding that of the passage immediately ahead of it, and a consistency that does not allow it to lodge in that passage Abramson (1924) in a review accepted the original definition, but

mentioned the case of Bozzolo (1896) in which a large pedunculated thrombus was found at necropsy Hewitt (1916) stipulated that the thrombus should have a smooth surface which shows no evidence of previous attachment to the heart wall, while Potter (1926) pointed out that the smoothness of the surface depends on the time the thrombus has been free, and accepted Wood's original definition Elson (1934), Aronstein and Neumann (1939), and Garvin (1941) considered that a distinction between free and pedunculated thrombi was academic since each produced identical symptoms To avoid ambiguity over the terminology of ball thrombus we have used the term *mass thrombus* to include any large thrombus, free or attached, that occupies the greater part of the left auricle, as well as any smaller thrombus that by reason of its proximity to the mitral valve may cause obstruction to the flow of blood through the mitral orifice When thrombosis is limited to the left auricular appendage it is without clinical significance except as a source of embolism

Incidence

Since Wood's original case in 1814 the reported cases have been well reviewed by Welch (1899), Hewitt (1916), Abramson (1924), Aronstein and Neumann (1939), Wright *et al* (1944) Forty-six cases have hitherto been recorded Cleland (1936) found only one ball thrombus among 3000 necropsies, and Garvin (1941) three among 6285 which included 156 cases with rheumatic heart disease Ball thrombus in chambers other than the left auricle is very rare (Gairdner, 1893, French, 1912, Wright *et al*, 1944) Our paper includes an analysis of 3083 consecutive necropsies among which there were 46 cases of mitral stenosis, in 6 of the latter a mass thrombus was discovered in the left auricle, and 3 of them conformed to the more rigid, and in our view too limited, definition of ball thrombus

Ætiology

Ziemssen (1890) was the first to state that mitral stenosis was essential to the formation of a ball thrombus, in the majority of cases there is great narrowing of the valve Yet a few cases have been recorded in which mitral stenosis was absent (Voelcker, 1893, Fischer, 1901, Pawinski, 1909, Dressler, 1928, Schwarz and Biloon, 1931, Kaplan and Hollingsworth, 1935) It is generally held that established auricular fibrillation contributes to the formation of a mass thrombus and that the condition rarely develops with normal rhythm (Osler, 1890, Spain, 1943) In one of our cases fibrillation had been paroxysmal until not more than four months before death, whilst in another fibrillation developed only at the last The size of the left auricle has no direct bearing on the formation of a mass thrombus, and there was only moderate dilatation in four of our cases In two there was great dilatation, but in none was it aneurysmal It is of interest that in the two cases of aneurysmal dilatation of the left auricle found in this series there was only moderate stenosis of the mitral valve

Symptomatology

It is probable that some of the symptoms and signs that have been ascribed to ball thrombus were the direct outcome of severe mitral stenosis, they include dyspnœa and embolism In order to evaluate the effects of the mass itself in the left auricle the symptoms ascribed to ball thrombus were compared with those arising from tumour of the left auricle (Table I) Twenty-seven reported cases were studied, and they included 21 with myxoma, 5 with sarcoma, and 1 with fibroma

TABLE I

Symptoms, other than Pain, in Patients Reported to have Tumour or Mass Thrombus of the Left Auricle Figures Denote the Number of Cases

Symptoms	Tumour (27)	Thrombus	
		Ball (46)	Present series (6)
Dyspnœa	Common	Invariable	Invariable
Cardiac asthma	Rare	Rare	1
Rapid course of heart failure	5	Absent	1
Syncope	7	6	1
Peripheral vascular signs	Absent	10	2
Auricular fibrillation	4	38	5
Murmurs	Systolic or presystolic	From mitral stenosis	From mitral stenosis
Postural effects	5	Absent	Absent
Sudden death	5	5	2

Dyspnœa was a more prominent symptom in the cases of ball thrombus as might be expected from the associated mitral stenosis It usually showed no special features, although cardiac asthma has been described (Schwarz and Biloon, 1931, Aronstein and Neumann, 1939) Such dyspnœa in uncomplicated mitral stenosis is thought to be due to rapid increase in the heart rate (McGinn and White, 1934), Ernstene (1936) and Bramwell and Jones (1944) consider that occlusion of the mitral orifice

is also a factor Although dyspnœa was rather less common as the first symptom of tumour of the left auricle, it occasionally presented unusual features in that it was sometimes severe in the absence of œdema (Horneffer and Gautier, 1913), or noticeably relieved by sitting up (Gilchrist and Millar, 1936) In Ernstene's (1936) case of mass thrombus due to bacterial endocarditis the patient lost consciousness whenever he sat up during an attack of paroxysmal dyspnœa In our series the first attack of chest pain was associated with severe dyspnœa in Case 1 and in Case 4 paroxysmal dyspnœa, which was relieved by assuming the upright posture, was a prominent symptom

Heart failure is common to cases of both tumour and thrombus, although in the former it is more rapid in its progress from the time of onset of symptoms (Houck and Bennet, 1929, Ludwig, 1933, Jensen, 1934, Shelburne, 1935*a*, 1935*b*, Gilchrist and Millar, 1936) In our series the symptoms of failure made their appearance from two months (Cases 1 and 4) to eleven years (Case 2) before death, and the average duration was four years The degree of failure shortly before death was slight in Cases 1, 3, and 5, moderate in Case 6, and severe in Cases 2 and 4 Failure was rapidly progressive whilst in normal rhythm in Case 4, though fibrillation supervened at the last

Giddiness and syncope, admittedly common symptoms in cardiological practice, appear to be more frequent in both tumour and mass thrombus of the left auricle Such symptoms were present in six reported cases of ball thrombus (Wood, 1814, Osler, 1897, Mathewson and Rotherford, 1920, Schwarz and Biloon, 1931, Elson, 1934, Garvin, 1941), and in our Cases 1 and 2 Ernstene and Lawrence (1936) described a patient who preferred to lie flat during attacks of paroxysmal dyspnœa because sitting up promptly resulted in loss of consciousness Giddiness and syncope are also common symptoms in tumour of the left auricle and they were present in seven reported cases (Berthenson 1893, Horneffer and Gautier, 1913, Houck and Bennet, 1929, Ludwig, 1933, Gilchrist and Millar 1936, Shelburne, 1935*a*, Fawcett and Ward, 1939) In Houck and Bennet s case, recurrent fainting in the erect posture was the first and most prominent symptom, and it was followed a few weeks later by sudden death In Shelburne s case fainting was followed in a few days by severe heart failure Paroxysmal fibrillation lasting three minutes was noticed during a fainting attack in Fawcett's case In our series loss of consciousness was found only once (Case 3), and even in this case it was probably the outcome of paroxysmal tachycardia

Auricular fibrillation is naturally a common accompaniment of mass thrombus since both conditions are found in long-standing mitral stenosis Normal rhythm has sometimes been noted (Osler, 1890, Spain, 1943), and it was observed in two of our patients, in Case 2 paroxysmal fibrillation was present for some years, while in Case 4 fibrillation set in very late That arrhythmia can result from a mass in the left auricle, quite apart from valvular disease, is shown by the incidence of paroxysmal or established fibrillation in cases of mass thrombus in the absence of mitral disease (Dressler, 1928, Kaplan and Hollingsworth, 1935, Pawinski, 1909) and in tumour of the left auricle (Jensen, 1934, Fawcett and Ward 1939) In other cases of tumour, bouts of extrasystoles or paroxysmal tachycardia have been noted (Eimer, 1928, Gilchrist and Millar, 1936, Thompson, 1944), and failure was present in at least two cases at the time In only one case did electrocardiographic evidence assist in the diagnosis (Shelburne, 1935*a*) when partial heart block developed due to sarcomatous involvement of the conduction system

Peripheral vascular phenomena Fishberg (1940) stated that occlusion of the mitral orifice by a free or pedunculated thrombus can only be assumed with any probability in the rare instances in which intense cyanosis develops with symmetrical ischæmia of all the extremities, the tip of the nose, and the ears He added that even this clinical picture may be caused by a very tight mitral stenosis The mechanism of this symmetrical ischæmia, which may proceed to gangrene, is thought to be severe peripheral vasoconstriction following a serious fall in the cardiac output Such a clinical picture developed in varying degrees in 10 of the 46 reported cases of ball thrombus (Fischer, 1901, Covey *et al*, 1928, Schwarz and Biloon, 1931, Elson, 1934, Schiller, 1935 Ernstene and Lawrence, 1936, Spain, 1934, Aubertin and Rime, 1926) Gangrene of the tip of the nose was described by Lutembacher (1917) but it is probable that this was embolic since bacterial endocarditis was also present Purpura was also a feature in two cases

In our series non-embolic peripheral vascular manifestations were present in two cases In Case 3 the extremities suddenly turned cold and pulseless, and at necropsy the mitral orifice was found occluded In Case 6 extreme cyanosis of the fingers was observed, disproportionate to the degree of heart failure and at necropsy a loose ball thrombus was found in the left auricle No case of transient peripheral cyanosis or gangrene was seen Among the 27 cases of tumour of the left auricle only two presented undue cyanosis of the hands and face, and severe heart failure was present in both It appears likely, therefore, that a stenosed mitral

valve is at least as important as a co-existent mass thrombus in the production of these phenomena Embolism is naturally common because of the mitral stenosis in cases of mass thrombus, but it is less frequent in those with tumour of the left auricle

Murmurs Evaluation of reported auscultatory signs is notoriously difficult, especially so with early writers It would appear, however, that a ball thrombus has little influence on the murmurs produced by the stenosed mitral valve Changing murmurs, although stressed in the past (Battistini, 1909, Pawinski, 1909) are rarely observed The case of Covey *et al* (1928) was remarkable in that a presystolic murmur developed whilst the patient was in hospital, and finally became so loud as to be heard a few feet away Schwartz and Biloon (1931) and Schiller (1935) noted the disappearance of sounds and murmurs with the advent of severe symmetrical cyanosis due to occlusion of a stenosed mitral valve by a mass thrombus, while Garvin (1941) remarked on the absence of murmurs in two cases of severe mitral stenosis with ball thrombus formation That a mass in the left auricle can cause murmurs which are indistinguishable by ordinary methods from those of mitral stenosis was the opinion of Ludwig (1933) who collected 20 reported cases and added another It has also been stated that a tumour of the left auricle may cause severe symptoms without the production of murmurs (Shelburne, 1935, Bennett *et al*, 1938, Fawcett and Ward, 1939, Hamilton-Paterson and Castleden, 1942) Of the murmurs found in cases of tumour of the left auricle a systolic murmur was the usual one, although a presystolic murmur was sometimes present

Radiology Mass thrombus in the left auricle cannot be detected by cardioscopy except in those very rare cases where a mural thrombus has become calcified (Berk, 1939) It does not affect the size or shape of the heart Tumours of the left auricle may alter the outline of the heart to resemble closely that of mitral stenosis (Dressler, 1928, Ludwig, 1933, Gilchrist and Millar, 1936, Bennett *et al* 1939), adding to the already erroneous diagnosis based on the murmurs which may be present Tumour of the right auricle may sometimes be suspected by a cardioscopic appearance similar to that seen in primary pulmonary hypertension (Hamilton-Paterson and Castleden, 1942), but a cardiogram should prevent this error

Sudden death Garvin (1941) described a man in whom heart failure had responded well to treatment in hospital, but who died suddenly when leaving the ward, at necropsy a small pedunculated thrombus was found to be wedged in the mitral orifice Sudden death may also result from a mass which occupies the larger part of the left auricle, and this has been reported in several instances where necropsy showed a tumour almost filling the auricle (Hoffmann, 1921, Houck and Bennet, 1929, Jensen, 1934, Gilchrist and Millar, 1936, Thompson, 1944) In our series death occurred unexpectedly and within a few minutes in Cases 1 and 5, in the former there was occlusion of the mitral orifice by the thrombus, and in the latter the thrombus filled two-thirds of the left auricle In Case 3 death occurred within a few hours of the onset of peripheral ischæmia, and at necropsy the mitral office was almost completely occluded by a thrombus As in the case of Thompson (1944) the terminal event was pulmonary œdema, presumably due to sudden heart failure, although in our case pulmonary œdema was remarkably slight

Cardiac pain An accurate account of pain was unusual in the literature that was reviewed, and vague terms such as oppression, præcordial pain, thoracic pain, etc, were used in the reported cases of ball thrombus (Arnold, 1890, Bozzolo, 1896, Hay, 1900, Ott, 1901, Elson, 1934) and in tumour of the left auricle (Bamberger, 1872, Berthenson, 1893, Thompson, 1904, Fawcett and Ward, 1939) Retrosternal pain was described in two cases of myxoma by Gilchrist and Millar (1936) and Bennett *et al* (1938), and in one of the three cases of occluding thrombus reported by Schwartz and Biloon (1931) The pain of cardiac ischæmia was a noticeable symptom in three of our six cases of mass thrombus in the left auricle Having regard to the non-specificity of other signs in this condition we mean to emphasize the importance of this symptom As we are at present observing 20 patients with mitral stenosis and cardiac pain, some of them for as long as ten years, it is unlikely that the pain is invariably caused by a mass thrombus None the less, in only one of the four cases in our series of 46 consecutive deaths from mitral stenosis in which pain had been a feature during life was a mass thrombus absent from the left auricle at necropsy Again, in six cases in which a mass thrombus was found, three had complained of cardiac pain, while only one of the remaining 40 cases of mitral stenosis without a mass thrombus of the left auricle had suffered from cardiac pain (Table II) We bring evidence to show, therefore, that although sometimes present in uncomplicated mitral stenosis, cardiac pain is a more likely event when mass thrombus in the left auricle has been added The pain in our cases was indistinguishable from that of cardiac ischæmia due to coronary disease or cardiac infarction Thus, its site was retrosternal, and its spread was into the shoulders

TABLE II

THE RELATION OF CARDIAC PAIN TO MASS THROMBUS OF THE LEFT AURICLE FROM AN ANALYSIS OF 46 CONSECUTIVE CASES OF MITRAL STENOSIS EXAMINED AT NECROPSY

Cases	Pain of cardiac ischæmia	Grade of mitral stenosis	Coronary atheroma	Mass thrombus in left auricle
1	Present	Severe	Incidental	Present
2	Present	Severe	None	Present
3	Present	Severe	Incidental	Present
4	Present	Severe	None	Absent
5	Absent	Severe	Incidental	Present
6	Absent	Severe	Incidental	Present
7	Absent	Severe	Incidental	Present
8 to 46	Absent	Slight 5 Moderate 17 Severe 17	None 0 Incidental 35 Severe 4	Absent

and sometimes down one or both arms It was brought on by exertion, especially walking, and it ceased as soon as the exercise which caused it was discontinued In Cases 1, 2, and 3 the pain also occurred at rest In Case 1 the first attack set in during rest and lasted an hour, it was accompanied by breathlessness In Case 2 the initial attack came on at rest and was only relieved five hours later after an injection of morphine, on five other occasions the painful attacks in this patient lasted for many hours Although the pain in Case 3 had usually been caused by exertion, her most severe attack startled her during rest and she cried out as she lost consciousness, auricular tachycardia was present in this attack, subsequently when in slow auricular fibrillation, she experienced cardiac pain In these three cases where the pain occurred at rest it was always more readily brought on by exertion Levine (1922) found only one case of mitral stenosis among 103 cases of angina, and White (1936) found two among 500 More recently Levine and Kauver (1942) found cardiac pain in 5 per cent of 314 patients with mitral stenosis In our series of 46 patients with mitral stenosis at necropsy cardiac pain had been present in four, in a fifth patient the attacks of retrosternal pain were brought on solely by paroxysmal tachycardia, and were not related to effort

Angina from all causes is reported as three times commoner in men than in women, but naturally the higher incidence of mitral stenosis in women increases the incidence in them of cardiac pain when it is the outcome of mitral stenosis, and all our cases were women

Concerning the age incidence of cardiac pain in mitral stenosis White and Mudd (1927) found that only about 2 per cent of cases of angina from all causes developed the pain before 40, while Levine and Kauver (1942) found 8 per cent in their series of mitral stenosis Three of our four cases began to have pain before 40 The average age at death in our series was 38 years, an age much younger than that given by Eppinger and Levine (1934) for all women with angina, or by Levine and Kauver (1942) in angina and mitral stenosis, where it was about 60 years

Different mechanisms have been invoked to explain the occurrence of cardiac pain in these cases (Sternberg, 1923, Telia, 1925, Hochrein 1930, Blackford, 1940) The importance of marked pulmonary changes with severe cyanosis was reported by Burgess and Ellis (1942) and by Parker and Weiss (1936), but they were not present in any of our cases

Naturally, coronary atheroma might coincide with mitral stenosis, but in our cases it was a casual finding when present, and it was never prominent enough to be significant as a cause of cardiac ischæmia

That cardiac pain is rare in auricular fibrillation has been over-emphasized, for although Levine (1922) found them to be associated in but two of 103 cases of angina, we have often observed them together even in non-valvular heart disease, while in three of the present cases cardiac pain and auricular fibrillation were found side by side Although some degree of heart failure was a common finding, we did not think that it contributed in any way to the development of pain

We believe that cardiac pain in mitral stenosis is the result of an impoverished coronary circulation resulting from the stenotic valvular effect, when mass thrombus in the left auricle is added the susceptibility to cardiac ischæmia is increased The fact that the incidence of cardiac pain is higher in those cases of mitral stenosis complicated by mass thrombus in the left auricle gives support to the belief that the pain is caused by cardiac ischæmia

SUMMARY AND CONCLUSIONS

The clinical findings in reported cases with ball thrombus or myxoma of the left auricle have been examined with the object of deciding which symptoms or signs permit a diagnosis of ball thrombus during life Among those attributed to the condition were dyspnœa, heart failure, giddiness, syncope, auricular fibrillation, certain heart murmurs, embolism and extreme cyanosis,

ischæmia or gangrene of the extremities None of them was a consistent finding

We consider that the definition customary for ball thrombus is too exacting and we suggest that the term *mass thrombus* should take its place and should include any large thrombus, free or attached, that occupies the greater part of the left auricle, as well as any smaller thrombus that by reason of its nearness to the mitral valve may cause obstruction to the flow of blood through the mitral orifice

Among 46 consecutive cases of pure mitral stenosis examined at necropsy we found six in which a mass thrombus was present in the left auricle Cardiac pain was a noticeable symptom during life in three instances, and it occurred once only among the 40 cases without a mass thrombus

We conclude that although cardiac pain from cardiac ischæmia may occur in uncomplicated mitral stenosis, the symptom is more likely to arise when a mass thrombus has formed in the left auricle

We wish to thank Professor Dorothy Russell, Director of the Bernhard Baron Institute of Pathology, and Dr W W Woods, for the records of the findings at necropsy in the cases we describe, and Dr A E Clark-Kennedy and Dr Horace Evans for permission to publish two cases under their care We are grateful to Sir John Parkinson, Physician to the Cardiac Department, for his helpful criticism of this paper

REFERENCES

Abramson, J L (1924) *Ann Clin Med*, 3, 327
Arnold, J (1890) *Beitr path Anat*, 8, 29
Aronstein, C G, and Neuman, L (1939) *Arch Pathol*, 27, 907
Aubertin, C., and Rimé, G (1926) *Presse méd*, 4, 736
Bamberger, V (1872) *Wien med Wschr*, 22, 26
Battistini, F (1909) *G Accad Med Torina*, 15, 313
Bennett, D W, Konigsberg, J, and Dublin, W (1938) *Amer Heart J*, 16, 117
Berk, L H (1939) *Arch intern Med*, 63, 1183
Berthenson, L (1893) *Arch Méd exp*, 5, 386
Blackford, L M (1940) *Amer Heart J*, 20, 492
Bozzolo, C. (1896) *Rif med*, 1, 98, 328
Bramwell, C, and Jones, A M (1944) *Brit Heart J*, 6, 129
Burgess, A M, and Ellis, L B (1942) *New Engl J Med*, 226, 937
Cleland, J B (1936) *Med J Austral*, 2, 50
Covey, G W, Crook, R., and Rogers, F H (1928) *Amer J med Sci*, 175, 60
Dressler, W (1928) *Wien klin Wschr*, 41, 1245
Eimer, K (1928) *Dtsch Arch klin Med*, 159, 164
Elson, J (1934) *Amer Heart J*, 10, 120
Eppinger, E G, and Levine, S A (1934) *Arch intern Med*, 53, 120
Ernstene, A C, and Lawrence, J C (1936) *Amer Heart J*, 12, 618
Fawcett, R E M, and Ward, E M (1939) *Brit Heart J*, 1, 249
Fischer, K (1901) *Ann allg Krankenh München*, 11, 165–184
Fishberg, A (1940) *Heart Failure* Lea and Febiger, Philadelphia, p 521
French, H (1912) *Guy's Hosp Rep*, 66, 353
Gairdner, W T (1893) *Edinb Hosp Rep*, 1, 221
Garvin, C F (1941) *Amer Heart J*, 21, 371
Gilchrist, A. R, and Millar, W G (1936) *Edin med J*, 43, 243
Hamilton-Paterson, J L, and Castleden, L I M (1942) *Brit Heart J*, 4, 103
Hay, J (1900) *L'pool med-chir J*, 20, 135
Hewitt, J H (1916) *Johns Hopk Hosp Rep*, 17, 1
Hochrein, M (1940) *Dtsch Arch klin Med*, 169, 195
Hoffmann, P D (1921) *Proc N Y path Soc*, 21, 85
Horneffer, C, and Gautier, P (1913) *Rev med Suisse rom*, 33, 57
Houck, G H, and Bennet, G A (1929–30) *Amer Heart J*, 5, 787
Jensen, C R (1934) *Northw Med, Seattle*, 33, 394
Kaplan, D, and Hollingsworth, E W (1935) *J Amer med Ass*, 105, 1264
Levine, S A (1922) *Ibid*, 79, 928
——, and Kauver, A J (1942) *J Mt Sinai Hosp, N Y*, 8, 754
Ludwig, H (1933) *Zeitsch klin Med*, 123, 587.
Lutembacher, R (1917) *Arch Mal Cœur*, 10, 353
Mathewson, G D, and Rotherford, A (1920) *Lancet*, 745
McGinn, S, and White, P D (1934) *Amer Heart J*, 9, 697
Ogle, J W (1863) *Trans path Soc Lond*, 14, 127
Osler, W (1890) *Johns Hopk Hosp Rep*, 2, 56
—— (1897) *Montreal med J*, 25, 729
Ott, F (1901) *Ann d stadt allg Krankenh z München*, 11, 185
Parker, F, and Weiss, S (1936) *Amer J Path*, 12, 573
Pawinski, J (1909) *Z klin Med*, 68, 75
Potter, E B (1926) *Ann clin Med*, 4, 736
Schiller, I A. (1935) *J Mt Sinai Hosp, N Y*, 2, 153
Shelburne, S A (1935*a*) *Ann intern Med*, 9, 340
—— (1935*b*) *Texas State J Med*, 31, 433
Schwartz, S P, and Biloon, S (1931) *Amer Heart J*, 7, 84
Spain, D M (1943) *Ann intern Med*, 19, 144
Sternberg, M (1923) *Z klin Med*, 97, 110
Telia, L (1925) *Arch Mal Cœur*, 18, 531
Thompson, R B (1944) *Brit Heart J*, 6, 23
Voelcker, A. F (1893) *Trans path Soc Lond*, 44, 31
Welch, W (1899) "Thrombosis" In Albutt, F C, *System of Medicine*, London, 6, 720
White, P D, and Mudd, S G (1927) *Amer Heart J*, 3, 1
—— (1936) *Diseases of the Coronary Arteries and Cardiac Pain, N Y*, p 269
Wood, W (1814) *Edin med surg J*, 10, 50
Wright, I S, Flynn, J E, and Druet, K L (1944) *Amer Heart J*, 27, 858
Ziemssen, V (1890) *Verh Kongr inn Med*, 9, 281

THE VARIATION OF CASUAL, BASAL, AND SUPPLEMENTAL BLOOD PRESSURES IN HEALTH AND IN ESSENTIAL HYPERTENSION

BY

JOHN ALEXANDER KILPATRICK

From the Department of Medicine, University of Otago, New Zealand

Received December 10, 1947

The levels of the blood pressure as ordinarily measured are widely variable but levels observed under standard conditions have been suggested to be less variable Consequently, standardized procedures have been devised to give stable blood pressure levels and the results, termed basal blood pressures, have been found to be much lower than the casual pressures ordinarily obtained No evidence has so far been presented to show that such basal pressures are physiologically constant in each individual

The term *basal blood pressure* originated when Addis (1922) used the expression to describe the level he had recorded in patients before they rose from bed in the morning He contrasted these low levels with those recorded later in the day Addis observed a much smaller difference between daytime and basal pressures in cases of glomerulonephritis than in cases of essential hypertension Ayman (1931) suggested means whereby more stable levels of blood pressure could be obtained especially as a preparatory step to evaluate the effects of treatment on essential hypertension, but did not refer to these levels as basal The term basal blood pressure was used in the Joint Report of the Committees of the Cardiac Society of Great Britain and Ireland and the American Heart Association on the standardization of methods of measuring the arterial blood pressure (1938) This committee stated "In detailed researches on blood pressure the use of a basal pressure might be considered after preparation similar to that used for basal metabolism It should be determined 10 to 12 hours after the last meal of the previous night and after resting for half an hour in a warmed room"

Alam and Smirk (1938) indicated that they were using a basal blood pressure as a base-line in studies of blood pressure raising reflexes and later (1943) obtained results approximating to the basal blood pressure with a procedure which they termed emotional desensitization to the presence of the observer and to the process of sphygmomanometry, with special attention to rest in a warm quiet room, but taking no special precautions as to the time of day or the time after the last meal Alam and Smirk, from observations of blood pressure obtained by this method, suggested that readings obtained under ordinary clinical conditions should be called casual blood pressures, and those obtained under basal conditions, basal blood pressures, and that the difference between casual and basal blood pressure levels should be called the supplemental blood pressure This represents the degree of elevation of the blood pressure above the basal level due to physical, metabolic, mental, and emotional stimuli at the time the casual blood pressure is taken The less the physical metabolic and emotional pressor stimuli at the time the casual pressure is observed the nearer will this pressure approach the basal level for that individual and the lower will be the supplemental pressure

Later Smirk (1945) showed that the technique Alam and he had described for basal blood pressure determination, when applied without regard to the time of the previous meal, produced lower results than were ordinarily obtained by the method advocated by the Cardiac Societies He showed further that when both methods were combined the resulting basal blood pressure level was slightly lower than with either method when used alone

This investigation was primarily designed to determine if in health and in essential hypertension the basal pressure is in fact a constant measurement for the individual In the course of the work observations were made to investigate a more rapid and convenient method of basal blood pressure

determination using a hypnotic drug Different degrees of variability of blood pressure were observed among the hypertensive subjects studied and an analysis of the supplemental pressure of these and of normal subjects was undertaken to determine if there was also a relationship between the presence of congestive heart failure and variability of the blood pressure level

Method

Except in the group of subjects in which an hypnotic drug was given the method of basal blood pressure determination which was used throughout this study was that outlined by Smirk (1945), namely a combination of the routine described by the combined committee on blood pressure measurement and that of Alam and Smirk (1943) The procedure was designed to measure the blood pressure when the subject was in the basal metabolic state and was free from states of emotion or mental alertness

Many subjects will not attain a basal state if they gain the impression that the blood pressure measurements are merely the prelude to some unfamiliar and possibly unpleasant procedure For this reason the subjects were informed on the day before the determination that no procedure would take place except blood pressure measurements with which they were already familiar The object of the experiment and the procedure to be used were outlined and instruction was given to keep the mind blank and the body relaxed and still, as though trying to go to sleep Talking was not allowed In the morning the subject used a urinal or bed pan, if necessary, soon after waking The subject did not get out of bed nor have any food but was moved to a quiet warm single room where he or she remained alone, without reading and, if possible, asleep for about half an hour The observer then entered quietly, adjusted the sphygmomanometer and proceeded to record the level of the blood pressure about twice each minute, for the next twenty to thirty minutes No other person entered the room during the determination The observer did not move about the room or engage in any pursuits that would divert the subject's attention The lowest systolic pressure which was recorded three times and the accompanying diastolic pressure were taken as the basal blood pressure

All the blood pressure measurements were made on the left arm which was supported at heart level The same mercury manometer was employed throughout the study using the method of judging systolic and diastolic level detailed by the British and American Cardiac Societies All the observations were made by the author and the sphygmomanometer used was checked against a standard instrument several times in the course of the study In each of the subjects casual blood pressure readings were taken on the day before or later on during the day on which basal blood pressure determinations were made These casual blood pressure measurements were designed to conform with those ordinarily made in wards or clinic The measurements were all made with the patient reclining and on the left arm which was supported at heart level, but no special precautions were taken to eliminate the effects of exercise, meals, or emotional factors

Subjects

The subjects upon whom measurements were made were mainly convalescent patients awaiting discharge These subjects had blood pressures ranging from normal to hypertensive levels The reason for admission to hospital varied, most of the subjects having complaints quite distinct from essential hypertension such as hernia, peptic ulcer, chronic diarrhœa, etc , but there were several whose main complaint was associated with essential hypertension, such as headaches, dizziness, encephalopathy, or hemiplegia

To assess the degree of constancy of casual and basal blood pressure levels, casual blood pressure readings were made and the procedure of determining the basal blood pressure was carried out from four to seven times in each of 33 subjects These subjects were grouped according to the level of the casual blood pressure

Group I Eleven subjects in whom the mean casual systolic blood pressure was 132 mm of mercury or less and in whom no single systolic reading exceeded 140 The casual diastolic readings were never above 90

Group II Eight subjects in whom the casual blood pressures were higher than those of Group I but whose mean casual systolic pressure did not exceed 160 the mean casual diastolic readings were all below 90

Group III Fourteen subjects with essential hypertension without albuminuria but including some with early congestive heart failure, whose mean casual systolic pressures all exceeded 160 and whose mean diastolic pressures were all above 90

The effect of premedication with pentobarbitone soluble in decreasing the time required for basal blood pressure determination was studied in nine subjects equally distributed among the above three groups

In 44 subjects casual blood pressure levels were measured and basal blood pressure determinations

were carried out on one occasion and the supplemental (casual minus basal) pressure determined by calculation These subjects were grouped as before into a group of 14 subjects with normal levels of casual blood pressure and a group of 8 subjects with intermediate casual blood pressure levels but the third group of hypertensive subjects was divided into two sections Group III A 13 hypertensive subjects whose blood pressures conformed to the levels outlined previously for Group III in general but without history or signs of congestive heart failure Group III B 12 hypertensive subjects as above except that they showed signs of congestive heart failure

Results and Discussion

To determine the variability from day to day of both casual and basal pressures the results in the first series of 33 subjects were graphed separately (Systolic pressures Fig 1 to 6) The graphs were drawn on a common chart for each group so that the zero line represents the mean systolic blood pressure of each subject and each continuous line shows the fluctuation of that subject's blood pressure above and below the zero line from day to day The charts were all drawn to the same scale

Fig 1 shows the variation among the casual systolic blood pressures measured from day to day in each of 11 normal subjects (Group I) while Fig 2 shows the variation of the basal systolic pressures in the same subjects

The close approximation of the lines in Fig 2 suggests that over the period of two weeks to one month during which observations were made the basal systolic pressure of these subjects was almost constant The greater degree of variability in the casual blood pressure is shown by the wider spread of the lines in Fig 1 than in Fig 2

The charts of Group II—Fig 3 and 4—show an even more marked difference between the variation of casual and basal systolic pressures This group of subjects was selected to conform to the pre-hypertensive subjects of Hines (1940) and the hyper-reactors of Ayman (1934) In this group the casual systolic pressures (Fig 3) are more variable than those of the normal subjects of Group I (Fig 1) The basal pressures of this group seem to be slightly less constant than in the normal subjects There is a general tendency for the first basal pressure in each subject to be high This initial high reading may indicate that the first attempt was unsuccessful owing to the presence of concealed emotional tension or of apprehension When these doubtful initial readings are eliminated from the charts the basal pressures upon which reliance may be placed are seen to be almost constant

Fig 5 and 6 show the variability of casual and basal systolic pressures in the hypertensive subjects of Group III The gross variation of the casual pressures from day to day (Fig 5) is striking, while the basal pressures (Fig 6) are less variable and, if the first observation is excluded for the reasons given above, the remainder show appreciably less variation than do the casual pressures

The degree of constancy shown by the basal systolic figures in general and in Group I in particular (Fig 2), increases in significance when the following points are considered It had been shown that with repetition of the readings, blood pressure levels tend to drop due to the removal of some of the emotional stimulation or mental alertness associated with sphygmomanometry Such repeated readings, would, therefore, tend to become more constant This factor plays a large part in producing the relatively small variation of casual pressure seen in Fig 1, as the subjects were having readings taken over many days, and towards the end of the series they were so accustomed to the procedure that the casual pressure would fall and the readings observed would show some degree of false constancy not actually to be expected in a series of truly casual readings The basal blood pressures observed, on the other hand, were readings taken after placing the subject as far as possible in basal conditions The experimental errors which could occur would all tend to give readings rather higher than the true basal level, and such errors might be many Small, apparently innocuous variations of technique might occur On one occasion it was found that two subjects were showing rather higher basal pressures than had previously been recorded On investigation it was found the subjects had walked from the ward to the room where the basal pressures were measured instead of being moved in bed These readings were, of course, discarded as being non-basal One patient, who was suffering from peptic ulceration, showed a high level of basal pressure after a night disturbed by slight but annoying abdominal pain

The most remarkable divergences from the usual basal level were shown when concealed emotional factors were present One hypertensive subject had received by letter disturbing news about her son's conduct. The basal pressure next morning was 50 mm higher than usual and only after prolonged questioning was the cause revealed In another instance the subject, a soldier, showed slowly increasing levels of basal pressure Interrogation failed to reveal any cause for anxiety known to the subject, but it was found by chance that he was

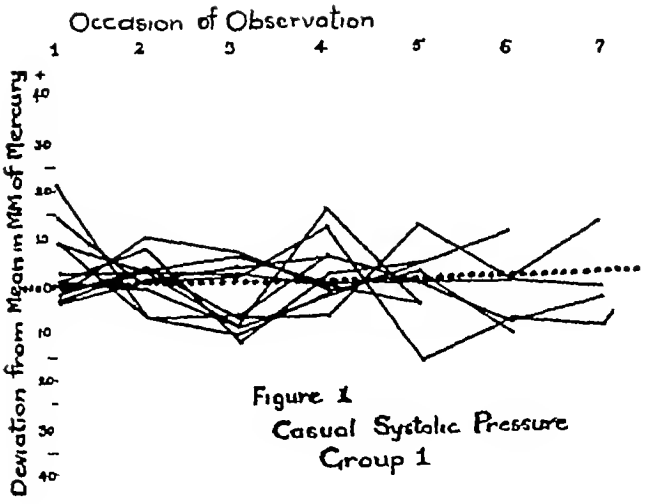

Figure 1
Casual Systolic Pressure
Group 1

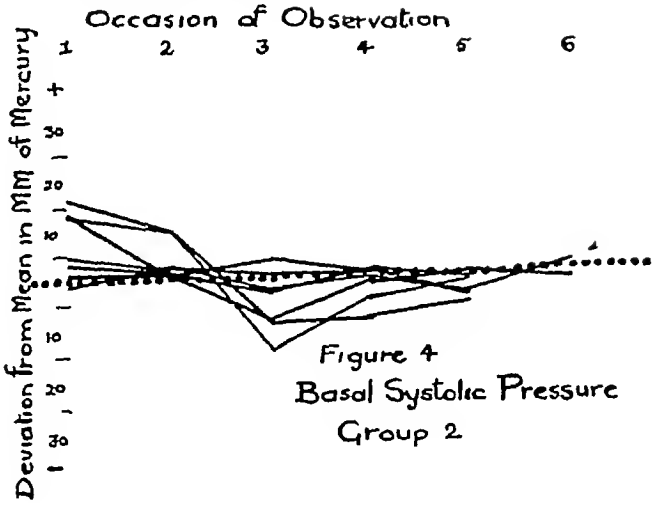

Figure 4
Basal Systolic Pressure
Group 2

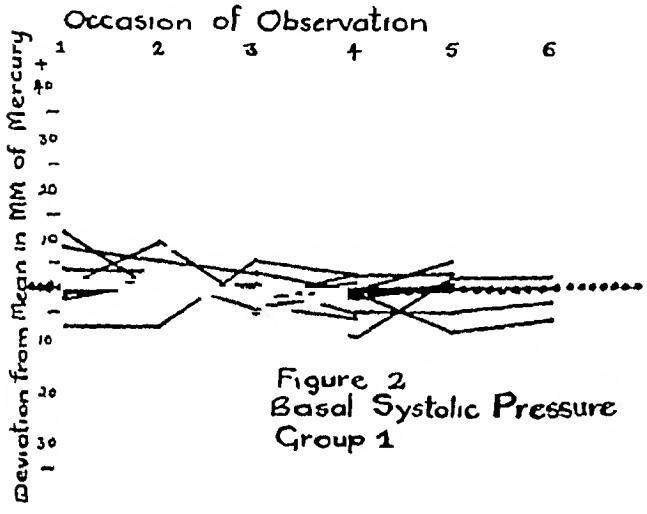

Figure 2
Basal Systolic Pressure
Group 1

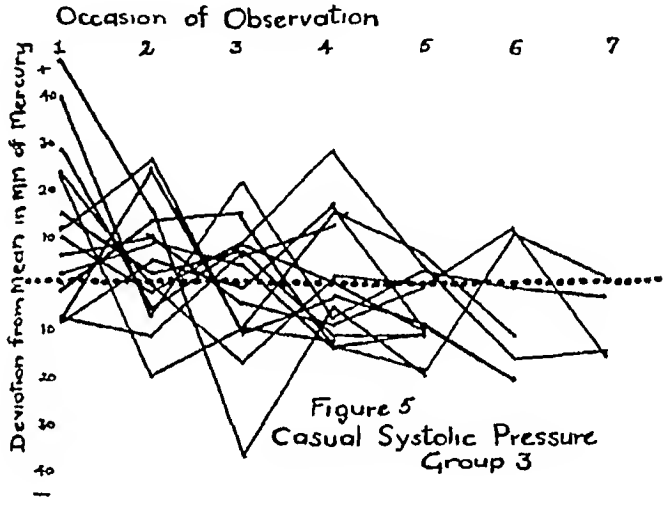

Figure 5
Casual Systolic Pressure
Group 3

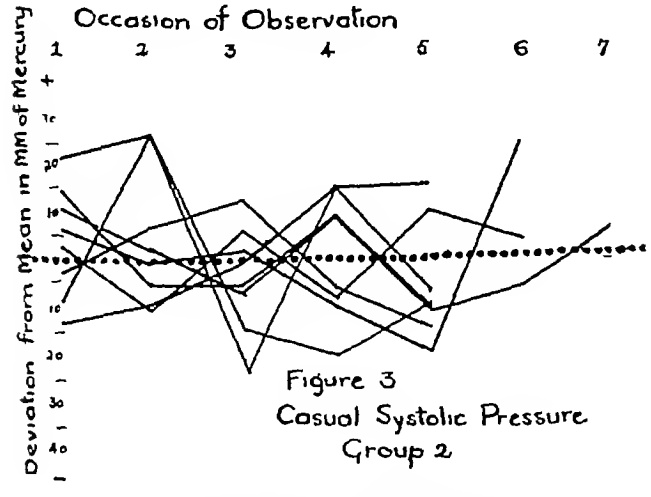

Figure 3
Casual Systolic Pressure
Group 2

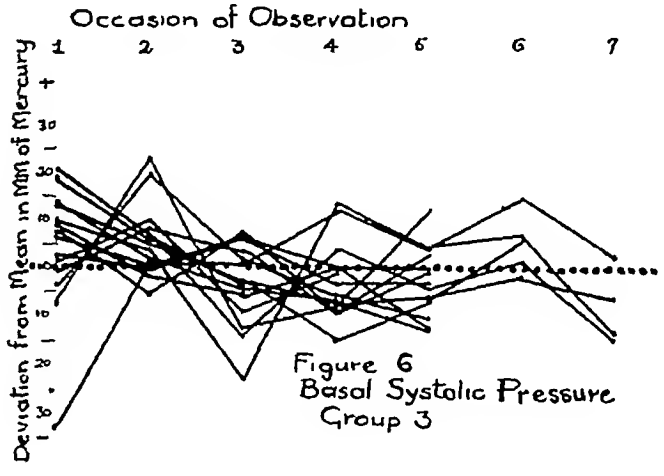

Figure 6
Basal Systolic Pressure
Group 3

FIG 1–6 —The degree of variation from day to day of the systolic blood pressure levels of the subjects in the three groups The levels of the individual readings of each subject are plotted as points above or below a zero line that represents the mean level of that subject The points are connected by lines so that each line shows the variation of blood pressure in one subject The casual and basal pressures are shown separately In each group the lines for the individual subjects are drawn to the same scale on the one chart so that the one common zero line represents the mean of each subject

The degree of variation is shown by the extent of spread of the lines above and below the zero line The scale is in millimetres of mercury

The subjects were grouped as follows Group I, normal blood pressure levels, Group II, intermediate pressure levels, Group III, hypertensive levels

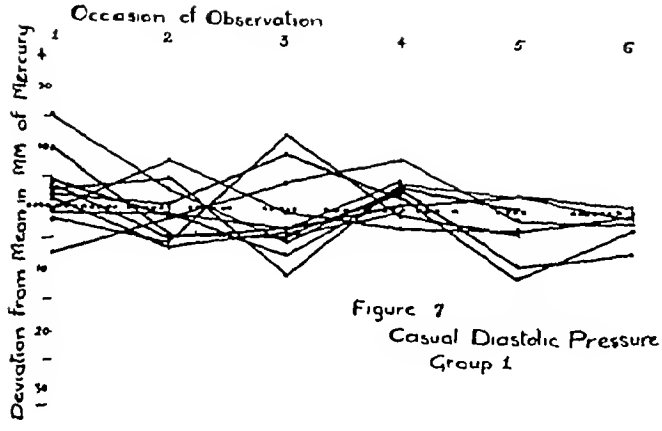

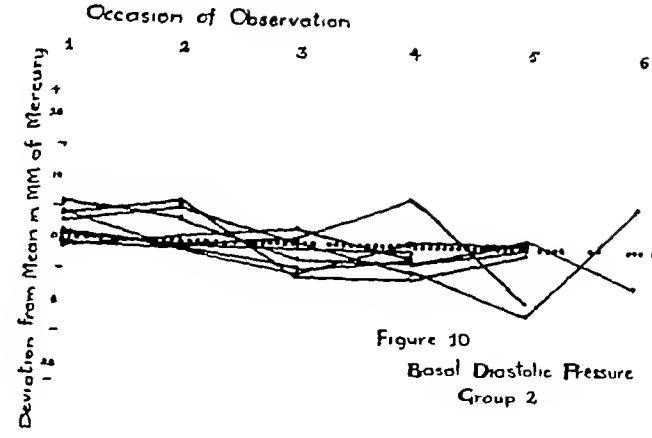

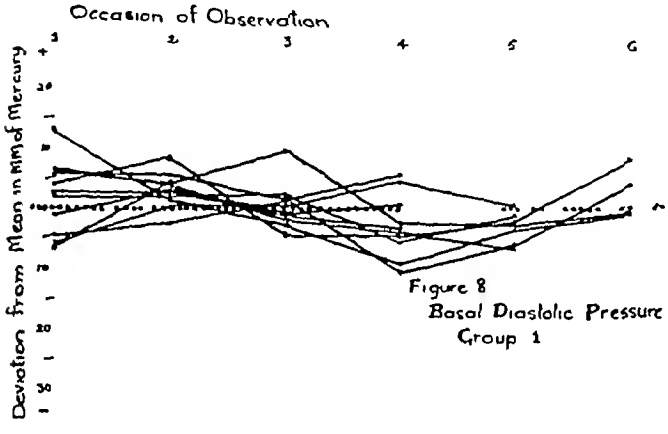

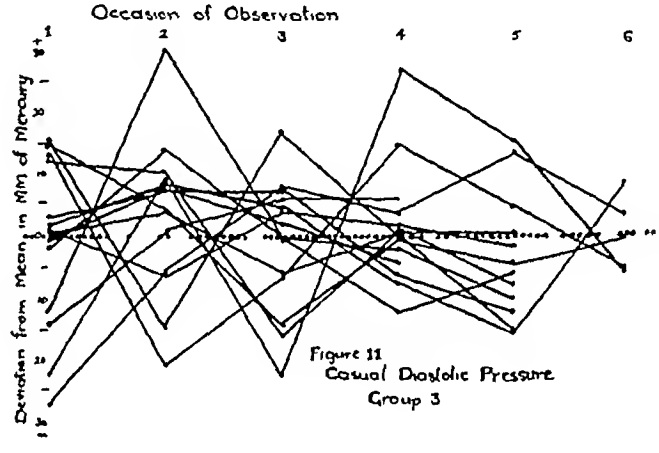

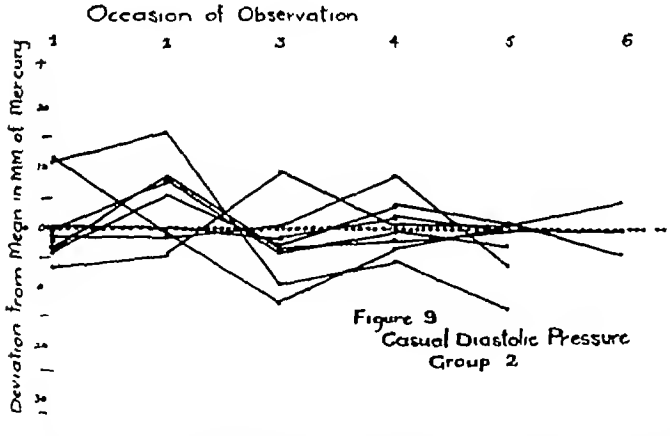

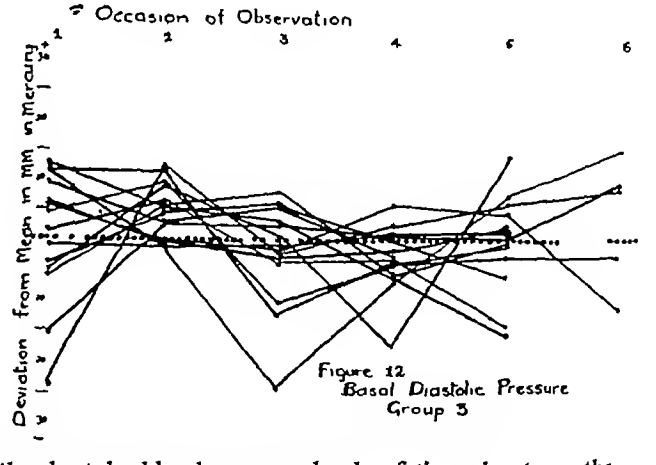

FIG 7–12 —The degree of variation from day to day of the diastolic blood pressure levels of the subjects in the three groups The casual and basal pressures are shown separately For details see Fig 1–6

due to have an Army Reboard to decide if his military service would be terminated He was discharged from the Army, as he had hoped, and further basal blood pressure readings returned to their previous level In such cases there was failure to obtain a basal pressure Some such errors may have been present without our knowledge in a few of the readings which have been accepted as basal and would tend to make the variation observed in the basal pressure appear to be greater than the true variation, which must be slight

One of the most constant experimental errors which must be considered in assessing the accuracy of the results is that due to the sphygmomanometer This error is due to the vibration of the mercury column with the pulse wave and to a few millimetres

rise and fall of the blood pressure during respiration Neither of these factors is constantly present but both may, in certain subjects, be the source of a relatively large error There is also the factor of personal error which is more important in assessing the diastolic level A reasonable estimate of the total possible error would be ±4 mm of mercury for the systolic and ±8 mm of mercury for the diastolic Larger errors were prevented by strict adherence to the method of blood pressure measurement outlined by the combined committee of the Cardiac Societies

When these sources of error are kept in mind and Fig 1 and 2 reconsidered it is obvious that the basal systolic pressure must be considered to be constant from day to day in normal subjects in a physiologically constant state Fig 1 to 6 show that casual systolic readings are much more variable in essential hypertension than in health Throughout the series of observations it was noticed that hypertensive patients did not relax easily, neither physically nor mentally Basal levels of blood pressure were more difficult to attain especially if there was at the time any emotional disturbance such as apprehension During basal blood pressure determination sudden noises, interruptions from the corridor, lift-gates slamming, etc, would produce larger elevations of pressure in hypertensives than comparable stimuli in normal subjects It has previously been noted that definite emotional pressor factors were found in some hypertensives and that these factors were difficult to eliminate Some hypertensives may be inherently emotional, tense and restless Others, no doubt, have vascular systems which are more reactive than the average to emotional or other stimuli Very likely still others are inherently emotional and have, as well, a high vascular reactivity

In any experimental studies to determine the degree of improvement in essential hypertension, a comparison of the basal blood pressure levels before and after treatment would give a more accurate measure of the clinical result than would a comparison of casual levels, which are so highly variable In almost all reports on the results of therapy in essential hypertension conclusions have been drawn from an observed difference in casual blood pressure levels and in many the difference observed could easily have been due to chance variation

The levels of the diastolic pressures were also recorded throughout the study and the results graphed as for the systolic pressures Fig 7 and 8 show the variation of casual and basal diastolic pressures of the normal subjects (Group I), Fig 9 and 10 the casual and basal diastolic pressures of Group II with rather higher pressure levels, and Fig 11 and 12 show the casual and basal diastolic pressures of the hypertensive subjects (Group III) The same general features may be seen as with systolic pressures namely that the basal levels are much more constant than are the casual levels Fig 8 shows that within the rather larger limit of experimental error (±8 mm of mercury) the basal diastolic pressure is constant from day to day in healthy subjects

It is often stated that the diastolic pressure is less variable than the systolic pressure Except in the subjects with slightly abnormal blood pressure levels (Group II—Fig 3 and 4, 9 and 10) this does not seem to apply to the subjects studied as the spread of the graphs in Fig 7 and 11 is not significantly less than the spread in Fig 1 and 5 respectively It is to be expected that in the hyper-reactors of Group II, the diastolic pressures, both casual and basal, would be more constant than the systolic pressures because lability of the systolic pressure is the main criterion of selection in this group

The levels of blood pressure observed in this section of the study are shown in Fig 13 For Group I, the subjects with normal blood pressure level, the mean casual pressure was 118 mm systolic and 79 diastolic, while the mean basal pressure was 103 systolic and 72 diastolic In Group II, composed of prehypertensive subjects, the mean casual level was of course higher, namely 138 mm systolic and 82 mm diastolic, while the mean basal level was not appreciably different from those of group one, namely 109 mm systolic and 69 mm diastolic In the third group, in which hypertensive subjects of varying levels were classed, the mean casual pressure was 177 mm systolic and 117 mm diastolic It should be emphasized here that in any group of subjects the mean supplemental pressure must be calculated from the individual casual and basal levels of each subject The difference between the mean casual level, and the mean basal level gives no information as to the mean supplemental pressure of the group

In several cases in each group of subjects 1 5 grains of sodium pentobarbitone was given by mouth shortly after waking on the morning of the basal blood pressure determination It was found that basal levels were more quickly attained in this way, in nine of the cases in whom an average of over eight minutes was required for the blood pressure to reach basal levels without premedication, the use of the drug gave equivalent levels in under three minutes For accurate work, however, a much longer time should be spent in the determination because in some cases low levels are attained only after twenty to thirty minutes of habituation The hypnotic had the added advantage

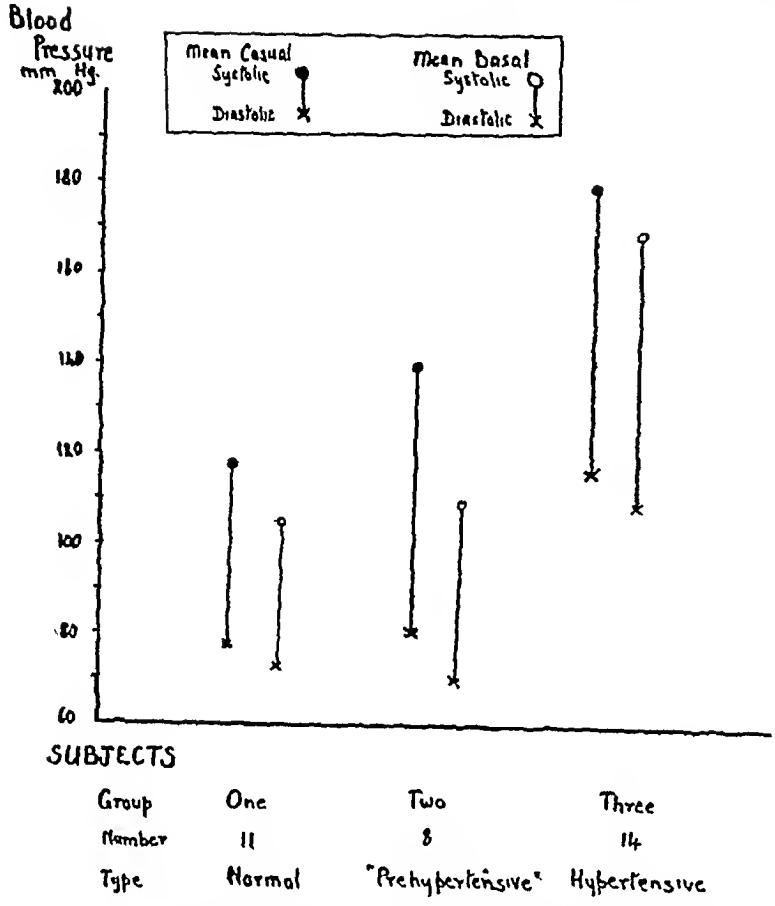

FIG 13 —The mean casual and basal blood pressure levels in Groups I, II, and III

of keeping the patient rested and quiet for a much longer period so that the determination of the basal blood pressure level could be made at a time much more convenient for the investigator than soon after the subject wakes in the morning as was originally proposed

The method of basal blood pressure determination used in this study was designed to give as accurate an estimate of the true basal blood pressure as it is possible to obtain In practice a fair approximation may be obtained on outpatients in the consulting room by a trained assistant with preparation of the patient as for basal metabolic rate determination The accuracy of such readings would be increased if premedication with a rapidly acting barbiturate, such as sodium pentobarbitone as described above, were used and if several determinations were made on different occasions as the first reading is usually higher than later ones The effect of the premedication rapidly wears off, all of the subjects studied being quite able to carry on their daily work two hours after the test

THE SUPPLEMENTAL PRESSURE

In the course of the investigation there were found to be striking differences in the drop in blood pressure observed in different subjects during basal blood pressure determination To amplify this observation a further series of 44 subjects was studied, one casual blood pressure reading and one basal blood pressure determination being carried out on each subject and the supplemental pressure determined by subtraction The supplemental pressure is a measure of the degree of elevation of the blood pressure due to emotional, nervous, and metabolic factors and to physical exertion and therefore varies from person to person and from moment to moment but gives an indication of the reactivity of the blood pressure

The subjects were grouped as before into three main groups according to the level of the blood pressure, normal, intermediate, and hypertensive, but the hypertensive group was further subdivided into two sections Group III A consisted of 13 hypertensive subjects without signs or symptoms of congestive heart failure and Group III B was composed of 12 subjects with varying degree of congestive heart failure

Table I shows the results of the investigation in these 44 subjects There are obvious and striking differences in the mean supplemental pressures of the various groups The normal subjects showed supplemental pressures of about 20 mm, while the group with intermediate casual pressure levels showed a rather higher figure as was to be expected from the method of selection In the subjects with essential hypertension the mean supplemental pressure was over twice that of the normals When the essential hypertension was complicated by congestive heart failure, however, the supplemental pressure was barely one-fifth of that in the uncomplicated cases and barely half that of the normal subjects

To determine the significance of these observations a statistical analysis was made, the results (Table I) giving mean supplemental pressures in the three groups To assess the statistical significance of the differences observed between these mean values of supplemental pressure, the standard error of each

TABLE I

THE MEAN SUPPLEMENTAL BLOOD PRESSURE AND STATISTICAL SUMMARY

Group and number of subjects	Mean supplemental pressure in millimetres of mercury	Standard deviation in millimetres of mercury	Difference between mean supplemental pressures with standard error of difference in millimetres of mercury		
			Groups compared	Difference with standard error of difference	Significance
I 14 normals	18 2	8 51	I (18 2) II (25 0)	6 8±4 97	Nil
II 8 prehypertensives	25 0	12 51	III A (44 6) I (18 2)	26 4±4 27	High
III A 13 hypertensives without heart failure	44 6	13 02	III A (44 6) III B (9·0)	35 6±3 82	Very high
III B 12 hypertensives with heart failure	9 0	4 32	I (18 2) III B (9 0)	9 2±2 59	High

difference was calculated A statistically significant difference between two mean values exists when the numerical difference between the values exceeds double the standard error of that difference In this table it may be seen that the supplemental pressure of the group of hypertensive subjects is significantly higher than that of either the normal subjects or the subjects with hypertension complicated by heart failure, and the supplemental pressure of this latter group is significantly lower than that of the normal subjects

The great elevation of the supplemental pressure in essential hypertension accords with the previous observation that in essential hypertension the blood pressure shows marked variation The low supplemental pressure in essential hypertension with congestive heart failure shows that the reactivity of the circulatory system to metabolic factors, physical work, and nervous and emotional factors is reduced It might be argued that the basal blood pressure in these subjects would therefore be constant In those subjects on whom repeated basal blood pressure determinations were made, however, it was found that from day to day the level of the basal blood pressure was not quite constant although during each determination the level of the systolic pressure changed very little This suggests that a possible explanation for the low supplemental pressure found in these heart failure cases is that the method of basal blood pressure determination does not succeed in removing the pressor factors mentioned above and that a true basal level is not attained Possible causes for this are the frequent presence of dyspnœa and Cheyne-Stokes respiration and the general discomfort of the patient, all of which would tend to prevent the attainment of completely basal conditions In several patients, however, determinations were made during both the acute illness when dyspnœa and general discomfort were marked and during convalescence when the patient was well In these cases the supplemental pressure during convalescence was as low as that found during the acute phase of heart failure

Apart from this effect the strictly controlled conditions of the experiment do not seem to admit of other reasons for failure to attain a basal level and there is, therefore, no reason to suspect that the process of basal blood pressure determination was any less effective in the patients with congestive heart failure than in those with uncomplicated essential hypertension Similarly, the presence of the low supplemental pressure in the convalescent patient suggests that heart failure by itself is not sufficient to account for the vastly different supplemental pressures found in compensated and in failed essential hypertension The reduction of cardiac output which may accompany congestive heart failure may account, in part, for the low supplemental pressure observed For in cases of congestive heart failure the cardiac output is close to its maximum and cannot be much increased in response to the usual pressor stimuli The blood pressure, which is maintained by the cardiac output and the peripheral resistance, may, however, be altered by variation in the latter factor

If alteration in the cardiac output was the sole cause of the low supplemental pressure one would expect that with recovery of some degree of circulatory compensation the low supplemental pressure observed in the acute phases would be expected to rise In the cases observed this did not occur

It is possible that the low supplemental pressure observed in congestive heart failure was present before failure occurred and that it is a manifestation of reduced variability of the peripheral resistance rather than reduced variability of the cardiac output A low supplemental pressure may indeed indicate an early onset of congestive heart failure, in that with a sustained high level of peripheral resistance the cardiovascular system would fail sooner than when, with the same level of casual blood pressure and a high supplemental pressure, the cardiovascular system was relieved, during rest, of a large part of the peripheral resistance The presence of a low supplemental pressure in cases of essential hypertension may, therefore, be of assistance, along with the degree of hypertension, in assessing prognosis, especially as to the onset of congestive heart failure

The hypertension of chronic nephritis, in which only a small amount of variation occurs (Kylin 1921, Ayman 1931, Gatman, Nassif Amin, and Smirk 1943) is, in this respect distinctly different from the hypertension of subjects with early stages of essential hypertension (Group III A) in which a large supplemental pressure occurs On the other hand the hypertension of chronic nephritis, which is widely accepted as being mediated by the renin system, resembles that of the failed cases of essential hypertension of Group III B in that a low supplemental pressure occurs in both The observation that the relief of renal congestion by an improvement in cardiovascular function does not increase the supplemental pressure suggests that renal congestion by itself is not sufficient to account for the similarity of the blood pressure responses of chronic nephritis and of cases of failed essential hypertension

Conclusions

The basal blood pressure of normal subjects is constant for periods of one to three weeks

The casual blood pressure of normal subjects is a variable figure

The casual blood pressure of subjects with essential hypertension is exceedingly variable

The basal blood pressure of subjects with essential hypertension is much more constant than the casual blood pressure A part of this variability is probably due to the greater difficulty in securing basal condition in these subjects

The use of an hypnotic drug (soluble pentobarbitone, 1 5 grains given by mouth half to one hour before the test) preparatory to basal blood pressure determination gives levels of basal blood pressure comparable to those obtained without such premedication and greatly reduces the time taken to obtain a basal level in nearly all cases

The mean supplemental pressure in a group of normal subjects was 18 mm of mercury In a group of hypertensive subjects the mean supplemental pressure was 44 mm of mercury The difference between these figures is statistically significant In a group of hypertensive subjects with congestive heart failure, however, the mean supplement pressure was 9 mm of mercury, significantly lower than that of the normal subjects and, even more so, of the hypertensive subjects without heart failure

Thanks are due to Professor F H Smirk for his encouragement, advice, and criticism throughout the preparation of this paper, and to Miss Walsh for clerical assistance

Part of the investigation was aided by a grant from the Dunbar Research Fund of the University of Otago for which I wish to thank the University Council

REFERENCES

Addis, T (1922) *Arch intern Med*, **29**, 539
Alam, G M, and Smirk, F H (1938) *Clin Sci*, **3**, 259
——, —— (1943) *Brit Heart J*, **5**, 152
Ayman, D (1931) *Amer med Ass*, **96**, 2091
—— (1934) *Arch intern Med*, **53**, 792
Hines, E A (1940) *J Amer med Ass*, **115**, 271
Gatman, M, Nassif Amin and Smirk, F H (1943) *Brit Heart J*, **5**, 161
Kylin, E (1921) *Acta med Scand*, **55**, 368
Report of the Combined Committees of the Cardiac Society of Great Britain and Ireland and the American Heart Association (1938) *J Amer med Ass*, **133**, 294
Smirk, F H (1945) *Brit Heart J*, **6**, 176

CARDIOVASCULAR CHANGES FOLLOWING ELECTRO-CONVULSIVE THERAPY

BY

RALPH KAUNTZE AND GERALD PARSONS-SMITH

From St George's Hospital

Received January 7 1948

Electro-convulsive therapy was first used extensively in 1939, and with such success that three years later Kolb and Vogel (1942) in a survey of the United States reported its use in 42 per cent of mental hospitals and in the treatment of 2 3 per cent of all mental hospital patients, this latter group was comprised of the schizophrenias, the manic-depressive states, involutional melancholias, and the psychoneuroses As convulsant treatment is now of established value in the affective neuroses and as electric shock has largely superseded insulin and metrazol as a convulsant, it seemed pertinent to attempt some assessment both clinically and electrocardiographically of its effect on the cardiovascular system These observations consisted of a clinical history (which by the nature of the psychiatric condition was not always complete), a routine examination of the cardiovascular system and electrocardiograms (standard leads only) both before and after the convulsion The second cardiogram was taken in the recovery phase directly after the clonic movements had ceased, in some instances there was slight delay due to uncontrollable spasmodic movements The patients in this series were not specially selected, a quarter were observed during their initial treatments

The convulsant apparatus used was that of Strauss and MacPhail (1946), which by means of a rapidly discharging condenser yields the higher voltages at the start, thereby overcoming the initial resistance, and as only minimal energy is then necessary to induce the fit, the equally rapid damping minimizes subsequent neuronic bombardment The time factor is therefore of less importance and the dosage is reckoned in Joules or total energy rather than in in volts this varies according to weight and general fragility, the usual dosage in this series was 18 Joules diphasic A monophasic discharge yields a quieter recovery but is less certain in inducing a convulsion The electrodes, soaked in 20 per cent saline, are applied to the temples, anterior to and a little above the external auditory meati The duration of the shock is variable, lasting about 0 35 sec , unconsciousness is instantaneous and is succeeded by a tonic phase, thence a clonic phase, which in turn is followed by exhaustion and relaxation or irritability, from which consciousness is recovered in from four to fifteen minutes—a consciousness clouded by disorientation and amnesia Occasionally the shock may produce a " stun " only, the patient remaining conscious Successive " stuns " may induce cardiovascular collapse The average duration of the tonic phase, as observed in 22 patients, was 16 seconds, of the clonic phase 25 seconds The length of the tonic period bore no relationship to that of the clonic Directly after the shock oxygen was administered by mask, and as the tonic phase is short, cyanosis was not observed

Results

Fifty-one patients, of whom 38 were women and 13 men, were observed before and after 63 electroconvulsions The presenting psychiatric symptom in 82 per cent was depression The average findings in pulse rates and blood pressures are set out in Table I In seven instances the pulse rate following the convulsion remained unchanged or was decreased, in the main there was considerable increase

The systolic blood pressure following the convulsion was elevated in about a third, showed no significant change (systolic ± 10 mm , diastolic ± 5 mm) in a third and was actually lowered in the remainder Where an increase occurred, this lay usually between 20 and 35 mm and was accompanied in under a third, by a small fall in the diastolic reading The maximum increase was 55 mm , from 135/70 to 190/95 in a man, aged 27, who displayed marked restlessness and considerable tachycardia However, restlessness with tachycardia was not invariably accompanied by a rise in the blood pressure

TABLE I

PULSE RATE AND BLOOD PRESSURE AFTER ELECTRO-CONVULSIVE THERAPY

Nos	Age		Pulse rates after convulsion				Blood pressure				
							Average				
	Average	Extremes	Increased	Unchanged	Decreased	Av increase per minute	Before	After	Increased	Insignificant change †	Decreased
Women											
38	43 3	24–69	34	3	1	23	150/91	147/87	12	12	14
*											
9	47	24–62	7	1	1	17	145/90	135/81	1	4	4
Men											
13	43 6	26–62	12	—	1	27	129/80	136/75	4	6	3
*											
3	46	27–62	3	—	—	32	145/83	173/98	2	1	—

* = Subsequent records † = Systolic pressure ±10 mm, diastolic ±5 mm

The decrease in blood pressure lay within a similar range the greatest fall was from 185/100 to 120/80 and is probably, in part, a measure of anxiety

Three patients with severe hypertension showed slight elevation of the systolic or diastolic levels or both

None of these patients had curare before the electroplexy and it was not possible to take the blood pressure during the convulsion As the cardiogram was taken first, there was a slight delay between the end of the fit and the recording of the blood pressure, during which it was thought that the readings might have been considerably raised Preliminary observations of patients who have had curare and pentothal show a small initial fall and then following the convulsion there may be no considerable rise in systolic pressure, or where an increase occurs, this may be delayed for a minute or two and has not been excessive (Fig 1) With curare in the usual dosage, there is some movement of the arms in the clonic stage, which makes a blood pressure reading usually impossible In one patient, who had five consecutive shocks in twenty minutes, it was possible to record the blood pressure during one clonic stage (Fig 2) the systolic level was raised 20 mm and remained so for 45 seconds after the convulsion had ceased If sufficient curare is given to abolish all movement of the arms, then the likelihood of anoxia from paralysis of the respiratory muscles may make the blood pressure readings unreliable

Hypertension was the commonest abnormal finding in routine examination, being present in 1 man and 14 women (29 per cent), the upper limit of normality was arbitrarily taken as *155/95* at rest and on repetition It may be suggested that these levels are too low in the circumstances, but the patients were rarely agitated or indeed alarmed at the thought of the approaching convulsion for which there is subsequent amnesia Of these 15 hypertensives, 12 were mild to moderate and 3 were considered severe (above 220/130), one of these latter had commencing right ventricular failure Two patients suffered from bronchial asthma of moderate degree One patient had chronic bronchitis with early right-sided failure and one was a chronic alcoholic In no patient was there history of cardiac pain on exertion or suggestive of a previous infarction

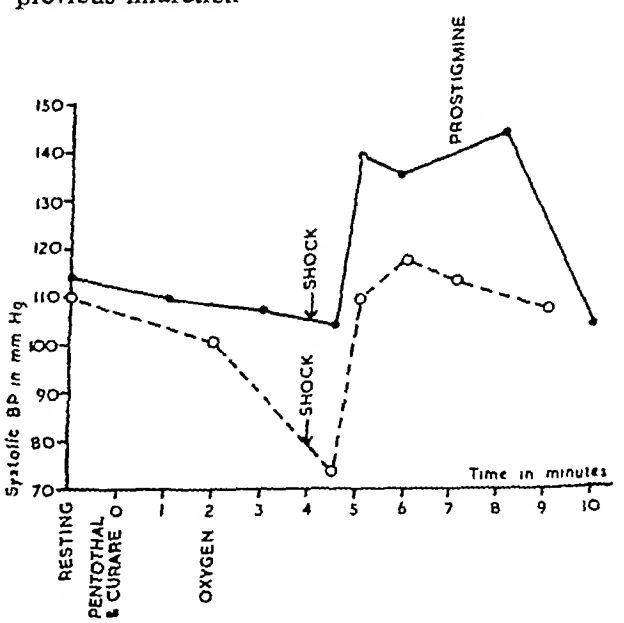

FIG 1 —Systolic blood pressure during two convulsions under pentothal 0 5 g and curare 30 mg in a man aged 45 The second record is in dotted lines

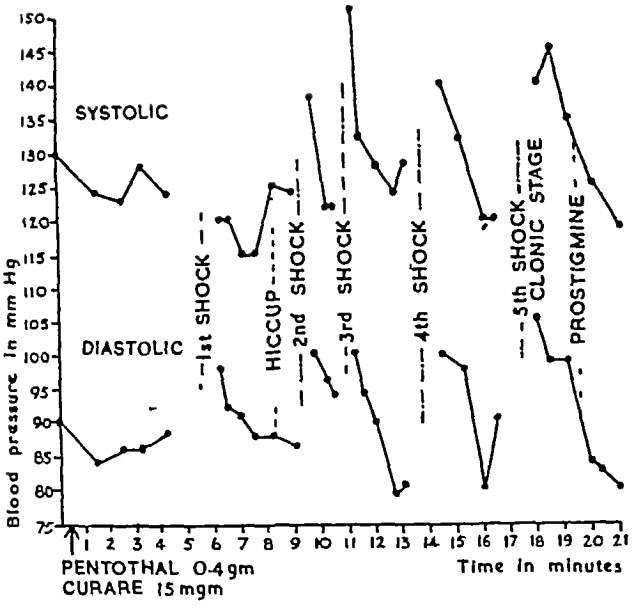

FIG 2 —Blood pressure records in a girl aged 27 during five consecutive convulsions under pentothal 0 4 g and curare 15 mg

Although the motor discharge varied considerably from patient to patient, persistently raised cervical venous pressure following the convulsion was not observed However, Altschule, Sulzbach, and Tillotson (1947) have noted increased venous pressure during the convulsion and slight elevation subsequently, less evident in patients given curare

The cardiographic changes following convulsion are summarized in Table II the main features are increase in the height of the P wave in lead II, prolongation of the P–R interval, increase in the amplitude of the T waves in leads II and III, and less frequently diminution of R I and depression of S–T II (see Fig 3)

An increase in P II was present in 61 per cent of patients, the increment ranging from very slight up to 1 5 mm , this was reflected to a lesser extent in lead III (31 per cent) The P–R interval was lengthened in 52 per cent , this was invariably associated with an elevation of P II, although the converse was not necessarily so No gross prolongation was found, the increase lying between 0 02 and 0 06 sec

R I was diminished in size in 29 per cent, the most marked reduction was —5 mm This diminution was not accompanied by any constant change in the complex, nor was it consistently present on repetition of the cardiogram after subsequent convulsions

Depression of the S–T segments occurred chiefly in lead II, was slight in extent, and present in 29 per cent Elevation of the T waves was noted in lead II in 55 per cent and in lead III in 41 per cent, the

TABLE II

ELECTROCARDIOGRAPHIC CHANGES FOLLOWING ELECTRO-CONVULSIVE THERAPY

Nos	P I	P II	P III	P–R		R I		S–T II	S–T III	T I		T II		T III	
	+	+	+	+	—	+	—	—	—	+	—	+	—	+	—
Women 38	2	22A	10A	22	1	3	14	8	6	0	4	18	4	15	2
In subsequent convulsions 9	1	3	3	3	0	0	5	4	2	1	0	4	1	5	0
Men 13	2	9	6	4	0	4	1	7B	4	1	1	10	0	6	0
In subsequent convulsions 3	0	3	0	1	1	2	0	0	0	0	0	1	1	1	1
Totals Percentage (51 cases)	8%	61%	31%	52%	2%	14%	29%	29%	20%	2%	10%	55%	8%	41%	4%
After standard exercise in healthy young men															
Percentage (6 cases)		50%	33%	0%	33%	—	17%	67%	—	—	—	67%	0%	50%	0%

A = P II and P III were decreased in one patient B = S–T II was elevated in one patient

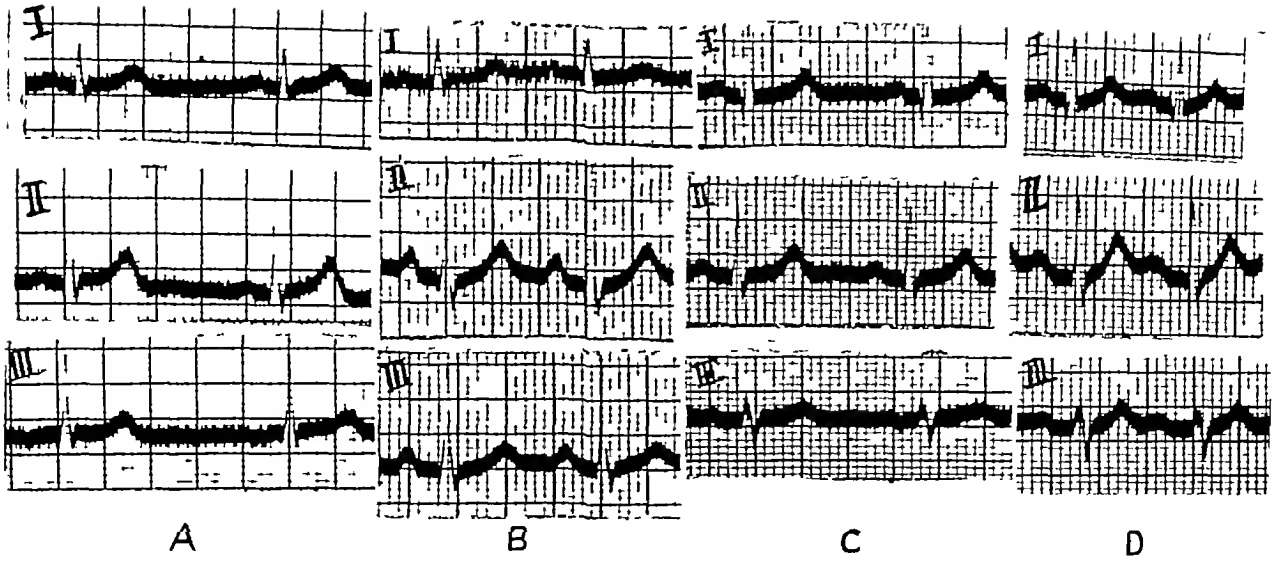

FIG 3 —(A) before, (B) directly after the convulsion showing increase in P II and P III and slight lengthening of the P–R interval (C) before, (D) directly after the convulsion showing increase in T II and T III

increase in height was usually greater in lead II varying between 0 5 and 2 5 mm

Among less frequent changes were increased prominence of S II and S III in 5 patients, intra-ventricular delay in two patients unassociated with prolongation of the P–R interval, 12 patients showed premature beats, in 4 of whom they were observed only after the convulsion, these consisted of auricular, nodal, and ventricular premature beats

Where subsequent cardiograms were taken the pattern had reverted to the original ten minutes later

DISCUSSION

Increased amplitude of P II and T II and slight downward displacement of S–T II together with tachycardia are all encountered in the healthy adult following exercise (Table II), and seem best explained as the result of those processes entailed in muscular activity As to the decrease in size of R I, this with a trend to right axis deviation is also an accompaniment of exercise in a proportion (Wood and Wolferth, 1931), perhaps more frequent in the less fit psychiatric patients P II elevation presumably indicates some degree of right heart strain Some further explanation is necessary for the slight prolongation of the P–R interval, encountered in 52 per cent, as opposed to the shortening frequently accompanying increase in the heart rate, as also for the occurrence of intra-ventricular delay That this slowing of A-V or bundle branch conduction, in the presence of tachycardia, is due to vagal action seems most unlikely

Two patients previously showing some lengthening of the P–R interval following convulsion, were given atropine 1/50 of a grain before a subsequent fit and in both instances the P–R delay was again present (Fig 4) Two further possibilities present themselves, firstly, that the lowered conductivity is caused by anoxia or secondly, is an after-effect of adrenaline Anoxia produces increase in excursion of the P waves, the P–R interval may be lengthened the S–T segment may be depressed and the T waves

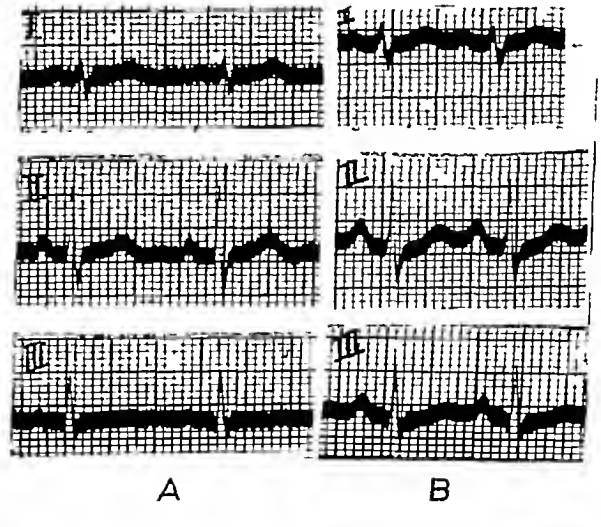

FIG 4 —Atropine gr 1/50, followed 20 minutes later by E C T (A) before, (B) directly after the convulsion showing increase in P II and P III and slight prolongation of the P–R interval

lowered (Graybiel and White, 1946) Although the tonic phase of the convulsion is short and oxygen is administered from the beginning, and although cyanosis has not been remarkable, the possibility of anoxia being a factor in the production of the lowered conductivity of the bundle cannot be excluded Alternatively, adrenaline in the experimental animal (cat) may produce partial heart block and bundle branch block after the preliminary acceleration, this, of course, in hyper-physiological concentrations As electric shock produces a synchronous discharge such as never occurs naturally and as the passage of the current is not far removed from the prefrontal areas, it is conceivable that a very high adrenaline concentration temporarily results Adrenaline may also be the cause of cardiac irritability, shown by ectopic beats, as occurred in a patient with a chromaffin adrenal tumour described by Espersen and Jørgensen (1947) Anoxia, however, seems the more likely factor in producing the P–R prolongation and intraventricular delay

Bellet, Freed, and Dyer (1939) found noteworthy cardiographic changes in two-thirds of 58 insulin shock treatments in 40 patients, namely depression of S–T segments, diminution in the height of the T waves, prolongation of the Q–T interval and various arrhythmias including shifting pace-maker, sino-auricular block, auricular extrasystoles, and auricular fibrillation The auricular fibrillation occurred in two patients and lasted for four and twenty-four hours respectively Similar changes were observed by Hadorn (1937), who in addition found the P–Q interval lengthened in 10 per cent

Nyman and Silfverskiold (1943) stress the similarity of the electrocardiographic findings after electroplexy and those produced by the Valsalva experiment, with the exception of the markedly increased heart rate in the former In a series of 13 patients they found increased amplitude of P II (69 per cent), diminished R I in all patients and increase in T II (69 per cent), with return to normal after a few minutes They postulate that the increase in intrathoracic and intra-abdominal pressure occurring in electric convulsions produces these changes

Kolb and Vogel (1942) state that the deaths resulting from electroconvulsive therapy were 0 5 per 1000 compared with 1 per 1000 for metrazol and 6 per 1000 with insulin Of six fatalities reviewed by Napier (1944) one was ascribed to myocardial degeneration, which was confirmed at autopsy, death occurred half an hour after the convulsion Ebaugh, Barnacle, and Neuberger (1943) describe two deaths following electric convulsions, the first patient, aged 57 years, had anginal pain directly after the thirteenth treatment and died an hour and a half later, the autopsy revealed extensive coronary atheroma and a recent thrombosis A previous electrocardiogram had been reported as normal Their second patient, who had been treated with curare, died of respiratory failure Death has also resulted from massive pulmonary œdema, two days after the second convulsion in a 35-year-old negro, who post-mortem showed meningo-vascular syphilis (Gralnick, 1945)

There was little evidence of cardiac or circulatory embarrassment resulting from electroplexy, nor was an important arrhythmia encountered in our cases, the majority of which, however, had normal or near normal hearts None the less, in one patient with chronic bronchitis and early failure, and in the three patients with severe hypertension nothing untoward occurred The dramatic nature of the treatment may have over-emphasized its potential dangers, although it is obviously undesirable that a patient with a history or cardiographic evidence of coronary disease should be submitted to electro-convulsive therapy, on occasion psychiatric indications may outweigh this consideration Perhaps the risk from electroplexy, off set by curare and the particular avoidance of anoxia, is not so great as at first seemed likely Certainly there is less danger of arrhythmia than from insulin produced convulsions In the presence of valvular disease the possibility of precipitating auricular fibrillation exists but is probably slight

Summary

"Steepwave" electroplexy produces moderate tachycardia and little sustained change in blood pressure With oxygen inhalation there is no obvious cyanosis The degree of increased venous pressure during the fit is difficult to assess, but it has not been persistent clinically

The cardiographic changes in 51 patients observed after 63 convulsions consist of elevation of P II and T II and slight increase in the P–R interval in half, R I was diminished and S–T II slightly lowered in less than a third, S II and S III were more prominent in 10 per cent, 2 patients (4 per cent) showed intraventricular delay, 4 patients (8 per cent) had heterotopic beats after the convulsion only

It is suggested that the changes in P II, T II, R I and S–T II are the result of "muscular activity" and that the delay in auriculo-ventricular and intraventricular conductivity may be the result of anoxia

Patients of middle age or over should have cardiograms before electroplexy is undertaken Although evidence of coronary disease is a strong contra-indication, on occasion psychiatric considerations may be so imperative as to override this

REFERENCES

Altschule, M D, Sulzbach, W M Tillotson, K J (1947) *Arch Neurol Psychiat*, **58**, 193

Bellet, S, Freed, H, Dyer, W W (1939) *Amer J med Sci*, **198**, 533

Ebaugh, F, Barnacle, C, Neuberger, K (1943) *Arch Neurol Psychiat*, **49**, 107

Espersen, T, Jørgensen, J (1947) *Acta med Scand*, **127**, 494

Gralnick, A (1945) *J Nerv Ment Dis*, **102**, 483

Graybiel, A and White, P D (1946) *Electrocardiography in Practice* Philadelphia

Hadorn, W (1937) *Arch Kreislauf*, **2**, 70

Kolb, L, Vogel, V H (1942) *Amer J Psychiat*, **99**, 90

Napier, F J (1944) *J Ment Sci*, **90**, 875

Nyman, E, Silfverskiöld, B P (1943) *Acta med Scand*, **114**, 223

Strauss, E B, and MacPhail, A (1946) *Lancet* **2** 896

Wood, F C, Wolferth, C C (1931) *Arch intern Med*, **47**, 339

ABSTRACTS OF CARDIOLOGY

Thrombosis and Embolism of Pulmonary Vessels with Special Reference to Pulmonary Vein Thrombosis D M SPAIN and J B MOSES *Amer J med Sci*, **212**, 707–712, Dec, 1946

The general incidence of pulmonary emboli or thrombi in a series of 1000 consecutive necropsies (not inclusive of bacterial endocarditis and traumatic cases) was 10 9% The source of emboli in the lungs is approximately twice as frequent from the systemic veins as from thrombi within the heart Pulmonary emboli in patients without heart disease frequently do not cause pulmonary infarcts In 100 consecutive necropsied cases of myocardial infarction, pulmonary emboli were noted 36 times and systemic arterial emboli 25 times The incidence of pulmonary emboli is much greater in association with recent myocardial infarcts than with healed infarcts The pulmonary emboli very often contributed to the death of the patient Pulmonary venous thrombi as a source of systemic arterial emboli occur more frequently than is generally recognized Pulmonary tuberculosis was the disease most often associated with pulmonary venous thrombi Infected emboli resulting from pulmonary thrombophlebitis are exceedingly rare — [Authors' summary]

Fluctuations of the " Δ " Wave in a Case of the Wolff-Parkinson-White Syndrome (Fluctuations de l'onde Δ dans un cas d'invasion ventriculaire précose) R PANNIER *Acta cardiol*, **1**, 37–43, 1946

A case of the Wolff-Parkinson-White syndrome is described An electrocardiogram taken between the attacks of paroxysmal tachycardia showed the changes characteristic of the syndrome—namely (1) The presence of the supplementary " Δ " wave (previously described by Segers, Lequime, and Denolin) in the P–Q interval An apparent shortening of the P–Q interval and broadening of the QRS complex was commonly produced by the merging of this supplementary wave with the QRS complex (2) The S–T segment was displaced in leads I and III These changes were subject to spontaneous fluctuations and could be diminished by deep inspiration by intravenous atropine sulphate (1 mg), or by acetylcholine (20 mg), all of which also modified the P wave Intravenous quinine sulphate (50 mg) abolished all the abnormal changes but did not affect the P wave *B McArdle*

Cardiac Clinics CXVII Electrocardiograms Displaying Short P–R Intervals with Prolonged QRS Complexes An Analysis of Sixty-five Cases F A WILLIUS and H M CARRYER *Proc Mayo Clin*, **21**, 438–444, Nov 13, 1946

The relatively short history of the Wolff-Parkinson-White syndrome is reviewed, and the theory that its mechanism depends upon short-circuiting through accessory conduction pathways between auricle and ventricle is favoured During 1945 this electrocardiographic pattern was seen in 65 cases at the Mayo Clinic There was no evidence of heart disease in 46 (71%) There were 8 cases in the third decade (20 to 29), 17 in the fourth, 22 in the fifth, 12 in the sixth, 4 in the seventh, and 2 in the eighth Paroxysmal tachycardia occurred in 57%, but 3 of these cases proved to have auricular flutter The electrocardiogram simulated left bundle-branch block in 26 instances (40%), right in 4 (6%), and was dissimilar to either form in 35 (54%) One death occurred among those without heart disease, in a woman of 26 who died suddenly during an attack of paroxysmal tachycardia No pathological or experimental evidence bearing on the mechanism of this syndrome is submitted, there is no note concerning the effects of any drug *Paul Wood*

Anastomosis of the Aorta to a Pulmonary Artery Certain Types in Congenital Heart Disease W J POTTS, S SMITH, and S GIBSON *J Amer med Ass*, **132**, 627–631, Nov 16, 1946

Attempts have been made in several American centres to relieve anoxia due to pulmonary stenosis and atresia by effecting some form of shunt between systemic and pulmonary arterial systems Direct anastomosis between the aorta and pulmonary artery had not previously been considered in man since Gross and Hufnagel (*New Eng J Med*, 1945, **233**, 287) and Blalock and Park (*Ann Surg*, 1944, **119**, 445) showed in the experimental animal that the clamping of the aorta long enough to perform anastomosis gave a quite high incidence of paralysis in the hind legs Blalock and Taussig (*J Amer med Ass*, 1945, **128**, 189) avoided aortic occlusion by performing an anastomosis between the subclavian or innominate artery and the pulmonary artery distal to its atretic segment The present authors, desirous of effecting a direct anastomosis between the pulmonary artery and aorta, have devised a special clamp that will occlude only one-half of the aortic lumen and will permit aortic circulation to continue through approximately half of the lumen while the anastomosis is carried out to the lower border Only the lower surface of the aortic arch is occluded by the clamp, and formal lateral anastomosis is performed between the left pulmonary artery and this isolated portion of aorta The operation has been done in 3 children, one of whom did not survive, the child died apparently of post-operative pulmonary congestion The condition of the other two children, aged respectively 21 months and 7 years, was substantially improved, and the arterial oxygen tension was elevated to a pronounced degree

[For full details of the operative procedure the original

article should be consulted since the structure of the clamp is of essential importance in the operative procedure] *Ian Aird*

An Electrocardiographic Study of Psychoneurotic Patients S S WINTON and L WALLACE *Psychosom Med*, 8, 332–337, Sept -Oct, 1946

The authors point out that so far studies of electrocardiographic abnormalities of psychoneurotic patients have been confined to determining whether a specific pattern exists in cardiac neurosis, but that comparisons with large groups of tracings from normal patients have not been made During the war large-scale electrocardiographic surveys were carried out among Service personnel and it was seen that similar abnormalities occurred in these groups The purpose of the authors' investigation of 76 patients under the age of 40 with no organic cardiovascular disorders was to ascertain whether any electrocardiographic characteristics of psychosis or neurosis existed. The chief complaints of the patients were referable to the cardiovascular system, and the most common were palpitation, a præcordial sensation of constriction not necessarily related to effort, dizziness, vertigo, and dyspnœa with excitement or effort In 4 of the 76 cases the curve was abnormal, in 2 it was probably abnormal, and in 8 cases it was borderline In the remainder the curves were normal There was no combination of abnormalities that fitted into any distinct pattern characterizing psychoneurotics, but about 12% presented a right heart strain pattern as suggested by tall P waves, right axis shift, and S–T depression in the limb leads Flat or inverted T waves in leads I and II occurred about 15 times as frequently in this series as in a large group of young healthy aviators *S Oram*

The Technique of Creation of an Artificial Ductus Arteriosus in the Treatment of Pulmonic Stenosis A BLALOCK *J thorac Surg*, 16, 244–257, June, 1947

This is a technical account of the author's now classical operation (first reported in 1945) performed at Johns Hopkins Hospital, Baltimore, for the relief of congenital pulmonary stenosis, such as occurs in "blue babies" and is characterized by the tetralogy of Fallot—pulmonary stenosis, an over-riding aorta, ventricular septal defect, and right ventricular hypertrophy The patients' ages ranged from 2 months to 26 years, but the optimum time for operation is between 3 and 7 years

The chest is opened on the side opposite to that on which the aorta descends (38 of 144 patients had a right-sided aorta, and were therefore operated upon from the left), so as to gain access to the innominate artery and its branches The subclavian artery is then freed up to its first large branch, divided between clamps, and turned down so that its cut end can be anastomosed to the side of the similarly cleared pulmonary artery, which is temporarily clamped This permits an extensive shunt of inadequately oxygenated systemic blood through the pulmonary circulation, with corresponding relief of anoxic symptoms

Though the author regards the above procedure as the best, frequent anomalies, both of the systemic and of the pulmonary vessels, are encountered and may necessitate the use of the innominate or carotid artery instead of the subclavian, and of an end-to-end rather than end-to-side anastomosis Total absence of the left pulmonary artery has been met, but it is emphasized that one systemic trunk or another is always available The anastomosis is made with No 00000 silk, in a single layer everting the intima, and interrupted in several places to avoid constriction of the lumen The special clamps used for the temporary occlusion of the pulmonary artery are described

The mortality rate among the 144 patients discussed was 22%, and all the survivors were improved Since this publication the author has operated on a total of 450 children *Geoffrey Flavell*

Clinical Features of Patent Ductus Arteriosus with Special Reference to Cardiac Murmurs S A LEVINE and A E GEREMIA *Amer J med Sci*, 213, 385–394, April, 1947

The accurate diagnosis of the exact anatomical lesion in congenital cardiac disease has only become of practical importance during the last few years because of the use of specific surgical treatment The authors analyse 37 cases of patent ductus arteriosus, in which the diagnosis was confirmed at operation The murmur, having both systolic and diastolic components, varies considerably in loudness from case to case It is generally loudest in the second, but occasionally in the first or third left interspace It may be transmitted to the back of the chest A thrill was present in over half the cases The pulse pressure decreased from an average of 65 mm, before operation to 45 mm after operation There was no typical electrocardiographic pattern Right axis deviation does not occur Rare cases exist in which no murmurs, or at least no diastolic murmurs, are audible, a possible explanation of this is that the pressure in the pulmonary artery is as great as that in the aorta and therefore no flow takes place through the ductus The persistence of a basal diastolic murmur after operation was found to be due either to the recanalization of the ductus or to bacterial endocarditis which had also involved the aortic valve In puzzling or atypical cases cardiac catheterization is necessary to establish an accurate diagnosis *Geoffrey McComas*

INTERNATIONAL CONFERENCE OF PHYSICIANS

President The Lord Moran, M C, M D, P R C P

SECTION OF CARDIOLOGY

President Sir Maurice Cassidy, K C V O, C B, M D, F R C P

The INTERNATIONAL CONFERENCE OF PHYSICIANS was held in London from September 8 to September 12 The five sessions of the section of Cardiology were attended by four or five hundred physicians among whom were welcomed many distinguished visitors from overseas Two of the sessions were joint meetings with the section of Pædiatrics and the section of Disorders of the Chest, respectively

THE SURGERY OF CONGENITAL HEART DISEASE

September 9, 1947 Joint Meeting with Section of Pædiatrics

MALFORMATIONS OF THE HEART AMENABLE TO THE BLALOCK-TAUSSIG OPERATION

BY HELEN B TAUSSIG,* Baltimore, Maryland

There are three types of malformation of the heart that cause persistent cyanosis In the first group there is lack of adequate pulmonary blood flow, as for example in pulmonary stenosis and pulmonary atresia In the second group there is difficulty in the direction of oxygenated blood to the systemic circulation, as in complete transposition of the great vessels In the third group there is failure of the blood to be fully oxygenated in its passage through the lungs, as in the Eisenmenger complex It is only the first of these three groups that is amenable to the Blalock-Taussig operation, and hence only this group is discussed in this paper

The operation developed by Dr Alfred Blalock is designed to increase the circulation to the lungs This is accomplished by the anastomosis of the proximal end of one of the systemic arteries to the side, or distal end, of the right or left pulmonary artery In order that the blood should flow from a systemic artery to a pulmonary artery the pressure in the systemic circulation must be higher than that in the pulmonary circulation This is true in all cases of pulmonary stenosis or atresia In such malformations a Blalock-Taussig operation virtually restores the condition to that existing before the closure of the ductus arteriosus When there is pulmonary atresia, only rarely does the collateral circulation develop with sufficient rapidity to enable the infant to survive the closure of the ductus arteriosus Consequently, in such instances, if operation is to be life-saving, it must usually be performed before the ductus arteriosus undergoes obliteration When, however, there is pulmonary stenosis, operation can usually be postponed until childhood

The diagnosis of pulmonary stenosis or atresia is based upon the history, combined with certain clinical and radiological findings The history of the development of cyanosis at an early age is a characteristic of this malformation The position which the child assumes when tired is a diagnostic aid because most children who suffer from a reduction in pulmonary blood flow squat when tired

The outstanding findings on physical examination are persistent cyanosis combined with a heart that is little, if at all, enlarged, a basal systolic murmur and a clear second sound The electrocardiogram shows a right axis deviation X-ray of the heart shows an absence of the normal pulmonary conus and upon fluoroscopy there is absence of pulsations of the hilar shadows

The degree of cyanosis is subject to great variation Most children are intensely cyanotic There are, however, a few with a tetralogy of Fallot but with lips

* From the Department of Pædiatrics of the Johns Hopkins University and the Cardiac Clinic of the Harriet Lane Home of the Johns Hopkins Hospital

of normal colour and only slight cyanosis of the fingernails, who are extremely incapacitated Upon exercise such children usually suffer from a marked fall in the oxygen saturation of the arterial blood

The cardiac findings are also variable A basal systolic murmur and a clear second sound are the rule However, with extreme pulmonary stenosis there may be no murmur Usually diastole is clear

The exact diagnosis of the anatomical abnormality is not as important as it is to have the malformation amenable to surgery The essential criteria for successful operation are (1) the lack of adequate circulation to the lungs, (2) the availability of a systemic artery, (3) the existence of a pulmonary artery, (4) a pressure greater in the systemic than in the pulmonary artery, (5) the structure of the lungs such that the patient can survive the collapse of one lung and the occlusion of one pulmonary artery, and (6) a heart of such size and structure that it can adjust to the altered circulation *

Although the existence of a pulmonary artery and of low pulmonary pressure are essential for successful operation, these facts are not always easy to determine prior to operation

Fluoroscopy is of prime importance both for the visualization of the pulmonary artery and for determining the presence or absence of hilar pulsations In infants who suffer from lack of adequate pulmonary blood flow, the lungs are usually exceptionally clear In adults with a large pulmonary artery and high pulmonary pressure, the visualization of hilar pulsations when present is usually not difficult In children, however, the vessels are smaller and the pulsations are correspondingly more difficult to see In the rare instances of complete transposition of the great vessels, the pulmonary artery lies posterior to the aorta and there is a considerable amount of lung tissue overlying the pulmonary artery Under such circumstances the pulsations in the pulmonary artery are difficult, if not impossible, to demonstrate

Furthermore, the hilar shadows increase as the collateral circulation develops through the posterior mediastinal vessels These shadows are caused by an aggregation of small vessels and when the observer's eyes are fully dilated appear as an aggregation of minute shadows, which never show expansile pulsations Absence of hilar pulsations is a pre-requisite for the operation, as their presence is a strong indication of adequate or excessive pulmonary blood flow and is usually indicative of high pulmonary pressure Nevertheless, in the absence of hilar pulsations, the existence of a pulmonary artery cannot be determined with certainty prior to operation

The occurrence of a continuous murmur calls for careful consideration Such a murmur may be caused by the persistent patency of the ductus arteriosus or by the flow of blood through large vessels of the collateral circulation The differentiation is important because in the former condition there is certainly a pulmonary artery and therefore operation is possible, whereas in the latter there may be no pulmonary artery in which case operation will be impossible

As regards the size and structure of the heart, great cardiac enlargement is a contraindication for operation because should the operation cause further enlargement the patient would be unable to maintain compensation

An over-riding aorta or some pathway for the direction of venous blood into the systemic circulation is essential because it is the direction of venous blood to the lungs that is of benefit to the patient Indeed, the fundamental difference between the artificial ductus arteriosus in a tetralogy of Fallot and an uncomplicated ductus arteriosus or an arteriovenous aneurysm is that in the former the dextroposed aorta permits the direction of mixed venous blood to the lungs, whereas in the latter conditions only fully oxygenated blood is redirected to the lungs In a patient with a tetralogy of Fallot, although operation may lead to a marked rise in the oxygen saturation of the arterial blood, the oxygen content of the arterial blood never reaches normal because of the over-riding of the aorta The saturation of the arterial blood remains between 75 and 85 per cent, and upon exercise it drops to 70 per cent or less Consequently the blood directed through the artificial pathway to the lungs is essentially that normally directed through the pulmonary artery to the lungs

The simplest method for the demonstration of the dextroposition of the aorta is by the determination of the circulation time A short circulation time, arm to tongue, of less than 10 seconds is strong presumptive evidence that venous blood is being pumped directly into the systemic circulation In doubtful cases, angiocardiography may be necessary to determine the time at which the aorta is visualized

Cardiac arrythmias are dangerous Partial heart block of such a nature that the heart slows with exercise is especially dangerous, because at the end of the operation the heart normally accelerates to adjust to the increased pulmonary blood flow Slowing of the heart rate at this time is liable to lead to acute cardiac dilatation and standstill

* These criteria were discussed in detail in the Brown Memorial Lecture given by the author in Atlantic City, June 1947, entitled "An Analysis of Malformations of the Heart Amenable to a Blalock-Taussig Operation," to be published in the *American Heart Journal*

Rotation of the heart upon its axis calls for careful investigation, as this condition is frequently associated with a complicated malformation

The over-all mortality rate of the first 350 patients* submitted to a Blalock-Taussig operation is shown in Table I Although not shown in this table, the mortality rate in infants and in adults has been considerably higher than in children The mortality rate in infants has been approximately 30 per cent and that in children approximately 10 per cent and in adults approximately 18 per cent The 16 instances in which only exploratory operation was performed include patients in whom no pulmonary artery was found, patients in whom the pulmonary pressure was abnormally high, and patients in whom the heart action was so poor that Dr Blalock was forced to close the chest even though the condition appeared to be amenable to surgery The eight cases (or 2 5 per cent) in which there was no improvement indicate how seldom a thrombosis occurred at the site of the anastomosis

TABLE I

RESULTS OF THE FIRST 350 BLALOCK-TAUSSIG OPERATIONS

	Total No of Cases	Percentage
Deaths	60	17 0
Exploratory	16	4 5
Unimproved	8	2 5
Slight improvement	18	5 0
Excellent	248	71 0

The amount of the benefit derived from operation depends upon the size of vessel used for the anastomosis, the extent of the over-riding of the aorta, and the existence of other malformations in addition to a tetralogy of Fallot The beneficial effects of operation are measured by the changes in the blood, by the changes in the heart size, and by the increase in the exercise tolerance of the individual. The oxygen saturation of the arterial blood rises to between 75 and 90 per cent and the red blood cell count, the hemoglobin level, and the hematocrit reading return to normal values

The changes in the oxygen saturation of the arterial blood in four typical cases are shown in Table II The first column gives the pre-operative values, the second column shows the rise in the oxygen saturation approximately three weeks after operation, the subsequent columns give the values at six months, one year, and two years after operation In Case 2 it will be noted that the oxygen saturation after two years had fallen Table III gives the red blood cell counts and the hematocrit values on the corresponding patients at the corresponding times In these tables it is seen that in Case 2 the fall in the oxygen saturation was not accompanied by a rise in the red blood cell count or in the hemoglobin level, therefore the lower oxygen saturation of the arterial blood was probably due to the fact that the child was crying (not in a basal state) when the sample was taken As shown in these tables, in most instances after operation the oxygen saturation of the arterial blood rises to between 75 and 85 per cent and the red blood cell count, the level of the available hemoglobin and the hematocrit reading return to normal values

TABLE II

THE PERCENTAGE OF OXYGEN SATURATION OF THE ARTERIAL BLOOD BEFORE AND AFTER A BLALOCK-TAUSSIG OPERATION

	Name	Before oper	After operation			
			Immed	6 mo	1 yr	2 yr
1	R S	78 0	85 0	86 9	88 4	88 4
2	J S	65 8	79 5	84 0	83 0	68 0
3	H C	65 9	81 4	82 0	—	83·0
4	M C	20 6	47 9	58 9	59 0	64 0

TABLE III

RED BLOOD CELL COUNT IN MILLIONS AND HEMATOCRIT READING IN FOUR CASES OF A TETRALOGY OF FALLOT BEFORE AND AFTER A BLALOCK-TAUSSIG OPERATION

	Name	Before oper	After operation			
			Immed.	6 mo	1 yr	2 yr
		Red cell count				
1	R S	6 4	5 5	5 5	5 5	5 5
2	J S	9 0	6 9	5 3	5 0	4 8
3	H C	10 5	6 6	5 5	—	5 5
4	M C	5 7	5 2	6 3	6 3	6 4
		Hematocrit				
1	R S	59	48	42	46	47
2	J S	71	56	44	47	41
3	H C	86	57	48	—	47
4	M C	48	43	48	47	53

Case 4 is from the record of an infant, and as so frequently happens in spite of extreme anoxæmia, he did not have polycythemia In this instance the oxygen saturation of the arterial blood has risen steadily but has not yet reached the optimum level,

* Since the paper was read, Dr Blalock and his assistants have operated on more than 250 additional patients with an operative mortality rate of less than 10 per cent

and the red blood cell count and the hematocrit value have also risen It is to be hoped that when the oxygen saturation of the arterial blood reaches 75 per cent, the red blood cell count and hematocrit reading will again decline

In every instance the above changes are accompanied by a dramatic change in the patient's physical condition The lips are usually of normal colour and although the fingernails may show a tinge of cyanosis, the clubbing slowly recedes, furthermore the patient's exercise tolerance is greatly improved

The ability of the heart to adjust to the operation is shown by the after course The degree of cardiac enlargement has varied from patient to patient, and by and large it has varied with the size of the vessel anastomosed to the pulmonary artery In most instances, however, the heart has been able to adjust to the load and to maintain compensation Indeed, only 3 of the first 220 patients, operated on for pulmonary stenosis or atresia and discharged improved, have subsequently died of cardiac failure Two of these three were known not to have a tetralogy of Fallot because they both showed electrocardiographic evidence of a left axis deviation Two other patients have developed cardiac failure and, in addition, two children have shown radiological evidence of progressive cardiac enlargement That progressive cardiac enlargement and cardiac failure are the exception, not the rule, is shown by the fact that approximately 30 per cent of the patients have shown no change in the size of the heart following operation, 30 per cent have shown an increase in size during the first three weeks after operation and thereafter have shown no further increase in heart size, and approximately 30 per cent have shown an increase in heart size between the time of discharge and their return for the six months checkup and thereafter have shown no further cardiac enlargement

All patients are permitted full activity at the end of the third month after operation The extent of the improvement in the exercise tolerance has been tremendous We expect any child with a pulmonary stenosis or atresia to walk more than a mile after a successful operation Many a child three months after has walked six miles, and more than one twelve-year old boy who estimated his exercise tolerance before operation as three or four city blocks has been on a 10-mile hike within the first six months after operation

Surgical Treatment of Pulmonic Stenosis

By Alfred Blalock, Baltimore, Maryland

I wish to thank the members of the Section of Cardiology for the privilege of participating in this symposium

Six years ago Dr Edwards A Park and I carried out experiments in an attempt to devise a treatment for coarctation of the aorta The thoracic aorta of the experimental animal was cut across, the two ends were closed and the subclavian artery was used to by-pass the point of occlusion Before this method was used in the treatment of coarctation in man, a better method was developed by Dr Crafoord of Stockholm his operation is the preferred procedure but there are some instances in which it is necessary to employ the method which Dr Park and I described

In discussing the experimental work on coarctation with Dr Helen Taussig, she suggested that I try to find a method for increasing the blood flow to the lungs in cyanotic patients with pulmonic stenosis As you know, the most common abnormality of this type is the tetralogy of Fallot This problem was investigated in the experimental laboratory and I found that the cyanosis produced by an operative procedure which I shall not go into at this time could be partially alleviated by the creation of an artificial ductus After the experimental work was completed, the problem was returned to the clinic and work on patients was begun

As Dr Taussig has said, the major difficulty in the tetralogy of Fallot is the pulmonic stenosis Fortunately the stenosis is usually limited to a single point (pulmonary conus region), and the pulmonary artery distal to this point is usually a fair sized vessel Since this is true, the pulmonary artery in most cases is suitable for anastomotic purposes

I would like to review for a moment the anatomy of this region As you know, the arch of the aorta usually gives rise to the innominate artery, the left carotid artery, and the left subclavian artery When the aortic arch descends to the left, which is usually the case, the innominate arises on the right side When the aortic arch descends to the right, which is observed in one-fourth of our cyanotic patients, the innominate arises on the left I prefer to use the subclavian branch of the innominate for the anastomosis, and hence the position of the aorta should be determined pre-operatively This can be done with great accuracy by the use of the method of Bedford and Parkinson of London The incision is usually made on the side opposite that on which the aorta descends The operative procedure consists of anastomosing a branch of the

aorta or the aorta itself (as recommended recently by Potts) to one of the two pulmonary arteries As you know, the pressure in the pulmonary artery is low, the pressure in the aorta and its branches is high, and a large quantity of blood will flow from the systemic to the pulmonary circuit after such an anastomosis is made The incision is made with the patient lying on his back but with the side to be operated upon at a slightly higher level This leaves the opposite lung in good condition for carrying out respiratory functions during the operative procedure After the pleural cavity has been entered, the azygos vein is doubly ligated and divided The pulmonary artery is then exposed and it is dissected free of the surrounding tissues The innominate with its branches is then exposed and in the usual operation the subclavian branch of the innominate is ligated distally It is occluded proximally with a bulldog clamp and is cut across proximal to the ligature The pulmonary artery is then occluded proximally with a special rubber-shod instrument and distally with a bulldog clamp, and a transverse opening is made on its upper surface between the two points of occlusion Using fine non-absorbable suture material an anastomosis is then made between the end of the subclavian and the side of the pulmonary artery The subclavian branch of the innominate makes a good angle with its parent vessel and stenosis at the point of origin is not nearly so apt to occur as when the subclavian artery that arises directly from the aorta is used

As stated previously, the end-to-side type of anastomosis is preferred In some instances, however, it is necessary to do an end-to-end anastomosis after having ligated and divided one of the pulmonary arteries One of the advantages of the end-to-side anastomosis is that it allows the shunted blood to go to both lungs

The motion picture, a portion of which I will show now, illustrates the operation on a five-year-old boy who had a moderate degree of cyanosis His disability was fairly marked The anæsthetic agent in this case was cyclopropane with a high concentration of oxygen The exposure of the right pulmonary artery is shown The pressure in the artery was measured by the use of a needle and a manometer In this patient the pressure was about 200 mm of water (15 mm Hg) which is about the average pressure that we have obtained in our cases If the pressure is higher than 375 mm of water, we hesitate to carry out the procedure

You will note in the picture that there is no difficulty in this case in approximating the subclavian artery to the pulmonary artery Difficulty is encountered in some of the older, larger patients in approximating these vessels In some of these the incision is made on the opposite side and the subclavian branch of the aorta is used You will note that the transverse opening in the upper surface of the pulmonary artery is slightly larger than the end of the subclavian artery You will note also that the suture everts the intima of the vessels

I now show you a picture of this boy 18 days after the operation You will observe that his cyanosis is much lessened It takes a longer period of time for the characteristic clubbing of the fingers to disappear More important, however, is the lessening or the disappearance of the disability Thus far some of the patients seem to be able to lead normal lives

A few comments might be of interest regarding the various vascular anomalies we have found In the first 475 patients there were 121 in whom the aortic arch was on the right and in the majority of these there was an obliterated ductus which joined the subclavian branch of the innominate In at least 14 of these patients there was an anomaly in the position of the superior or inferior vena cava or both, the number is probably considerably in excess of this In at least 5 the superior pulmonary vein entered the superior vena cava In 15 patients or more there was rotation of the heart to the right Various other arterial and venous anomalies were encountered

The mortality rate has been high but not discouragingly so When the last analysis was made, it was found that 474 patients who were thought pre-operatively to have the tetralogy of Fallot or one of its variations had been operated upon An end-to-side anastomosis between the subclavian artery and the pulmonary artery was performed in 331 of these and among these there were 37 deaths, or 11 per cent. Among the patients who succumbed in this group there were three with transposition of the aorta and the pulmonary artery and one with truncus arteriosus Several of the deaths occurred a number of months following the operation

An end-to-end anastomosis between a branch of the aorta and the divided distal end of one of the pulmonary arteries was performed in 23 cases with 4 deaths An end-to-side anastomosis between one of the carotid arteries and a pulmonary artery was performed in 30 cases with 9 deaths An end-to-side anastomosis between the innominate artery and a pulmonary artery was carried out in 47 cases with 13 deaths A side-to-side anastomosis between the aorta and one of the pulmonary arteries was performed in 2 cases with 1 death In 37 of the total number of cases only an exploratory thoracotomy was performed, in most of these a pulmonary artery was not present or at least could not be found Among these patients who

had an exploratory thoracotomy without an anastomosis there were 18 deaths In the entire total of 474 cases there were 86 deaths, a mortality of 18 per cent This includes all patients who have died, whether in hospital or after leaving hospital, and whether or not an anastomosis was performed

There has been no serious disturbance of the circulation of the arm, the subclavian of which was ligated, in any of the patients and the function of the arm is excellent There have been approximately 400 such patients in whom the subclavian artery was ligated and divided

The age of patients operated upon has varied from two months to 44 years We consider the ideal age for operation to be from three to nine years All of the patients received penicillin There have been no instances of empyema or pericarditis Heparin and dicumarol have been used very rarely

In conclusion I would like to say that it is too early to evaluate the ultimate effects of this operative procedure since it has been less than three years since the first such operation was performed We can state that the results thus far are quite encouraging.

By J W Brown, Grimsby

Ample justification for operation is found in the relatively bad prognosis of cyanotic congenital heart disease Observation of over 100 cases has shown that many die before the age of three, and about a quarter of the cases survive the school age Most of the children can be educated if given the opportunity and they should always be taught to read and write Between 60 and 70 per cent of the cases fall into the group of the tetralogy of Fallot where pulmonary stenosis is combined with a large interventricular septal defect, an over-riding dextro posed aorta, and right ventricular hypertrophy

Cyanosis is present and depends upon the oxygen unsaturation of the blood and the polycythæmia, which in their turn are dependent upon the degree of pulmonary stenosis and upon the amount of the pulmonary blood supply Cyanosis may vary from day to day and definitely with the season The factor of the over-riding aorta cannot be of enormous importance when the figures of oxygen saturation after operation are considered, but it is of importance in relation to paradoxical embolism and cerebral abscess In this series thrombotic incidents due to polycythæmia have not been frequent Commonly there is a basal systolic murmur and a clear second sound Absence of a murmur does not invalidate diagnosis of the tetralogy

Diagnosis is essentially radiological, and the picture of a small pulmonary artery with a concave pulmonary arc and absence of pulmonary congestion and of hilar pulsation are convincing A right aortic arch is frequently present, and a cœur-en-sabot may be seen in the older children The electrocardiogram shows a right axis, but abnormalities of the ventricular complexes and conduction defects do not appear to be so common as in auricular septal defect

There are other conditions that may be confused with the tetralogy Tricuspid atresia is distinguished by the presence of a left axis in the electrocardiogram, a pathognomonic finding in a cyanotic case Transposition of the great vessels usually causes gross cardiac enlargement over a short period of time, and survival is generally short There is a narrow vascular pedicle which broadens in the oblique view, for then the aorta comes directly in front of the pulmonary artery

The evil prognostic signs are a rising red cell count, a high hematocrit reading, syncopal attacks, and thrombosis Many of the cases exist rather than live in the fullest sense

The point before us is that operation is not a cure, but a physiological adjustment that allows a greater circulation to the lungs through an artificially created ductus arteriosus The subject still remains liable to the inherent risks of the patent ductus, and the mixed blood in his aorta is little different from venous blood The immediate results of operation are so beneficial to the patient that we must critically study every case of cyanotic heart disease so that those types of abnormality likely to be helped by operation may be recognized Where clinical and ordinary laboratory investigation fails to make a satisfactory diagnosis, some help may be had by intracardiac catheterization and by angiocardiography

Of the operation, one is entitled to ask at this stage whether the calibre of the anastomosis created in infancy will increase pari passu with the growth of the child There might well be the risk of contraction and ultimate obliteration at the suture line in the same way as the small ventricular septal defect of the maladie de Roger may spontaneously close by contraction of its fibrous margins We know too that in the cyanotic case a patent ductus fulfilling an obviously physiological purpose in shunting blood between two pressure systems may quite suddenly close and bring about the death of the patient, showing that the mere fact of a shunt does not necessarily keep open an abnormal com-

munication The Potts operation of direct anastomosis between aorta and pulmonary artery may have something to offer in allowing the surgeon to determine the size of orifice that he may make

If prognosis is to be the basis on which surgical treatment of congenital heart disease is to be founded, the time has come when this problem should be seriously and collectively examined Our present ideas are based upon statistics that contain many neonatal cases Statistics depend upon the interest shown by clinicians and pathologists, and naturally the highest incidence of congenital heart disease is in children's hospitals, rather than the general hospital Only the interesting case is reported, and no account is taken of the living because we tend to publish only the case with post-mortem control As an example where is the adult with patent ductus arteriosus? We certainly do not see him in our clinics He has not been cured in childhood by the surgeon as yet Do we fail to recognize him when he is in failure, or when he has infective endocarditis? He is not seen by the pathologist who perhaps practises section of the great vessels within the pericardium Does the ductus after all close spontaneously in adolescence or early adult life?

Coarctation of the Aorta

By C Crafoord, Stockholm

First of all I want to say that I feel it as a great honour that I have been invited to read this paper We have heard an excellent review by Dr Taussig and Dr Blalock of the work they have done on the treatment of the blue babies There are, however, two more congenital heart malformations that have been more closely studied than ever before because experience has shown that by surgery these two can be completely cured—patent ductus and coarctation of the aorta I am going to deal with coarctation, which has been thoroughly studied in my hospital where the first operations for this disease were performed, and to give you only a résume of my results in patent ductus as this is going to be covered by the following speakers

Coarctation of the aorta was first described by Morgagni in 1760 Wadstein in 1897 collected 103 reported cases Maud Abbott (1931) described among 1000 cases with congenital cardiovascular defects 142 cases of coarctation, which indicates that about 15 per cent of all congenital lesions in this group are coarctation

The incidence of the adult form of this malformation is about 1 per 1500–2000 when estimated from large post-mortem series The juvenile form has no surgical interest as these cases die very early The adult form is usually confined to the area of the ductus arteriosus From the United States Pearlman, when examining men between 18 to 35 years of age for army service found only 1 in about 10,000 This discrepancy depends on the fact that by rapid clinical examination quite a number of coarctation cases are never detected Both clinical and post-mortem findings show that the incidence of this congenital lesion is much more common than was previously believed and more common among men than among women Maud Abbott gives this proportion as 3 to 1 Among my 22 resected cases 7 were females

Other developmental disturbances may be combined with this form of coarctation the bifid aortic cusp, estimated by Abbott to occur in 25 per cent of the cases, secondly hypoplasia of the aortic wall, according to Abbott in 10 per cent of cases, this is naturally of surgical importance and must always be borne in mind as a pronounced hypoplasia makes a resection and suture impossible to perform, thirdly patency of the ductus arteriosus, and finally there is a small group of cases in which the points of origin of the great vessels leaving the aorta are abnormally situated, the coarctation itself may be of considerable length, and defects of the ventricular or atrial septum may be present Some of these are of importance in diagnosis because their existence may influence the decision to operate or not

Early atherosclerosis in arteries proximal to the narrowed segment seems to be very common The oldest patient I have resected was 27 years of age and some have been around 20 in these cases we could find very slight or no atherosclerotic changes

The prognosis regarding length of life is of special interest Ask Upmark (1942) found that about 25 per cent of all cases died before they reached 20, 50 per cent before 40, and 90 per cent before 50 years of age The commonest causes of death according to Abbott are in order of frequency congestive heart failure, rupture of the aorta or the heart, cerebral hæmorrhage, and bacterial endocarditis

All my coarctation cases have been studied in the heart clinic of Prof Nylin before operation, a collaboration that I consider to be of greatest importance Coarctation seems always to be accompanied by increased blood pressure above the level of the coarctation, and decreased pressure below It is not known how early in infancy these changes in the blood pressure are present In

a 3-year-old child reported by Bodlander (1946) the blood pressure was 130/60 which is to be considered as hypertension at this age, erosion of the ribs was seen in the radiographs

We are of the opinion that a higher blood pressure in the legs than in the arms practically excludes coarctation In our material the blood pressure has been high in the arms and low in the legs in all patients In the two youngest, both children of 11 years of age, we found systolic blood pressures ranging in the arms in one between 150 and 190, and in the other between 140 and 150 mm

If hypertension is present, the possibility of coarctation should always be borne in mind The subjective symptoms resulting from the hypertension in the upper part of the body vary and may include general weakness, palpitation, vertigo, throbbing headache, and a feeling of heaviness in the head, and visual troubles

The low blood pressure in the lower half of the body, which never occurs in hypertension from other causes, not infrequently produces vague or even quite pronounced symptoms suggestive of intermittent claudication, but may cause no symptoms at all

The majority of patients seek medical advice because of one or more of the above symptoms The clinical findings on examination are mainly as follows

1 By inspection and palpation abnormal pulsation is found, both in collaterals (most often in the axillæ, the supraspinous fossæ, and close to the lower borders of one or more ribs), and also in dilated arteries in the neck and head, central to the stenosis, and finally absence of pulsations in the arteries in the legs

2 By percussion and auscultation one finds hypertrophy of the heart mainly on the left and a harsh systolic murmur over the base of the heart also at the back especially in the interscapular area to the left Probably the murmur originates from collaterals and not from the stenosed part of the aorta In one case of mine, in which the stenosis was complete, this systolic murmur was present before operation and vanished afterwards, which shows that the murmur could not have been due to the stenosis itself A systolic murmur over large collaterals can also be heard and recorded phonocardiographically

3 *Oscillographic findings* This examination has been used with special interest in our hospital and has been carried out with a new apparatus designed by Dr Ejrup in the heart clinic of Prof Nylin The recordings can be callibrated and are thus directly comparable at different examinations The auscultatory method is adequate in studying blood pressure changes in the arms, but in the legs it is often difficult to hear the sounds when auscultating in the popliteal fossæ The oscillogram gives a clear and visible record of the blood pressure and pulsations in the legs even in coarctation cases, and is of great interest because, as shown by Ejrup in 1945 and 1946, there is a special reaction to exercise If in a normal case an oscillogram is taken on the upper or the lower limbs after exercise, the blood pressure is higher and the pulsations are greater than in the oscillograms taken during the rest

In organic obstruction of the arteries and in coarctation an " inverse reaction " with a diminished blood pressure and a decrease of pulsations appears after exercise This reaction has been found in patients with thrombo-angiitis obliterans, severe arteriosclerosis, and arterial embolism It is not influenced by the presence or absence of intermittent claudication In obstruction of the arteries of the lower extremities intermittent claudication will sooner or later develop if the exercise is great enough, but the abnormality is shown by oscillography long before clinical symptoms appear

In coarctation cases at rest the oscillographic tracings show big pulsations and an elevated blood pressure in the arms and small pulsations and low blood pressure in the legs After work test the tracings show further increase of the pulsations and the blood pressure in the arms but in the legs a paradoxical or pathological reaction is demonstrated by either a decrease of the blood pressure and the pulsations or absence of increase in blood pressure compared with the tracings at rest

4 *X-ray examination* We have found (A) and (B) constant findings, (C), (D), and (E) inconstant findings

(A) Widening of the left subclavian artery which shows up as an S-curved outline to the left of the superior mediastinum, an impression on the œsophagus, and an indentation to the left in the posterior mediastinum

(B) Dislocation and shortness of the aortic arch with absence of the aortic knuckle

These constant findings are easy to understand A frontal section from a frozen body in the post-mortem room makes it easy to understand that a dilatation of this left subclavian artery will produce a convex shadow against air-containing lung and an impression on the œsophagus

The indentation we believe is most often formed between the entrance of the subclavian artery in the aorta and the aortic wall above the coarctation, and not due to the constricted area itself The dense fibrous tissue which can be dissected when the aorta is freed at operation often gives by itself such a shadow that the actual coarctation is difficult to

see as an indentation in the X-ray film I have, however, a picture that shows two different indentations one cranial formed by the subclavian artery and the aorta, and one caudal due to the coarctation itself

(C) Erosions of the ribs

(D) Enlargement of the left ventricle and increased curve to the right of the ascending aorta

(E) Enlargement of the left auricle

In experimental studies on dogs in 1935–6, I demonstrated that the flow of blood to all the organs could remain suspended for as long as 25 minutes without there being any subsequent signs of organic damage, provided an adequate flow to the brain was secured This circulation to the brain was maintained by creating anastomosis between the carotid and jugular vessels in a dog of the same size lying beside it On the strength of this observation I took, in certain patients with a patent ductus, the risk of placing clamp forceps on the aorta above and below the point of entry of the duct, leaving them in place during the time necessary to divide the duct and suture the aorta In one of the patients this part of the operation took no less than 27 minutes I was forced to it because an attempted ligature cut the ductus completely with bleeding somewhat difficult to control In spite of this no noticeable disturbances were observed

Because of repeated experiences of clamping of the aorta in cases suitable for division of the ductus I began in 1943 to discuss whether it might not be possible to treat congenital coarctation of the aortic isthmus by resection

In the light of the results obtained in the experiments and of the clinical experiences it seemed that in patients with congenital isthmus stenosis, who already possessed a well-developed collateral system between the large arteries arising central to the coarctation and the arteries in the lower half of the body, the aorta could be kept closed for considerably longer than 27 minutes without danger to the patient

As far as I had been able to ascertain at that time the only other investigator who had considered the possibility of relieving coarctation surgically was Blalock, who, however, attacked the problem from a different standpoint, having considered some form of anastomosing operation or plastic reconstruction as the only way of improving the circulation peripheral to the stricture

I, therefore, decided that the bad prognosis of aortic coarctation was a sufficient justification for attempting surgical treatment which was tried for the first time on two cases in October, 1944

Resection of the constricted part of the aorta was carried out and the aorta was sutured end to end with oiled silk with a technique similar to the one described by Carrell Both cases healed and normal blood pressure conditions were re-established

Until the end of July, 1947, 22 cases have been resected with 2 deaths, one due to hæmorrhage from a divided intercostal artery from cutting through of the central ligature, and one (about a month after the operation) due to formation of a false dissecting aneurysm from insufficiency of the aortic suture Three more cases have been explored without any attempt at resection In one the constriction of the aorta extended from the origin of the innominate artery to well below the left subclavian artery In the second the aortic wall was extremely thin and hypoplastic In the third, the oldest in my series, aged 35 years, there was extensive atherosclerosis The two first mentioned of these cases died of post-operative complications The first had bilateral pneumonia, insensitive to penicillin and sulphonamides, he had been treated for months before operation with a combination of penicillin up to a million unites a day and sulpha-compounds because of bacterial endocarditis and with healing of this complication The second died from extensive uncontrollable oozing from the wound, and into the pleural cavity, he had been operated on many years before for appendicitis, that time also with severe after-bleeding from the wound The third of these patients healed without complications

Despite this experience I would like to stress that an ordinary exploratory thoracotomy cannot be considered more dangerous than an exploratory laparotomy and is certainly justified in a great variety of cases and also in order to determine whether or not resection can be performed in those cases of coarctation that are deemed suitable for operation

Methods of investigations taken up since a year ago, which we hope will diminish the number of explorations in coarctation cases, are cardio-angiography and heart catheterization

By the latter method all sorts of shunts such as ventricular or atrial defects or patent ductus can be diagnosed by taking blood samples simultaneously from different parts of the heart and a peripheral artery Cardio-angiography I believe will be of utmost importance By this method the site and the extent of the constriction can be determined and unnecessary explorations can be avoided, it also makes it possible to study the anatomical result of the operation

We intend now if possible to take cardio-angiograms as a routine after our operations In 5 of 6 cases we have found normal conditions In the

sixth there was a small vague rounded shadow close to the aorta at the calculated site of the anastomoses indicating the possibility of formation of a small aneurysm at this point This case will be subjected to further cardio-angiograms in order to see what happens Clinically he is in very good condition

As mentioned we have now resected the aorta in 22 patients Two of these died The 20 surviving have healed without or with minor post-operative complications of no importance to the subsequent course They have all been followed up in all the subjective symptoms that the patients had before the operation have vanished

In most cases the blood pressure in the arms has returned to low normal values In a few it is still at or slightly above the normal upper limits In all cases the blood pressure in the legs has been elevated—in some up to 10–20 mm higher than in the arms which is to be considered as normal in the others up to the same or slightly below the blood pressure in the arms All the blood pressure readings I am now discussing are at rest

In all cases the oscillograms from the lower limbs after work have gone back to normal showing much increased oscillations and an increasing blood pressure instead of the pathological or paradoxical reaction before operation

Cardiac tolerance tests as used by Nylin have been made in all cases In some before operation this test has indicated a certain amount of cardiac insufficiency after work In all when these tests were repeated after operation a normal function was found This correlates with our finding that the cardiac volume has returned to normal in all cases with pathological findings in that respect before operation In some cases in which the heart volume has been within calculated normal values we have, however, also found a diminution after operation

Patent Ductus Arteriosus

I want to give a brief résumé of my results in 101 operations for patent ductus I have done double ligature with injection of 50 per cent glucose solution as a sclerosing agent between the ligature in 69 of the cases, and in the remaining 32 I have divided the ductus In most of these I have done a clean arterial suture of the wound both in the aorta and the pulmonary artery

All the cases have been correctly diagnosed and there was no discussion of the certainty of the diagnosis All had the typical continuous murmur with typical localization which could be demonstrated by auscultation and verified by phono-cardiographic registration

In all surviving cases this murmur disappeared and has not reappeared in any case

I have divided the 101 cases into 95 non-infected cases and 6 cases with infection of the ductus and septicæmia

In the first group 2 cases died The first could have been avoided Everything was quite normal until the catheter was passed through the intratracheal tube for post-operative aspiration It was not observed that the suction catheter practically filled the whole lumen of the small intratracheal tube, and in consequence the endobronchial pressure was rendered highly negative The same effect was produced as was described in this country from the effect of the negative pressure wave in blast injuries There was a sudden heart stop The wound was immediately reopened and the heart action revived by direct heart massage The time of complete heart arrest was, however, too long, about 5 minutes, and the patient died about 48 hours later from the result of severe cerebral anoxæmia

In the second case there was a very marked hypoplasia of the aortic wall around the ductus This was not observed before the ductus was divided after clamping of the aorta above and below Because of the hypoplasia of the aortic wall it was extremely difficult to obtain a sutureline without leak and the aorta had to be clamped for a little more than 45 minutes In this case post-operative anoxæmic damage of the spinal cord developed Because of this and other complications the patient died three weeks after operation

This gives a mortality of just over 2 per cent in this group, with complete healing without recurrences in the surviving cases

In the second group of 6 cases 5 healed with no complications and 1 died This was the first in the group before we had penicillin available in Sweden With only sulpha-drugs it was impossible to get negative blood cultures, which we have been able to obtain in the rest of the cases before operation This fatal case seemed to heal quite all right in the beginning She left hospital about 6 weeks after operation with negative blood cultures, normal temperature and only slightly elevated sedimentation rate However, she came back to hospital a couple of months afterwards with all clinical signs of a recurrence of her septicæmia and also a recurrence of her ductus arteriosus It was difficult to declare how this recurrence might have occurred as this patient was treated with complete division of the ductus and suturing of both the aorta and the pulmonary artery I believe that an infected hæmatoma must have formed between the pulmonary artery and the aorta and that this hæmatoma secondarily must have broken into both the pulmonary artery and the aorta The patient was submitted to a re-operation at which was found a

big false aneurysm between the aorta and the pulmonary artery with communication between the aneurysm and both the big vessels An attempt was made to resect the aneurysm and to close the aorta and the pulmonary artery This was, however, technically impossible to perform After a partial resection of the aneurysm this was sutured and the chest wound closed The patient died shortly after the operation was finished

Patent Ductus Arteriosus

By Rae Gilchrist, Edinburgh

Notable contributions have been made to this subject in recent years I shall confine my remarks to the diagnosis of the *patent ductus* and the results of surgical occlusion Nearly 70 cases have been under observation and I am greatly indebted to my surgical colleagues, Sir John Fraser and Mr Walter Mercer, who have kindly placed their operative notes at my disposal

In diagnosis the hallmark is the continuous murmur described by Gibson, heard best below the inner end of the left clavicle and almost invariably accompanied by an accentuated second pulmonary sound. Difficulties arise in infancy before the murmur has developed its full continuous quality, and also in later life, when, in the presence of congestive heart failure, it may at times be inaudible so that the lesion escapes clinical recognition By the time school age is reached the murmur has usually developed its distinctive continuous quality When the channel is large, the ductus of wide bore, 1 cm or more in diameter, the leak from the aorta to the pulmonary artery is considerable The physical signs are then well marked, the murmur loud and roaring, with a thrill coarse and widespread The heart is larger than when the murmur is less intense and an isolated finding On cardioscopy a fast, vigorous over-active heart with an increased and flicking type of pulsation in the aorta and pulmonary artery is very characteristic In my experience the dilated left auricle and a hilar-dance in the smaller vessels of the lung roots are exceptional They do not occur in the average case, but only when the ductus is of wide bore On the other hand, in the pulmonary artery itself the vigorous, forceful pulsation—what we call in Edinburgh a Highland fling—is very characteristic

Bohn's exercise test in our hands has not come up to expectations When the physical signs are doubtful in a child, that is before the Gibson murmur has developed, the response of the blood pressure to exercise has seldom been of help in reaching a diagnosis In the majority of children the electrocardiogram is of normal form After the age of 10 years the proportion of patients who show a minor grade of left axis deviation tends steadily to increase

In diagnosis it is important to correlate any general septicæmic signs with the local evidence of a patent ductus, as this at once gives the clue to a bacterial infection restricted at its onset to the pulmonary artery in the immediate neighbourhood of the mouth of the ductus In the diagnosis of the infected case there is a triad of signs that make a characteristic clinical picture (1) local evidence of a patent ductus, often overwhelmed by the more dramatic and florid features of (2) a generalized septicæmia and later as the local vegetative process advances in the pulmonary artery, and (3) multiple lung infarcts It is, of course, desirable to make the diagnosis of endarteritis of the pulmonary artery before infarcts, systemic or pulmonary, occur Early ligation should be urged

With the increasing experience of the past seven years I have little hesitation in expressing the view that on the recognition of a patent ductus in childhood, surgical closure should be recommended with few exceptions The results obtained by closure of the channel are very good As the ductus may on occasions close spontaneously surgery can be withheld, if the physical signs are not advanced and the heart unembarrassed, perhaps until the age of 7 or 8 After this age if the ductus remains patent the child should be sent to the thoracic surgeon, preferably before the age of 10 is reached If the signs are gross, nutrition impaired, and the child obviously handicapped, closure of the ductus should be undertaken earlier, even by the age of 3 or 4 years After the age of 10 the surgical technique is a trifle more hazardous and the structure less resilient and the late Mr Tudor Edwards showed that the mortality rate for intra-thoracic interference increased with each decade In my experience the age period 7 to 10 years is for choice the most suitable time to recommend ligation When recognized first about the age of 20 to 30 there is less justification for recommending surgery If the general state of health is satisfactory, the response to effort good, and the heart not enlarged, then the ductus must impose no more than a trifling burden on the circulation In these circumstances I doubt the wisdom of recommending a major

surgical procedure The development of a fever, or any septicæmic signs demands prompt action and every care should be taken to reduce the risk of a *Streptococcus viridans* infection so commonly derived from oral or dental infection It is important, for instance, to recommend the administration of sulphonamides over the period of dental extractions if the risks of septicæmia are to be avoided in those known to harbour this and other congenital cardiac defects

In the immediate post-operative care of these patients measure to reduce the tendency to massive pulmonary collapse are important A pleural effusion should be tapped even within 24 or 48 hours of operation Respiratory exercises should be commenced at the first opportunity In fact it is useful to have the child taught the appropriate exercises in the days before surgery is undertaken

The results we have obtained in Edinburgh have been very satisfactory It is seven years since the first ligation was undertaken Deaths have occurred from massive pulmonary collapse in two infected cases and also from mediastinal infection (before penicillin was available) in one case and from hæmorrhage in another With the exception of three patients in whom recanalization occurred the remainder have all obtained striking benefit, more than sufficient to compensate for the bitter disappointments of our earlier experience

Perhaps one or two case records are more instructive than a statistical analysis All the patients improved in physical fitness and general nutrition A decrease in the size of the heart and an improved psychological outlook are the rule A boy, attending a special school for crippled cardiacs had his ductus ligated 3 years ago, he now plays Rugby football Only eight months ago a boy of 13 had his ductus ligated last week his mother sent me his headmaster's report for the term " He is an entirely different boy since his operation His thrust and responsiveness are much more positive and sustained We have seen this at his cricket and at his work He has lost his diffidence " One other exceptional patient is worthy of mention, as five years have elapsed since this boy's ductus was ligated at the age of 13 within two years he gained 43 lb in weight and grew 8 inches in stature Since then he has been accepted as A1 for the Army, and has won a regimental boxing competition, does a 15-mile cross-country run twice a week, and claims to have done 100 yards in 10 seconds Surgery can save lives from invalidism and prevent premature death from infection Closure of the ductus is a most notable advance in cardiac therapeutics

By Holmes Sellors, London

I am confining my remarks to *patent ductus arteriosus*, the only form of congenital heart disease with which I have had much experience Previous speakers have stressed most of the clinical and therapeutic aspects of the condition, and I want to speak of some of the most unusual features At the outset I would like to stress the view that it should be regarded as a condition requiring surgery unless there are obvious contraindications Even though it is less than ten years since the first ductus was tied, the minimal risk of operation in practised hands far outweighs the risks that the patient undergoes from being left alone I have been most impressed by the results, even in patients who had practically no symptoms Children develop quickly physically and mentally, and young adults are most emphatic in stating how well they feel after the arterio-venous shunt has been relieved

In all I have now operated on 46 patients with this lesion, with one death Ten of these patients had infective endocarditis, and 5 were ligated in the active phase of the disease Since the use of penicillin, we have tended to wait until the infection has been well controlled, and to tie the ductus some weeks later

Another 10 patients were showing signs of embarrassment with dyspnœa, considerable enlargement of the heart, and subjective symptoms

Of the remaining 24 about half complained of some disability or limitation of activities that was cured by ligation of the ductus The others, mainly young children, were virtually symptomless

The diagnosis depends on a combination of the classical murmur, the low diastolic pressure, and radiography, and it is fair to say that the murmur occupies most attention In our 46 cases the murmur and thrill could be regarded as typical in 35 But there were two patients in whom no murmur was heard until infective endocarditis developed—one of these had been fully investigated some months previously, and the evidence for previous absence in the other case was quite strong In other words, a thrill or murmur can be absent with a patent ductus

Next there was a group of 9 cases in which the murmur was atypical In 5 instances a harsh systolic sound only could be detected, and in the remaining 4 the lesion was probably complicated The diagnosis had to be based on other factors, but in each patient the patent ductus was recognized and occluded This brings me to an important point in the observation and behaviour of the

murmur at operation In all cases we have used a stethoscope directly on the heart to establish the point of maxium intensity which ordinarily lies 3 5 cm below the actual ductus on the conus Normally when the ductus is compressed the murmur and palpable thrill disappear, but there have been a number of cases in which sounds still persisted A coarse systolic bruit that disappears in several weeks is fairly common, but there were 4 cases in which the thrill and murmur altered in character and position but still persisted If we had only recognized this after operation, the possibility of recanalization or failure to close the ductus would have been considered In these unusual cases complete closure of the ductus was confirmed and additional dissection to exclude other channels was carried out One of these patients constituted our only fatality the diagnosis before operation was recorded as a persistent ductus plus a patent auricular septum The residual murmur, which was that of the patent septum, was heard, and the septum was demonstrated at autopsy The cause of death was an unrecognized low degree of hæmophilia which led to continued pleural hæmorrhage in spite of the use of anticoagulants and massive blood transfusions I have emphasized this, because I feel that additional lesions can easily be overlooked, and that our knowledge of the causation of both thrill and murmur is incomplete On occasions an accidental pressure or kinking of the pulmonary artery has produced unusual sounds, and even mediastinal displacement can add to the confusion There is also the effects of air or traces of blood in the pericardium to be considered if this sac is nicked during operation

One cannot exclude the possibility of recanalization if simple ligature is used I have employed no other method in the series, and am left with two cases which would in many ways serve as examples, both were originally infective cases in which the murmur persisted in an altered character, both are clinically in excellent condition, and in one the diastolic pressure is at normal level, the other maintained a low diastolic all through, even directly after the ductus was tied

The question of blood pressure has been fully studied, and in children under 14 years the average figure was 106/44 mm before operation and 104/71 some time after In adults an average reading of 123/56 went to 128/81, giving a rise in the diastolic level of 25 mm At the moment of ligature the pressures sometimes rise appreciably and a typical reading was 100/40 before operation, 130/110 immediately after ligature, persisting for 10 to 14 days to stabilize at 96/70 This rise in blood pressure occasionally coincides with a very rapid post-operative pulse rate lasting for a week to a fortnight and not due to any difficulty in lung expansion

The final point I would make is concerned with the radiographic appearances On screening the dilated conus and the free active pulsation in the lung root may be recognized, and we have found considerable value in kymography, where we have noted an erratic notching over the conus in a proportion of cases I am not certain, but feel that this is almost diagnostic, and it has been of help in doubtful cases

Of other abnormalities that have been encountered at operation, there has been a stricture of the left pulmonary artery, and a large vein resembling a left superior vena cava in size and position which in part entered lung substance

These points I have brought forward to suggest that diagnosis is not always simple, and that there are an appreciable number of additional complications that may be encountered Surgery, apart from its therapeutic value, has afforded some light on the pathology of the living, and has certainly led to some doubt as to the reliability of interpretation of classical physical signs

By O S Tubbs, London

I wish to congratulate Dr Taussig, Dr Blalock, and Dr Crafoord on their remarkable work My experience is limited to 33 patients operated upon with the diagnosis of patent ductus, and my comments are based on this series

In 32 of these 33 cases, the diagnosis of patency of the ductus proved correct at operation An additional lesion was almost certainly present in two, in the rest, the ductus appeared to be the only abnormality A Gibson murmur was present in all the cases except in one child of 8 in whom the murmur was confined to systole, the lumen of the ductus in this latter case proved extremely small

With regard to the X-ray findings, prominence of the pulmonary artery below the aortic knuckle should not be expected in every case, as it was sometimes completely absent The sex incidence in the series showed the expected preponderance of females (22 females and 10 males)

Indications and optimum time for operation Starting in 1939 with an infected case, my experience was for a long time confined to those with infection,

but it is now thought that *all* cases in which a patent ductus is diagnosed as the sole lesion, should be treated surgically at about the age of 7, unless there are special indications to operate earlier Subsequent to the age of 7, secondary changes and complications, including infection are liable to occur in the untreated case, so that operation should not be delayed much beyond this age

With regard to an upper age limit, the operation does not become more hazardous after the age of 20 There had been 12 patients over the age of 20 with 2 deaths, and 20 patients under 20 with 3 deaths, *all* the deaths being in infected cases

The higher mortality in the presence of infection, i e 5 deaths in 12 cases (40 per cent) had been the general experience before penicillin became available This raises the question as to the place of operation in the infected case at the present time The dramatic reduction in fever and rapid removal of bacteria from the blood stream in such patients is well recognized, but although many patients progress to complete recovery, the mortality is considerable On these grounds a full course of penicillin should be given, and this should be followed by operation to prevent recurrence In the penicillin-resistent case the ductus should be closed as soon as the diagnosis had been made Evidence of systemic embolism in addition to pulmonary infarction is not a contraindication to operation as, although the chance of cure is much less when systemic embolism has become apparent, recovery does sometimes follow

Cyclopropane had been used as the anæsthetic agent in earlier cases, but ether was now preferred, with curare to diminish the respiratory excursion, as this was less likely to produce cardiac irregularities With regard to the operation, the posterior approach through the fourth intercostal space was much preferred to the anterior incision, as the cosmetic result was better, and, far more important, it gave a wider exposure so that it would be possible to deal with any accident that might occur

The best method of closing the ductus remained a subject for discussion as the incidence of recanalization following the various techniques was still argued The criterion on which recanalization could be diagnosed was also not fully agreed although most workers considered a diastolic murmur as indicative of a leak The short ductus of large calibre was the type most likely to recanalize following simple ligature, and on these grounds it was probably preferable to divide such cases and suture the two ends

The changes consequent to closure of the ductus were mentioned, including the immediate rise of diastolic blood pressure, the abolition of the thrill in the pulmonary artery and of the diastolic murmur, and the rapid reduction in the size of the heart, and in the prominence of the pulmonary artery and its branches in the lung field

Complications were rare Tachycardia was commonly seen in the first week or ten days after operation, but proved of little consequence Massive collapse of the left lung or left lower lobe had been seen, but this had not caused serious disturbance Fluid collection in the pleural sac was occasionally sufficient to require aspiration

Coarctation of the Aorta

By Crighton Bramwell, Manchester

Sufficient time has not yet elapsed since the introduction of this operation to enable one to tell how much it would add to the span of life, but there is good reason to be optimistic

In his own series of 36 cases of coarctation, 13 were over 30 years of age at the time they first came under observation His 3 oldest patients were dead, but all lived to over fifty, and 2 died of conditions unassociated with their coarctation, one of carcinoma of the stomach and the other of lobar pneumonia Of the other 10 patients over thirty, 9 were still living and many of these were capable of undertaking strenuous physical exertion without any apparent disability The third decade seemed to be the most dangerous, for many patients were free from symptoms and, being men of good muscular development, were liable to be subjected to severe physical strain, while in the case of women, their first confinement might prove fatal There seemed to be a fair chance that those who survived the hazards of the third decade might live another twenty years Should these older patients be operated on, or should we consider that having come safely through the dangerous period from twenty to thirty implied that their coarctation was sufficiently well compensated to make their further outlook more favourable? Perhaps my patients may have been particularly fortunate, since in Maud Abbott's series there were 23 per cent of deaths in the fourth decade

The sex incidence is difficult to explain Women with coarctation are less likely to break down because apart from confinement, they are not subject to the same physical strain as men, and

hence they may never be medically examined This, however, cannot be the whole explanation for even in Maud Abbott's series, which was based on post-mortem statistics, the number of males was twice as great as the number of females Necropsies, however, were more frequently performed on males

Regarding cardiac enlargement my experience differs from Dr Crafoord's In only 4 of my 36 cases was the heart much enlarged, and in all four there was some additional lesion that would account for the enlargement three had aortic incompetence and one a freely patent ductus

MAURICE CAMPBELL spoke of the gradual rise of blood pressure observed directly in some cases and deduced from analysis of all reported cases (*Brit Heart J*, 1947, 9, 203)

S SUZMAN described a method by which the collateral circulation in the back could be demonstrated or increased (*Brit Heart J*, 1947, 9, 187)

PULMONARY HEART DISEASE ACUTE AND CHRONIC

September 10, 1947, morning Joint Meeting with Section of Diseases of the Chest

By J McMichael, London

Heart failure from primary disorder of the lungs may be classified as follows

Acute Pulmonary embolism
Subacute Miliary carcinoma
Chronic (1) Primary pulmonary hypertension
(2) Secondary to lung disease
Emphysema (Bronchitis, Bronchiectasis, Cystic disease)
Pneumoconiosis (Silicosis, Anthraco-silicosis)
Pulmonary fibrosis (Fibroid tuberculosis, Scleroderma)
(3) Kyphoscoliosis

Acute pulmonary embolism Recognized by circulatory collapse, raised venous pressure, electrocardiographic and other signs of right heart strain

Chronic cor pulmonale Commonest cause is emphysema Capacity of lung vessels in health is approximately 800 ml and this volume is mainly in the capillaries Obliteration of half the vascular bed in the lungs by ligation of left pulmonary artery produces no rise of pulmonary artery pressure Best measurement of anatomical lung damage is percentage of residual air in total lung volume Normal average 28, range 16–40 per cent, anything over 60 denotes severe emphysema Optical records of systolic right ventricular pressure also measure pulmonary artery systolic pressure Normal range 18–30 mm Hg In emphysema without heart failure this pressure is often raised, but there is no correlation between residual air percentage and degree of pulmonary hypertension It is therefore unlikely that anatomical damage to lungs is itself directly responsible for pulmonary hypertension

In heart failure from emphysema cardiac output is normal or above normal except when blood pressure falls terminally

High output failure This group includes (1) subjects with circulatory shunts which are parasitic on normal circulation (arteriovenous aneurysms, Paget's disease of bone), (2) conditions demanding an excessively rapid circulation due to deficiency of available oxygen (anæmia, cor pulmonale), (3) beri-beri The rapid circulation is achieved by a rise in venous pressure, even though œdema also appears

Clinical Features General dusky cyanosis, warm hands, and good peripheral pulse (Contrast cold blue hands and ears of low output failure resulting from hypertension, valvular and ischæmic heart disease) Often an exacerbation of chronic bronchitis, in absence of this, orthopnœa strikingly absent Auricular fibrillation unusual Terminally pulmonary œdema often present Radiologically enlargement of pulmonary artery Electrocardiographic signs of right heart stress

Treatment Oxygen tent and penicillin aerosol inhalation Venesection lowers cardiac output Digoxin usually does the same, and both procedures may be harmful

Some clinical varieties (1) Acute circulatory collapse from valvular pneumothorax or large bulla, due to loss of negative intrathoracic pressure and defective filling of the heart with resulting fall in output (2) Miliary carcinomatosis Oxygen saturation of arterial blood falls, cardiac output rises, often with rise in venous pressure (3) Primary pulmonary hypertension occurs with no disease in lungs other than increased vascular resistance (4) Scleroderma may be associated with fibroid changes in the lungs and right heart strain (5) Kyphoscoliosis Cor pulmonale a well recognized terminal event in such patients

Lung vessels are sensitive to falling oxygen tension which causes vaso-constriction of pulmonary arterioles (Cournand, Von Euler and Liljestrand) Defective ventilation causes closure of the pulmonary circulation in atelectatic and pneumonic lobes This reaction may also produce pulmonary hypertension in emphysematous, fibrotic, and miliary carcinomatous lungs

La Pression Ventriculaire Droite Moyenne (P V D M) Dans Certaines Affections Broncho-pulmonaires Chroniques

Par J Lenegre et P Maurice, Paris

L'hypertension dans la circulation arterielle pulmonaire est considérée depuis longtemps comme un des principaux facteurs qui expliquent l'évolution possible de certaines affections broncho-pulmonaires chroniques vers l'insuffisance ventriculaire droite Mais cette conception, quoique basee sur des arguments cliniques, radiologiques, electriques et anatomiques, e-tait seulement jusque dans ces dernieres années une hypothèse plausible, puisque les médecins étaient incapables de mesurer chez l'homme la pression dans la petite circulation

Depuis six ou sept ans, des recherches poursuivies aux Etats-Unis, en France et en Angleterre, ont permis de mesurer chez l'homme la pression qui règne dans les cavités droites du cœur et même dans l'artère pulmonaire

En 1941, Richards *et al*, de New-York, les premiers à notre connaissance, puis en 1944, McMichael et Scharpey-Schafer, de Londres, font connaitre les chiffres de la pression auriculaire droite chez l'homme normal et en état d'insuffisance cardiaque En decembre 1943, Lauson, Bloomfield, Breed, et Cournand rapportent quelques chiffres de pression ventriculaire droite (systolique, diastolique et differentielle) a l'état normal et chez les cardiaques En Mai 1944, Lenegre et Maurice exposent leurs premiers résultats de la mesure de la P V D M chez 51 sujets dotes d'un coeur normal ou atteints de cardiopathies diverses Depuis, ces recherches se sont multipliees aux Etats-Unis (Bing, Vandam, et Gray, Jr), au Mexique, au Danemark (Tybjaerg, Hansen, et Warburg), en Suède

Il est donc inopportun de reprendre en détail la technique actuellement bien connue de la cathétérisation du coeur droit une sonde stérilisee est introduite aseptiquement par une veine du pli du coude (de préférence la basilique) jusque dans l'oreillette droite ou le ventricule droit Personnellement nous utilisons une sonde uretérale n° 13, longue de 120 centimètres, que nous faisons pénétrer dans la veine par dénudation sanglante ou grâce à un trocart dont le calibre interieur est de 2,4 mm Faute d'un matériel plus précis, nous mesurons avec un manomètre anéroïde (Claude) la pression moyenne qui regne dans les cavités droites, notamment dans le ventricule droit La technique est à la fois sûre et simple Si elle connait quelques échecs, dûs souvent à des spasmes veineux, elle est inoffensive Elle n'est suivie d'aucun incident, sauf parfois d'une induration un peu douloureuse et tres passagère de la veine ponctionnée

Nos premières recherches nous ont conduits a considérer que la P V D M varie suivant les sujets a l'état normal entre 10 et 20 cm d'eau, soit 7 5 à 15 mm de mercure Le chiffre moyen est de 15 5 cm d'eau, soit 12 mm de mercure

Le but de cette communication est d'exposer les chiffres de P V D M recueillis par 42 explorations chez 41 sujets atteints 1°—d'une affection broncho-pulmonaire chronique avec ou sans catarrhe bronchique asthme (8 cas), emphysème (13 cas), silicose ou asbestose (13 cas), tuberculose fibreuse (1 cas), dyspnée de cause inconnue (1 cas), 2°—d'une cyphoscoliose accentuée avec gibbosité (4 cas), 3°—d'une thrombose primitive des deux artères pulmonaires (1 cas) Chez ces 41 malades, l'insuffisance cardiaque, et notamment une insuffisance ventriculaire droite typique (coeur pulmonaire chronique), était présente 10 fois

Nous avons divise ces 41 sujets en 2 groupes suivant que leur affection était bien ou mal tolerée Nous avons admis que les signes suivants étaient les indices d'une mauvaise tolerance 1°—dyspnée accentuée au repos ou au moindre effort, limitant plus ou moins l'activité sociale, 2°—cyanose, 3°—bruit de galop droit, gros coeur, gros foie, oedèmes des membres inférieurs Nos resultats sont consignes dans les deux tableaux suivants

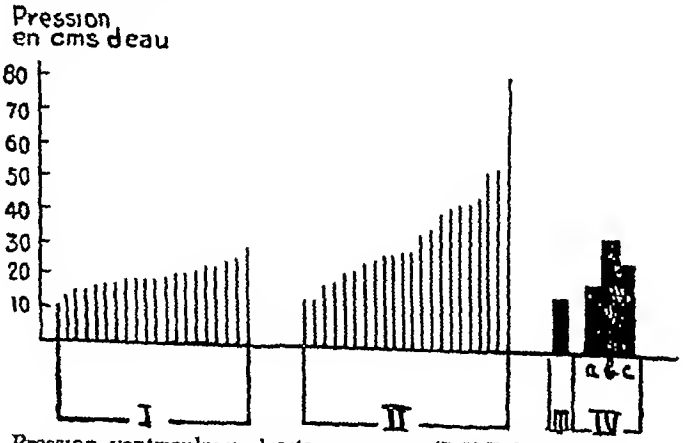

Pression ventriculaire droite moyenne (P V D M) chez 41 sujets atteints d'une affection broncho-pulmonaire chronique avec ou sans catarrhe bronchique (asthme, emphysème, silicose, sclérose tuberculeuse), ou d'une cyphoscoliose accentuée ou d'une insuffisance ventriculaire droite
I—Affection broncho-pulmonaire bien tolérée (20 cas) II—Affection broncho-pulmonaire mal tolérée (22 mesures chez 21 malades) III—P V D M chez le sujet normal (15 cm d'eau) IV—P V D M dans les affections broncho-pulmonaires chroniques a) bien tolérées 18 7 cm d'eau b) mal tolérées 33 cm d'eau c) moyenne générale 26 2 cm d'eau

Il ressort les faits suivants

(1)—Dans 20 cas d'affection broncho-pulmonaire chronique (ou autre) bien tolérée, la P V D M est

—14 fois mormale (10 à 10 cm d'eau, soit 7 5 à 15 mm de mercure)

—3 fois à peine superieure à la normale (21 a 22 cm d'eau, soit 16 mm de mercure)

—3 fois moderément augmentée (24 à 28 cm d'eau, soit 18 à 21 mm de mercure)

Le chiffre moyen, calculé sur ces 20 cas, est de 18 7 cm d'eau (14 mm de mercure), e'est-à-dire voisin de la normale

(2)—Sur les 22 mesures effectuees chez 21 sujets atteints d'une affection broncho-pulmonaire chronique (ou autre) mal tolerée, la P V D M est

—4 fois normale (13 a 18 cm d'eau, soit 10 a 15 mm de mercure)

—2 fois a peine superieure a la normale (21 a 22 cm d'eau, soit 16 mm de mercure)

—16 fois franchement ou considérablement augmentée (25 a 80 cm d'eau, soit 19 à 60 mm de mercure)

Le chiffre moyen calcule sur les 22 mesures est de 33 cm d'eau (25 mm de mercure), soit plus du double du chiffre normal

(3)—La moyenne genérale des chiffres de P V D M , calculée d'après nos 42 explorations chez 41 sujets atteints d'affections broncho-pulmonaires chroniques diverses, bien ou mal tolerées, s'etablit à 26 2 cm d'eau (20 mm de mercure) Elle est donc franchement élevee

La confrontation des chiffres de la P V D M avec les signes cliniques, radiologiques ou electriques, montre que, dans l'ensemble, plus la maladie broncho-pulmonaire est sevère et plus l'hypertension ventriculaire droite est elevée Le fait est particulierement évident dans les cas d'insuffisance ventriculaire droite avéree, qui correspondent comme on peut le voir sur le deuxieme tableau, aux chiffres les plus forts, a savoir, 35, 40, 41, 42, 44, 52, 53 et 80 cm d'eau, soit 26 à 60 mm de mercure

Dans 6 cas cependant ou la maladie broncho-pulmonaire chronique peut passer pour bien tolérée, la P V D M est deja elevee (21 à 28 cm d'eau, soit 16 a 21 mm de mercure) Cette hypertension dans la circulation artérielle pulmonaire représente fort probablement un indice defavorable L'avenir montrera si l'evolution s'est faite plus rapidement chez ces malades vers l'insuffisance ventriculaire droite

Inversement, dans 4 cas ou l'affection broncho-pulmonaire chronique parait dejà mal tolerée (dyspnée accentuee et parfois cyanose), sans être cependant accompagnee d'insuffisance ventriculaire droite, la P V D M reste normale (13 a 18 cm d'eau, soit 10 a 15 mm de mercure) Ces résultats, un peu insolites, ne s'expliquent pas par des considérations d'âge et de sexe, et leur mécanisme nous echappe encore Ils sont d'ailleurs relativement rares et n'empêchent pas d'admettre que l'augmentation de la P V D M marche de pair avec la gravité de la maladie elle représente probablement un des facteurs décisifs dans l'evolution et le pronostic d'une affection broncho-pulmonaire chronique Nos recherches semblent donc confirmer l'opinion classique

Nos constatations sont en harmonie avec celles de Cournand, effectuees a l'aide d'une technique plus precise (enregistrement, avec un manomètre à membrane de Hamilton, de courbes etalonnées de la pression ventriculaire droite, systolique, diastolique et différentielle) Par cette méthode, Cournand admet que chez l'homme normal la pression ventriculaire droite systolique varie entre 18 et 30 mm de mercure, avec une valeur moyenne de 25 mm de mercure Chez 17 sujets atteints d'emphysème ou de sclérose pulmonaire sans gros coeur, la pression ventriculaire droite systolique s'est montrée 4 fois normale (autour de 24 mm de mercure) et 13 fois elevée (44 à 45 mm de mercure)

Dans un autre travail, Bloomfield, *et al* (1946) relevent les resultats suivants qui portent sur 20 mesures effectuees chez 19 sujets atteints d'emphyseme ou de sclérose pulmonaire sans insuffisance ventriculaire droite pression systolique, 16 à 57 5 mm de mercure, pression differentielle (pulse pressure), 16 à 54 mm de mercure Chez deux autres malades ou l'affection se compliquait d'insuffisance ventriculaire droite evidente, la pression systolique était de 35 et 77 mm de mercure et la pression différentielle de 21 et 68 mm de mercure De ses recherches, Cournand conclut

"(a) That pulmonary hypertension had not developed in cases with moderate degree of emphysema, (b) but that in the group with the most marked degree of emphysema, hypertension in the lesser circulation was present, and finally, (c) that in the group with fibrosis and moderate emphysema and apparently small heart, pulmonary hypertension was already quite marked For a time, it was our impression that polycythemia played a decisive role in the early development of pulmonary hypertension by increasing the resistance to flow"

Nous avons aussi cherché s'il n'existerait pas des signes cliniques, radiologiques ou electriques susceptibles de faire prévoir l'hypertension dans la circulation artérielle pulmonaire Le plus souvent, il n'est pas possible d'en inferer du syndrome clinique à la pression ventriculaire droite Cependant, sur 7 cas ou la cyanose était présente, la P V D M s'est montree franchement augmentee 5 fois Sur 4 cas ou l'axe electrique du coeur etait vertical, la P V D M

était nettement augmentée 3 fois Enfin, elle etait franchement élevee dans les 4 cas d'axe électrique droit Ce dernier signe, d'après notre expérience personnelle, parait donc être un indice a peu pres certain de forte hypertension pulmonaire Mais nous ne croyons pas devoir attribuer d'importance à l'amplitude augmentee des ondes auriculaires P dans les deuxieme et troisieme derivations, et notre élève Ferrero publiera prochainement ses constatations à ce sujet

Comme nous l'avons dejà signalé, la presence d'une insuffisance ventriculaire droite d'origine pulmonaire est, elle aussi, un test géneralement decisif d'hypertension dans la circulation pulmonaire

SUMMARY

La pression ventriculaire droite moyenne (P V D M) est etudiee dans 41 cas d'affections broncho-pulmonaires chroniques (asthme, emphyseme, cyphoscoliose, etc) avec ou sans insuffisance ventriculaire droite

Chez 20 malades dont l'affection est bien toleree, la P V D M est 14 fois normale, 3 fois à peine superieure à la normale, 3 fois modérement augmentée Le chiffre moyen, calculé sur ces 20 cas, est de 18 7 cm d'eau, ou 14 mm de mercure, c'est-à-dire voisin de la normale (15 5 cm d'eau ou 12 mm de mercure)

Chez 21 malades, qui ont permis 22 explorations et dont l'affection est mal tolérée, la P V D M s'est montrée 4 fois normale, 2 fois à peine supérieure a la normale et 16 fois franchement ou considérablement augmentée (jusqu'à 3 et même 5 fois la valeur normale) Le chiffre moyen calcule sur ces 22 mesures est de 33 cm d'eau (25 mm de mercure), soit plus du double du chiffre normal

Sauf rares exceptions, plus la maladie broncho-pulmonaire est sévère, et plus l'hypertension ventriculaire droite est accentuée Le fait est particulièrement evident quand existe une insuffisance ventriculaire droite avérée, ou quand l'axe electrique du coeur est devie à droite

Dans les affections broncho-pulmonaires chroniques, l'élévation de la pression ventriculaire droite (ou artérielle pulmonaire) represente probablement un des facteurs essentiels de l'évolution vers l'insuffisance ventriculaire droite

REFERENCES

Bing, R J, Vandam, L D, et Gray, F D, Jr (1947) *Johns Hopkins Hosp Bull*, 80, 107 et 121

Bloomfield, R A, Lauson, H D, Cournand, A, Breed, E S, and Richards, D W, Jr (1946) *J Clin Invest*, 25, 639

Cournand, A (1946) Meeting of New York Academy of Medicine, 7 Mars

Lauson, H D, Bloomfield, R A, Breed, E S, Baldwin, E F, and Cournand, A (1943) Meeting of New York Section of Society for Experimental Biology and Medicine, 15 Dec

Lenegre, J, et Maurice, P (1944) *Arch mal coeur*, 37, 101, *et Bull Mém Soc Méd Hôp*, Paris, 60, 239

Lenegre, J, et Maurice, P (1947) *Stanford Med Bull*, 5, 61

—— (1947) *Acta Cardiologica*, 2, 1

Maurice, S (1946) *La pression ventriculaire droite chez l'homme* Louis Arnette, edit, Paris

McMichael, J, and Sharpey-Schafer, E P (1944) *Brit Heart J*, 6, 33

Richards, D W, Jr, Cournand, A, Darling, R C, and Gillespie, W H (1941) *Tran Ass Amer Phys*, 56, 218

Tybjaerg Hansen, A, et Warburg, E (1947) *Amer Heart J*, 33, 709

PULMONARY HEART DISEASE

BY W D W BROOKS, London

I propose in this discussion to examine some of the causes and the consequences of hypertension in the pulmonary circulation, particularly in so far as the lungs are concerned Hypertension in the pulmonary circulation increases the work of the right ventricle and in certain circumstances may cause pulmonary heart disease The process may be acute, or may occur gradually and be chronic

Acute Cor Pulmonale The most frequent cause is the sudden obstruction of a considerable proportion of the pulmonary circulation by embolism from a systemic venous thrombus usually in the pelvis, abdomen, or leg The phenomenon not unfrequently follows an operation Occasionally the embolus derives from the right side of the heart itself Fat embolism too may give this result Very rarely an aortic aneurysm ruptures into the pulmonary artery and causes acute cor pulmonale

No primary pulmonary disorder is known that gives rise to acute cor pulmonale It has not been reported to occur for example, as a result of blast, irradiation burns of the lungs, or of any acute infection Spontaneous pneumothorax, even when bilateral, does not have this consequence, presumably because the blood flow into the thorax and through

the lungs is reduced proportionately as the intrapleural pressures increase and the lungs shrink A respiratory death is the rule

On one occasion during the war a traumatic diaphragmatic hernia was seen to give rise to acute cor pulmonale A sailor, aged 27, in 1942 fell down a ladder on a destroyer and was admitted to R N H Chatham eight hours later Pain in the front of the chest, dyspnœa, and shock were marked features of the case, and he had a very large (left) traumatic diaphragmatic hernia containing the stomach and some coils of intestine, and the mediastinum was grossly displaced The size of the hernia continued rapidly to increase because the stomach was so kinked on its pyloric attachments that complete obstruction at that level resulted Increasing systemic venous pressure, enlargement of the liver, together with clinical and radiological evidence of dilatation of the right ventricle became evident At this time an electrocardiogram showed negative T waves in leads II and III, and a prominent Q in lead III The passage of a stomach tube and other measures gave some relief, but he died on the operating table Only one other instance of this sequence of events has been recorded (McGinn, S , and Spear, L M *New England J Med* (1941), 224, 1014)

While considerable attention has been paid to the cardiovascular phenomena in acute cor pulmonale the consecutive pulmonary sequelæ have been somewhat neglected They are not unimportant As a direct consequence of the rapid rise in pulmonary vascular pressure the lungs become less easily altered in volume and shape Respiration thus requires more muscular effort, the intrapleural pressure fluctuates at a more nearly atmospheric level, and may exceed atmospheric pressure during expiration The chest can be seen to be relatively distended in expiration, so that in the more usual type of case it seems highly probable that despite extensive infarcts the residual air is relatively and perhaps absolutely increased The vital capacity is reduced, sometimes almost to the level of the tidal air No doubt pain too contributes to cause shallow respiration Moreover, there may well be enough distension of the residual patent pulmonary capillaries to reduce the efficiency of gas interchange at the alveolar surface All this occurs acutely and there is little time for adjustment and compensation to take place, in contrast to what happens when, for example, congestive heart failure supervenes on mitral stenosis As a consequence, and apart altogether from the cardiac effects respiratory inefficiency acute and severe in degree gives rise to anoxæmia, makes the issue more hazardous, and the need for oxygen therapy more urgent The later results of pulmonary infarction in those patients who survive are well known and need not detain us

Chronic Cor Pulmonale Though the pressure in the right ventricle and pulmonary artery can now be measured directly the procedure is scarcely yet one which can be called a routine clinical method As a rule, therefore, the diagnosis of pulmonary hypertension depends upon an understanding of the disorders capable of producing it, and upon the recognition of the clinical features that they may produce

These disorders are numerous but they fall into four groups

(1) obstruction of the pulmonary circulation within its own limits, e g in emphysema, and in certain pulmonary fibroses,
(2) obstruction of the pulmonary circulation beyond its structural limits, e g in the left ventricular failure, and in mitral stenosis,
(3) shunting of blood from the arterial into the pulmonary circulation in, e g certain instances of congenital heart disease and
(4) in severe deformity of the thoracic bony structures, e g severe kyphoscoliosis

In conformity with our original limitation discussion will be restricted to the association of emphysema and pulmonary fibrosis with pulmonary hypertension and chronic cor pulmonale

Symptoms and Signs Dyspnœa is the outstanding symptom It is, of course, a major clinical feature of both these disorders but with the advent of pulmonary hypertension it becomes progressively worse and ultimately incapacitates the patient Cough is frequently but not always present, and it is productive when chronic bronchitis or passive congestion of the lungs complicate the case When the right ventricle fails the systemic veins become more distended, the liver enlarges and often becomes tender, and œdema, ascites, oliguria, and sometimes nausea and vomiting occur

When the heart enlarges it is the conus arteriosus and right ventricle that are predominantly concerned, and the latter, occupying a greater proportion of the heart's anterior surface than is normal may give rise to visible and palpable pulsation in the third and fourth left intercostal spaces The pulmonary second sound is accentuated, and later gallop rhythm may be heard Less constant and very variable features are cyanosis, clubbing of the fingers and toes, and polycythæmia To these will be added the well-known symptoms and physical signs of the underlying pulmonary abnormality It will be observed that a majority of the clinical features of pulmonary hypertension are also features of emphysema and of certain pulmonary fibroses such as the pneumokonioses Only when failure

of the right heart develops, do distinctive symptoms and signs arise For this reason, the early recognition of pulmonary hypertension is greatly helped by radiological examination The distended pulmonary vessels can as a rule be seen spreading far out into the lungs, and the aggregate of major pulmonary vascular trunks at the hila are much more dominant a feature than is usual I am indebted to my colleague, Dr E Rohan Williams, for his demonstration that enlargement of the pulmonary artery near the hilum can often especially well be shown by radiography in the lordotic position Tomography also can demonstrate these dilated vessels beautifully

It has long been assumed that emphysema causes pulmonary hypertension and ultimately cor pulmonale by progressive obliteration of the capillaries within the lungs The major weakness in this hypothesis is the lack of correlation between the degree of emphysema and the accompanying cardiovascular change Parkinson and Hoyle (1937) (*Quart J Med*, 6, 59) summarize the historical background and set forth this difficulty so well that I need only cite this one report In the last ten years the part played by consecutive arteriosclerotic changes particularly in the pulmonary arterioles has been emphasized in several reports of which (Parker, R L (1940), *Ann intern Med*, 14, 795, and Gilmour, J R, and Evans, H (1946) *J Path Bact*, 56, 587) are noteworthy The last authors in a case of primary pulmonary hypertension reported aplasia or hypoplasia in innumerable small pulmonary arteries, and concluded that this deficiency was a factor leading to the later genesis of endarteritis and pulmonary hypertension From these reports it would seem likely that in emphysema associated arteriosclerosis in the pulmonary arterioles is a requisite for the development of cor pulmonale It is not yet clear to what extent in emphysema the obliteration of capillaries and hypertension from this source causes arteriolar sclerosis Cases occur in which pulmonary arteriosclerosis arises independently of any pulmonary disease or indeed of any known cause so that other factors may be concerned There are few if any comparable investigations in patients with pneumonokoniosis

It was thought worth while to investigate series of normals, of emphysema, and of pneumonokoniosis with and without pulmonary hypertension, and to compare the cardiac output, cardiac area, and lung volumes in these series in the hope that some correlation between the pulmonary pathology and the extent of the pulmonary hypertension might be found

Results

The results of the estimation of the cardiac output and lung volumes in 12 normal controls of similar ages to those of the cases of emphysema and fibrosis are set forth in Table I Basal conditions obtained throughout

Cardiac output showed a variation dependent on difference in size of the individuals, the cardiac index being nearly constant Mean C I =2 2 lit per sq metre probable error ±0 083 The cardiac area as determined by a planimeter from standard postero-anterior radiograms was 173 3±5 11 sq cm The value of the total pulmonary capacity and its subdivisions, the vital capacity and residual air, fell within the limits of normality in regard to both relative and absolute values of these quantities

Emphysema Fifteen male patients were investigated Their physical and clinical characteristics, the duration of symptoms, the signs, and the X-ray and cardiographic findings were recorded Their disability ranged from dyspnœa on moderate exertion to dyspnœa at rest Cyanosis, while the

TABLE I

NORMALS

Case	Cardiac output	Cardiac index	Cardiac area	T P C *	V C *	R A *	$\frac{RA}{TPC}\times 100$
1	3 70	1 74	204	7 08	5 80	1 28	18 1
2	4 26	2 23	168	6 57	5 30	1 27	19 3
3	4 38	2 11	202	5 27	4 19	1·08	20 5
4	2·47	1 44	191	6 56	4 90	1 66	25 3
5	3 56	1 99	189	5 46	3 95	1 51	27 7
6	5 04	2 93	128	4 66	3 48	1 18	25 3
7	4 46	2 13	152	7 80	5 70	2 10	26 9
8	4·06	2·06	181	7 10	5 10	2 00	28 2
9	3 92	2 20	133	4·47	3 20	1 27	28 4
10	3 14	2 11	145	3 76	2 64	1 12	29 8
11	5 38	3 18	193	4 31	2 95	1 36	31 5
12	4 71	2 35	187	8 56	5 73	2 83	33 1

* T P C, total pulmonary capacity, V C, vital capacity, and R A, residual air

TABLE II

EMPHYSEMA

Case	Cardiac output	Cardiac index	Cardiac area	T P C	V C	R A	$\frac{RA}{TPC} \times 100$
13	6 96	3 36	213	5 73	4 04	1 69	29 5
14	7 60	4 04	184	6 45	4 54	1 91	29 6
15	4 51	3 30	194	4 11	2 72	1 39	33 8
16	8 30	4 19	268	7 71	4 95	2 76	35 8
17	3 59	2·05	192	5 55	3 50	2 05	36 9
18	6 36	3 60	174	4 54	2 74	1 80	39 7
19	7 39	3 47	206	4 29	2 56	1 73	40 3
20	4 34	2 89	169	6 58	3 92	2 66	40 4
21	6 13	4 41	129	4 20	2 48	1 72	41·0
22	4 72	2 36	210	6 47	3 80	2 67	41 3
23	3 26	1 71	165	5 46	3 18	2 28	42 2
24	5 84	3 06	181	6 90	3 80	3 10	44 9
25	4 94	3 38	114	4 66	2 46	2 20	47 2
26	3 74	2 63	109	4 77	2 04	2 73	57 2
27	5 30	2 76	299	5 84	1 77	4 07	69 6

patient was resting, was present in eight, but clubbing of the fingers was noticeable in one patient only In two cases (16, 27) the chronic pulmonary disorder was complicated by hyperpiesis Pulmonary hypertension could be diagnosed in eleven cases, and cor pulmonale in five—as a result of an aggregate of the above and subsequent findings (Cases 13, 16, 17, 18, 19, 20, 22, 23, 24, 26, 27 and 13, 16, 19, 22, and 27 respectively)

In Table II the cases (as in Table I) are set forth in order of the severity of the emphysema as measured by the relative size of the residual air $\frac{RA}{TPC} \times 100$ No correlation could be found between this ratio and the estimated degree of pulmonary hypertension, nor with the incidence or severity of cor pulmonale when that was present

The cardiac output and index were as a rule higher than had been found in normal controls, and this was also true in cases with cor pulmonale

The cardiac area, apart from Cases 16 and 27, both of which had systemic hypertension, was essentially the same as that found in the normal controls, the mean cardiac area being 172 7±6 6 sq cm Vital capacity was reduced, residual air increased so that $\frac{RA}{TPC} \times 100$ was increased The total pulmonary capacity was not greatly abnormal

Fibrosis A similar investigation of 14 cases of pneumonokoniosis was undertaken Dyspnœa was an even more noticeable feature and cyanosis at rest was apparent in 9 cases

Six patients had been sand blasters, five coal miners, and one an iron moulder, while in two no recognized industrial hazard productive of pneumonokoniosis had occurred in their history The duration of exposure was noticeably short in those whose occupation had been sand blasting In four cases electrocardiography showed left ventricular preponderance and two of these presented evidence of systemic arteriosclerosis and a high blood pressure

In Table III the degree of pulmonary fibrosis varied from slight to very severe as judged radiologically, but the X-ray findings bore little or no relation to the patient's disability as measured by dyspnœa or to the ratio $\frac{RA}{TPC} \times 100$ In five (Cases 30, 37, 39, 41) pulmonary hypertension could be diagnosed and in two (Cases 30 and 37) cor pulmonale was present Again there was no correlation to be found between the severity of the respiratory disorder as measured by $\frac{RA}{TPC} \times 100$ and the observed consecutive cardiovascular abnormality or between the latter and the radiological extent of the disease Cardiac output was often raised and this was true also in those with cor pulmonale The mean cardiac area (excluding the two cases with systemic hypertension) was 185 8±4 9 sq cm which showed a slight statistically significant increase as compared with the normals

The total pulmonary capacity was decreased as a result of a marked decrease in the vital capacity, the residual air being absolutely and relatively increased.

These results confirm previous findings that correlation is lacking between the severity of emphysema and the associated degree of pulmonary hypertension and cor pulmonale They also show a similar lack of relationship to obtain in cases of pneumonokoniosis—which has not previously been reported

TABLE III

FIBROSIS

Case	Cardiac output	Cardiac index	Cardiac area	T P C	V C	R A	$\frac{RA}{TPC} \times 100$
28	4 54	2 40	161	2 88	2 20	0 68	23 6
29	3 81	2 25	237	5 32	3 87	1 45	27 2
30	5 28	3 03	203	4 58	3 16	1 42	31·0
31	7 48	3 84	168	4 36	2 68	1 68	38 5
32	2 92	1 90	155	4 01	2 30	1 71	42 6
33	4 77	3 11	183	3 99	2 24	1 75	43 8
34	2 87	1 95	180	2 75	1 54	1 21	44 0
35	4 89	3·09	168	4 12	2 18	1 94	47 0
36	4·68	2 56	157	4 33	2 22	2 11	48 7
37	4 77	2 69	222	4 35	2 18	2 17	49 9
38	2 98	2 07	176	7 20	3 24	3 96	55 0
39	6 13	3 29	306	3 55	1 50	2 05	57 7
40	8 98	6 36	170	4·48	1 68	2 80	62 5
41	6 25	3 80	282	3 89	1·06	2 83	72 7

In both emphysema and pneumonokoniosis progressive obliteration of small pulmonary vessels occurs which could theoretically ultimately cause pulmonary hypertension In both disorders the distruction of available effective alveolar surface for oxygenation could give rise to decreased arterial oxygen saturation of the blood and so in turn theoretically cause a "work hypertrophy" and ultimately failure of the heart In neither disease, however, can the severity of the pathological process be directly related to the observed associated cardiovascular change, and therefore it seems probable that when pulmonary hypertension or cor pulmonale develops some other causal factor, unrelated to the primary pulmonary disease, must be present

ELECTROCARDIOGRAPHIC APPEARANCES IN ACUTE AND CHRONIC PULMONARY HEART DISEASE

BY PAUL WOOD, London

An analysis of the electrocardiographic appearances in 20 cases of massive pulmonary embolism with raised jugular venous pressure was presented Limb leads showed an almost constant S wave in lead I, frequent Q wave in lead III, inversion of T III, flattening or slight inversion of T II, and rather low voltage Occasionally P II was tall and sharp Multiple chest leads revealed inversion of T from V I to V 3 or 4 in all, reversion to normal taking three to six weeks Transient right bundle-branch block occurred in three The changes were attributed to acute right ventricular stress

In 100 cases of chronic pulmonary heart disease, limb leads showed a tall sharp P wave in 85, right axis deviation in 46, a tendency to right axis deviation in 11, a prominent S wave in all leads in 9, right bundle-branch block in 4, and low voltage in 40 Multiple chest leads showed normal ventricular deflections in the majority, inversion of T from V 1 to V 3 occurred in only 13 per cent and a chiefly upright QRS complex in V 1 with a conspicuous S wave in V 5 was seen in only 16 per cent In another 16 per cent of cases anterior chest leads from V 1 to V 5 revealed a fixed RS pattern with S dominant It was concluded that the tall spiked P wave was by far the most significant change.

The rest of the communication summarized the author's investigations into this P wave In normal controls the maximum auricular deflection very rarely measured more than 1 5 mm in amplitude and averaged 1 mm The pulmonary P wave commonly ranged between 2–3 mm in height, but was never widened It was never seen in normal vertical hearts which refuted the suggestion that it depended on cardiac rotation due to emphysema It could not be attributed to anoxia for it was an early finding and tended to diminish in voltage when anoxia became severe, nor was it present in cases of severe anæmia It could not be ascribed to an elevated cardiac output, for it was seen in a much less conspicuous form in cases of thyrotoxicosis in which the cardiac output was considerably higher, moreover, as already mentioned, P was of low voltage in severe chronic anæmia with outputs up to 14 litres a minute Intracardiac pressure studies failed to reveal any correlation between this P wave and the right auricular pressure, but there appeared to be some association between it and the right ventricular pressure Just on what such a relationship might depend was unknown

THE CLINICAL VALUE OF CHEST LEADS

September 10, 1947, afternoon Section of Cardiology

By Frank N Wilson,* Ann Arbor, Michigan

In the growth of electrocardiography as a clinical method, British physiologists and physicians have played a more important role than those of any other nationality Waller was the first to show that the electrical activities of the human heart could be recorded by leading from the extremities or from the surface of the chest Mackenzie, although he did not deal directly with this subject, tremendously increased our knowledge of clinical disorders of the rate and rhythm of the heart beat and aroused a world-wide interest in this field Thomas Lewis contributed more than any other man to the development of the principles and methods of analysis upon which the interpretation of the electrocardiogram is founded Most of my own electrocardiographic studies have been the result of ideas derived from his investigations, and I am also deeply indebted to him for help and encouragement on many occasions I consider it a very great honour to be asked to discuss an important aspect of clinical electrocardiography here in his native land and in this great city where his work was done It would have been a still greater pleasure to come here if he were still living and could take part in this discussion

It was the work of Lewis and Rothschild on the spread of the excitatory process that first aroused my interest in the possibility of exploring the anterior ventricular surface by placing one electrode on the præcordium and the other far from the heart The observations and ideas contained in their paper and notions derived from a study of the physical principles upon which the work of Einthoven and that of Waller on the electrical axis of the heart is clearly founded led to a series of investigations concerned with the character of the heart's electrical field These investigations were first undertaken late in 1919 and were continued off and on through the early twenties A preliminary report to the effect that præcordial leads of the kind mentioned are semi-direct leads very similar to the unipolar direct leads first used by Lewis and Rothschild was published in 1926, but the systematic use of multiple leads of this sort at the University of Michigan dates from the summer of 1929 It was precipitated at that time by the observations on bundle branch block by Barker, Macleod, and Alexander, and was undertaken with the purpose of obtaining additional data bearing on their conclusions A preliminary report of this work was published in 1930, the final report came out in 1932, and was nearly simultaneous with the paper on the use of a single chest lead in the diagnosis of infarction by Wolferth and Wood Since that time the percentage of cases in which præcordial leads are employed has steadily increased We have never taken præcordial leads routinely

For the purpose of studying disturbances of the rate and rhythm of the heart beat, or of the time relations and sequence of auricular and ventricular activation, unipolar chest leads are only occasionally better than limb leads, and are not in general superior to bipolar chest leads of the kind used by Lewis in his studies of auricular fibrillation, and are much less useful than œsophageal leads They have not thus far proved to have any special advantages in the study of the form of the auricular complex On the other hand, chest leads and particularly unipolar leads from the præcordium, are indispensable for the detection and differentiation of abnormalities of the ventricular complex They frequently disclose abnormalities of the QRS group, the T complex, or both, when the limb leads show either no deviation from the normal or none that have diagnostic significance On this occasion, it will suffice to consider only those conditions in which the value of unipolar præcordial leads has been most clearly demonstrated It should, of course, be clearly understood that clinical diagnosis should seldom, if ever, be made on the basis of electrocardiographic findings alone To rely solely upon an interpretation of the electrocardiogram that is not supported by the case history or other clinical data after an adequate investigation has been made frequently means to run the risk of converting an essentially normal person into a psychoneurotic invalid

Præcordial leads are of value, first of all, in the recognition of abnormalities affecting the intraventricular conduction of the cardiac impulse They make it possible in the vast majority of the cases in which the QRS interval measures 0 12 second or more to ascertain whether one is dealing with right bundle branch block, left bundle branch block, arborization block, Wolff-Parkinson-White

* Working under a grant from the Kresge Foundation, University of Michigan

syndrome, or a conduction defect not belonging in any of these catagories Intraventricular conduction defects that produce a less striking increase in the QRS interval are somewhat more difficult to differentiate, but præcordial leads often disclose the presence of incomplete right branch block when the ventricular complexes of the limb leads are not distinctly abnormal They also make it possible in many instances to recognize such combinations as complete or incomplete right branch block plus right ventricular hypertrophy or myocardial infarction, and left bundle branch block plus left ventricular hypertrophy The electrocardiographic diagnosis of left bundle branch block plus infarction is in our experience rarely possible Incomplete left branch block is difficult to distinguish from the effects of preponderant hypertrophy of the left ventricle Many have expressed the opinion that all defects in intraventricular conduction have the same clinical significance and that it is not worth while to attempt to differentiate one from another The answer to this objection is that we cannot tell whether it is valid until the differentiation in question can be made with reasonable certainty In the past this has not been possible, and the older studies of the significance of the different varieties of intraventricular block which were based on limb leads can no longer be considered definitive There are some clinical disorders that produce one type of intraventricular block exclusively or much more often than any of the others Right bundle branch block is common in pulmonary embolism, Chagas disease, infarction of the ventricular septum, and congenital cardiac anomalies in which the septum is defective, left branch block does not occur at all in some of these conditions and is rare in others True arborization block is usually, if not always, a consequence of old infarction

In the second place, præcordial leads are of very great value in the diagnosis of preponderant hypertrophy or enlargement of one ventricle, and particularly in the diagnosis of preponderant hypertrophy or enlargement of the right ventricle The last is not infrequently induced by pulmonary hypertension, which is often difficult to detect by clinical means The systematic electrocardiographic study of all cases of heart disease of obscure origin will disclose many cases of unsuspected cor pulmonale Many patients with congenital heart disease are now candidates for cardiovascular surgery The use of præcordial leads in such cases frequently yields valuable evidence bearing on the presence or absence of suspected or unsuspected complications It is now clear that the position of the mean electrical axis of the QRS deflections is determined not by the relative weight or size of the two ventricles, but by the position of the heart in the chest This is not wholly determined by the nature of the cardiac lesion present Thus it is possible to have right axis deviation in a case of preponderant enlargement of the left ventricle or left axis deviation associated with preponderant enlargement of the right ventricle

Finally, chest leads find their greatest field of usefulness in the diagnosis of myocardial infarction, and I have seen a great many instances in which this condition was certainly present and not recognizable by any other method There are a great many infarcts of the less extensive sort that can be easily recognized if præcordial leads are taken, and nevertheless give rise to no constitutional symptoms whatsoever and to only the most trivial complaints The infarcts that are least likely to produce characteristic changes in the limb leads but regularly give rise to such changes in præcordial leads are those that involve the anterior part of the ventricular septum and adjacent parts of the anterior wall of the left ventricle We speak of these as anteroseptal infarcts Other types of infarcts that produce more striking changes in præcordial leads than in the limb leads are those associated with right bundle branch block, which usually involve the upper ventricular septum, those that for some reason give rise to small bizarre deflections in all of the standard limb leads, and certain posterior or high lateral infarcts It is desirable to take præcordial leads in all cases in which myocardial infarction is considered a possibility and in all cases in which symptoms of cardiac weakness or cardiac failure develop rapidly without obvious cause If this is done many instances of clinically undiagnosed examples of infarction will be discovered

In considering abnormalities of the form of the ventricular complex, particularly those of a nonspecific kind, it is necessary to ask one's self whether they are the result of (1) a minor congenital anomaly, (2) some long past illness which has left behind an anatomic or physiologic scar, (3) an acute process, such as acute myocarditis, myocardial infarction, pericarditis, or toxæmia, or (4) a slowly progressive degenerative condition such as coronary atherosclerosis Perhaps a fifth possibility, derangement of the vegetative nervous system should be added In reaching a decision it is often necessary to repeat the electrocardiographic examination at intervals over a considerable period If the electrocardiographic changes persist unchanged, they should not be ascribed to an acute process It is also imperative that the final conclusions be based on a careful scrutiny of all the clinical and laboratory data available, and not upon the electrocardiogram alone

By C W Curtis Bain

This communication has been published in fuller form (Brit Heart J, 1948, 10, 9)

By Terence East

After hearing Dr Wilson's address and studying his writings, it is clear that unipolar leads can afford valuable information, more clear than any hitherto available The difficulty is that the full electrical exploration of the heart may involve the taking of so many records If one uses the three standard, the six unipolar chest, with perhaps an abdominal or epigastric, the three unipolar limb leads and, possibly, other thoracic and an œsophageal lead, one may end by taking some fifteen or sixteen tracings For ordinary clinical practice this is too many, time does not permit such elaboration, one must now begin to consider whether a new approach may not be adopted which will reduce the initial number of leads used further exploration can be done to elucidate details, but it might be possible to cut down the number taken at first, or perhaps select special leads suitable for obtaining special information This seems more logical than just using the standard leads and one or more præcordial leads at random This method must surely become obsolete in the near future

Definite information can be sought from the cardiogram on the following points The answer is often final and conclusive

1 Auricular activity. This is essential in the interpretation of most of the arrhythmias, especially circus movements, and in the study of auriculo-ventricular conduction
2 Intraventricular conduction and bundle branch block
3 Indication of unilateral or bilateral ventricular hypertrophy and strain
4 The position of the heart
5 Pathological changes in the myocardium, in particular ischæmic disease, and the detection and localization of infarcts, and also unspecific minor variations from the normal
6 Pulmonary embolism and infarction This might come under heading 3
7 Pericarditis, with or without effusion

To a certain degree the three standard leads have for long revealed a good deal on these points, the addition of chest leads was the first extension into further fields of exploration The choice of chest contacts is wide, both in site of application, and also whether a unipolar or paired technique should be used It would appear that there are good reasons for employing the unipolar præcordial technique rather than using a distal electrode on the right arm or left leg There are also good reasons for using unipolar limb leads, rather than the standard, for thereby true single changes of potential are recorded rather than the differences between two Apart from the six præcordial contacts, running from right to left, there are others that have been proposed One of the most promising was the right upper abdominal, which, by a high positive deflection, might be useful as an indication of hypertrophy of the right ventricle This is not the case, for it has been found that such deflections are given in this lead by vertical hearts, which are actually normal One might suggest that a practical solution of the difficulties arising from the taking of so many leads is to select the following, for the reasons that are appended

Lead V 1

1 This will show auricular waves, and be useful for circus movements, auricular tachycardia, and for measuring auriculo-ventricular block
2 A large R and small S will show right ventricular hypertrophy
3 The position of the intrinsic deflection in a prolonged QRS will diagnose the site of bundle branch block
4 The size of the normally negative deflection will show the position of the heart

Lead V 4 (*or* V 5) The one selected depends on the size of the heart, it should be just outside the apex beat (V 6 or 7 might on occasion be needed)

1 Hypertrophy of the left ventricle is shown by the large R and no S wave T may be negative (as in standard lead I) Digitalis effects are shown
2 Anterior infarcts are shown by Q and changes in RS–T junction and T waves
3 Bundle branch block location is confirmed by the position of the intrinsic deflection in a prolonged QRS
4 Possibly changes due to pericarditis

Lead VL (The unipolar left arm lead)

1 This may reveal some lateral infarcts
2 The position of the heart is shown, particularly when vertical, the normally positive leads becoming small or negative
3 One might expect changes due to pericarditis

Lead VF (The unipolar left leg lead)

1 Posterior infarcts are shown
2 The changes of pulmonary infarction are detected

3 The position of the heart is shown, particularly when horizontal

4 One might expect changes due to pericarditis

By giving the third strip on the film two separate exposures V L and V F can be shown consecutively, and all four leads will then appear on one film It is intended to adopt this selective technique on a series of cases, controlled by the standard leads, to determine whether the latter can ultimately be dropped altogether It may at any time be desirable to amplify the preliminary data obtained by such an approach with full electrical exploration of the heart, using such additional leads as may seem indicated

By Camille Lian, Paris

After the very interesting communication of Dr Wilson and Dr Bain, I shall only say a few words about two chest leads that I have specially studied

First, the auricular lead which I have named S 5, the right arm electrode is placed on the middle of the sternal manubrium and the left arm electrode on the anterior extremity of the fifth right intercostal space In this way, the auricular waves are well recorded even when they are invisible in the limb leads For the same purpose, I have recently employed with success the well known chest leads CF 1 and V 1, but the chest lead S 5 gives better results

For another purpose, I have used the chest lead BF (back-foot) or VB (back-central terminal of Wilson) After placing the exploring electrode in the standard position, 1, 2, 3, 4, etc , I place it midway between the left scapula and the spine, two fingers above the inferior angle of the scapula In this lead, the T wave is negative in healthy subjects

As you know, in cases of coronary disease giving the T III type of curve in limb leads, the T wave generally keeps its normal direction in standard chest leads But these same cases generally show a reversal of T wave in the chest lead BF or VB, taken as described, that is to say the normally negative T wave becomes positive

Therefore, in a case presenting an inverted T in lead III, this special chest lead may be informative, for if the inverted T III is due to coronary occlusion, the chest lead BF generally shows a reversal of T, that is a positive instead of a negative T wave The chest lead BF of VB can thus be useful in cases presenting the T III type of electrocardiogram

THE USE OF THE PHONOCARDIOGRAPH IN CLINICAL CARDIOLOGY

September 11, 1947 Section of Cardiology

By William Evans, London

The phonocardiograph was born soon after the electrocardiograph, but their growth has been unequal in that the latter has been applied immediately to clinical medicine and has flourished while the former test, used to display such murmurs as the presystolic and the one identified with patent ductus arteriosus, has become largely exhibitional and for that reason has lost ground More recently, however, phonocardiography has shown signs of coming into its own, and he now predicted for it a place in cardiology not far behind electrocardiography He proposed to show some of the ways in which the test had already contributed to our knowledge and to point the way in which it could be usefully developed in the future

In the first place, it had confirmed the clinical classification for *Triple Heart Rhythm* Such a classification had become necessary owing to the confused terminology connected with this rhythm All cases of triple heart rhythm fall naturally into three groups First, from addition of the third heart sound which immediately follows the second sound, secondly, from addition of the fourth heart sound which immediately precedes the first heart sound, and thirdly, from addition of a sound in late systole This third variety was an innocent condition and only assumed importance in its differentiation from the presence of the third heart sound

The first kind of triple heart rhythm was found in healthy subjects and in those conditions that produce right heart failure this included mitral stenosis, hypertensive heart failure, emphysema, pulmonary embolism, primary pulmonary hypertension, auricular septal defect, constrictive pericarditis, cardiac infarction, and anæmia He spoke briefly about each of these forms of triple heart rhythm

The second variety from addition of the fourth heart sound was found in prolonged A-V conduction or in left ventricular heart failure as in hypertensive heart failure, aortic, incompetence and failure, and in cardiac infarction

Turning to *Heart Murmurs*, he stressed the importance of the phonocardiograph in confirming the reliability of certain clinical signs which had been assembled for the differentiation of innocent heart murmurs into five main varieties, and he outlined such signs Concerning the murmurs of organic heart disease he mentioned how common it was for the phonocardiograph to show that the systolic murmur of mitral disease actually occurred during auricular systole as in the case of the presystolic murmur The mid-diastolic murmur of mitral stenosis was even more important in the light of this newer test, so that in 74 cases of undoubted mitral stenosis the test had shown the presence of this murmur in all of them, but more cases need to be tested before one could say that it was an invariable finding He then dealt with the murmurs of aortic valvular disease, hypertension, congenital heart disease, anæmia, and heart block

Dr Evans believed in the importance of the test not only for research purposes but also for clinical diagnosis in specific instances The test had come to stay We would not be able to live without it and for the good reason that our patients would not be able to live so well without it

In conclusion, he stressed three things in clinical auscultation First, the advantage to clinical diagnosis of finding and placing the added heart sound which created a triple heart rhythm Secondly, that the quality and intensity of murmurs matter far less than their place in the cardiac cycle and in relation to the heart sounds Thirdly, and above all else, the phonocardiograph had emphasized the importance of self catechism during clinical auscultation He mentioned six questions which should be applied when the bell of the stethoscope rested on any part of the chest in the search for heart disease

By Camille Lian, Paris

I appreciate the honour of being invited to attend this International Conference and to address the Section of Cardiology I have been specially interested in phonocardiography for many years and, together with a distinguished qualified engineer, Mr Minot, have succeeded in designing an original

phonocardiograph, known in France as the Lian-Minot Telestethophone With this apparatus it is possible to record the heart sounds while actually hearing them reproduced by loud-speaker, a feature of capital importance The electrocardiogram and the apex impulse can be recorded simultaneously with the heart sounds

I propose to speak to-day about triple rhythm which I regard as the principal indication for employing phonocardiography in the clinic

I shall first consider *that variety of triple rhythm in which the second sound is single, and where we have to distinguish between gallop rhythm and a reduplication of the first heart sound* (Fig 1 and 2) The clinical diagnosis is usually easy—in gallop rhythm, the extra sound is separated from the first heart sound by a silent interval, but there is no silent interval between the two constituents of a reduplicated first sound However, I have established by phonocardiography that, exceptionally, this silent interval between the gallop sound and the first sound is lacking, and I have described this particular phenomenon as *delayed presystolic gallop* (galop présystolique retarde) (Fig 3) In this case, the clinician is likely to make the serious error of mistaking a gallop rhythm, which signifies left ventricular failure, for a reduplicated first sound which is a sign of little importance *Here the phonocardiograph triumphs over the stethoscope* In the phonocardiogram, if the first constituent of the double sound precedes the summit of the R wave of the electrocardiogram, then we are dealing with a presystolic gallop If, on the other hand, both constituents of the double sound fall after the summit of the R wave, then we are dealing with a reduplication of the first heart sound

These remarks apply to records obtained by *the Lian-Minot phonocardiograph which is not sensitive to vibrations of low frequency, for its curve of sensitivity is almost identical with that of the human ear For this reason, in my phonocardiograms of healthy subjects, no part of the vibrations belonging to the first sound occurs before the summit of the R wave of the electrocardiogram* Recently, in the United States, Rappaport and Sprague have supported the view that a phonocardiograph should have the same curve of sensitivity as that of the ear Contrary to the opinion of the Argentine authorities, they consider, as I do, that the vibrations constituting the normal first heart sound never occur earlier than the summit of the R wave of the electrocardiogram Therefore, both components of a reduplicated first sound are always later than the summit of the R wave I have also established, both clinically and by phonocardiograph, that there are *arterial reduplications of the first sound*, for aortic or pulmonary vibrations of appreciable magnitude are added to the ventricular vibrations which constitute the first sound In these arterial reduplications there is a protosystolic snap of maximum intensity at the right or left second or third intercostal space

I now come to *the second variety of triple rhythm in which the first sound is single Here the diagnosis lies mainly between a reduplication of the second sound and the triple rhythm of mitral stenosis* I say this because I have established both clinically and by phonocardiography that *the triple rhythm of mitral stenosis is constituted not by a reduplication of the second sound but by the opening snap of the mitral valve* (Fig 4)

Triple rhythm in mitral stenosis may also be due to an initial reinforcement of the diastolic murmur, which is characteristic, or sometimes to a reduplication of the second sound which is not characteristic as it occurs in many other conditions It is therefore important to distinguish a reduplicated second sound, which is not peculiar to mitral stenosis, from the opening snap of the mitral which is quite characteristic (Fig 5)

I give the following rules for making this distinction On auscultation, a reduplicated second sound is best heard in the second or third left intercostal space, and the mitral opening snap in the fourth or fifth left space, or less often near the apex I have also found that a reduplicated second sound is inaudible immediately above the sternum (namely, in the suprasternal notch), while the opening snap is often audible at this site

In phonocardiography, I prefer to record the apex impulse electrically, as can be done by the electrokymograph of the Lian-Minot apparatus In such records, the second constituent of a reduplicated second sound occurs during the descent of the apex curve, between points C and D The mitral opening snap occurs at point D, and the initial reinforcement of the diastolic murmur, still later, at point E

It is not essential to record the apex impulse in order to identify these three varieties of triple rhythm, for it can also be done by measuring the time interval between the second heart sound and the extra sound In the case of a reduplicated second sound, the extra sound occurs from 0 03 to 0 07 sec after the commencement of the second sound In the opening snap of the mitral, this interval is 0 07 to 0 11 sec, and in the initial reinforcement of the diastolic murmur it is 0 10 to 0 17 sec

In the diagnosis of mitral triple rhythm, there are several other possible sources of error to be considered There is the snap I have described as the *late systolic pleuro-pericardial snap* (Fig 6) which

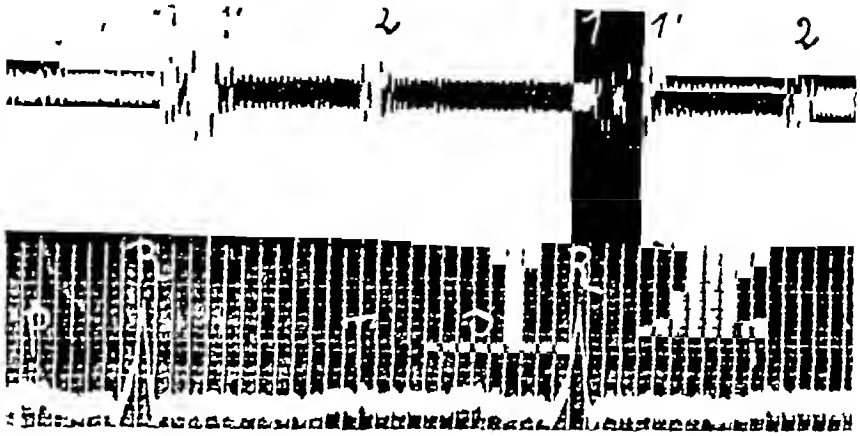

FIG 1 —*Reduplication of the first sound* The two groups of vibrations constituting the first sound both occur after the summit of the R wave in the electrocardiogram

FIG 2 —*Presystolic gallop rhythm* The gallop sound coincides with the termination of the P wave in the electrocardiogram (three leads recorded simultaneously), and it is separated from the first sound by a silent interval



FIG 3 —*Retarded presystolic gallop rhythm* The gallop sound coincides with the termination of the P wave There is no silent interval between the gallop sound and the first heart sound

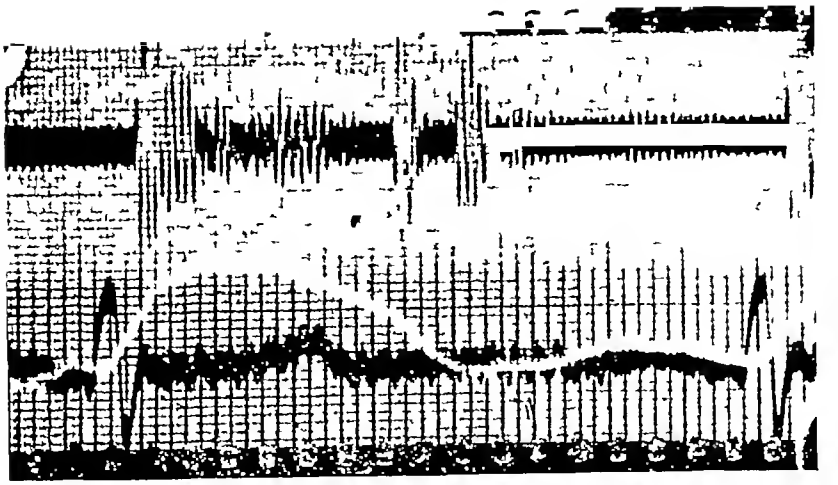

FIG 4 —*Mitral opening snap* Above, the phonocardiogram, below, in white, the apical electromyogram, and in black the electrocardiogram The record shows, in succession, the first sound, a systolic murmur, the second sound, and finally the opening snap of the mitral The second sound coincides with the start and the opening snap with the termination of the descending limb of the apical cardiogram The snap begins 0 07 seconds after the start of the second sound



FIG 5 —*The complete phonocardiogram of a case of mitral stenosis*

(A) Above, phonocardiogram taken from the fourth left interspace, and below it, the apical electro myogram in black, and the electrocardiogram in white These show the two elements of the reduplicated second sound which coincide with the start of the descending line CD of the apical cardiogram, then the mitral opening snap (CO), which coincides with the base of the descending line at D

(B) Below phonocardiogram taken from the apex, in the left lateral decubitus It shows successively the first sound, the second sound, the snap (CO) which is slight, and the diastolic rumble (Rd) with its initial protodiastolic accentuation There is no presystolic accentuation owing to the presence of auricular fibrillation

These two tracings were taken at the same time and from the same patient

depends on an adhesion between the left pleura and the pericardium In 10 per cent of such cases, there is also a *late systolic murmur* between the snap and the second sound I have seen many cases in which the diagnosis of mitral stenosis was mistakenly made, simply on account of this late systolic snap, which is of no importance The clinical recognition of this snap is not very difficult and with the phonocardiograph it is very easy

The diagnosis between mitral triple rhythm and a *protodiastolic gallop* (Fig 7) is not usually difficult as other signs of left ventricular failure accompany the gallop

More difficult to distinguish from mitral triple rhythm is *the physiological third heart sound,* often heard in young subjects It is usually intermittent If it is permanent, the patient should be instructed to hold his breath after a deep inspiration, when the third heart sound will disappear immediately, a characteristic phenomenon

Lastly, we must distinguish between mitral triple rhythm and the sign which I have described as *the isodiastolic or protodiastolic pericardial snap* (Fig 8) of adhesive pericarditis This sound is heard at the same site as the mitral opening snap but it is louder When it is very loud, you may safely make the diagnosis of calcified pericardium

In conclusion, I hope that I have shown you the great interest that attaches to phonocardiography in the study of triple heart rhythm



Claquement Telesystolique

Bruitement Telesystolique

FIG 6 —*Telesystolic snap and murmur* due to left-sided pleuro-pericardial adhesions Above, the snap (C) situated between the first and second sounds, and nearer to the second Below, the snap (C) is not pronounced, but the late systolic whining murmur is well shown between the snap and the second sound

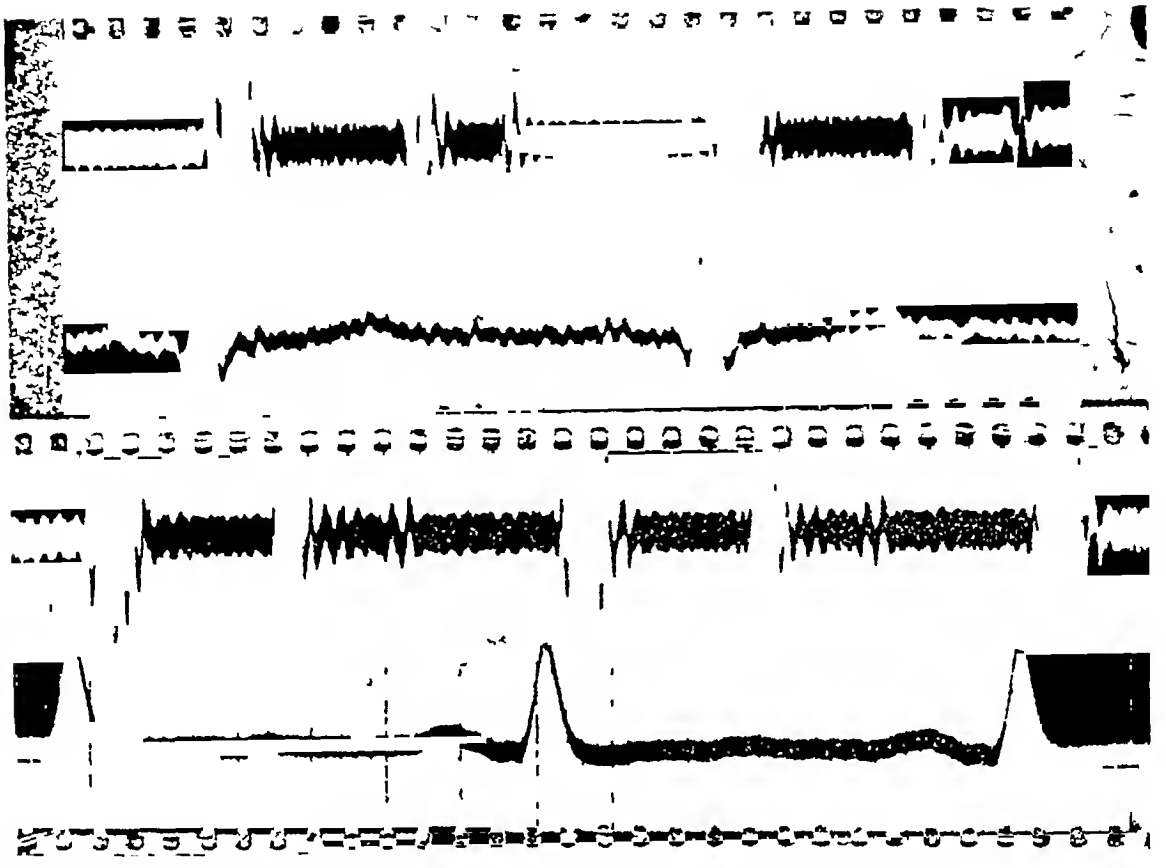

FIG 7 —*Third heart sound and protodiastolic gallop* Above, a third sound begins 0 13 seconds after the onset of the second sound Below, a protodiastolic gallop sound begins 0 15 seconds after the onset of the second sound The two records belong to different patients, but the phonocardiographic appearances are similar

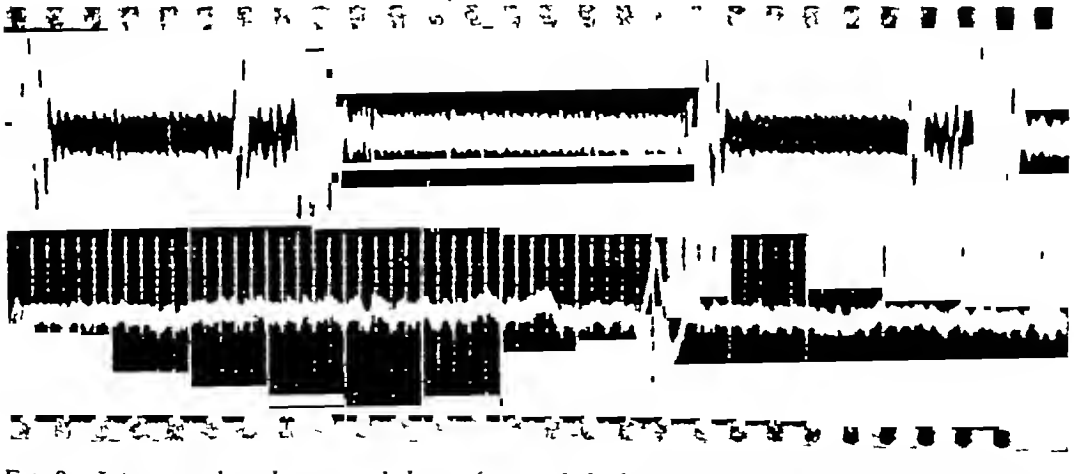

FIG 8 —Intense *isodiastolic pericardial snap* (pericardial vibration) in a case of calcified pericardium The snap occurs 0·08 seconds after the onset of the second sound, and is therefore isodiastolic The vibrations are of far greater amplitude than those of the second sound

Professor CRIGHTON BRAMWELL (Manchester) said how much he appreciated the privilege of hearing the communication of Professor Lian, an acknowledged master in this subject

He then referred to certain difficulties which he himself had encountered in recording the heart sounds In phonocardiography there were two distinct objectives One was to obtain a true record of the heart sounds and murmurs, the other to determine their time relation to the events of the cardiac cycle The second of these was relatively easy, but the first was much more difficult, because the sound picture was apt to be contaminated by instrumental artifacts Wigger's optical method of recording heart sounds, employing a delicate rubber membrane and a very light mirror, was quite adequate for timing murmurs but did not give a true sound picture Professor Bramwell showed a phonocardiogram taken from a patient with mitral stenosis and partial heart block The murmurs in this case differed from cycle to cycle and would have been difficult to interpret without a graphic record In cycles in which the P–R interval was prolonged the presystolic murmur died away before the first heart sound When the ventricle failed to respond there was a loud murmur but no first sound, and in the cycles in which the P–R interval was normal there was no murmur Clinically the reason for this was obscure but the record indicated that it was due to the fact that these cycles followed a missed beat The auricle had already discharged its contents into the ventricle and when it contracted a second time the ventricle was already so full that the blood flow through the mitral orifice was not sufficient to produce a murmur

He had used this method also for recording arterial sounds during deflation of the armlet in the estimation of blood pressure These observations had revealed an important artifact, namely that if the pick-up is connected to the recorder by a tube, vibration of the air in the tube will distort the record As in the case of an organ pipe, the frequency of vibration varies inversely with the length of the tube This error is apt to contaminate all records in which air conduction is employed

To obtain a true sound picture electrical conduction should be used since it is instantaneous Further both pick-up and recorder must have a natural frequency higher than that of the vibrations which one wishes to record

With this in mind he had used a Matthews' oscillograph in conjunction with a condenser microphone Both these instruments have a natural period of over 10,000 a second which is well above the frequency of even the higher harmonics of the heart sounds That this instrument does give a true sound picture is proved by the fact that the records are identical in form with those obtained with a cathode ray oscillograph which has no inertia This apparatus is excellent for research purposes, but is somewhat temperamental, and it was only by having the collaboration of an expert physicist that he had been able to obtain consistently good results For routine clinical work we want an instrument that is more fool-proof, like that of Lian and Minot or the Sanborn Stetho-cardiette

Whereas the timing of heart sounds and murmurs by means of phonocardiography was easy, to obtain a true picture of the sound vibrations was more difficult, since the record was apt to be contaminated by instrumental artifacts Both pick-up and recorder should have a natural frequency higher than that of the vibrations of the heart sounds and murmurs, and transmission should be by electrical and not by air conduction For routine clinical work the instrument must be fool-proof

SHORTER COMMUNICATIONS

September 12, 1947 Section of Cardiology

The Septal Anastomosis of the Coronary Arteries

By Prof Laubry, Paris

No summary available

Repetitive Paroxysmal Tachycardia

By John Parkinson and Cornelio Papp, London

The name " repetitive " is here applied to a special variety of paroxysmal tachycardia in which brief paroxysms separated by sinus beats constantly recur over months or years

Forty new cases of repetitive paroxysmal tachycardia have been collected, half of them with prolonged observation periods up to 18 years Ages from 4 to 75 years with two-thirds of the patients (including seven children) under 40 years of age, males predominate Of the 40 cases, only 3 had organic heart disease , 2 gave a rheumatic history but had no heart disease, 3 had toxic goitre

The usual symptom was palpitation, and four patients with ventricular paroxysms also had syncopal attacks Fourteen patients, including seven children, were symptomless

The only clinical sign was the peculiar irregular pulse

Diagnosis was based on a particular kind of electrocardiogram recorded at numerous successive examinations This almost always showed short paroxysms of tachycardia separated by normal sinus beats (paroxysmal tachycardia type), occasionally runs of multiform extrasystoles (extrasystolic type), more frequently both types together (mixed type)

The abnormal rhythm was divided as follows

(a) Repetitive auricular paroxysmal tachycardia, 24 cases —16 of the paroxysmal tachycardia type, 3 of the extrasystolic type, and 5 of the mixed type The average rate was 150 in children and 130 in adults

(b) Repetitive auricular *flutter*, 5 cases, 3 with irregular auricular rhythm (impure flutter), one with probable fibrillation

(c) Repetitive *nodal* paroxysmal tachycardia, 2 cases

(d) Repetitive *ventricular* paroxysmal tachycardia, 9 cases —7 of the paroxysmal tachycardia type with normal beats separating the runs, 2 of the mixed type

Repetitive paroxysmal tachycardia provides a connecting link between extrasystoles and paroxysmal tachycardia The extrasystolic runs are always irregular and so are the shorter runs of paroxysmal tachycardia, but the longer runs of the latter type are as regular as ordinary paroxysmal tachycardia though somewhat lower in average rate

This paroxysmal state is uncertain in its duration, but it often subsides In children it may cease at adolescence, in adults it may last for years and then disappear as it did in 8 of 14 cases long observed The prognosis as regards disability and length of life is good both in the auricular and ventricular form, though there are exceptions Digitalis is rarely effective, quinidine occasionally controls the ventricular form Repetitive paroxysmal tachycardia may be regarded as a distinctive disorder of rhythm rather than a cardiac disease of consequence

Sympathectomy for Hypertension

By Geoffrey Bourne, London

Dr Bourne said that he proposed to limit his remarks to the pathology of the condition and to try, from the information that was available, to stimulate a discussion as to whether sympathectomy was valuable, and at what stage of the disease it should be done

The approach to that question had hitherto been very largely empirical, various observers had stated that in females from twenty to thirty the results were good, from thirty to forty not so good, and after fifty on the whole rather bad, but he felt that an attempt to decide this in terms of the numerical

years of a patient's life was unscientific because a man was as old as his arteries, and many people's arteries were very much younger than their years There had been no real, comprehensible pathological basis explaining why it was that hypertension occurred The only satisfactory experimental work had been that of Goldblatt, and the theories of hypertension had, since then, been very largely founded upon the renin hypothesis

Within the last few months there had, however, emerged further work which might have considerable implications, and that was the work of Trueta and his colleagues at Oxford They had been able to produce an experimental ischæmia in rabbits by stimulation of the nervous system, this ischæmia was one of the cortex of the kidney, and could be produced in the absence of any organic disease It was possible that human hypertension in its early stages might be due to a similar phenomenon Trueta and his colleagues had also shown that the same cortical blanching might be produced by various other means, some of them biochemical, and their second point was that synchronously with this cortical blanching of the kidney there was in fact developed a secondary renal circulation which allowed the blood to be short-circuited back into the kidney without ever having passed the cortex This had been proved by injection methods and by seeing arterial blood pulsating in the renal vein during the course of their experiments on animals They had found that animals did not all react in the same way, and also had some evidence that although the stimulus was largely through the nervous system it might be brought about by large doses of posterior pituitary extract

During the early 'teens the boy or girl liable to hypertension had a blood pressure that was easily raised by emotion, but as the years went by there was a more permanent increase in the systolic and diastolic figures, and round about the age of forty there was developed the clinical case of persistent hypertension In the earlier stages there was a possibility of reducing the raised blood pressure temporarily to normal by the use of sedatives or by rest in bed or starvation, and many of the other means that had been employed hitherto in the treatment of hypertension, but after a variable time the factor of arterial degeneration was superimposed, so that in addition to spasm the hypertension was partially due to organic vascular renal disease Cortical spasm alone might well be the actual cause of hypertension in the younger, and a mixture of spasm and permanent renal disease in the older group

He described one similar to many hundreds seen by others, of a man of 37 years of age who, at 15 and at 17, had been examined and found to have high blood pressure, and at 22 they had the first recorded figures, 240/160 at the age of 32 it was 180/140 and at 37, 194/124, so that for over twenty years he had had considerable hypertension without any shortage of breath, or headaches, or any symptoms whatever He thought he might make quite legitimate deductions from such cases the first was that long-sustained increased pressure as such had no effect deleteriously on either the arteries or on the heart, hypertrophy only being caused During this first stage of hypertension there was available post-mortem evidence from young subjects, whose arteries had been examined, no sign whatever of any degeneration being apparent, such cases having been knocked down in the street or having died of something else

In the second stage one began to get arterial degeneration, and it seemed clear that this degeneration was really the first and primary cause of the so-called hypertensive lesions in heart, kidney, or retina Such degeneration in most cases was a manifestation of age, or wear and tear, but in a few young subjects the arterial tissue was affected by the presence of chronic nephritis

When it came to consideration of the effects of sympathectomy cases seemed to be divided into two kinds in one case the operation succeeded, and in another it clearly failed—there being a temporary fall in the blood pressure which within three months or so had risen again

It was clear they did not want to use sympathectomy too early, because such a patient might easily live without symptoms for twenty years with hypertension The actual follow-up of all cases of sympathectomy did not extend farther back than something like eight years If sympathectomy were done at this early stage it would be less easily applicable later when its help might be needed by the patient because of the onset of advancing arterial disease If a second sympathectomy were then done it certainly would be much more difficult technically Sympathectomy was equally contraindicated when dealing with cases that had severe or advanced vascular disease, particularly of the kidneys It would therefore seem to be their duty to try to find some way of judging when a patient was approaching the end of his period of benign hypertension, and not to leave it too late before they decided that sympathectomy should be done There were, of course, exceptions to the rule, such as those cases of malignant hypertension, particularly in young subjects with advanced retinitis who could barely see, but after operation could read The charts and retinal pictures of two such cases were shown, who during the post-operative five and six months

had improved greatly, both as regards vision and as regards general health

The family history was also helpful there were those individuals who had in the family a number of relations who had had raised blood pressure for many years without symptoms, and on the contrary there were families, many of whom seemed to die at the age of about forty-five Probably the safest guide was a regular periodic and careful examination of the patient, so that one might soon become aware early of any fresh change that had started to occur A watch should be kept for a sudden increase in the already high blood pressure and close observation of the retina should be made periodically by the same ophthalmic surgeon Then again, obvious deterioration in the cardiac function, as shown by increasing size of the heart and increasing shortness of breath would immediately lead one to consider most carefully whether sympathectomy should or should not be done In such cases angina and coronary disease were a contraindication to sympathectomy The renal function should be similarly reassessed at intervals Evidence of definite impairment of this was also a contraindication to the operation

By Sven Hammarström, St Erik's Hospital, Stockholm

The neurosurgical treatment of hypertension was introduced in Sweden in 1940 by Olivecrona and Berglund I have followed up 100 of their patients one to seven years after sympathectomy (*Acta med Scand*, 1947, Suppl 192) Most of the patients were submitted to dorso-lumbar sympathectomy according to Smithwick and a smaller group to supradiaphragmatic sympathectomy according to Peet The results of the last mentioned one-stage operation on the whole agree with those obtained with the more complicated and extensive method I recommend Peets' operation in selected cases of less severe hypertensive disease

About one half of the patients in our series before operation had a severe hypertensive disease with retinal exudates and hæmorrhages The operative mortality was 2 per cent and the late mortality 20 per cent

Even under so-called basal conditions there is a great variability of blood pressure in all groups of hypertensive patients, which must be considered in the evaluation of the effect of sympathectomy I have studied the blood pressure before and at various lengths of time after sympathectomy by means of 24-hour readings, which made possible a statistical evaluation of the significance of the post-operative change In 60 per cent of the patients still alive there is a significant drop in systolic and diastolic pressure during the whole follow-up time This lowering was regularly followed by an improvement or complete disappearance of hypertensive retinopathy and improvement or return to normal of the electrocardiogram

In 50 patients the average post-operative drop in systolic and diastolic pressure was essentially the same according to 24-hour readings registered shortly after the operation and after an average time of three years Furthermore the average drop in blood pressure was the same in those examined shorter and longer time than three years after sympathectomy

Contrary to the long-standing lowering of blood pressure in the recumbent position, the post-operative orthostatic hypotension and tachycardia is transient. Repeated tilting tests after sympathectomy showed that the orthostatic changes gradually subsided and usually disappeared within one year after sympathectomy There is furthermore no correlation between the amount of the pressure lowering in the recumbent position and the degree of the orthostatic changes

There is still no reliable test to predict the effect of sympathectomy I found no correlation between the postoperative change in blood pressure and its height, or spontaneous or induced variability before operation The main indication for sympathectomy is a progressive hypertensive disease with retinopathy, left ventricular strain, and cerebral symptoms, in the absence of the signs of severe organic vascular damage, which will be described below We do not usually operate on patients with uncomplicated hypertension who show no other objective signs than elevated pressure or in addition left axis deviation in the cardiogram and/or slight vascular eye-ground changes These patients, who constitute the great majority, often have a transient hypertension and only a slight excess mortality compared with the average population (Bechgaard (1946), *Acta med Scand*, Suppl 172) The occurrence and degree of subjective symptoms in hypertensive disease does not run parallel with the objective signs Even in benign hypertension the subjective symptoms may be incapacitating In most of these patients medical and psychotherapeutical measures give adequate relief In those who are unimproved by such prolonged treatment sympathectomy is advisable on account of its striking effect on headache and other subjective symptoms with restitution of the working capacity

An analysis of the failures of sympathectomy in our series showed that the following signs contraindicated neurosurgical treatment Impaired renal function shown by more than one of the following signs albuminuria, non-protein nitrogen above 45 mg per 100 ml, creatinine clearance below 80 ml /minute, cardiac decompensation where less than ordinary activity causes discomfort, and enlargement of the heart volume above 500 ml/m² body surface Valvular lesions and coarctation of the aorta must also be excluded Cerebral lesions with persistent symptoms such as hemiplegia or even advanced hypertensive encephalopathy contraindicate sympathectomy

Tomography in the Study of the Cardiovascular System

By E Tiscenco and J H Wright, Glasgow

An attempt was made to illustrate the application of tomography of the cardiovascular system by lantern slide demonstration In the absence of the apparatus for tomographic screening, a procedure was suggested by which the accuracy of the tomographic positioning, particularly for oblique projections, can be enhanced

The pulmonary vascular structures in health and in emphysema were demonstrated

The various parts of the normal aorta were shown followed by the appearances of the aorta in atheroma and in aneurysms

The normal left atrium was displayed by a tomographic section and compared with the appearances in varying degrees of its enlargement When straight examinations are inconclusive tomography may be of diagnostic value

The outflow and inflow tracts of the right ventricle were tomographically defined Examples of eccentric and concentric hypertrophy of the left ventricle in hypertension were given

A structure seen in several tomographs, substantiated by anatomical comparison as well as by demonstration of the lobus venæ azygos, was shown to be consistent with the major azygos vein

The last section of the demonstration was confined to the differentiation of pathological shadows projected close to or into the cardiovascular structures

Although the study was not conclusive, it was hoped that improvement in the mechanical side of tomography would not only enhance its accuracy but fully justify its application in the study of cardiovascular radiology

RAPID DIGITALIZATION

BY

WILLIAM EVANS, PETER DICK,* AND BYRON EVANS

From the Cardiac Department of the London Hospital

Received February 14, 1948

When it has been decided to give digitalis to a patient with heart failure, the need for inducing its effects quickly (rapid digitalization) is sometimes evident There is no unanimity on the best preparation to use for this purpose nor on the best way to give the preparation of choice Mackenzie (1914) said that he seldom failed to induce rapid digitalis effect by giving the drug by mouth, but occasionally in auricular fibrillation when the heart rate exceeded 140 a minute he had found that strophanthin (1/125 grain) intravenously reduced the rate and relieved symptoms in five to eight hours From his own observation he saw no reason to give preference to any preparation, but he pointed out the need to investigate this problem In 1925 Cushny again stressed the necessity to examine the comparative value of digitalis preparations

There is available a comparison of series of patients on different drugs with a digitalis effect, but the relative value of two or three preparations in the same patient has seldom been reported The present clinical trial was designed to discover the most effective preparation for rapid digitalization when given orally or intravenously, by comparing the effect of as many preparations as possible in the same patient and under the same conditions This procedure does not appear to have been adopted for rapid digitalization as it has been done in the case of maintenance therapy (Evans, 1940)

It was decided to test the following drugs as likely to prove of value strophanthin, ouabain and k-strophanthosid, digoxin, digitoxin, lanatoside C, digitalis leaf, and the tincture of digitalis In addition, certain remedies like coramine and cardiazol were given to certain cases as a control In order that the results might be comparable it was necessary to give a full dose of each drug In the earlier cases varying doses of some preparations were tried and in certain instances doses considerably larger than those recommended were used The relative value of these preparations was studied in 20 patients

The most satisfactory index of digitalization is the fall in the ventricular rate in auricular fibrillation and this was used, but improvement in the objective signs of failure was also observed and so was the diuretic response Because no digitalis preparation was to be given between the testing of each individual preparation, cases with severe heart failure could not be used Cases of rapid auricular fibrillation with slight or moderate congestive heart failure, were selected The patients had mitral stenosis, occasionally combined with aortic incompetence, or had hypertension They were confined to bed on a normal hospital diet and fluids were restricted The fluid intake and urinary output were measured. The apical rate was particularly recorded and any change in the signs of heart failure was looked for The majority received no other treatment, apart from sedatives when necessary, but in a few with moderate œdema mercurial diuretics were not withheld, they were not given during the testing period for the separate digitalis preparations nor on the preceding day After a few days of preliminary observation, and after ensuring that no digitalis had been given during the previous seven days, the first preparation was given The apical rate was counted over three consecutive half minutes, the respiration and blood pressure were also noted The drug was then given, and the heart rate was counted for three consecutive half-minute periods every quarter of an hour, until it had ceased to fall over a period of one and a half to two hours It was found in practice that the fall was almost always complete within four hours Symptoms and signs of toxicity were sought Subjective and objective signs of improvement were noted during the following forty-eight hours although a noticeable change was not found because of the relative freedom from symptoms

* This work formed the basis of a thesis submitted by P D and accepted for the M D Degree of the University of Cambridge

shown by the selected cases while at rest in bed A conspicuous diuretic response seldom résulted in these patients with only slight heart failure, and it was too erratic to be accepted as a measure of the benefit Reliance was placed on the heart rate as a criterion of improvement in the selected cases, during a short period following the administration of a particular digitalis preparation

The following is an example of how each trial was recorded

This experimental error, with a variation between the first and second preparation greater than between succeeding preparations, was never great, and was partly overcome by giving the preparations in a different order to each patient, a practice always adopted The number of tests that it was possible to carry out in each case was thus limited by the failure of the ventricular rate to rise to a comparable level after a variable number of tests In several cases after the first preparation it did not rise sufficiently for a fair comparison to be made with succeeding preparations and such were excluded from the series For this reason it proved difficult to collect a series of suitable patients for this investigation

Name C J S *Age* 31 *Date* 22/11/45
Diagnosis and Summary Mitral stenosis, auricular fibrillation, and heart failure
Observation Effect of 3 mg digoxin given orally

Time	Ventricular rate	Respiratory rate	Blood pressure	Remarks
10 30 a.m	140 134 146		120/80	
10 45 a m	142 130 130	18		Digoxin 3 0 mg given orally
11 0 a m	114 128 126			
11 15 a m	124 130 132		115/70	
11 30 a m	140 138 124			
11 45 a m	116 116 116	16		
12 0 p m	130 120 116			
12 15 p m	104 108 108		110/75	Had dinner 12 20 p.m Onset of nausea, unable to eat pudding
12 30 p m	120 110 110			Very nauseated
12 45 p.m	116 106 110	14		Nausea less
1 0 p m	118 98 106			Nausea completely gone
1 15 p m	98 98 106		110/70	
1 30 p m	100 88 94			
1 45 p m	96 92 92	14		
2 0 p m	104 86 92			
2 15 p m	84 80 84		110/75	
2 30 p m	86 84 92			
2 45 p m	82 76 74	14		
3 0 p m	74 80 76			
3 15 p m	74 84 80		110/75	
3 30 p m	76 74 74			
3 45 p m				
4 0 p m	74 80 94			
4 15 p m	86 86 84		120/80	
4 30 p m	80 80 88			
4 45 p m	78 80 82			
5 0 p m	88 84 80			
5 15 p m	80 84 78			
5 30 p m	80 78 76			
6 0 p.m	76 80 80			
8 0 p m	80 84 80			
23 11 45 8 a m.	74 72 68			No diuresis took place

The patient received no further digitalis for a period of three to fourteen days, until the ventricular rate had returned to its previous level and the effects of the previous preparation had worn off The length of time varied with the different preparations On many occasions the ventricular rate did not return exactly to its previous rate, tending to settle at a lower level after a trial with each preparation

Results

The criterion adopted for the effectiveness of a preparation has been the fall in heart rate produced

by it The results are summarized in the form of graphs showing this fall in heart rate The fall shown at each time period is an average of the preceding half-hour or hour's readings, deducted from the average initial rate before the administration of the drug, and thus represents the effect of the drug during the preceding half-hour or hour They are arranged usually in the order of effectiveness, and not in the order the drugs were given, for this was deliberately varied

The extent of the fall in heart rate produced by a digitalis preparation has been shown to be closely related to the initial heart rate (Lyon and Gilchrist, 1927), as would be expected The tendency of the heart rate to fall throughout the periods of trial in most cases, coinciding with the improvement of heart failure, has already been mentioned It is seldom possible to simulate laboratory conditions in a clinical investigation, and it could not be anticipated that any patient would be in exactly the same state prior to the administration of each preparation The consistency of action of a drug in the same dosage and in the same patient was tested in two cases . In one case, receiving 1 5 mg of digoxin by mouth on two occasions with a week's interval, although the initial heart rate was almost identical in both trials, the effect was different whereas in another case the effect was almost identical (Fig 1) On the whole drugs were found to reproduce the same result with remarkable consistency in successive cases

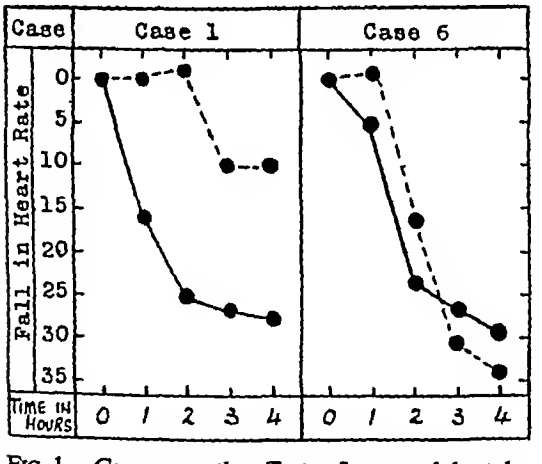

Fig 1 —Comparing the effects of repeated digitalis medication in the same patient In Case 1 the effect of 1 5 mg of digoxin by mouth was not the same, but in Case 6 the effect of 2·0 mg of digoxin by mouth was identical on each occasion. Continuous and discontinuous lines represent separate trials with one week's interval

A further difficulty was the determination of the size of the dose for each patient. The amount that will produce a full digitalis effect is known to vary a great deal in different patients, a fact that was apparent in these trials With the lesser doses, unless a satisfactory therapeutic action had taken place, there was no certainty that the patient had received what was for him a full dose of that preparation, and the result could not, therefore, be fairly compared with the action of another preparation For the purpose of comparison of the different drugs, a minimum full dose was chosen for each preparation, based partly on the result of these trials and partly on previous experience A further difficulty was the variability in the time taken to induce proper digitalization in relation to the size of the dose when given by mouth With large doses, such as 3 mg of digoxin by mouth, an effect was seen more rapidly than with smaller doses, although the final effect might be the same It was occasionally noticed with oral administration that the full effect was not seen within four hours, so that when comparing two drugs the results observed within four hours might reflect the dosage rather than the effectiveness of the preparation With intravenous therapy the maximal effect was invariably seen within four hours and comparison with an oral preparation might on that account be open to the same fallacy at times

As this study was undertaken to ascertain the best preparations for rapid digitalization some time-

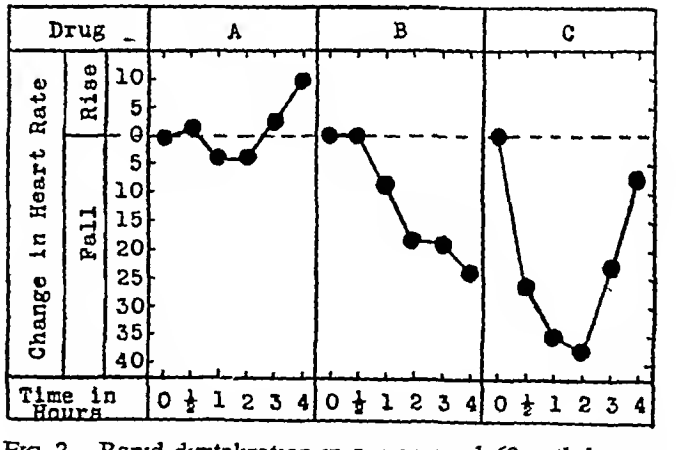

Fig 2.—Rapid digitalization in a man aged 60 with hypertension and auricular fibrillation (A) Digitaline (Nativelle), 2 0 mg. by mouth (B) Digoxin, 2 0 mg by mouth. (C) K-Strophanthosid, 0 5 mg intravenously

limit had to be applied within which the effect would be regarded as rapid Four hours was selected as a suitable period for it represents the time which may be regarded as maximal in a patient requiring rapid digitalization The comparison of results, therefore, has been based entirely on a preparation's effectiveness within that period

In giving the results each drug is considered in turn and its effectiveness judged in each patient A digitalis effect was classified as good when the fall in heart rate within four hours was 75 per cent of the maximal fall produced by any preparation in that patient, moderate between 50 and 75 per cent, and slight below 50 per cent This method of assessing the therapeutic effect was possible, as an optimum result was produced in all patients, with the exception of one, by at least one preparation The results are summarized in the form of a Table for each drug, showing the number of times it was more, equally, or less effective than the others, within two and within four hours The effect of two preparations was regarded as equal if the difference in the fall of the heart rate was not more than 5 per cent of the maximum produced by any drug in that patient Tables 1 to 7 show the number of times each preparation proved more effective than the other, but they do not show the relative differences Table 8 shows the consistency of effectiveness of each drug in different doses The actual change in the heart rate from different preparations in the same patient is shown in Fig 2 to 20

Other remedies These were introduced solely for the purpose of controlling the results obtained from the use of active preparations

Coramine (Nikethamidum B P), described as a respiratory and vasomotor stimulant, was given once in a dose of 1 7 ml and four times in a dose of 3 4 ml of a 25 per cent solution intravenously In one case its administration was followed by momentary dizziness, but no other effect was noted and there was no significant change in the heart rate

Cardiozol (Leptazolum B P), a convulsant in large doses, and stated to be a respiratory and vasomotor stimulant in smaller doses, was given to two cases in a dose of 2 ml intravenously In one case the rate rose from 100 to 105 during the first five minutes and remained at about this level for the first hour, but during the second hour it averaged 125 In another the injection was followed by a sensation of dizziness lasting eight minutes The heart rate rose from 105 to 140

Analeptic preparation 3067/16 (Roche) was given intravenously once Two minutes later the patient experienced severe dizziness and mental excitement which passed off gradually A slight rise in the heart rate took place

Cycliton was given once in a dose of 2 ml intravenously The heart rate rose sharply following the injection

Strophanthin

Strophanthin was given intravenously 6 times in a dose of 1/100 gr (0 65 g) and 4 times in a dose of 1/60 gr (1 08 mg) In a dose of 1/100 gr it had a good effect once, a slight effect once, and practically none in another In two cases a sharp fall in the heart rate occurred during the first hour, but it had risen to its previous level by the fourth hour In one case it was followed by a slight rise in rate In a dose of 1/60 gr it had a good effect three times, and a slight effect once No toxic effects were seen From previous reports 0 5 mg is generally regarded as the maximal safe dose, and this, therefore, was considered to be a full dose for the purpose of comparison It was compared with ouabain intravenously 3 times, strophosid intravenously 3 times, digalen intravenously twice, digoxin by mouth 14 times, digoxin intravenously 10 times, digitaline (Nativelle) by mouth once, and lanatoside C intravenously 3 times The results are shown in Table I

TABLE I

THE EFFECT OF STROPHANTHIN INTRAVENOUSLY COMPARED WITH THAT OF OTHER PREPARATIONS

Drug for comparison	No of trials	Efficiency of Strophanthin compared with other Preparations					
		Within 2 hours			Within 4 hours		
		Greater	Equal	Less	Greater	Equal	Less
Ouabain	3	3	—	—	2	1	—
Strophosid	3	—	1	2	—	1	2
Digalen	2	1	—	1	1	—	1
Digitaline (Nativelle) (m)	1	1	—	—	—	—	1
Digoxin (m)	14	6	1	7	2	—	12
Digoxin (v)	10	1	1	8	—	1	9
Lanatoside C (v)	3	—	1	2	1	—	2

In this and in other tables (m) indicates that the preparation was given by mouth and (v) intravenously

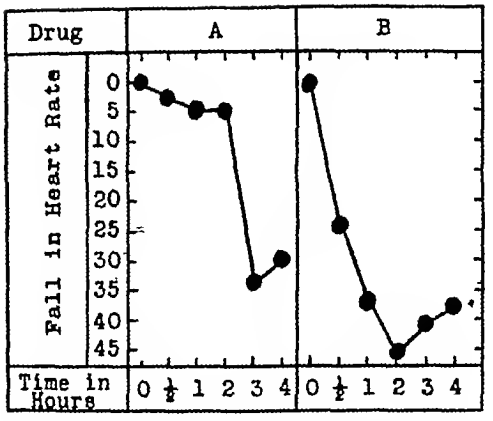

FIG 3 —Rapid digitalization in a woman aged 61 with mitral stenosis and auricular fibrillation (A) Digitaline (Nativelle), 1 75 mg by mouth. (B) Lanatoside C, 1 2 mg. intravenously

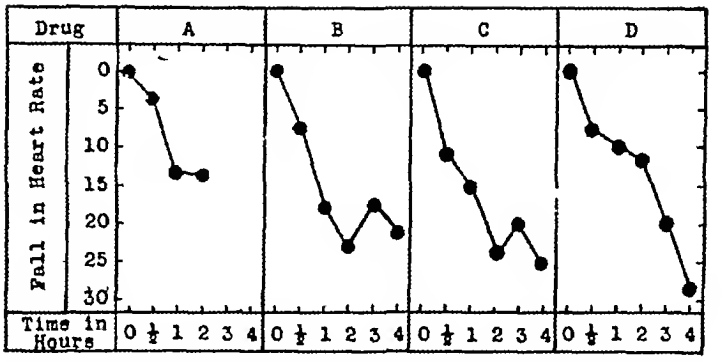

FIG 4 —Rapid digitalization in a man aged 54 with hypertension and auricular fibrillation (A) Digoxin, 1 5 mg. by mouth. (B) Digoxin, 1 5 mg intravenously (C) Lanatoside C, 1 5 mg. intravenously (D) Digitaline (Nativelle), 1 2 mg intravenously

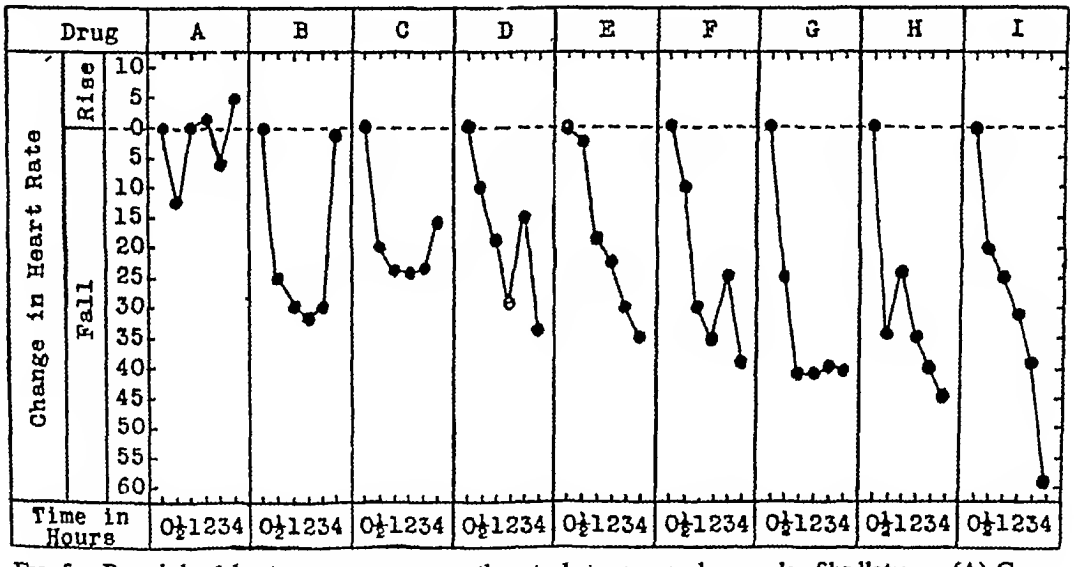

FIG 5 —Rapid digitalization in a woman with mitral stenosis and auricular fibrillation (A) Coramine, 3 4 ml. intravenously (B) Lanatoside C, 1 0 mg by mouth (C) Lanatoside C, 1 mg intravenously (D) K-Strophanthosid, 1 ml intravenously (E) Strophanthin, 1/60 gr intravenously (F) Digoxin, 2 0 mg by mouth (G) Digoxin, 1 5 mg. intravenously (H) Digalen, 1 ml intravenously (I) Digoxin, 3 0 mg by mouth

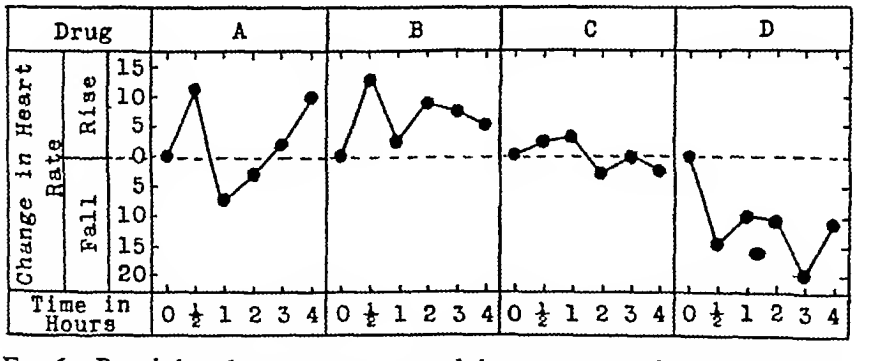

FIG 6 —Rapid digitalization in a man with hypertension and auricular fibrillation (A) Analeptic 3067/16 (Roche), 2 ampoules intravenously (B) Cardiazol, 2 ml intravenously (C) Coramine, 3 4 ml intravenously (D) Tincture of digitalis, 2 drachms by mouth

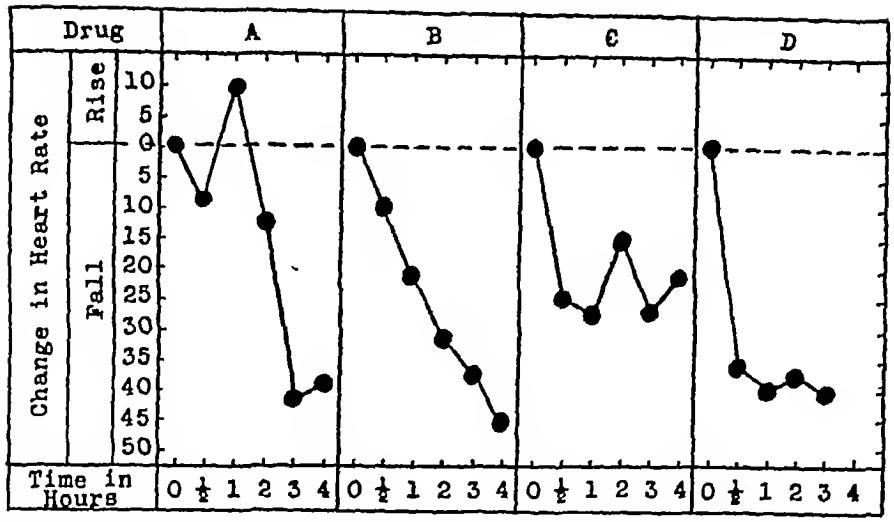

FIG 7 —Rapid digitalization in a woman aged 37 with mitral stenosis and auricular fibrillation (A) Digoxin, 1 5 mg. by mouth (B) Digitaline (Nativelle), 2 0 mg by mouth (C) Lanatoside C, 3·0 mg by mouth (D) K-Strophanthosid, 0 5 mg intravenously

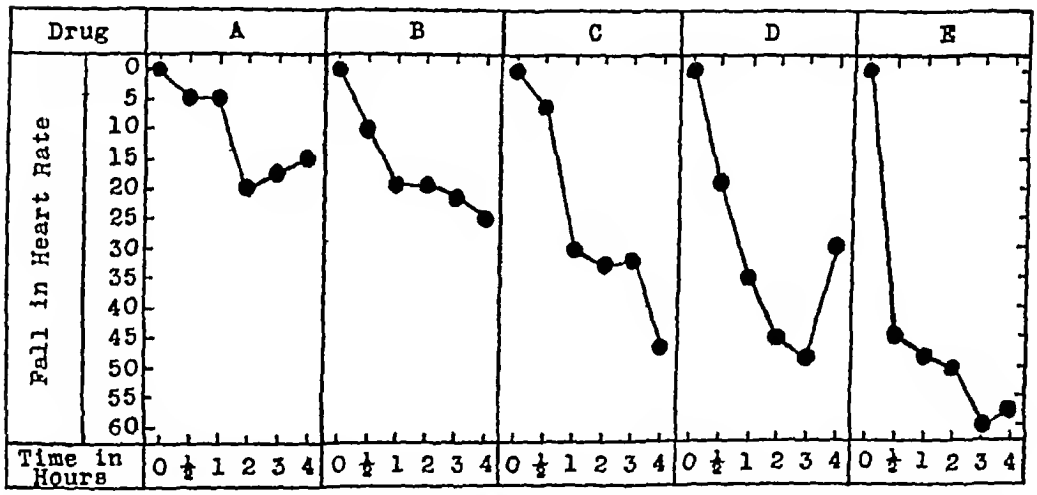

FIG 8 —Rapid digitalization in a woman aged 57 with hypertension and auricular fibrillation. (A) Digitaline (Nativelle), 1 25 mg by mouth (B) Digoxin, 1 25 mg by mouth (C) Digitaline (Nativelle), 1 2 mg intravenously (D) Digoxin, 1 25 mg intravenously (E) Lanatoside C, 1 5 mg intravenously

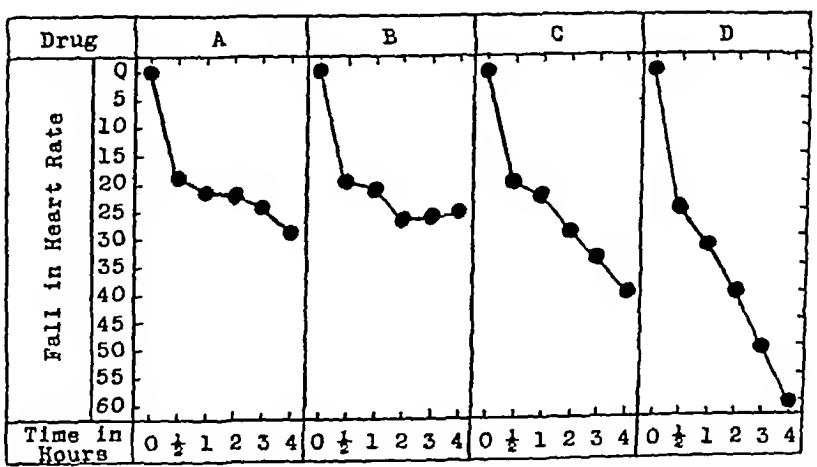

FIG 9 —Rapid digitalization in a woman aged 48 with mitral stenosis, aortic incompetence, and auricular fibrillation (A) Digoxin, 1 5 mg intravenously (B) Digitaline (Nativelle), 1 5 mg intravenously (C) Digitaline (Nativelle), 1 5 mg. by mouth (D) Lanatoside C, 1 5 mg intravenously

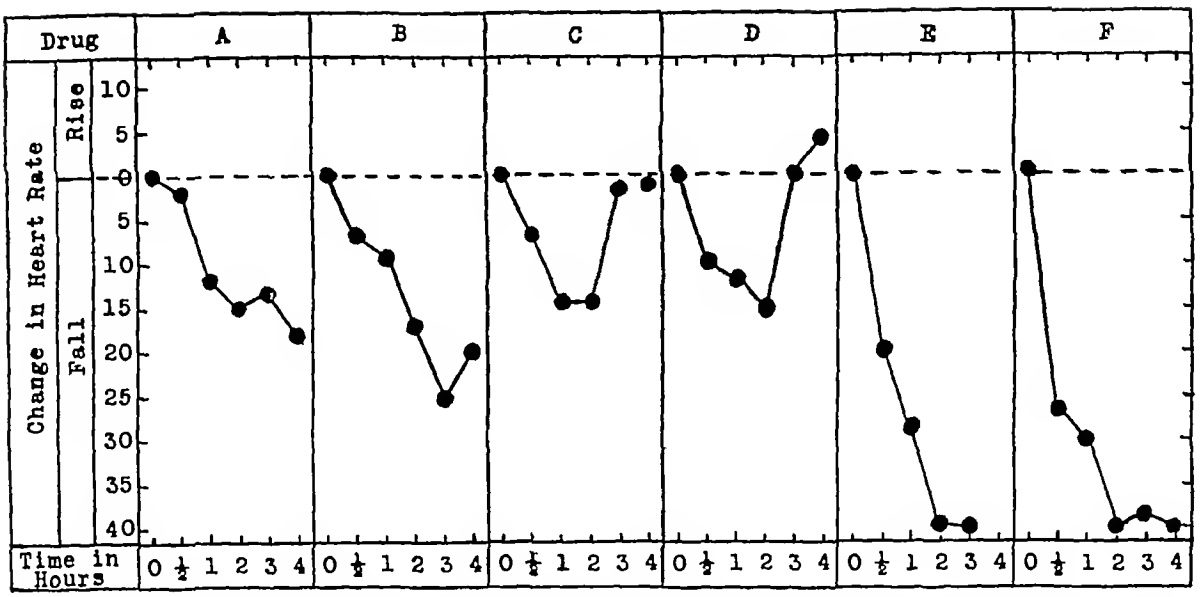

FIG 10—Rapid digitalization in a man aged 29 with mitral stenosis and auricular fibrillation (A) K-Strophanthosid, 0 5 mg intravenously (B) Digitaline (Nativelle), 2 0 mg by mouth (C) Digoxin, 2 0 mg by mouth (D) Lanatoside C, 3 0 mg by mouth (E) Lanatoside C, 1 5 mg intravenously (F) Digitaline (Nativelle), 1 5 mg intravenously

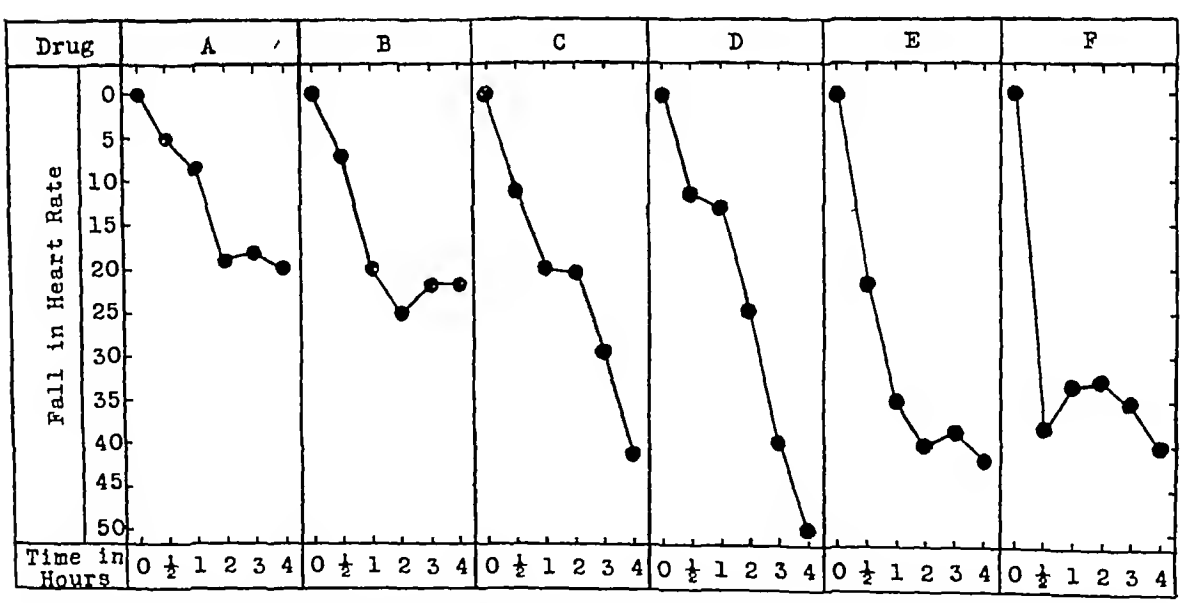

FIG 11—Rapid digitalization in a man aged 31 with mitral stenosis and auricular fibrillation (A) Lanatoside C, 3 0 mg by mouth (B) K-Strophanthosid, 0 5 mg. intravenously (C) Digitaline (Nativelle), 2·0 mg by mouth (D) Digoxin, 3·0 mg by mouth (E) Digitaline (Nativelle), 1 5 mg intravenously (F) Lanatoside C, 1 5 mg intravenously

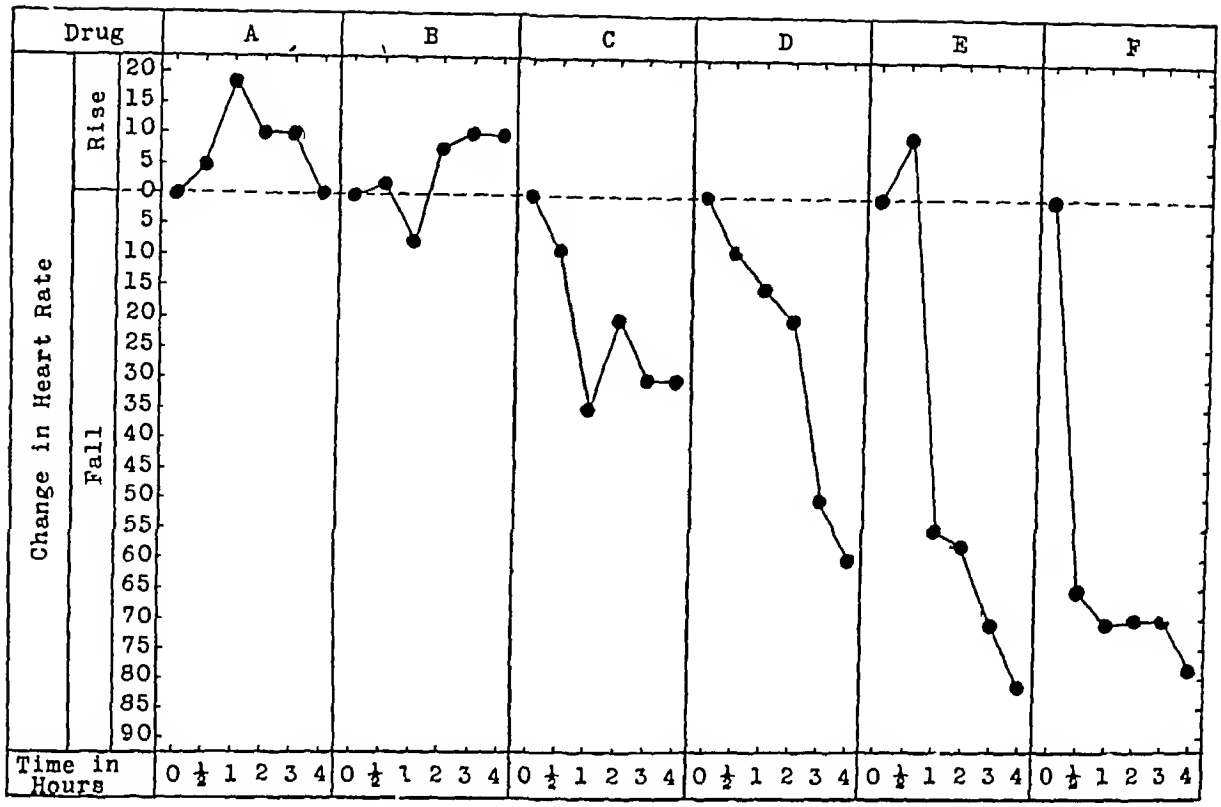

FIG 12 —Rapid digitalization in a woman aged 34 with mitral stenosis and auricular fibrillation (A) Lanatoside C, 3 0 mg by mouth (B) Coramine, 1 7 ml intravenously (C) Lanatoside C, 0 8 mg intravenously (D) K-Strophanthosid, 1 ml intravenously (E) Digoxin, 3 0 mg by mouth (F) Digoxin 1 5 mg intravenously

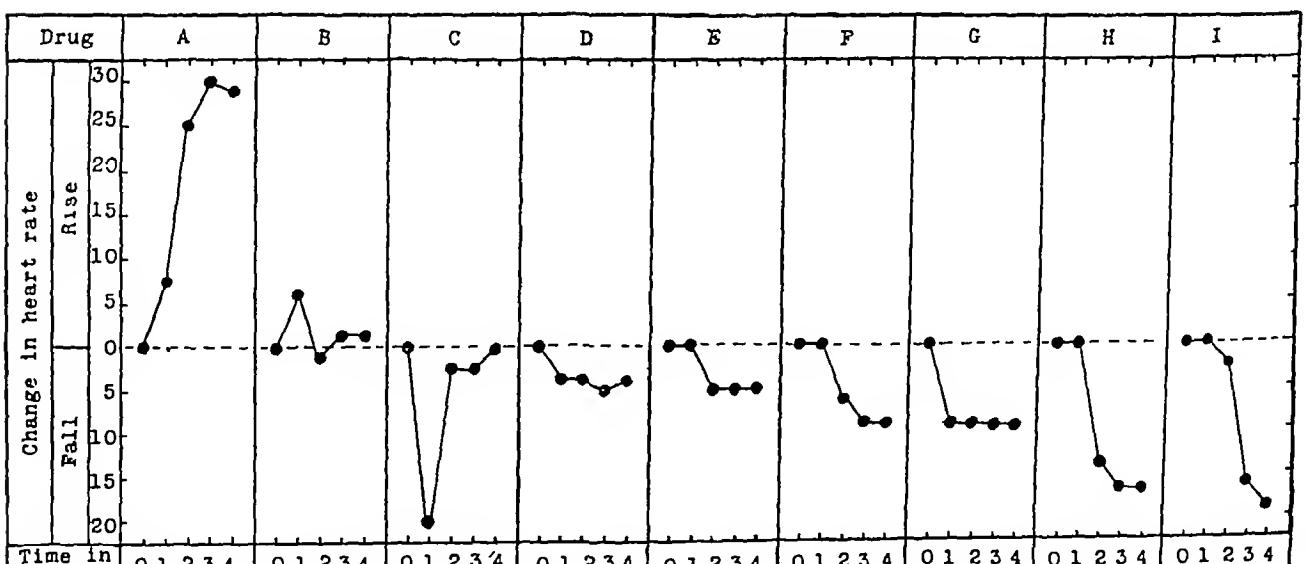

FIG 13 —Rapid digitalization in a man aged 45 with mitral stenosis and auricular fibrillation (A) Cardiazol, 2 ml intravenously (B) Ouabain, 1/240 gr intravenously (C) Strophanthin, 1/100 gr intravenously (D) Coramine, 3 4 ml intravenously (E) Strophanthin, 1/60 gr intravenously (F) Digoxin, 1 5 mg by mouth (G) Digoxin, 1 0 mg intravenously (H) Digoxin 1 5 mg chewed (I) Digoxin, 3 0 mg by mouth

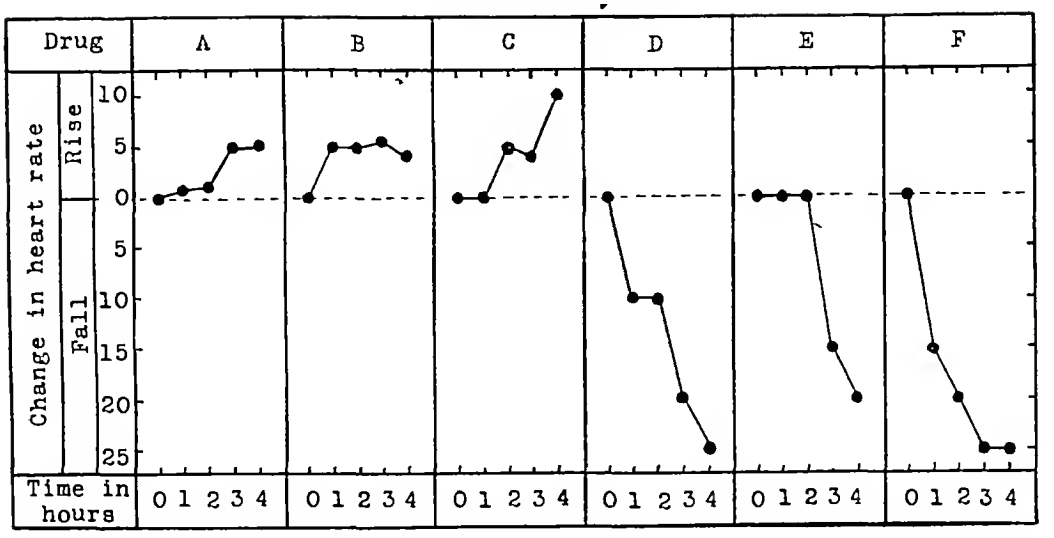

FIG 14—Rapid digitalization in a man aged 54 with hypertension and auricular fibrillation (A) Digitalis leaf, 6 grains by mouth (B) Tincture of digitalis, 2 drachms by mouth (C) Digitaline (Allen and Hanbury), 1/30 gr by mouth (D) Strophanthin, 1/100 gr intravenously (E) Digoxin, 1 5 mg by mouth (F) Digoxin, 1 0 mg intravenously

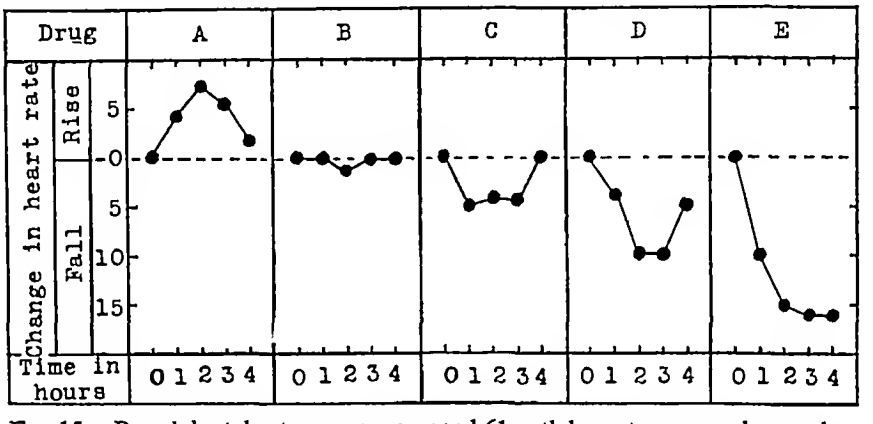

FIG 15—Rapid digitalization in a man aged 61 with hypertension and auricular fibrillation (A) Strophanthin, 1/100 gr intravenously (B) Digitaline (Allen and Hanbury), 1/30 gr by mouth (C) Digoxin, 1 5 mg by mouth (D) Digitalis leaf, 6 gr by mouth (E) Digoxin, 1 0 mg intravenously

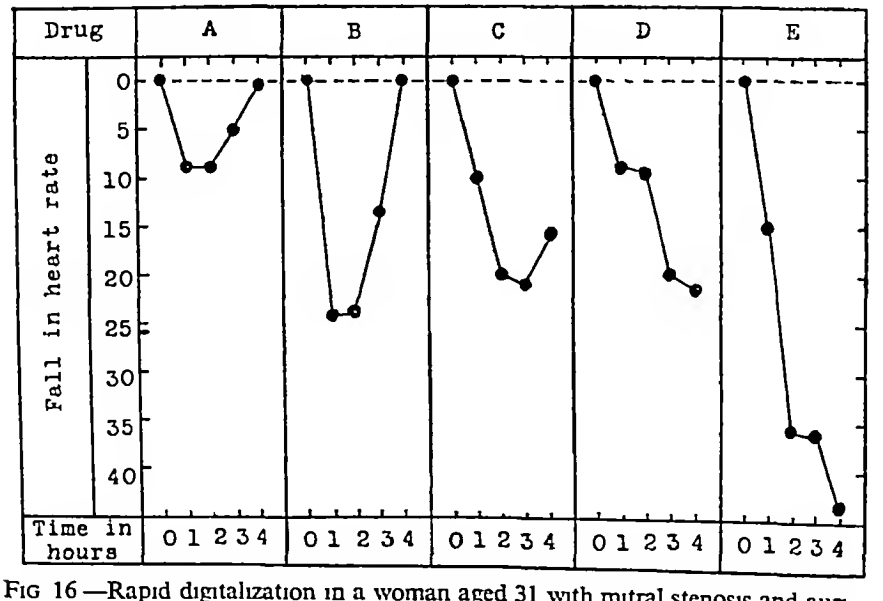

FIG 16—Rapid digitalization in a woman aged 31 with mitral stenosis and auricular fibrillation (A) Digitaline (Nativelle), 1/300 gr intravenously (B) Strophanthin, 1/100 gr intravenously (C) Digitaline (Nativelle), 1/50 gr by mouth (D) Digoxin, 1/5 mg by mouth (E) Digoxin, 1 5 mg intravenously

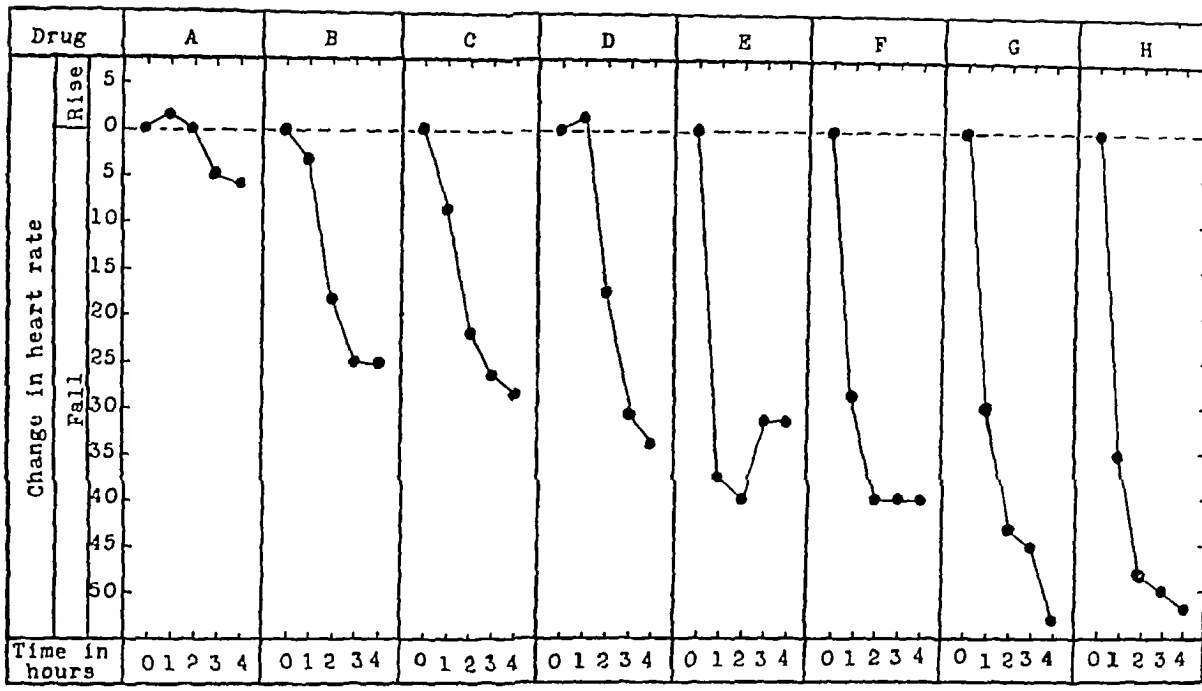

FIG 17—Rapid digitalization in a woman with mitral stenosis and auricular fibrillation (A) Coramine, 3 4 ml intravenously (B) Digoxin, 1 0 mg by mouth (C) Digoxin, 2 0 mg by mouth (D) Digoxin, 2 0 mg by mouth (E) Strophanthin, 1/60 gr intravenously (F) Digoxin, 1 0 mg intravenously (G) Lanatoside C, 0 8 mg intravenously (H) K-Strophanthosid, 1 ml intravenously

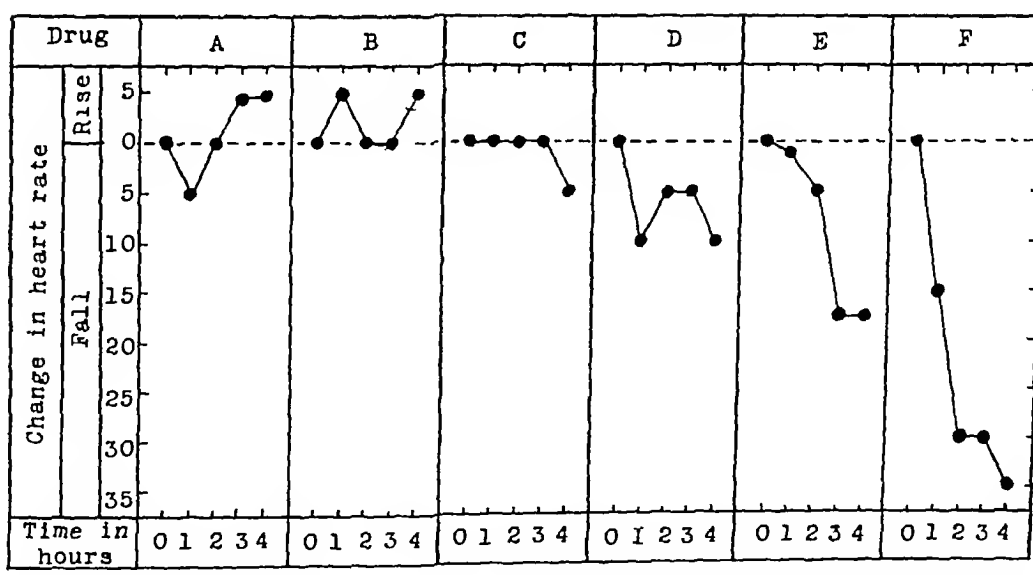

FIG 18—Rapid digitalization in a man aged 46 with mitral stenosis and auricular fibrillation (A) Digitaline (Allen and Hanbury), 1/30 gr by mouth (B) Tincture of digitalis, 2 drachms by mouth (C) Digitalis leaf, 6 gr by mouth (D) Strophanthin, 1/100 gr intravenously (E) Digoxin, 1 5 mg by mouth (F) Digoxin, 1 0 mg intravenously

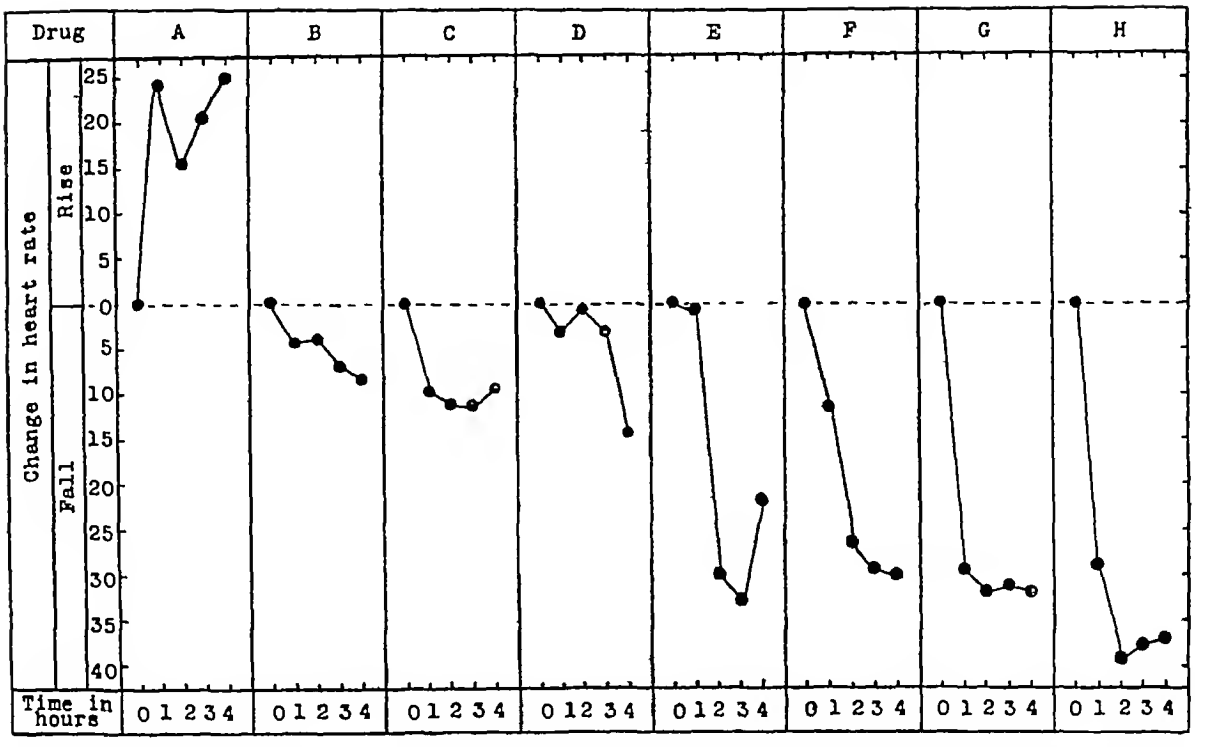

FIG 19 —Rapid digitalization in a woman aged 76 with mitral stenosis and auricular fibrillation. (A) Cycliton, 2 ml intravenously (B) Digitaline (Nativelle), 1/240 gr intramuscularly (C) Ouabain, 1/240 gr intravenously (D) Digalen, 1 ml intravenously (E) Digoxin, 1 mg intravenously (F) Strophanthin, 1/60 gr intravenously (G) Lanatoside C, 4 ml intravenously (H) K-Strophanthosid, 1 ml intravenously

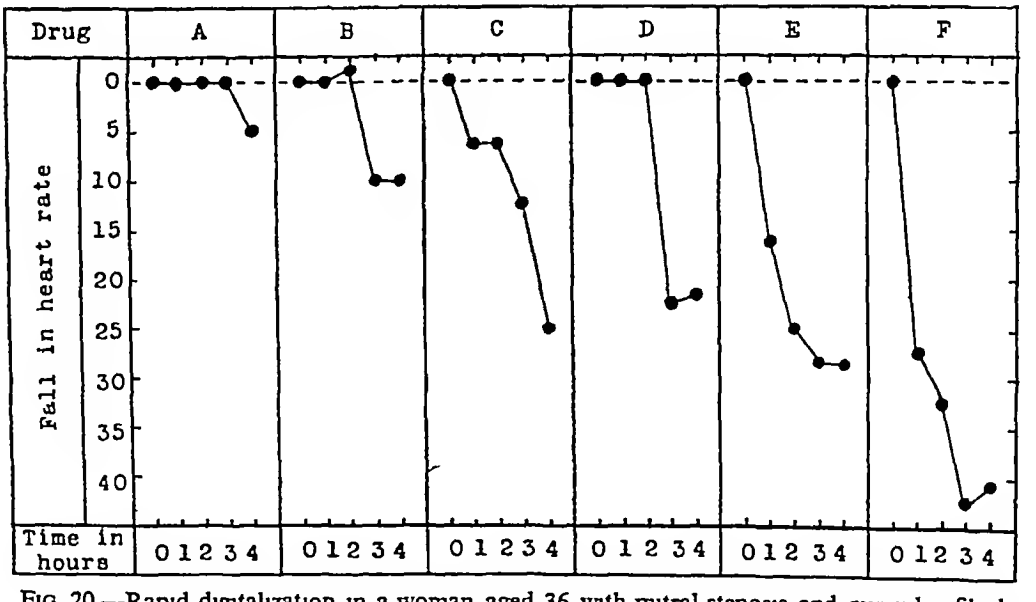

FIG 20 —Rapid digitalization in a woman aged 36 with mitral stenosis and auricular fibrillation. (A) Strophanthin, 1/100 gr intravenously (B) Digoxin, 1 5 mg. by mouth (C) Digoxin, 1 5 mg chewed. (D) The same as C (E) Digoxin, 1 5 mg by mouth (F) Digoxin, 1·0 mg intravenously

Ouabain was given intravenously in a dose of 1/240 gr to two cases It produced no effect in one case and only a slight effect in another It was not given a sufficient number of times to justify any comparison with other drugs

Strophosid

Strophosid (Sandoz) in a dose of 1 ml containing 0 5 mg of k-strophanthosid, was given 9 times It produced a good effect in 5, a moderate effect in 2, and a slight effect in 1 case In one there was a considerable fall during the first two hours, but the heart rate had returned almost to its previous level by the fourth hour In the absence of any previous reports of the drug, the dosage of 1 ml recommended by the manufacturers was regarded as a full dose It was compared with strophanthin intravenously 3 times, with ouabain once, with digoxin by mouth 8 times, with digoxin intravenously 5 times, with digitaline (Nativelle) by mouth 4 times, with digitaline (Nativelle) intravenously 3 times, and with lanatoside C intravenously 7 times The results are summarized in Table II

Digitalis tincture and leaf

The tincture was given by mouth 3 times in a dose of 2 drachms It had practically no effect in 2 cases, and only a slight effect in one within four hours Digitalis leaf by mouth in a dose of 6 grains was given 3 times In one case its administration was followed by a slight rise in heart rate, in one by a slight fall and in the third there was no change As the full comparable dose of digitalis leaf lies between 15 and 25 grains these results could not be compared with other preparations

Digalen, a water soluble preparation of total digitalis alkaloids, was given twice intravenously in a dose of 1 ml It produced a good effect in one case, and a moderate effect in the other It was not given a sufficient number of times to allow comparison with other drugs

Digitaline (Allen and Hanbury) was given three times by mouth in a dose of 1/30 gr (2 2 mg) In no case did a significant fall in the heart rate occur within four hours

TABLE II

THE EFFECT OF STROPHOSID INTRAVENOUSLY COMPARED WITH THAT OF OTHER PREPARATIONS

Drug for comparison	No of trials	Efficiency of Strophosid intravenously compared with that of other preparations					
		Within 2 hours			Within 4 hours		
		Greater	Equal	Less	Greater	Equal	Less
Strophanthin	3	2	1	—	2	1	—
Ouabain	1	1	—	—	1	—	—
Digalen	2	1	—	1	1	—	1
Digitaline (Nativelle) (m)	4	2	2	—	1	—	3
Digitaline (Nativelle) (v)	3	—	—	3	—	—	3
Digoxin (m)	8	4	1	3	2	1	5
Digoxin (v)	5	3	—	2	3	—	2
Lanatoside C (v)	7	3	1	3	3	1	3

TABLE III

THE EFFECT OF DIGITALINE (NATIVELLE) BY MOUTH COMPARED WITH THAT OF OTHER PREPARATIONS

Drug for comparison	No of trials	Efficiency of digitaline (Nativelle) by mouth compared with that of other preparations					
		Within 2 hours			Within 4 hours		
		Greater	Equal	Less	Greater	Equal	Less
Strophanthin	1	—	—	1	1	—	—
Strophosid	4	—	2	2	3	—	1
Digitaline (Nativelle) (v)	4	—	1	3	1	1	2
Digoxin (m)	5	3	1	1	1	—	4
Digoxin (v)	3	1	—	2	1	—	2
Lanatoside C (v)	5	—	1	4	—	1	4

TABLE IV

THE EFFECT OF DIGITALINE (NATIVELLE) INTRAVENOUSLY COMPARED WITH THAT OF OTHER PREPARATIONS

Drug for comparison	No of trials	Efficiency of digitaline (Nativelle) intravenously compared with that of other preparations					
		Within 2 hours			Within 4 hours		
		Greater	Equal	Less	Greater	Equal	Less
Strophosid	3	3	—	—	3	—	—
Digitaline (Nativelle) (m)	4	3	1	0	2	1	1
Digoxin (m)	2	2	—	—	1	—	1
Digoxin (v)	6	2	—	4	2	—	4

Digitaline (Nativelle)

This preparation was given by mouth 8 times, once as 1 25 mg with slight effect, once as 1 3 mg with moderate effect, once as 1 5 mg with good effect, once as 1 75 mg with good effect, and four times as 2 mg, with this dosage it had a good effect twice, moderate once, while on one occasion there was no fall in the heart rate The full dose by mouth is generally accepted as 1 2 mg and this was taken as the minimum for purposes of comparison It was compared with strophanthin intravenously 4 times, with digoxin by mouth 5 times, with digoxin intravenously 3 times, and with lanatoside C intravenously 5 times (see Table III) It was given intramuscularly in a dose of 0 27 mg in one case when a slight fall in heart rate occurred

It was given 7 times intravenously Once in a dose of 0 22 mg it produced a sustained fall in heart rate, three times in a dose of 1 2 mg it had a good effect and 3 times as 1 5 mg it also had a good effect The full intravenous dose is generally accepted as 1 2 mg It was compared with strophosid intravenously three times, with digitaline (Nativelle) by mouth four times, with digoxin by mouth twice, and with lanatoside C intravenously six times The results are shown in Table IV

Digoxin

The relationship of the oral to the intravenous dose of digoxin, and the size of the full therapeutic dose was studied in 11 cases, because this did not appear to be known and because the full doses which have been generally recommended appeared to be inadequate The effectiveness of digoxin when chewed was studied on three occasions In one case, 1 5 mg. was chewed with the same effect on two occasions The same dose was swallowed twice by this patient, producing once a slightly better effect than when it was chewed, and on the other a much lesser effect. In another case, 1 5 mg was chewed on one occasion and swallowed on another It produced a better effect when chewed, but the actual fall in heart rate was not great and the difference in effect of the two methods of administration was slight

In two cases an equal dose was given intravenously and orally In each a very much better effect was obtained with the intravenous dose In one case an oral dose one-third times larger than the intravenous dose was given, the intravenous dose was slightly more effective On seven occasions the oral dose was one-half times larger than the intravenous dose and each time the intravenous

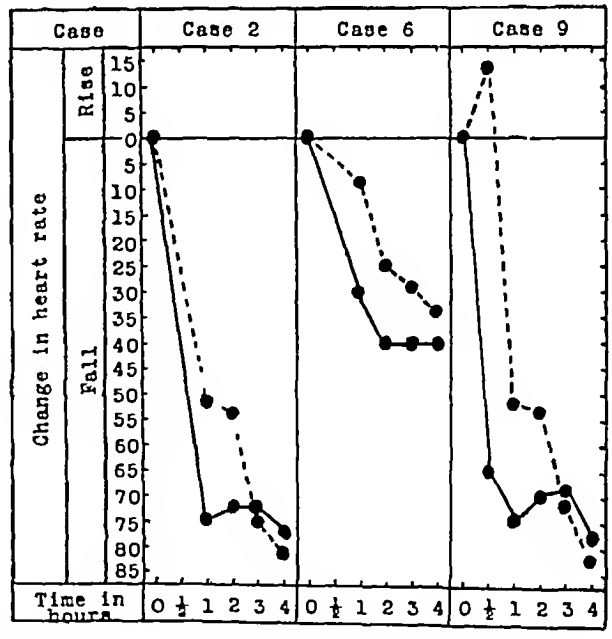

FIG 21 —A comparison of the effects of digoxin given by mouth and half the amount given intravenously in three cases In Case 2 digoxin, 3 0 mg was given by mouth (represented by discontinuous lines) and 1 5 mg intravenously (continuous lines) In Case 6 digoxin, 2 0 mg was given by mouth and 1·0 mg intravenously In Case 9 digoxin, 3 0 mg was given by mouth and 1 5 mg intravenously

dose produced a better effect, usually much better In two cases the oral dose was twice the intravenous dose, and an equal effect was obtained In a third case an oral dose twice the intravenous dose was given on two occasions, the intravenous dose was slightly more effective (Fig 21) Although occasionally the effect of digoxin by mouth was not complete within four hours, any further effect was very slight

Digoxin was given by mouth 18 times It was given as 1 0 mg once with good effect, as 1 25 mg once with moderate effect, as 1 5 mg eight times, as 2 0 mg four times, and as 3 0 mg four times In the 8 cases that received 1 5 mg a good effect was seen three times, a moderate effect four times, and no effect once With a dose of 2 0 mg a good effect was seen three times, and there was no fall in the heart rate in one case With a dose of 3 0 mg a good effect was seen in all four cases The minimal full dose was regarded as 1 25 mg for the purpose of comparison It was compared with strophanthin intravenously 14 times, with ouabain intravenously twice, with strophosid intravenously 8 times, with digalen intravenously twice, with digitaline (Nativelle) by mouth 5 times, with digitaline (Nativelle) intravenously twice, with digoxin intravenously 14 times, and with lanatoside C intravenously 7 times The results are shown in Table V

Digoxin was given intravenously 14 times It was given as 1 0 mg 8 times, producing a good effect in seven and a moderate effect in one, as 1 25 mg twice, producing a good effect once, and an ectopic rhythm in the other, as 1 5 mg 4 times producing a good effect 3 times and a moderate effect once The minimum full dose intravenously was regarded as 1 0 mg It was compared with strophanthin intravenously ten times, with ouabain intravenously twice, with strophosid intravenously five times, with digalen twice, with digitaline (Nativelle) by mouth three times, with digitaline (Nativelle) intravenously four times, with digoxin by mouth fourteen times, and with lanatoside C intravenously eight times The results are shown in Table VI

TABLE V

THE EFFECT OF DIGOXIN BY MOUTH COMPARED WITH THAT OF OTHER PREPARATIONS

Drug for comparison	No of trials	Efficiency of digoxin by mouth compared with that of other preparations					
		Within 2 hours			Within 4 hours		
		Greater	Equal	Less	Greater	Equal	Less
Strophanthin	14	7	1	6	12	—	2
Ouabain	2	1	1	—	2	—	—
Strophosid	8	3	1	4	5	1	2
Digalen	2	1	1	—	1	—	1
Digoxin (v)	14	—	—	14	3	3	8
Digitaline (Nativelle) (m)	5	1	1	3	4	—	1
Digitaline (Nativelle) (v)	2	—	—	2	1	—	1
Lanatoside C (v)	7	3	—	4	4	—	3

TABLE VI

THE EFFECT OF DIGOXIN INTRAVENOUSLY COMPARED WITH THAT OF OTHER PREPARATIONS

Drug for comparison	No of trials	Efficiency of digoxin intravenously compared with that of other preparations					
		Within 2 hours			Within 4 hours		
		Greater	Equal	Less	Greater	Equal	Less
Strophanthin	10	8	1	1	9	1	—
Ouabain	2	2	—	—	2	—	—
Strophosid	5	2	—	3	2	—	3
Digalen	2	2	—	—	1	1	—
Digitaline (Nativelle) (m)	3	2	—	1	2	—	1
Digitaline (Nativelle) (v)	4	2	—	2	2	1	1
Digoxin (m)	14	14	—	—	8	3	3
Lanatoside C (v)	8	2	1	5	2	—	6

Lanatoside C

Lanatoside C was given by mouth 5 times Once in a dose of 1 0 mg there was a temporary fall in the heart rate, which, however, rose almost to its previous level within four hours It was given four times as 3 0 mg In one case a fall in heart rate did not occur, in another there was a slight fall, while in a third a moderate fall took place In the last three there was an initial fall in rate, but it returned to the previous level within three hours As the full dose of lanatoside C is probably about 10 mg by mouth, for its rate of absorption is variable, its effect could not be compared with that of other preparations

Lanatoside C was given intravenously 11 times In a dose of 0 8 mg it had a good effect in two cases, and moderate in one As 1 0 mg it was given once producing a moderate effect, and as 1 2 mg once producing a good effect It was given 6 times as 1 5 mg with a good effect in all cases For purposes of comparison 0 8 mg intravenously was regarded as a full dose It was compared with strophanthin intravenously three times, with ouabain intravenously once, with strophosid intravenously seven times, with digalen intravenously twice, with digitaline (Nativelle) intravenously six times, with digitaline (Nativelle) by mouth five times, with digoxin by mouth seven times, and with digoxin intravenously eight times The results are shown in Table VII

Very rapid digitalis action Full digitalis effects within one hour were only seen with intravenous administration A fall occasionally occurred within 15 to 30 minutes Strophanthin produced such a rapid effect once in a dose of 1/60 gr , out of a total of nine intravenous administrations Strophosid produced a very rapid effect three times out of nine, and digitaline (Nativelle) intravenously once out of six Intravenous digoxin was given 14 times and a very rapid effect was seen 8 times With lanatoside C intravenously a very rapid effect occurred in 7 out of 10 trials

Toxic effects Several cases experienced slight nausea after some preparations, but in only three cases did vomiting occur Paroxysmal tachycardia occurred in one patient 1½ hours after receiving 1 25 mg of digoxin intravenously , it lasted for 10 hours and was not accompanied by any distress

TABLE VII

THE EFFECT OF LANATOSIDE C INTRAVENOUSLY COMPARED WITH THAT OF OTHER PREPARATIONS

Drug for comparison	No of trials	Efficiency of lanatoside C intravenously compared with that of other preparations					
		Within 2 hours			Within 4 hours		
		Greater	Equal	Less	Greater	Equal	Less
Strophanthin	3	2	1	—	2	—	1
Ouabain	1	1	—	—	1	—	—
Strophosid	7	3	1	3	3	1	3
Digalen	2	1	—	1	1	—	1
Digitaline (Nativelle) (m)	5	4	1	—	4	1	—
Digitaline (Nativelle) (v)	6	4	—	2	4	—	2
Digoxin (m)	7	4	—	3	4	—	3
Digoxin (v)	8	5	1	2	6	—	2

DISCUSSION

In earlier times ideas on the *dosage* of digitalis became confused, and its value to some extent suffered on this account Generally it was used in inadequate doses, and in the absence of any method of standardizing the strength of such a potent drug it is not surprising that physicians tended to err on the side of under-dosage Many workers have pointed out the variations in potency of preparations assayed by animal experiments and the differences in effect, when applied to man, of preparations having the same potency by animal assay (Cushny, 1925 , Gold *et al*, 1941 *a*, *b*, Gold and Cattell, 1941 , Lyon and Gilchrist, 1927), but the introduction of such pharmacological assay has nevertheless been a great advance in the use of digitalis

Mackenzie (1914) advised "steadily to push the drug, whichever preparation is employed, until a reaction is observed" He then omitted the drug for a few days, starting again on half the dosage until further adjustment became necessary He advocated instructing the patient in the symptoms of over-dosage, and found that most patients by their own sensations quickly acquired the knowledge of how

much of the drug was needed Mackenzie recorded an interesting example of the intelligent use of the drug by a patient who came under his care and who made his own infusion of foxglove and was in the habit of taking the drug whenever he was unable to lace up his boots He mainly employed the tincture, giving one drachm daily, in doses of 15 to 20 minims, in cases of marked failure until a reaction was observed, but in cases of great distress and urgency he used 2 drachms daily when the effect was usually seen in two to three days He stressed that its dosage must be determined individually for each patient

Cushny (1925) wrote that the best results are obtained only by the largest doses which can be given without gastric or intestinal symptoms, and this principle with certain modifications has been reiterated by nearly all writers on the subject since A study of methods of rapid digitalization began with Eggleston's (1915) work on the dosage of digitalis He found that the average dose of the tincture necessary to produce an ideal therapeutic effect was 0 146 cat units per lb weight, i e about 22 cat units for a patient of 150 lb , this is roughly equivalent to 33 grains of digitalis leaf White and Morris (1918) tried the method and reported favourably on it Fraser (1922) employed it in 14 cases using slightly smaller doses and concluded that it was very useful in suitable cases The amount calculated by Eggleston was that necessary to produce a full therapeutic effect just short of toxic doses, and in fact in many cases it did produce toxic effects That this dose is greater than that necessary to produce a therapeutic effect has been pointed out by many workers Marvin (1928) stated that his custom in rapid digitalization was to calculate the amount according to Eggleston's formula, and then to give a little less than the total amount Robinson, White, Eggleston, and Hatcher (1924) and Levy and Mackie (1927) found that 22 grains (1 5 g) of digitalis leaf was the average dose necessary to produce full therapeutic effect within forty-eight hours in an adult It came to be accepted that the dose of digitalis that would produce the optimum effect was less than that necessary to produce any toxic effect in the great majority of cases, that there was in fact a wider therapeutic range to the drug, and that " full dose " digitalization in accordance with Eggleston's original studies was undesirable Luten (1937) felt that the ideal plan was to ascertain the optimum level of dosage for each individual patient

The divided dose method of Eggleston, used by the above workers, allows of alteration in the succeeding doses, if indicated by the patient's irregular response to the drug, although the total amount likely to be required was calculated in advance Attempts to give the whole dose at once have been looked on with disfavour for many reasons Individual susceptibility to digitalis has sometimes resulted in toxic reaction to an average dose The inconstant response to doses calculated in accordance with the body weight has been pointed out by Lyon and Gilchrist (1927), while Gold and Travell (1941) found that the body weight was only one factor determining the amount of digitalis necessary for individual patients The relative inconstancy of preparations assayed by biological methods was a further drawback to their use for massive-dose digitalization A method of assaying digitalis in man has been produced to overcome the variable effects from preparations assayed in cats (Gold *et al*, 1942), but it is unlikely to be generally applied This difficulty, however, is removed by the use of the purified glucosides, in which the dosage by weight has been determined directly in man Further, the liability of large doses of digitalis tincture and leaf to produce vomiting from its local effect, apart from the central vomiting occurring later when the patient is saturated with the drug, does not apply to the same extent in the case of certain purified glucosides The absorption of digitalis, although apparently only about 20 per cent, is fairly constant (Eggleston and Wyckoff, 1922 , Wyckoff and Goldring, 1927), and this favours its use in large doses The most important objection to the production of full digitalis effects by one dose would appear to lie in the individual variability of the amount required, but since there is a therapeutic range of digitalis dosage, within which the optimum lies, it is unnecessary to give doses just short of producing toxic effects Gold and De Graff (1930) emphasized the wide margin of safety between the minimal therapeutic and the toxic doses They also said that in the average ambulatory cases with auricular fibrillation and some heart failure, much less digitalis was required to produce a full effect than was necessary with more severe heart failure, and that in the former cases there was a wide margin of safety between therapeutic and toxic doses, this margin, however, diminished as the failure became more severe They also pointed out that the effective concentration within the body necessary to maintain full effects was less than that required to initiate them

In spite of the opinions against one-dose methods, the experience of many workers indicates that under certain conditions the method is safe and in our view it is desirable Robinson (1920) tried the effect of a single large dose of digitalis, and gave 15 to 25 ml of the tincture of digitalis to 26 patients without producing toxic effects, he concluded that the method was safe under controlled conditions In

a series of studies of digitalis medication, Gold and his co-workers (1942 and 1944) have had a wide experience of single dose method of digitalization in which digitalis sufficient to saturate the patient is administered Digitaline, in view of its constant potency and the fact that in their opinion it is almost completely absorbed, was mostly used and in 1944 they summarized their results, having given this preparation to more than a thousand patients They found that 1 20 or 1 25 mg (equivalent to 3 cat units) by mouth, produced full digitalization in the average patient, and that minor toxic symptoms such as nausea and vomiting occurred in less than 5 per cent, the effect was complete in four to ten hours When using an amount of digitalis leaf necessary to produce an equivalent result, which they found to be from 12 to 20 cat units, vomiting occurred in 20 per cent of cases They stated that digitaline by this method was safe and effective Maintenance dosage could be started on the following day and adjusted as necessary, or in cases where a full effect had not been produced within twenty-four hours, a larger dose than would normally be required for maintenance could be given on the second day Katz and Wise (1945) confirmed the safety and efficiency of Gold's method, but stated that they preferred the divided dose technique

The water-soluble preparations of digitalis leaf for *intravenous use* vary in their potency and this has lessened their value (Haag and Hatcher, 1929 , Levy, Bruenn, and Ellis, 1932) Strophanthin intravenously, introduced by Fraenkel and Schwarz (1907), became popular and has remained so on the continent and in Latin America until the present time Indeed, the question of the value of intravenous therapy in the past has been partly concerned with the relative value of strophanthin as a cardiac remedy Owing to the development of the Eggleston method of rapid digitalization in this country and America, intravenous digitalis therapy was not common practice until the purified digitalis glucosides came into use in recent years Mackenzie (1914) stated that intravenous strophanthin may be given in doses of 1/250 gr , but considered that it was needed only in exceptional and urgent cases, for he had rarely failed to get a reaction in good time by giving digitalis by mouth The main advantage of intravenous digitalis therapy lies with its rapidity of action A digitalis effect may be seen within a few minutes The presence of gastro-intestinal upset is a further indication for its use (Wenckebach, 1910), and rectal administration is a poor alternative

Precision in dosage has been advanced as an argument in its favour (Fraenkel, 1935), because the uncertainty of intestinal absorption is eliminated

The dangers attendant on intravenous therapy have been pointed out by many authors Robinson *et al* (1924) stated that intravenous digitalization should only be used after an adequate appreciation of these and especially where digitalis seems to be urgently required Clarke (1924) spoke against its intravenous use Luten (1937) expressed no enthusiasm for intravenous therapy, but stated that when the method had to be employed, the slow injection of ouabain, well diluted and in conservative amount, probably afforded the least objectionable procedure Fishberg (1940) stated that the hope of attaining success by the intravenous administration of digitalis to patients in whom large doses of the drug by mouth failed to produce improvement had always proved illusory in his experience The intravenous use of strophanthin or digitalis, since the introduction of the purified glucosides, has more recently been advised in urgent cases by many authorities including Lewis (1937), Parkinson (1940), and White (1944)

Methods of assay, chemical analysis, and the isolation of pure glucosides have rendered digitalis therapy simpler and safer, but the exact amount required in an individual case has still to be determined by trial and error in a manner similar to that employed by Withering Its effect in reducing the heart rate in auricular fibrillation, long known to parallel closely its beneficial effects and to be responsible for many of them, provides a method for the measurement of clinical benefit—not perfect, but the best available Gavey and Parkinson (1939) discussing the effects of digitalis on patients with auricular fibrillation said that most of those with slowing of the heart rate also showed clinical benefit, but in the absence of slowing there was no benefit When the effect of *oral* and intravenous administration of the digitalis preparations was compared (Table VIII) preparations given intravenously gave more consistent results within four hours than when given orally The difference, although significant, was not great, and was partly due to the fact that some of the oral doses were too small for particular patients The impossibility of forecasting the correct dosage in advance is the chief difficulty in reaching a satisfactory comparison of the oral and intravenous methods of administration

Strophanthin in a dose of 1/100 gr gave inconstant and poor results In a dose of 1/60 gr it produced a good effect in three out of four cases, but this is much larger than the maximum safe dose in the view of most writers Strophosid gave better results than strophanthin, it produced a good effect in five out of nine cases, a rapid action being seen in three cases It worked better than strophanthin twice, and as well once, in the three cases in which

TABLE VIII

THE EFFECTIVENESS OF DIGITALIS PREPARATIONS IN DIFFERENT DOSAGE, AND GIVEN BY MOUTH OR INTRAVENOUSLY

Preparation	Dosage	No of trials	Therapeutic effect			
			Good	Moderate	Slight	None
Strophanthin (v)	1/100 gr	6	1	—	1	4
	1/60 gr	4	3	—	1	—
Strophosid	1 ml	9	5	2	2	—
Digitaline (Nativelle) (m)	1 25 mg	1	—	—	1	—
	1 30 mg	1	—	1	—	—
	1 50 mg	1	1	—	—	—
	1 75 mg	1	1	—	—	—
	2 00 mg	4	2	1	—	1
Digitaline (Nativelle) (v)	1 20 mg	3	3	—	—	—
	1 50 mg	3	3	—	—	—
Digoxin (m)	1 00 mg	1	1	—	—	—
	1 25 mg	1	—	1	—	—
	1 50 mg	8	3	4	—	1
	2 00 mg	4	3	—	—	1
	3 00 mg	4	4	—	—	—
Digoxin (v)	1 00 mg	8	7	1	—	—
	1 25 mg	2	1	—	—	1*
	1 50 mg	4	3	1	—	—
Lanatoside C (v)	0 80 mg	3	2	1	—	—
	1 00 mg	1	—	1	—	—
	1 20 mg	1	1	—	—	—
	1 50 mg	6	6	—	—	—

* Toxic effect

the drugs were compared Yet, it did not produce the consistent results obtained from digitalis preparations, and we have found no justification for the continued use of strophanthin or strophosid

Digitaline (*Nativelle*) by mouth was somewhat inconstant in its action in the dosage tried It seemed that the doses used by us were too small, and this is in accordance with the view of Stewart (1945) who regarded 2 0 mg as an average dose In the few cases in which the effect of the intravenous and oral administration of the drug was compared, no support could be found for the contention that it is completely absorbed (Gold *et al* 1941 and 1942) Intravenously, however, it produced consistently good effects within two hours in a dose of 1 2 or 1 5 mg, and compared satisfactorily with both digoxin and lanatoside C A more rapid effect, namely, within the first hour, was only seen once in six cases, and therefore less often than with the other two preparations

Digoxin by mouth did not produce consistent results in a dose less than 2 0 mg A good effect was seen in all four cases who received 3 0 mg, and no toxic effect was seen with this dose It would appear that a dose of at least 2 0 mg by mouth is advisable if a full digitalis effect is required within four hours A much more rapid effect was seen when the drug was given intravenously In the fourteen cases in which the two methods of administration were compared, a better effect was seen in all during the second hour with intravenous administration Intravenously, digoxin produced a good effect in the great majority of cases and a very rapid effect was seen in more than half When compared with intravenous lanatoside C, however, it was not so effective in six out of eight cases *Lanatoside* C intravenously in a dose of 1 5 mg produced a good effect in all of six cases to which it was given Of the ten cases who received this drug a very rapid effect was seen in seven Thus, it gave better results than any other preparations when used intravenously, but only slightly better than digoxin

Where a digitalis effect is required within an hour intravenous administration is the method of choice, and the attendant risks of such therapy are small These investigations showed that lanatoside C and

digoxin were the best preparations for intravenous use, the slightly better results obtained with lanatoside C are within the limits of experimental error With oral administration the results obtained with different dosage have naturally varied, but a full effect within four hours can be ensured if an appropriate dose of digoxin is used

CONCLUSIONS

Strophanthin and a number of digitalis preparations were submitted to a clinical trial in 20 patients with auricular fibrillation and heart failure with the object of discovering the best means of bringing about a digitalis effect quickly (rapid digitalization)

Digoxin and lanatoside C proved to be the best and digitaline (Nativelle) was scarcely less efficient

Should it be necessary to induce digitalization within two hours, digoxin as 1 5 mg intravenously or as 2 0 to 3 0 mg orally, and lanatoside C as 1 5 mg intravenously only, can best accomplish it

To establish adequate digitalization within four hours digoxin as 2 0 mg by mouth is an effective method

As it is seldom necessary to obtain a digitalis effect in less than two to three hours, and as intravenous medication may be less convenient, digoxin as 2 0 to 3 0 mg by mouth is generally the best way to induce rapid digitalization

We wish to thank Dr Donald Hunter and Dr A E Clark-Kennedy for allowing us to treat four patients under their care Sir John Parkinson, Physician to the Cardiac Department, has given us advice on the preparation of this paper

REFERENCES

Clarke, N C (1924) *Amer J med Sci*, **168**, 201
Cushny, A R. (1925) *The Action and Uses in Medicine of Digitalis and its Allies* London
Eggleston, C (1915) *Arch Intern Med*, **16**, 1
—— and Wyckoff, J (1922) *Ibid*, **30**, 133
Evans, W (1940) *Brit Heart J*, **2**, 51
Fishberg, A M (1940) *Heart Failure* 2nd ed, London.
Fraenkel, A., and Schwarz, G (1907) *Arch exper Path Pharm*, **57**, 79
Fraser, F R (1922) *Lancet*, **2**, 703
Gavey, C J, and Parkinson, J (1939) *Brit Heart J*, **1**, 27
Gold, H, and Cattell, McK (1941) *Science*, **93**, 197
——, ——, Modell, W, Kwit, N T, Kramer, M L, and Zahm, W (1944) *J Pharmacol*, **82**, 187
——, and De Graff, A C (1930) *J Amer med Assoc*, **95**, 1237
——, and Travell, J (1941) *J Pharmacol*, **72**, 41
——, Kwit, N T, Cattell, McK, and Kramer, M (1941) *Ibid*, **72**, 17
——, ——, ——, —— (1941) *Ibid*, **73**, 212
——, Cattell, McK, Otto, H L, Kwit, N T, and Kramer, M D (1942) *Ibid*, **75**, 196
——, Kwit, N T, Cattell, McK, and Travell, J (1942) *J Amer med Assoc*, **119**, 928
Haag, H B, and Hatcher, R A (1929) *Amer J Pharmacol*, **101**, 474
Katz, L N, and Wise, W (1945) *Amer Heart J*, **30**, 125
Levy, R L, and Mackie, T T (1927) *J Amer med Assoc*, **89**, 432
——, Bruenn, H G, and Ellis, S L (1932) *Amer Heart J*, **8**, 226
Lewis, T (1937) *Diseases of the Heart* 2nd ed, London
Luten, D (1937) *The Clinical Use of Digitalis* London
Lyon, D M, and Gilchrist, A R (1927) *J Pharmacol*, **31**, 319
Mackenzie, J (1914) *Diseases of the Heart* 3rd ed, Oxford
Marvin, H M (1928) *New Eng J Med*, **199**, 547
Parkinson, J (1940) *Index of Treatment* 12th ed Edited by Sir Robert Hutchinson London
Robinson, G C (1920) *Amer J Med Sci*, **159**, 121
——, White, P D, Eggleston, C, and Hatcher, R A (1924) *J Amer med Assoc*, **83**, 504
Stewart, H (1945) *New York State J Med*, **45**, 1676
Wenckebach, K F (1910) *Brit med J*, **2**, 1600
White, P D (1944) *Heart Disease* 3rd ed, New York
——, and Morris, R E (1918) *Arch intern Med*, **21**, 740
Wyckoff, J, and Goldring, W (1927) *Ibid*, **39**, 488

THE RELATIVE VALUE OF DIGITALINE PREPARATIONS IN HEART FAILURE WITH AURICULAR FIBRILLATION

BY

PETER DICK

From the Cardiac Department of the London Hospital

Received February 12, 1948

At the present time there are at least six digitaline preparations in use in this country Digitaline, first isolated by Nativelle (1869), consists of digitoxin with traces of other glucosides and impurities In the *British Pharmaceutical Codex* (1934) the only standards stipulated for the drug are a melting point not below 240° C, and a loss of not more than 1 per cent at 100° C Although the drug is not a pure substance there is no obligation for a manufacturer to carry out a biological assay of the preparation, and it may be dispensed by weight Methods of manufacture vary slightly from one firm to another and the exact processes remain a secret in some instances The use of digitaline has been recently advocated by Gold and his associates (Gold *et al*, 1942, Gold *et al*, 1944) on the grounds of its ready and almost complete absorption from the intestinal tract (Eggleston and Wyckoff, 1922, Gold and Travell, 1941) For this reason they regard it as particularly appropriate for rapid digitalization by a single adequate dose given by mouth For maintained digitalization it is a satisfactory preparation, but there are good grounds for preferring digitalis leaf for routine use (Evans, 1940) Gold, Kwit, and Cattell (1940) found that 3 cat units of Nativelle's digitaline by mouth was equivalent to 25 cat units of digitalis leaf As Cushny (1925) pointed out, the cat method is only useful to compare different samples of the same drug and to estimate their probable effect in man, and is of little value for the comparison of different preparations of digitalis given in treatment Gold *et al* (1940) found that Nativelle's digitaline by weight was two hundred times more potent than digitalis leaf standardized by the cat and frog methods, but was one thousand eight hundred times more potent in man when given by mouth This difference is largely explained by the better absorption of digitaline Evans (1940) found that 1/600 grain (0 25 mg) of Nativelle's digitaline was equivalent to 1 grain of the powdered digitalis leaf, a finding in agreement with the observations of Campbell (1938) Digitaline (Allen and Hanbury), however, supplied in granules similar in appearance and dosage to Nativelle's digitaline, was not found to be so effective in a dosage of 1/240 grain, as was Nativelle's preparation in a dose of 1/600 grain (Evans, 1940)

The present work was undertaken to ascertain whether there was any variation in the value of six commercial preparations of digitaline when dispensed to patients with heart failure and auricular fibrillation The method for this clinical assay was the same as that described by Evans (1940) The preparations tested, marketed by six different firms, were designated A, B, C, D, E, and F

Thirteen patients, all of whom had been under observation for some time, were chosen for the clinical trial Three failed to complete the course, two owing to irregular attendance and the third owing to admission to hospital with an exacerbation of heart failure, leaving 10 in the series, six were men and four women Their ages varied from 24 to 63 Auricular fibrillation and heart failure were present in all, associated with hypertension in two and with mitral stenosis in the remaining eight They were all treated as out-patients and they led their usual lives, the majority being at work With one exception they had been receiving powdered digitalis leaf for prolonged periods before the tests The patients attended each fortnight, their statement on progress was recorded at each visit, and after a short rest the apical rate was counted over three successive half-minute periods, and the average rate was taken They were examined clinically and by cardioscopy at intervals according to need At each attendance they were given a different digitaline preparation for the following test period of 14 days, thus ensuring that by the end of the period each patient had been fully under the influence of the fresh preparation for

a few days at least One grain of powdered digitalis leaf and one pill (1/600 grain) of each digitaline preparation were given as single doses, while the number of doses a day was different for different patients according to their habitual requirements before the clinical trials were started, and it was kept constant for each patient throughout the investigation The order in which the preparations were given was deliberately varied in each case The following is an account of one case

Male, aged 45, with mitral stenosis, aortic incompetence, auricular fibrillation, and heart failure

At the age of 11 the patient had rheumatic fever He was prevented from playing games at school as a consequence of this, and was rejected from the army during the 1914–18 war on account of his heart Twenty years ago he had a small hæmoptysis and a larger one thirteen years later Dyspnœa had been present for seven years and recently this had become worse and was present at rest In the last five weeks he had been unable to work Hæmoptysis recurred a week before He had been receiving digitalis for the last three months from his doctor who sent him to the Cardiac Department for treatment.

He was breathless when examined and showed slight cyanosis and venous congestion in the neck The pulse was 80 and was irregular from auricular fibrillation The blood pressure was 160/55 There was no œdema The apex beat was displaced outwards to the anterior axillary line Systolic and mid-diastolic murmurs were heard in the mitral area, as well as aortic, systolic, and diastolic murmurs Fine crepitations were found at both bases and the liver was distended and tender The urine was normal Cardioscopy showed great cardiac enlargement, involving the left ventricle, left auricle, right auricle and the conus and pulmonary artery, there was moderate pulmonary congestion He was admitted to hospital the same day and responded readily to treatment with rest, restricted fluids, digitalis and two injections of neptal He was discharged four weeks later, with only slight pulmonary congestion, and he continued to take 1 grain of digitalis leaf twice daily He was included in the present series on August 13, 1946, and his progress during the clinical trials is set out below in tabulated form

Date	Medicine during previous 14 days	Digitalis dose (given twice daily)	Heart rate a minute	Patient's statement on progress
13 Aug.	Digitalis leaf	1 grain	68	Well
27 Aug	Drug E	1/600 ,,	78	Well
10 Sep	Drug C	1/600 ,,	65	Very well
24 Sep	Drug A	1/600 ,,	81	Well
8 Oct	Drug D	1/600 ,,	57	Very Well
22 Oct.	Drug F	1/600 ,,	87	Well
5 Nov	Drug B	1/600 ,,	65	Well

I

Clinical signs of heart failure did not increase during the period of trials, and the urinary output was satisfactory

The results for all six digitaline preparations are summarized in Table I

TABLE I

HEART RATE IN TEN PATIENTS WITH AURICULAR FIBRILLATION AFTER TREATMENT WITH SIX DIFFERENT KINDS OF DIGITALINE

Case No	Age	Sex	Weight in lb	No of doses daily	Drug A	Drug B	Drug C	Drug D	Drug E	Drug F	Average
1	24	F	149	3	109	85	87	85	91	87	91
2	58	M	180	2	83	68	85	73	76	63	75
3	44	M	144	2	103	82	85	84	79	77	85
4	47	M	132	2	82	70	73	79	82	89	79
5	59	M	127	2	97	81	73	99	82	108	90
6	48	M	146	2	109	95	102	80	81	101	95
7	63	M	201	2	114	104	79	84	80	113	96
8	45	M	126	2	81	65	65	57	78	87	72
9	27	F	101	2	53	65	61	51	58	52	57
10	56	M	140	2	87	79	77	79	87	81	82
		Average			92	79	79	77	79	86	

The results were examined statistically by the analysis of variance method (Fisher, 1937) There was found to be a significant difference between the effect of the drugs, due to the high heart rates obtained with drug A, and the probability of this difference occurring by chance was less than 1 in 100

In order to check these findings another series of trials was carried out with the same digitaline preparations on twelve other patients with auricular fibrillation and heart failure Three patients had to be excluded from the series owing to irregular attendance, and two on account of an increase in the severity of the heart failure necessitating admission to hospital In the seven remaining patients mitral stenosis was the underlying cause of the heart failure in four and hypertension in three The same procedure was followed in carrying out the trials but the order in which the drugs were given was decided by drawing lots The results are summarized in Table II

Applying the same statistical method to the results in Table II, Drug A is again found to be significantly inferior to the remaining five preparations, the probability of such a result arising by chance being about 1 in 21

It is apparent from these two series of trials that

TABLE II

HEART RATE IN SEVEN PATIENTS WITH AURICULAR FIBRILLATION AFTER TREATMENT WITH SIX DIFFERENT KINDS OF DIGITALINE AND WITH POWDERED DIGITALIS LEAF

Case No	Age	Sex	Weight in lb	No of doses daily	Drug A	Drug B	Drug C	Drug D	Drug E	Drug F	Digitalis leaf	Average
1	64	M	201	2	101	70	85	77	91	83	81	84
2	54	M	126	2	102	97	87	90	87	90	89	92
3	67	F	115	2	91	89	97	101	80	91	81	90
4	42	F	154	2	85	82	86	39	87	91	67	82
5	36	M	143	2	113	69	73	81	77	72	70	79
6	45	M	126	1	74	60	66	71	69	65	71	68
7	54	F	132	1	79	81	70	83	83	87	89	81
Average					92	78	81	83	82	83	78	
Average for first series					92	79	79	77	79	86		

Drug A is not as efficacious as the remaining preparations There was no significant difference between the effects of the other drugs It is now recognized that the dosage of digitalis necessary to produce an adequate clinical effect in any given patient lies within a fairly wide range, particularly when there is only slight or moderate heart failure present (Gold and De Graff, 1930), and it is probable that the inferiority of Drug A demonstrated in these two series of trials represents a fairly considerable difference of potency It is unsatisfactory that preparations with the same or similar names, but differing in clinical potency, should be marketed by different firms A practitioner prescribing digitaline cannot be certain that his patient will always receive a preparation of the same potency, and undesirable toxic effects may be produced by one drug, while another may have an inadequate effect There is no obligation on the manufacturers to standardize their products by biological assay, nor is it certain to what extent this would result in a greater uniformity of digitaline preparations The explanation of the inconsistent results obtained with digitaline preparations may lie in the method of manufacture In some instances certain stages of the procedure are a closely guarded commercial secret, and there is no certainty that the final products are identical with the different processes used, thus rendering the standardization of different digitaline preparations by biological assay of less value Digitalis leaf has been found to produce consistent clinical results by many observers Its method of preparation is known to all and is simple, and its standardization by biological assay is adequate for clinical purposes It is suggested that if a standard method of preparation were laid down for digitaline, as it is for digitalis leaf, and biological assay of the product were compulsory, variations in potency might be reduced At the present time powdered digitalis leaf would appear to be preferable for maintained digitalization

SUMMARY

The effect of six different commercial preparations of digitaline has been tried in two series of ten and seven patients with heart failure and auricular fibrillation One preparation was much less effective than the other five in both trials It is suggested that a standardized procedure for the manufacture of digitaline should be introduced, and that biological assay should be made compulsory The variability in the potency of digitaline preparations suggests the advisability of using digitalis leaf for continuous digitalization at the present time

I wish to thank Dr D Jennings for his advice on the statistical analysis of the results of this investigation

REFERENCES

British Pharmaceutical Codex (1934) London
Campbell, M (1938) *Guy's Hosp Gazette*, **52**, 177
Cushny, A R (1925) *Digitalis and its Allies* London
Eggleston, C, and Wyckoff, J (1922) *Arch Intern Med*, **30**, 133
Evans, W (1940) *Brit Heart J*, **2**, 51
Fisher, R A (1937) *The Design of Experiments* 2nd ed Oliver and Boyd, Edinburgh
Gold, H, Kwit, N T, and Cattell, McK (1940) *J Pharmacol*, **69**, 177
Gold, H, Cattell, McK, Modell, W, Kwit, N T, Kramer, M L, and Zahm, W (1944) *J Pharmacol*, **82**, 187
——, and De Graff, A C (1930) *J Amer med Ass*, **95**, 1237
——, Kwit, N T, Cattell, McK, and Travell, J (1942) *Ibid*, **119**, 928
——, and Travell J (1941) *J Pharmacol*, **72**, 41
Nativelle, J (1869) *Journ Pharm Chimi, Paris*, **9**, 255

THE HEART IN RHEUMATOID ARTHRITIS

BY

E J FISCHMANN AND F J GWYNNE

*From Auckland, New Zealand**

Received August 28, 1947

Recent reports suggesting the presence of cardiac lesions at autopsy in a high proportion of patients with rheumatoid arthritis appear to be in conflict with clinical experience In view of the scarcity of comprehensive clinical, and the absence of radiological studies of the heart in rheumatoid arthritis, and also of the contradiction between clinical and pathological findings, there appears to be a need of further clinical and radiological material

The incidence of heart disease at autopsy in patients suffering from what is variously called nodular rheumatism, chronic rheumatism, and genuine arthritis deformans is, in earlier studies, given as between 30 to 50 per cent (Charcot, 1881, Kast, 1901, Grzimek, 1932, Klinge, 1933), the heart disease being more frequent in secondary than in primary chronic rheumatism Changing conceptions of the ætiology and classification of rheumatic diseases in more recent years are an obstacle to the direct evaluation of these findings

More recently cardiac lesions " indistinguishable from those of rheumatic fever " were described in 56 per cent of 24 patients with rheumatoid arthritis at necropsy by Baggenstoss and Rosenberg (1941 *a*, *b*), in 22 per cent of 23 patients by Bayles (1943), and in 66 per cent of 38 patients by Young and Schwedel (1944)

In a clinical study Dawson (1933) found 7 cases of manifest rheumatic heart disease in 100 patients suffering from rheumatoid arthritis Colver (1937) in 69 children with Still's disease detected carditis during life in only 1, of 4 studied at autopsy none had carditis Hench and Rosenberg making a study of all their arthritic patients on a given date (1941) found none with clinical or electrocardiographic evidence of carditis The incidence of clinically manifest rheumatic heart disease in a series of rheumatoid arthritis patients, examined by Bayles and McGinn (1943) was 5 per cent Young and Schwedel's series (1944) occupies a unique place here, since the diagnosis of rheumatic heart disease was made during life in 18 of 32 patients with rheumatoid arthritis this, together with the high number of positive cardiographic findings, suggests selective accumulation of patients with heart disease Elman (1944) in 100 patients with rheumatoid arthritis found 8 with " rheumatic carditis," 5 of whom gave no history of rheumatic fever, he also observed 22 patients in whom rheumatic carditis coexisted with rheumatoid arthritis Rogen (1947) found only one patient with mitral disease in a group of 33 with rheumatoid arthritis

Material and Methods

The 60 patients studied here were selected from 150 patients with rheumatoid arthritis, after eliminating those where the clinical picture was not typical, where rheumatic fever occurred in the past, where chest deformity or inability to stand upright prevented satisfactory radioscopy, and where records were not sufficiently complete The criteria of diagnosis were those laid down by the Committee of the International League against Rheumatism (1934), Poynton and Schlesinger (1937), and a Committee of the American Rheumatism Association (1942) The clinical picture was regarded as typical if the smaller joints of the hand were characteristically involved in addition to the larger joints, and if joint involvement was accompanied by all or most of the following signs of general systemic involvement anæmia, weight loss, general malaise, easy fatigability, and increased sedimentation rate Patients in whom the process was limited to the larger joints or to a single joint, those in whom its onset coincided with the menopause, and those with a history of rheumatic fever or with

* Paper read in Wellington on May 22, 1947, before the Sixth Science Congress of the Royal Society of New Zealand

raised blood pressure were excluded Selection in this manner resulted in a group of patients with normal blood pressure, suffering from advanced rheumatoid arthritis of considerable duration

Forty-three of the 60 patients were women Ages ranged from 25 to 69 years, 5 being in the third, 6 in the fourth, 13 in the fifth, 21 in the sixth, and 15 in the seventh decade Healed pulmonary tuberculosis was found in 2 patients (Cases 4 and 32), and duodenal ulcer in 1 (Case 49) From each patient a relevant history was taken and a careful physical examination made, including X-ray and electrocardiogram

Clinical Manifestations of Heart Disease

Only 3 of these 60 patients presented clinical manifestations of heart disease

Case 9, male, aged 59, with extensive articular involvement, was the only one in the series who had a mitral diastolic murmur Radiologically his heart showed moderate left ventricular enlargement Displacement of the barium filled gullet as a result of left auricular enlargement was not present and the electrocardiographic record was normal Subjective symptoms related to the heart were absent

Two patients, both women, aged 69 and 62 respectively (Cases 2 and 30), displayed signs of heart failure with congestion There were no acoustic abnormalities, the cardiac silhouette was normal, and satisfactory response to digitalis and mercurial diuretics was obtained in both The electrocardiogram in Case 2 showed auricular fibrillation In the absence of signs of valvular involvement and in view of the patient's age, heart failure due to coronary disease appears the leading possibility with rheumatic heart disease not excluded

Faint systolic apical murmurs were found in a number of patients Some complained of slight shortness of breath and palpitation Apart from the patients with frank heart failure these symptoms were mild, and it seems that their presence is of no specific significance in view of the anæmia and general debility characteristic of rheumatoid arthritis

Electrocardiographic Changes in Rheumatoid Arthritis

Master and Jaffee (1932) taking daily cardiograms in 17 patients for 53 days, found only the slightest evidence of myocardial involvement Logue and Hanson (1944) in 100 cases with prolonged P–R interval found that rheumatoid arthritis has been present in 5 Young and Schwedel (1944) found changes in 7 of 22 patients, 4 having auricular fibrillation The changes in rheumatic carditis are transient and very variable, most cardiographic abnormalities having been encountered and a prolonged P–R interval being the most frequent

We have examined 131 cardiograms in these 60 patients, and except for low voltage curves have found only 3 with significant changes A woman, aged 46, with typical active rheumatoid arthritis had a normal curve, but a year later, when she was improving after chrysotherapy, had S–T depression in the first and elevation in the third lead A man, aged 69, had a normal curve first, but later developed auricular fibrillation and congestive heart failure A male, aged 69, with some cardiac enlargement, had a P–Q interval of 0 22 seconds As the second and third patients were 69, these findings have little, if any, significance

Low Voltage Low voltage in the standard leads has occurred more frequently in the present series than any other single cardiographic abnormality A voltage of all deflections in all leads of 0 5 mV or less is regarded as abnormal, and was found in 5 of the 60 patients (8 per cent) Low voltage has been associated with other cardiographic abnormalities in 2 patients, and with radiological cardiac enlargement and congestive heart failure in one of these The 3 other patients of this group have presented no further evidence of heart disease The ages of the 5 patients with low voltage were 57, 67, 67, 69, and 69 years In 18 patients (30 per cent) the voltage was 0 8 mV or less

The incidence of low voltage in healthy subjects shows considerable variation from author to author It ranges from none (Shipley and Hallaran, 1936, Hoskin and Jonescu, 1940, and Larsen and Skulason, 1941), 1 8 (Viscidi and Geiger, 1943), and 3 per cent (Levitt, 1939, Chamberlain and Hay, 1939) to 6 per cent (Leach, Reid, and White, 1941), and 8 per cent (McFarland *et al*, 1939) A voltage of less than 0 8 mV was found in 30 per cent by McFarland *et al* (1939) That age does not determine the occurrence of low voltage is suggested by the fact that both the Viscidi and Geiger (1943) and the McFarland (1939) groups consisted of young, healthy airmen.

In order to obtain further information, minimum, maximum, and average values of R I, R II, and R III in the first tracing obtained from each patient were determined Table I shows a comparison between values found in this series and normal controls reported by other workers in healthy subjects and also a control series of 50 healthy subjects

In the present series the incidence of voltage below 0 5 and below 0 8 mV respectively is as high as the highest in published work It is higher than in a series of 50 healthy controls The voltage of R in the present series is less than in any reported by other authors, with the exception of Lewis and Gilder (1912) and less than in a series of 50 normal controls examined by us In view of the elasticity of normal standards it is difficult to decide whether

TABLE I

COMPARISON OF THE VOLTAGE TO R IN RHEUMATOID ARTHRITIS WITH PUBLISHED DATA AND NORMAL CONTROLS

	Chamberlain and Hay (1939)	Hoskin and Jonescu (1940)	Larsen and Skulason (1941)	Wilson and Nyboer (1937)	Lewis and Gilder (1912)	Present study	
						Arthritis group	Control group
No patients	302	50	100	104	52	60	50
Minimum							
R I	1 5	—	1 8	1 5	2 0	1 0	2 1
R II	3 6	—	4 1	4 0	5 5	2 0	2 0
R III	0 5	—	0 7	1 0	—	1 0	0 5
Maximum							
R I	18 6	—	12 4	19 4	12 0	17 0	14 3
R II	23 6	—	23 4	23 6	16 5	21 0	21 0
R III	20 5	—	20 8	20 0	13 5	14 0	20 2
Average							
R I	8 0	9 8	7 7	5 73	5 16	4 85	7 07
R II	12 7	13 5	10 2	11 90	10 32	8 61	9 28
R III	7 3	6 5	4 6	7 99	6 61	3 95	4 03

the above findings really show a tendency to lower voltage, in patients with rheumatoid arthritis

Of the conditions associated with rheumatoid arthritis, anæmia (Turner, 1932, Szekely, 1940) and generalized wasting (Speckman and Rich, 1931, Steuer, 1934, Leach *et al*, 1941) were found to coincide with low voltage Considering that pericarditis is one of the known causes of low voltage, it is of interest that pericarditis was found at autopsy in a proportion of patients with rheumatoid arthritis by Baggenstoss and Rosenberg (1941 *a*, *b*) Bayles (1943), and Young and Schwedel (1944)

RADIOLOGICAL STUDY OF THE HEART IN RHEUMATOID ARTHRITIS

Published work on the heart in rheumatoid arthritis, as indicated above, deals chiefly with anatomical and clinical findings Extensive search of the journals has failed to reveal a comprehensive radiological study Rogen (1947) seems the only author who attempted cardiac X-ray examinations in some of his 33 rheumatoid arthritis patients, but gave it up because of difficulties in positioning, due to inability of the patients to stand upright

Method As it was intended to use heart size prediction tables based on height and weight, the 60 patients with rheumatoid arthritis in this series were selected from patients able to stand upright In addition a control group of 100 patients, seen in the course of daily radiological routine by one of us (F J G) was also investigated, they were selected to show an age distribution similar to the rheumatoid arthritis group, and patients with raised blood pressure were again excluded Using prediction tables based on weight in patients in whom weight loss is a prominent feature, the possibility arose that the impression of cardiac enlargement might be produced where discrepancy between predicted and actual heart measurement was due to discrepancy between the patient's present and past weight To test and minimize this source of error, the control group consisted of patients most of whom had shown considerable loss of weight

The heart was examined by frontal teleradiogram and fluoroscopy including study of the barium-filled gullet To determine heart size three standards were used

(a) The transverse cardiac diameter was compared with prediction tables based on height and weight, as devised by Ungerleider and Clark (1939) Generally 80 per cent of normals fall within ±10 per cent of the predicted transverse diameter, not more than 10 per cent exceed +10 per cent This means that a few normal hearts are classified as being enlarged, and others with minor degrees of enlargement are not recognized With these qualifications enlargement of the heart exists when the actual transverse measurement deviates from the predicted measurement by 10 per cent or more (b) According to Comeau and White (1942) in the great majority of cases a transverse diameter greater than 13 4 cm in males or 12 4 cm in females is a sign of cardiac enlargement Considered as a group the transverse diameter will be below 13 4 cm in 90 per cent of normal males and below 12 4 cm in 94 per cent of normal females (c) In using radiological methods for estimating heart size the difficulty of applying mathematical methods to biological

problems must be remembered (Gwynne, 1933, Comeau and White, 1942) The diagnosis of cardiac enlargement was therefore made only if in addition to showing increased measurements, the cardiac silhouette was judged to be enlarged on inspection

Table II shows that subjective judgment and measurement were not always in accord That radiographic measurement alone should not be relied upon to diagnose cardiac enlargement is indicated by the fact that different hearts are shown as enlarged by different standards (Table II)

Heart Size As measurements of heart size and subjective judgment (Table II) have given divergent results they will be discussed separately

A transverse diameter of more than 10 per cent in excess of the predicted figure, was found in 15 patients (25 per cent) in the rheumatoid group, with only 8 per cent in the control series In 8 patients (13 per cent) in the rheumatoid group the transverse diameter was 15 per cent or more in excess of the predicted figure, with not a single instance in the control series The figure of 12 4 cm in females and 13 4 cm in males was exceeded by 27 patients (45 per cent), the corresponding figure in the control series being 10 per cent

TABLE II

PATIENTS IN WHOM THE HEART WAS FOUND ENLARGED ACCORDING TO ONE OR MORE OF THE THREE STANDARDS EMPLOYED

Case No and type of enlargement	Transverse cardiac diameter in excess of predicted +10% of 12 4 in women, 13 4 in men				Heart judged enlarged
	Predicted (cm)	Actual (cm)	Excess (percentage)	Actual (cm)	
1	—	—	—	13 3 F	—
5 LA*	—	—	—	— F	—
6 LV,LA	11 9	13 2	11	13 2 F	+
7 G (Fig 1)	—	—	—	14 0 F	++
9 LV	11 6	14 0	21	14 0 M	+
19 LV	11 6	13 1	13	13 1 F	+
20 LV (Fig 2)	—	—	—	15 0 M	++
24 G (Fig 3)	13 1	15 1	15	15 1 M	++
27	—	—	—	13 5 F	—
28	11 7	13 2	13	13 2 F	—
30	—	—	—	13 2 F	—
32 G	11 5	13 2	15	13 2 F	+
35 LV,LA (Fig 4)	11 1	13 6	23	13 6 F	++
36 LV,LA	—	—	—	15 0 M	+
43 LV (Fig 5)	11 7	14 0	20	14 0 M	++
46 LV (Fig 6)	—	—	—	14 7 M	++
48 LV (Fig 7)	13 6	15 6	15	15 6 M	++
51	11 8	13 5	11	13 5 F	—
53 G	11 6	14 5	25	14 5 F	+
56	10 9	12 3	13	— F	—
57	11 2	12 4	11	— F	—
58	10 4	11 7	13	— F	—
60 LV (Fig 8)	11 2	13 1	17	13 1 F	++

* LV=enlargement mainly left ventricular G=enlargement generalized LA=left auricular enlargement causing gullet displacement F=female M=male +=moderate enlargement ++=pronounced enlargement

Eight women with a transverse diameter between 12 5 and 13 0 cm, but with no other evidence of cardiac enlargement, are not included in this table

Discrepancy was particularly obvious with regard to the standard of Comeau and White (1942), the number of hearts with transverse diameters in excess of their figures was strikingly high (45 per cent), while on inspection many appeared to be normal For this reason the relation of each heart examined to this standard was recorded, but the result was not regarded as decisive in judging heart size in any given patient, although considered significant in group comparison

On inspection the heart was judged to be enlarged in 14 patients (23 per cent) Enlargement was regarded as pronounced in 8 (13 per cent); and moderate in 6 (10 per cent) The radiograms showing pronounced enlargement are reproduced in Fig 1 to 8 Subjective judgment differed from that based on prediction tables In Cases 7 and 46,

FIG 1 —Case 7, female 52 years Generalized enlargement by inspection although measurement at upper limit of predicted range Clinically normal heart Cardiogram normal

FIG 2 —Case 20, male, 63 years Mainly left ventricular enlargement by inspection, although measurement at upper limit of predicted range Clinically normal heart, Cardiogram normal

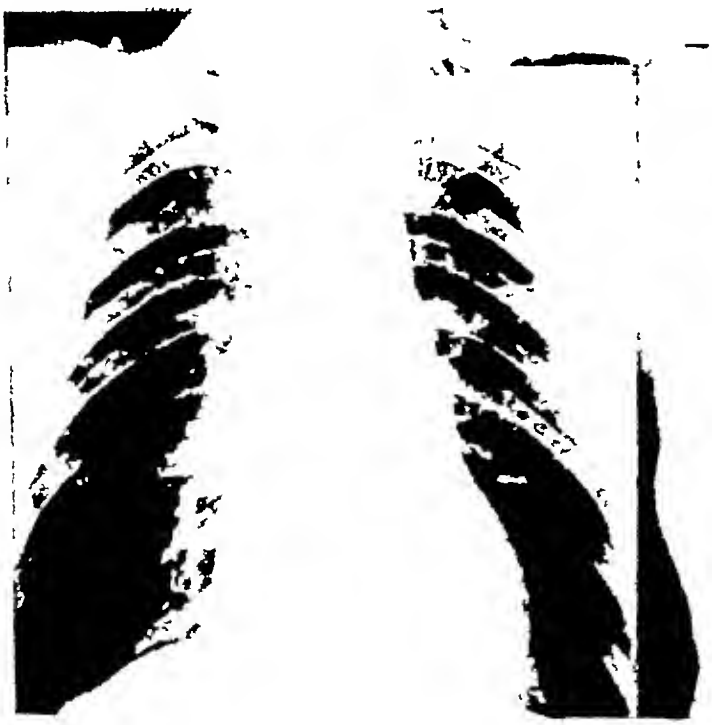

FIG 3 —Case 24 male 69 years Generalized cardiac enlargement by inspection and measurement Clinically normal heart P–Q phase 0 22 sec

FIG 4 —Case 35, female, 63 years Left auricular and left ventricular enlargement by inspection and measurement Clinically moderate shortness of breath on exertion Cardiogram normal

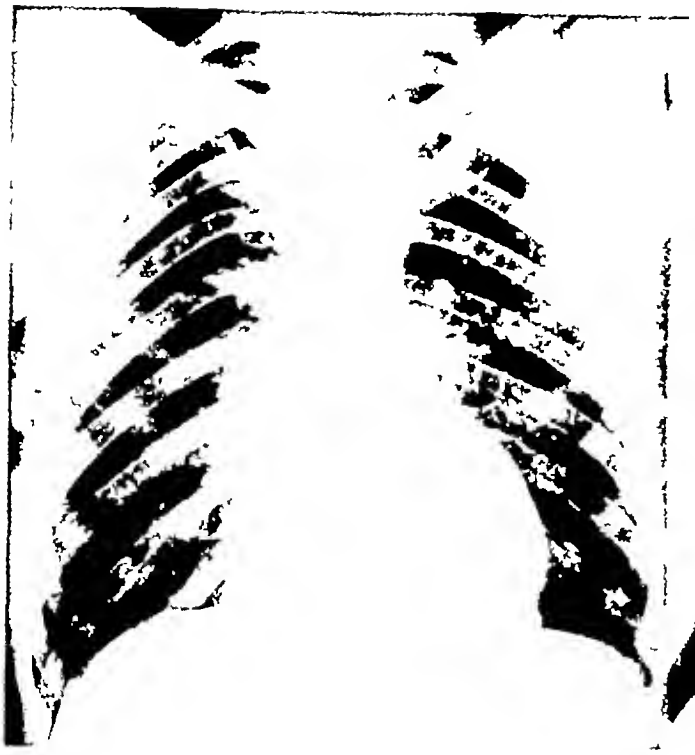

FIG 5 —Case 43, male, 26 years Mainly left ventricular enlargement by inspection and measurement Heart clinically normal Cardiogram normal

FIG 6 —Case 46, male, 46 years Mainly left ventricular enlargement by inspection, although measurement at upper limit of predicted range Clinically normal heart Cardiogram normal

FIG 7 —Case 48, male, 65 years Mainly left ventricular enlargement by inspection and measurement Triple rhythm with extra sound in mid-diastole, otherwise clinically normal Normal cardiogram

FIG 8 —Case 60, female, 23 years Mainly left ventricular enlargement Palpitation and shortness of breath on moderate exertion, otherwise clinically normal Normal cardiogram

the actual transverse diameter was less than 10 per cent in excess of the predicted figure although on inspection pronounced enlargement was deemed to be present On the other hand, of the patients whose transverse diameter was more than 10 per cent in excess of the predicted figure, 4 were not judged to be enlarged (Cases 28, 51, 56, 58) Of the 8 patients whose hearts were 15 per cent or more in excess of the predicted measurements all were judged to be enlarged, 3 moderately, and 5 considerably (Table II)

In clinical practice the radiological diagnosis of cardiac enlargement is usually made in a patient presenting signs and symptoms of a well-known heart disease and in most cases finally rests on a combination of radiological and clinical judgment The situation is different here, a type of patient being examined in whom enlargement of the heart has not been demonstrated radiologically in the past, and who is suffering from a disease where the presence of cardiac involvement is regarded as questionable and is the unknown factor being investigated Clinically these patients are characterized by the absence of signs or symptoms of heart disease Pronounced cardiac enlargement such as is present in 8 patients in the present series can be diagnosed on radiological grounds alone. The diagnosis of slight to moderate enlargement on the other hand should be made only in the presence of supplementary evidence (Parkinson, 1933, Bramwell, 1933) Clinical manifestations of heart disease, which are the usual source of such evidence, are strikingly absent in patients with rheumatoid arthritis It is suggested, on the other hand, that the evidence required to diagnose moderate cardiac enlargement in these patients is supplied from the following three sources

Study of Patients as a Group Prediction tables of heart size are composed of average figures derived from the study of large groups The error involved in their use will therefore be smaller if applied to a group instead of to an individual If in a single patient radiological determination of the transverse cardiac diameter in itself may not suffice to reveal the presence of *moderate* cardiac enlargement, in a group showing excessive measurements a tendency to cardiac enlargement may be assumed In the single patient the impression of cardiac enlargement may be created or hidden by variations within the physiological range, in a group variations in the two directions will tend to neutralize each other Comparison of the rheumatoid patients with the control group shows that a clear line of demarcation between patients with normal heart size and those with a tendency to enlarged hearts can be achieved by applying this method to groups instead of individuals

Comparison with Anatomical Findings Estimates of radiological enlargement in the present series are lower than the incidence rate of enlarged hearts reported at autopsy Baggenstoss and Rosenberg (1941 *a, b*) found hearts of greater than normal weight in 11 of 25, Bayles (1943) in 13 of 23, and Young and Schwedel (1944) in 19 of 33 patients These figures include cardiac enlargement due to rheumatic heart disease and to other causes, including hypertension Considering that radiological heart size estimation will inevitably miss a number of moderately enlarged hearts, and that the present series did not include patients with hypertension, there is no obvious discrepancy between the autopsy and radiological data

Radiologically revealed cardiac enlargement although in disharmony with the absence of clinical manifestations, is in keeping with the only positive group of facts we possess about the heart in rheumatoid arthritis, namely the findings at autopsy Discrepancies between radiological and clinical findings would appear no more "startling" (Hench, 1941, referring to the anatomical findings) than the much discussed discrepancy between anatomical and clinical findings The question arises here as to what extent these two in themselves independent discrepancies will serve to explain each other In the absence of symptoms and signs radiological enlargement may be the only clinical manifestation of the changes found at autopsy

Pronounced Cardiac Enlargement Cardiac enlargement of a pronounced degree was found in 8 out of 60 patients with rheumatoid arthritis In addition, 6 patients had hearts suggesting enlargement By themselves these may not be regarded as evidence of frequent cardiac enlargement If, however, an increased number of hearts are found to be at the upper limit of normal and 8, as compared with none in the control group, are found to be enlarged to a pronounced degree, the suggestion emerges that the hearts are actually increased in size in more than 8 out of 60 patients

Radiological Configuration of Enlarged Hearts Of the 8 considerably and 6 moderately enlarged hearts, left ventricular enlargement alone was found in 7, left ventricular and left auricular enlargement in 3, and generalized increase in size in 4 Left auricular enlargement alone was present in 1, and with left ventricular enlargement in 3 patients

Predominantly right-sided enlargement was not seen in any of the hearts examined It appears that the left ventricle is the chamber chiefly affected, and it was enlarged in every patient with an abnormal heart, excepting the one in whom left auricular enlargement was the only change present

Discussion

The result of the above investigation suggests the *presence* of radiologically evident, mainly left ventricular cardiac enlargement in 23 per cent of patients with rheumatoid arthritis On the other hand it appears that the cardiac abnormality underlying the enlargement is characterized by the *absence* of recognized clinical and electrocardiographic manifestations of heart disease

In an attempt to explain this discrepancy, published reports regarding autopsy findings in rheumatoid arthritis will have to be taken into consideration Three recent anatomical studies suggest that in patients with rheumatoid arthritis a disease of the heart is present which is "indistinguishable" from that found after

rheumatic fever (Baggenstoss and Rosenberg, 1941 *a*, *b*, Bayles, 1943, Young and Schwedel, 1944) The incidence of cardiac involvement in the three groups varies from 26 to 66 per cent, but unanimity exists with regard to certain points It seems that the lesions found resemble rheumatic carditis more closely than any known cardiac lesion and that pericarditis, chronic or subacute myocarditis, gross valvular distortion and cardiac enlargement was present in a proportion of cases The participation of the various chambers in the enlargement is not stated

In addition to these changes, coronary sclerosis with or without myocardial infarction was found in a smaller proportion of patients in the three above groups Coronary sclerosis as a cause of radiologically manifest cardiac enlargement in patients with rheumatoid arthritis is, in addition to its low incidence in the above three autopsy series, excluded by the following points The role of coronary sclerosis alone in causing cardiac hypertrophy is still a matter of controversy That it is able to cause enlargement is stated by Palmer (1937), denied by Jones (1930), Gross and Spark (1937), and Maun (1941) Clawson (1939) states that narrowing of the coronary orifices in syphilitic aortitis fails to produce hypertrophy in the absence of a valvular lesion If only 1 out of every 2 or 3 patients with coronary sclerosis is expected to have an enlarged heart, to explain cardiac enlargement in 23 per cent, as found in the present series, it would have to be assumed that coronary sclerosis was present in 46 to 69 per cent If coronary sclerosis were the chief cause of cardiac enlargement in rheumatoid arthritis, an increase of the incidence of cardiac enlargement with age could be expected Table III shows that

TABLE III

INCIDENCE OF ENLARGED HEARTS DECREASING WITH INCREASING AGE

Age group Years	All rheumatoid arthritis cases	Transverse diameter 10% in excess of predicted		Heart judged enlarged	
		No	Percentage	No	Percentage
20–39	11	4	36	3	27
40–59	34	8	24	8	24
60–79	15	3	20	3	20
20–79	60	15	—	14	—

this is not the case, as the percentage of enlarged hearts actually decreases with age In the control group only 8 per cent exceeded predicted cardiac measurements Neither clinical nor cardiographic evidence of coronary sclerosis was demonstrated in the arthritic patients

If coronary sclerosis is excluded, only the changes "resembling rheumatic carditis occur with enough regularity to need consideration as the basis of the radiological cardiac enlargement Whether these anatomical changes mean that rheumatic carditis is actually present, or whether they are an expression of rheumatoid arthritis ('rheumatoid carditis Rosenberg *et al*, 1944) is undecided This problem is closely linked with the controversy regarding the relationship of rheumatic fever and rheumatoid arthritis Since the ætiology of these two diseases is unknown, proof of their identity must be indirect, and either attempting to show the similarity of the conditions under which they occur, or the similarity of certain pathological and serological changes found in both The two diseases tend to occur in identical families and individuals, and their geographic distribution and seasonal incidence is similar The identity of the rheumatic nodule in the two diseases has been pointed out by Coombes and Coates (1926), Dawson (1933) and by Poynton and Schlesinger (1937), but questioned by Bennett *et al* (1940) Immunological evidence suggests the presence of a streptococcal antibody in both diseases, but in rheumatic fever it is a lysin (Todd, 1932 Coburn and Pauli, 1932), in rheumatoid arthritis an agglutinin (Dawson *et al*, 1934) The response to salicylates is different in the two diseases Inflammatory granulomatous changes regarded as specific for rheumatoid arthritis, were found by Steiner *et al* (1946) in muscle tissue obtained by biopsy Similar changes were also found (Curtis and Pollard, 1940, Freund *et al*, 1942) in the peripheral nerves These changes were not demonstrated in rheumatic fever The above data suggest that while evidence of the pathological and immunological identity of the two diseases is incomplete and in view of more recent investigations open to doubt, the two diseases tend to occur under similar circumstances, and in the same individual For this reason, and because the cardiac changes described at autopsy in rheumatoid arthritis resemble rheumatic fever more closely than any other known cardiac disease, the possibility that the radiological enlargement is due to rheumatic carditis deserves attention

If so, one must explain the discrepancy between the presence of the familiar clinical and radiological picture in chronic rheumatic carditis and its absence in these patients This need still exists, if the anatomical changes are an expression of rheumatoid carditis," because regardless of ætiology, it is still not explained why gross cardiac disease remains without symptoms or signs

The heart disease assumed to be present in rheumatoid arthritis is characterized by the presence of left ventricular enlargement, and the absence of gross congestive heart failure, acoustic abnormalities, auricular fibrillation, and cardiographic changes

The absence of congestive failure is partly explained by assuming a milder myocardial process due to three causes (1) A difference in the age at onset, which will alter the course of these two forms of heart disease owing to the greater sensitivity of the heart in youth to the rheumatic agent (Poynton and Schlesinger, 1937, Sangster, 1940 De Liee *et al*, 1943), and the greater capacity of the young heart muscle to hypertrophy (Palmer, 1937) Hypertrophy, although initially increasing the efficiency of the heart eventually becomes a liability (2) A reduction of physical performance of the patient due to joint involvement Available evidence suggests that the progression and outcome of rheumatic heart disease is influenced by the amount of rest and

exercise during its course (3) More gradual development of the rheumatic process This would allow for smoother adjustment of the heart to the changes in circulatory dynamics

The assumption of a milder form of cardiac disease is in keeping with the statement by Rosenberg *et al* (1944) that the cardiac lesion associated with rheumatoid arthritis is not as severe or widespread as such a lesion in young persons who have rheumatic fever, and also with the fact that in the present series of patients with rheumatoid arthritis, radiologically evident cardiac enlargement, although frequently present, was in most cases not excessive

There are two possible contributory causes of the absence of abnormal sound phenomena (1) A milder myocardial process Triple rhythm due to rapid diastolic inflow is the only acoustic abnormality in heart disease of the rheumatic carditis type, the absence of which may be explained on this basis, since it usually accompanies advanced disease (Weber, 1937, Evans, 1943) (2) Physical properties of the blood The incidence and intensity of other murmurs here being considered is not dependent on the extent of cardiac involvement If as we are informed by those who investigated such hearts anatomically valvular and muscular changes are identical in the two conditions, the question arises, whether the physical state of the blood accounts for some of the differences Estimation of blood velocity and the B M R in ten patients in this series gave normal results, nor did significant murmurs appear when blood velocity was increased by exertion Information regarding the kinematic viscosity of full blood in rheumatoid arthritis is so far not available and is being studied at present by Sagar and Fischmann (1947)

Left ventricular enlargement was found in this series, instead of the characteristic cardiac silhouette of rheumatic valvular disease In chronic rheumatic carditis the distribution of dilatation and hypertrophy of the cardiac chambers is determined by the combined effect of the inflammatory lesion and the distribution of mechanical strain, the latter according to the localization of the pathological process in the valves In rheumatoid arthritis, on the other hand, with the lessening of physical exertion the importance of the mechanical factor will diminish and the distribution of enlargement will follow chiefly, or alone the distribution of the inflammatory process In rheumatic carditis Gross and Erhlich (1930) found that Aschoff bodies were almost invariably present in the interventricular septum and the posterior wall of the left ventricle, while other parts of the heart were less frequently invaded Also the enlargement of the heart found in patients dying in the early stages of rheumatic carditis is largely limited to the left ventricle (Boyd, 1931)

Summary

The 60 rheumatoid arthritis patients in this series were selected to have normal blood pressure, no history of rheumatic fever, and no chest deformity, and to be able to stand upright for cardiac radiography

Clinical and electrocardiographic findings were negative apart from a tendency to low voltage of the standard leads

Radiological examination suggested the presence of cardiac enlargement in 23 per cent of patients Enlargement was left ventricular in 50 per cent of these, left ventricular and left auricular in 21 per cent, generalized in 29 per cent, and right sided in none of the hearts judged enlarged The gullet was displaced backward at the level of the left auricle in 29 per cent of enlarged hearts

It is thought probable that radiologically manifest cardiac enlargement in rheumatoid arthritis is an expression either of chronic rheumatic carditis or a form of cardiac involvement due to the ætiological factor of rheumatoid arthritis

An attempt is made to explain the prevalence of the left ventricle in cardiac enlargement and also the absence of clinical and electrocardiographic manifestations of heart disease in the presence of radiologically demonstrated enlargement

The authors are deeply indebted to Dr F H Smirk, Professor of Medicine, Otago University, for his detailed critical analysis of this paper, to Dr W E Griesbach of the Thyroid Research Department, Otago University, for helpful suggestions, and to Dr E P Neale, Secretary of the Auckland Chamber of Commerce, for checking the tables Thanks are due to the Superintendent of the Auckland Public Hospital, for the loan of some X-ray films, and to Mr A Fischman and Misses K Harper and P Newdick, for technical assistance

REFERENCES

Baggenstoss, A H, and Rosenberg, E F (1941*a*) *Proc Staff Meet Mayo Clin*, 16, 232
——, —— (1941*b*) *Arch intern Med*, 67, 241
Bayles, T B (1943) *Amer J med Sci*, 205, 42.
—— and McGinn, S (1943) Unpublished observations cited by Bayles
Bennett, G A, Zeller, J W, and Bauer, W (1940) *Arch Path*, 30, 70
Boyd, W (1931) *The Pathology of Internal Diseases* London
Bramwell, C (1933) *Brit med J*, 2, 597
Chamberlain, E. N, and Hay, J D (1939) *Brit Heart J*, 1, 105
Charcot, J M (1881) *Clinical Lectures on Senile and Chronic Diseases* New Sydenham Soc, London
Clawson, B J (1939) *Amer Heart J*, 17, 387

Coburn, A F, and Pauli, R H (1932) *J exp Med*, **56**, 609
Colver, I (1937) *Arch Dis Childh*, **12**, 253
Comeau, W J, and White, P D (1942) *Amer J Roentgen*, **47**, 665.
Committee of International League against Rheumatism (1934) Cited by Fox, R F, and Van Bremen, J 1934) *Chronic Rheumatism*, London
Committee of the American Rheumatism Association (1942) *J Amer med Ass*, **119**, 1089
Coombes, C, and Coates, V (1926) *Arch Dis Childh*, **1**, 183
Curtis, A C, and Pollard, H M (1940) *Ann intern Med*, **13**, 2265
Dawson, M H (1933) *J exp Med*, **57**, 845
——, Olmstead, J, and Jost, E (1934) *J Immunol*, **27**, 355
De Liee, E M, Dodge, K G, and McEwen, C (1943) *Amer Heart J*, **26**, 681
Elman, P (1944) *Lancet*, **2**, 581
Evans, W (1943) *Brit Heart J*, **5**, 205
Freund, H A, Steiner, G, Leichtentritt, B, and Price, A E (1942) *Amer J Path*, **18**, 865
Gross, L, and Ehrlich, C (1930) *Ibid*, **6**, 621
Gross, H, and Spark, C (1937) *Amer Heart J*, **14**, 161
Grzimek, N, (1932) *Virchows Arch*, **286**, 286
Gwynne, F J, (1933) *Med J Aust*, **1**, 207
Hench, P S (1941) Cited by Baggenstoss and Rosenberg (1941*b*)
——, and Rosenberg, E F (1941) Discussion of paper by Baggenstoss and Rosenberg (1941*a*)
Hoskin, J, and Jonescu, P (1940) *Brit Heart J*, **2**, 33
Jones, W E, (1930) *Quart J Med*, **24**, 204
Kast, L (1901) *Prag Med Wchnschr*, **26**, 493, 508, 521
Klinge, F (1933) *Ergebn allg Path path Anat*, **27**, 1
Larsen, K, and Skulason, T (1941) *Amer Heart J*, **22**, 625
Leach, C E, Reid, W C, White, P D (1941) *Ibid*, **2**, 551
Levitt, G (1939) *Amer Heart J*, **18**, 693
Lewis, T, and Gilder, M D D (1912) *Philos Trans*, **202**, B 351
Logue, R. B, and Hanson, J F (1944) *Amer J med Sci*, **207**, 765
Master, A M, and Jaffee, H (1932) *J Amer med Ass*, **98**, 881
Maun, M E (1941) *J Lab clin Med*, **26**, 1239
McFarland, R A, Graybiel, A, Liljencrantz, E, and Tuttle, A D (1939) *J Aviation Med*, **10**, 160
Palmer, J H (1937) Cited by Leach, Reid, and White (1941)
Parkinson, J (1933) Special Report Series 222, Med Research Council
Poynton, F J, and Schlesinger, B (1937) *Brit med J*, **2**, 591
Rogen, A S (1947) *Advances in the Study of Rheumatism*, London
Rosenberg, E F, Baggenstoss, A H, and Hench, P S (1944) *Brit med J*, **1**, 87
Sagar, F H, and Fischmann, E. J (1947) *Ann intern Med*, **20**, 903
Sangster, C B (1940) To be published
Shipley, R A, and Hallaran, W R (1936) *Med J Austral*, **1**, 461
Speckman, R N, and Rich, M L (1931) *Amer Heart J*, **11**, 325
Steiner, G, Freund, H A, Leichtentritt, B, and Maun, E (1946) *J Lab clin Med*, **17**, 165
Steuer, L G, (1934) *Amer J Path*, **22**, 103
Szekely, P (1940) *Amer Heart J*, **9**, 642
Todd, E Q (1932) *Brit Heart J*, **2**, 1
Turner, K B (1932) *Brit J exp Path*, **13**, 248
Ungerleider, H E, and Clark, C P (1939) *Arch intern Med*, **50**, 380
Viscidi, P C, and Geiger, A J (1943) *Amer Heart J*, **17**, 92
Weber, A (1937) *Ibid*, **26**, 763
Wilson, F N, and Nyboer, J (1937) in Stroud, D W (1940) *Die Elektrokardiographie*, Berlin
Young, D, and Schwedel, J B (1944) *The Diagnosis and Treatment of Cardiovascular Disease*, Philadelphia
Amer Heart J, **28**, 1

ABSTRACTS OF CARDIOLOGY

Physiological Studies in Congenital Heart Disease I Procedures R J BING, L D VANDAM, and F D GRAY *Bull Johns Hopk Hosp*, 80, 107–120, Feb, 1947

The technical aspects of physiological studies of cases of congenital heart disease are described The procedures and formulæ mentioned are those dealing with the measurement of blood flow in the pulmonary artery, systemic circulation, pulmonary capillary bed, and intracardiac shunts In all, 14 formulæ are presented, including one for measuring the peripheral resistance The techniques used involve the evaluation of oxygen and carbon dioxide in arterial and venous blood and also in blood collected by intracardiac catheterization, together with determination of the rates of oxygen consumption and carbon dioxide elimination by indirect calorimetry

[This paper cannot easily be abstracted, and those interested in the subject are advised to consult the original communication] *A I Suchecki*

Physiological Studies in Congenital Heart Disease II Results of Preoperative Studies in Patients with Tetralogy of Fallot R J BING, L D VANDAM, and F D GRAY *Bull Johns Hopk Hosp*, 80, 121–141, Feb, 1947

This paper deals with results of pre-operative studies on patients with cardiac abnormalities and in whom a reduced pulmonary blood flow is an important feature Altogether 120 patients with the tetralogy of Fallot have been investigated. Here there is an intracardiac shunt from right to left However, there may be some concomitant flow from left to right, as indicated by a higher oxygen content of right ventricular blood as compared with that of the right auricle In some cases both systemic and pulmonary artery flows are equally reduced below normal values the intracardiac shunt is negligible and the aorta rises chiefly from the left ventricle With varying degrees of pulmonary stenosis and ventricular septal defect, the systemic blood flow depends to a large extent on the importance of the intracardiac shunt The total pulmonary flow (pulmonary capillary flow) approaches closely the volume of pulmonary artery flow normally and rarely in the tetralogy of Fallot, indicating in the latter absence of measurable collateral circulation In the majority of patients with pulmonary stenosis, however, pulmonary capillary flow exceeds pulmonary artery flow, suggesting the presence of an important collateral circulation to the lungs In 4 patients with pulmonary stenosis and patent ductus arteriosus the volume of blood flow through the ductus could be determined by measuring the difference between the pulmonary capillary and pulmonary artery flows

It has been shown directly, by intracardiac catheterization, that the systolic pressure in the right ventricle in cases of the tetralogy is above normal and approximates to the systolic pressure in the systemic circulation. In 8 out of 22 recordings the general level of the ventricular diastolic pressure was also elevated When the catheter is passed into the stenosed pulmonary artery the pressure falls sharply In 3 subjects the systolic pressures in the right ventricle and in the aorta were similar

In the tetralogy of Fallot the oxygen consumption is decreased and this, the authors suggest, is the result of physiological adaptation to chronic anoxia The decreased metabolic rate may also be due to a poor nutritional status, lack of physical activity, or poor calorie intake The ratios of oxygen consumed and carbon dioxide produced decreased during the standard exercise test, while the arterial oxygen saturation dropped immediately after the exercise This exercise test might be of diagnostic help Finally, the authors stress the interrelationship of venous-arterial shunts and decreased pulmonary blood flow in the production of anoxæmia The volume of " effective pulmonary blood flow " is the determining factor *A I Suchecki*

Physiological Studies in Congenital Heart Disease III. Results Obtained in Five Cases of Eisenmenger's Complex R J BING, L D VANDAM, and F D GRAY *Bull Johns Hopk Hosp.*, 80, 323–347, June, 1947

Physiological methods have been used to study the circulation in the heart and great vessels in 5 cases of Eisenmenger's complex Clinically these cases can be distinguished from those of Fallot's tetralogy because the cyanosis and clubbed fingers develop later in life, though breathlessness on exertion is present from childhood The patient also suffers many hæmoptyses, and a loud systolic murmur is audible over the base of the heart close to the left of the sternum Radioscopy shows a prominent pulmonary conus, marked vascular root shadows, and expansile pulsations in the lung fields Such cases are not at present amenable to surgical treatment

In 4 or 5 such cases exercise was accompanied by a rise in the ratio of oxygen consumed per litre of ventilation, whereas in patients with the tetralogy of Fallot the ratio usually declines The preponderant shunt of blood was from the left to the right ventricle in 3 cases and from right to left in 2, though in all there was interventricular mixing of blood The authors believe that there is an increased resistance in the pulmonary bed in these cases, because there was no marked tendency for the blood to flow from left to right and because the pulmonary arterial pressure was increased The calculated work of the

right ventricle was 30 to 50% of that of the whole heart, whereas it is usually 15% and the ratio velocity energy/total work, when calculated for the right ventricle, was only one-tenth of the normal It is pointed out that in some cases of septal defects in infants generalized narrowing of the pulmonary arterioles due to thickening of the media and intima has been found, and similar changes have been described in 2 cases of large interauricular septal defect These post-mortem findings appear to tally with the ante-mortem finding of increased pulmonary vascular resistance *H E Holling*

Studies of Congenital Heart Disease I Technique of Venous Catheterization as a Diagnostic Procedure L DEXTER, F W HAYNES, C S BURWELL, E C EPPINGER, R E SEIBEL, and J M EVANS *J clin Invest*, 26, 547–553, May, 1947

This paper, the first of a series of three, deals with the application of intracardiac catheterization to the study and diagnosis of congenital heart disease The method described by the investigators is that introduced by Cournand and his associates for the study of hæmodynamics Several samples of blood from the right cardiac chambers and pulmonary artery and vena cava are collected and examined for oxygen content, in addition, blood from the femoral artery and oxygen consumption are studied The data obtained can be utilized for the calculation of blood flow in patients with congenital heart disease (Fick's formula) The volume of flow through single one-directional shunts may most easily be estimated by calculating the difference between the pulmonary and peripheral flows The estimation becomes more difficult when double shunts, shunts in both directions, and collateral circulation are present The authors give details of estimation of the blood pressure in the pulmonary artery, right ventricle, and right auricle A continuous pressure curve can be recorded during the withdrawal of the catheter from the pulmonary artery through the right cardiac chambers The method of intracardiac catheterization, as already shown by others, carries no danger In a few patients ventricular extrasystoles and auricular fibrillation have been noted, but these, as well as a venous spasm occasionally seen, are transient Of 42 patients, only 1 presented symptoms troublesome enough to require interruption of the procedure *A I Sucheckı*

Studies of Congenital Heart Disease II The Pressure and Oxygen Content of Blood in the Right Auricle, Right Ventricle, and Pulmonary Artery in Control Patients, with Observations on the Oxygen Saturation and Source of Pulmonary "Capillary" Blood L DEXTER, F W HAYNES, C S BURWELL, E C EPPINGER, R P SAGERSON, and J M EVANS *J clin Invest*, 26, 554–560, May, 1947

This communication deals solely with results of intracardiac catheterization performed in control patients known to have no congenital cardiac defect The blood pressures in each chamber have been recorded, and there seems to be little difference between pulmonary artery and right ventricle pressures this normal finding contrasts with that in pulmonary stenosis, where the systolic ventricular pressure is clearly higher than that in the pulmonary artery In some congenital heart conditions, left to right shunt introduces arterial blood into the right chambers, thereby increasing the oxygen content of blood in the latter What, then, are the normal variations in oxygen content in the right heart? The results in the controls show that the greatest increase in oxygen from the superior vena cava to the right auricle is 1 9 vol %, from the right auricle to the right ventricle, 0 9 vol %, and from the right ventricle to the pulmonary artery, 0 5 vol % Within each chamber variation of oxygen content occurs, it is minimal in the pulmonary artery It is suggested by the authors that blood from the pulmonary artery be employed for the determination of oxygen content in mixed venous blood for use in Fick's formula Lastly, by comparing the oxygen values of a sample of blood obtained through the catheter obstructing a small branch of the pulmonary artery with that from the femoral artery, the investigators have shown that the former blood originates in the pulmonary capillary and venous bed rather than in pre-capillary anastomoses with systemic arteries *A I Sucheckı*

Studies of Congenital Heart Disease III Venous Catheterization as a Diagnostic Aid in Patent Ductus Arteriosis, Tetralogy of Fallot, Ventricular Septal Defect, and Auricular Septal Defect L DEXTER, F W HAYNES, C S BURWELL, E C EPPINGER, M C SOSMAN, and J M EVANS *J clin Invest*, 26, 561–567, May, 1947

The authors describe intracardiac catheterization as a diagnostic aid in 7 patients with four varieties of congenital heart disease (1) Patent ductus arteriosus the oxygen content of the blood in the pulmonary artery was, in 1 patient, 2 2 vol % higher than that from the right ventricle This is taken as direct evidence of entry of arterial blood into the pulmonary artery, a less constant finding is an elevation of blood pressure in the pulmonary artery and the right ventricle (2) Tetralogy of Fallot pulmonary stenosis was recognized by finding a higher systolic pressure in the right ventricle than in the pulmonary artery, and a narrow pulse pressure in the latter In another case the intracardiac catheter passed from the right ventricle to the aorta, thus demonstrating a ventricular septal defect (3) Interventricular septal defect (Roger's disease) in 1 case the blood in the right ventricle was found to be more highly oxygenated than that in the right auricle (4) Interauricular septal defect cases may be diagnosed by introducing the catheter into the left auricle through the septal defect, or by finding a significant increase in the oxygen content of blood in the right auricle (left to right shunt) In 1 such case a large increase of oxygenation of blood in the right auricle was found as compared with that of the superior vena cava (more than 1 9 vol %), the value was practically identical with that found in the femoral artery Similar findings to those in group 4 can be seen in tricuspid insufficiency associated with interventricular septal defect, and in the rare cases where a pulmonary vein empties into the right auricle *A I Sucheckı*

Venous Catheterization of the Heart I Indications, Technics, and Errors M C SOSMAN *Radiology*, 48, 441–450, May, 1947

Catheterization of the right heart is most useful in the study of hæmodynamics and in helping to establish an accurate diagnosis in congenital heart disease In addition, the method has been used in the study of cerebral, renal, and hepatic physiology, in order to collect samples of blood directly from the jugular, renal, and hepatic veins

From the median basilic vein in either antecubital fossa the catheter, made of woven silk, is passed upward into the axillary vein, the superior vena cava, and the right auricle From there it may be guided into the right ventricle or, as the patient takes a deep breath, into the inferior vena cava, thence into either renal vein or into one of the hepatic veins The direction of the tip of the catheter is controlled under intermittent fluoroscopic vision by twisting its proximal end The tip moves with each cardiac pulsation, slightly in the auricle but much more so when the right ventricle is entered From the right ventricle the catheter may be guided into either right or left pulmonary artery Clotting of blood in the catheter is prevented by continuous perfusion of normal saline

All patients have a test of basal metabolism before catheterization to determine their oxygen consumption Arterial blood is withdrawn under oil by puncture of the femoral artery, for determination of arterial oxygen saturation In patients with congenital heart disease, samples of blood are withdrawn from the pulmonary artery, right ventricle, right auricle, and superior vena cava, and films are taken of the catheter tip in each position Peripheral blood flow is calculated by the direct Fick principle of dividing the oxygen consumption by the arteriovenous oxygen difference between the femoral artery and the right heart Pulmonary flow may be estimated by dividing the oxygen consumption by the difference in oxygen content of the pulmonary artery and the femoral artery The value of teamwork is stressed

Examination was unsatisfactory in 13 out of 100 patients tested, causes for failure included unsatisfactory veins, spasm of vein around the catheter, kinking of an unsatisfactory catheter, and unco-operative patients General anæsthesia is indicated only in young children Extrasystoles were sometimes noted as the tip of the catheter passed through the tricuspid valve In only two instances were subjective symptoms distressing enough to cause abandonment of the procedure No evidence of thrombus formation or of damage to the endothelium of the large veins or heart has been found Cournand has reported 1200 such examinations without fatality or serious complications from passage of the catheter

Several radiographs, illustrating "normal" and abnormal or accidental positions of the catheter tip, add to the interest of this paper Thus the tip is seen in an azygos vein, in an additional left-sided superior vena cava, in a coronary venous sinus, in a right-arched aorta, and (through an auricular septal defect) in a pulmonary vein *T Semple*

Venous Catheterization of the Heart II Results, Interpretations, and Value L DEXTER *Radiology*, 48, 451–462, May, 1947

This paper discusses diagnostic aid obtainable in congenital heart disease by previous abstract In auricular septal defect the catheter may be introduced through the defect or arterial blood may be found in the right auricle The recognition of an uncomplicated interventricular septal defect depends on finding a significantly higher oxygen content of blood in the right ventricle than in the right auricle In the tetralogy of Fallot the venous catheter may pass through the stenosed pulmonary valve into the pulmonary artery, where the pressure would be lower than that of the right ventricle, or it may pass through the septal defect and go directly into the overriding aorta In patent ductus arteriosus, blood from the pulmonary artery has a higher oxygen content than that from the right ventricle

With the aid of line drawings and serial radiographs the passage of the catheter is demonstrated from the superior vena cava to various positions in the representative types of cogenitally abnormal heart *T Semple*

Experimental Serum Carditis and its Relationship to Rheumatic Fever E F MCKEOWN *J Path Bact*, 59, 547–555, Oct, 1947

It has been reported by other workers that cellular infiltrations in the heart like those of rheumatic carditis have been found in 2 fatal cases of serum sickness, and that polyarteritis, like the occasional polyarteritis nodosa which may complicate rheumatic fever, may be a result of sensitization Cardiac lesions, which show many of the histological characters of the rheumatic lesion, may also be found in the experimentally sensitized animals The work here reported is an attempt to verify these experimental observations

Rabbits were given 10 ml of horse serum per kg body weight intravenously or intraperitoneally 17 days later 1 ml of serum was injected intravenously to absorb circulating antibody 2 days later the initial dose of serum was repeated, 1 week later, and in some instances after longer intervals, the animals were killed The vascular lesions described could be found after a single injection of serum, but were more widespread in animals receiving a second dose They were present in 88% of the animals, the coronary arteries were most often affected The histological appearances of an inflammatory exudate surrounding and infiltrating the vessel are fully described

Small granulomata closely resembling the Aschoff nodule of rheumatic fever were often found in the myocardium Inflammatory nodules were also found in the endocardium, leading to fibrotic thickening Similar lesions were found in the mitral valve and valve ring, less frequently in the aortic and tricuspid valves, and never in the pulmonary valve The author believes that in histological structure and in site these experimental lesions are identical with those of rheumatic fever, and concludes that hypersensitivity is probably the essential mechanism in the production of the rheumatic lesion *Kenneth Stone*

New Test for Hypertension due to Circulating Epinephrine M GOLDENBERG, C H SNYDER, and H ARANOW *J Amer med Ass*, **135**, 971–976, Dec 13, 1947

The only clinically significant type of hypertension due to circulating adrenaline results from phæochromocytoma It is suggested that this tumour may be much more common than is generally realized The diagnosis is dependent on (1) the typical syndrome of paroxysmal hypertension with signs of vasoconstriction, pallor, headache, vomiting, and tachycardia, hypertension may sometimes be persistent, (2) demonstration of the tumour by perirenal insufflation of air, this may not succeed as there are other sites in which chromaffin tissue may occur, (3) demonstration of circulating adrenaline in the blood, but this may be very difficult The principle of the new procedure described is that hypertension due to circulating adrenaline will be abolished by the injection of adrenolytic compounds, hypertension due to any other cause will persist Benzodioxanes in tolerable doses are adrenolytic only, and not sympathicolytic Piperidyl methyl benzodioxane was used in a dose of 0 25 mg per kilo intravenously In cases of phæochromocytoma the injection of benzodioxane was followed by a fall in blood pressure which lasted for several minutes in 3 out of 4 cases In the fourth the pressure fall was slighter The diagnosis was confirmed at operation in all these cases In patients with essential hypertension the blood pressure usually rose after benzodioxane, but rarely a slight and less significant fall of pressure took place Benzodioxane produced some side-effects, such as tachycardia, flushing, palpitation, coldness of limbs, and dizziness Fourteen patients found it unpleasant, while 44 were undisturbed by the test *J McMichael*

Studies on Plant Hypertensinase F GOLLAN, E RICHARDSON, and H GOLDBLATT *J exp Med*, **87**, 29–39, Jan 1, 1948

The extraction of hypertensinase from wheat bran is described A preparation free from renin and with low toxicity was produced This was found to cause a rise in plasma hypertensinase when injected intravenously into dogs but not when injected intramuscularly The reaction of these animals to injections of hypertensin or renin was less marked. In dogs with experimental hypertension the blood pressure was reduced by intravenous hypertensinase, while the plasma hypertensinase level remained high, though hypertensin could be detected in the plasma These effects were not produced by inactivated hypertensinase *Majorie Le Vay*

Spinal Nerve Root Pain (Radiculitis) Simulating Coronary Occlusion A Common Syndrome D DAVIS *Amer Heart J*, **35**, 70–80, Jan, 1948

More careful investigation of some cases diagnosed as coronary thrombosis reveals that they are really cases of spinal nerve root pain The author describes 10 such patients who were under his care during 1946 The patients had described præcordial pain coming on in attacks and radiating either to the left arm or to the jaw, but a more careful probing of the history revealed that the pains might come on in bed, after there had been certain movements of the spine, or after such acts as coughing, sneezing, or straining at stool Pressure over the dorsal vertebræ might provoke an attack, and tenderness in the region of the costo-chondral junctions might be elicited The diagnosis can be confirmed by the beneficial response to postural correction and manipulation of the cervico-dorsal spine Cervico-dorsal radiculitis may also coexist with coronary disease Recognition of the syndrome and differentiation from coronary disease may prevent much unnecessary invalidism *H E Holling*

Vitamin E in Angina Pectoris D H MAKINSON, S OLEESKY, and R V STONE *Lancet*, **1**, 102, Jan 17, 1948

Twenty-two patients with typical angina of effort were treated with vitamin E, phenobarbitone, aminophylline, and calcium lactate, each drug being given for 3 weeks, after which the patients were asked to compare the effects of the drugs From this small but clinically significant series it is concluded that vitamin E is not of any therapeutic value in the routine treatment of angina pectoris —[Authors' summary]

The Use of Dicumarol in Experimental Coronary Occlusion I The Ineffectiveness of Dicumarol when Ligation is the Method of Occlusion E J BEATTIE, E C CUTLER, M FAUTEUX, T D KINNEY, and H D LEVINE *Amer Heart J*, **35**, 94–105, Jan, 1948

The descending branch of the left coronary artery was crushed or ligated in 40 healthy dogs Ligation was found to be a more certain way of producing an infarct, and for various reasons only 22 of the ligation experiments were found to be suitable for inclusion in the study One group of these dogs was given adequate doses of dicoumarol after the ligation, a control group received no dicoumarol The electrocardiographic and pathological changes were studied in both groups and no significant differences were found Before applying these results to experience with human cases of coronary occlusion the limitations of the experiments must be borne in mind (*a*) The coronary arteries of these dogs were healthy and therefore less likely to be the seat of an extensive thrombosis than the coronary artery of patients (*b*) The experiments produced abrupt and total occlusion whereas in clinical coronary thrombosis the occlusion may be gradual (*c*) Hæmorrhage after the operation was the cause of death in 3 of the dogs receiving dicoumarol and this factor would not operate in clinical work (*d*) The number of satisfactory experiments is too small for statistical analysis *H E Holling*

Rupture of the Heart Following Acute Myocardial Infarction R S DIAZ-RIVERA and A J MILLER *Amer Heart J*, **35**, 126–133, Jan, 1948

Rupture of the heart occurred in 5 of 147 cases of myocardial infarction coming to necropsy, all 5 cases were from a group of 53 in which the infarction was acute Rupture of the interventricular septum had been recognized ante mortem by the anginal pain followed by

the sudden appearance of a systolic murmur and the electrocardiographic changes typical of myocardial infarction and right axis deviation In every instance of rupture of the left ventricle, clotting of the blood in the pericardium had occurred, and it was evidence that cardiac rupture resulting from acute myocardial infarction was not a cause of instantaneous death

H E Holling

Treatment of Angina Pectoris by Reduction of Basal Metabolism G SCHOENEWALD *Brit med J*, 1, 251-253, Feb 7, 1948

The author divides cases of angina pectoris into three groups—obese, anæmic, and slim Patients in the first two groups can be helped by weight reduction and by correction of anæmia respectively, those in the third group can be given nitroglycerin to shorten their attacks Commenting on total surgical removal of the thyroid gland, which has not been widely practised in Britain, the author describes 3 patients treated ambulantly with methylthiouracil All were given 600 mg daily for several weeks, with improvement in each case It is noted that in order to reduce thyroid activity it is necessary to give much larger doses for a longer period to patients with normal thyroid activity than to those with thyrotoxicosis

Geoffrey McComas

The Electrocardiographic Diagnosis of Right Ventricular Hypertrophy G B MYERS, H A KLEIN, and B E STOFER *Amer Heart J*, 35, 1-40, Jan, 1948

The electrocardiographic criteria for the diagnosis of right ventricular hypertrophy have been reconsidered A critical review of the literature is presented Forty cases of right ventricular hypertrophy proven at necropsy were carefully studied The authors find, as previous workers have shown, that right axis deviation in the standard leads, with depression of RST2 and RST3 and with inversion of T1 and T2, is not diagnostic of right ventricular hypertrophy This pattern may be found in left ventricular hypertrophy and even in normal subjects when the heart is in a vertical position [For the electrocardiographic features now considered typical of right ventricular hypertrophy the original paper must be consulted]

H E Holling

Effect of Increasing the Blood Volume and Right Atrial Pressure on the Circulation of Normal Subjects by Intravenous Infusions J V WARREN, E S BRANNON, H S WEENS, and E A STEAD *Amer J Med*, 4, 193-200, Feb, 1948

A series of normal young subjects were given intravenous infusions of normal saline or 5% human serum albumin in normal saline The amounts ranged from 750 to 1,825 ml and were given at rates ranging from 32 to 72 ml per minute The increase in blood volume consistently caused a rise in right auricular pressure, but cardiac output, arterial blood pressure, and pulse rate showed no consistent changes Variations in auricular pressure of about 125 mm water produced no demonstrable changes in the transverse diameter of the heart It is concluded that increasing the blood volume and auricular pressure throws no demonstrable burden on the circulation of normal subjects It is suggested (*a*) that this may also be true of patients with cardiac failure, (*b*) that in them acute pulmonary œdema is precipitated by intravenous infusions because certain factors operate to cause a large portion of the administered fluid to accumulate in lungs already moderately œdematous

R T Grant

Experiences in the Management of Subacute Bacterial Endocarditis Treated with Penicillin P A TUMULTY and A McG HARVEY *Amer J Med*, 4, 37-54, Jan, 1948

Of 35 patients suffering from subacute bacterial endocarditis who were treated with penicillin 22 recovered, of these 12 remained well over periods of 3 to 36 months, 7 had some, usually mild, cardiac symptoms, one suffered from increasing heart failure, one died of cardiac and renal failure 5 months after the conclusion of treatment, and another died, after 6 months, in a mental hospital, the cause of death in the last case could not be ascertained by the authors These patients had received penicillin treatment for 13 to 100 days, the amounts given daily varying between 200,000 and 18,000,000 units, with totals of 3,500,000 to 1,450,000,000 units Of the 13 patients who did not recover only 4 were regarded as having received adequate treatment with penicillin, the cause of death in most of them was cardiac failure and embolism Two died of myocardial infarction, which, in one case, was caused by a mycotic aneurysm of a coronary artery and in the other by coronary thrombosis

The authors stress the difficulty of clinical diagnosis in the frequent absence of the classical signs, and the importance of retaining and reviewing blood cultures for 3 weeks before discarding them as sterile The possibility of unusual causative organisms, such as the genus *Bacteroides*, is to be kept in mind The authors consider as a " basic and minimal treatment schedule " 100,000 units of penicillin 2-hourly for 8 weeks, and assess satisfactory response mainly on clinical criteria, such as return of temperature and pulse rate to normal, improved appetite, and general well-being If necessary, the dose of penicillin must be increased until satisfactory response is obtained As a prophylactic measure against the development of subacute bacterial endocarditis in patients who suffer from valvular or congenital heart disease, the administration is recommended of at least 500,000 units of penicillin a day for 4 days in the case of dental extractions or other surgical procedures and manipulations which are likely to produce a transient bacteriæmia

B Samet

Effect of Tetraethyl Ammonium Chloride on a Mixed Type of Hypersensitive Carotid Sinus Syndrome. R D TAYLOR, L C UNDERWOOD, and I H PAGE *J Lab clin Med*, 32, 1491-1495, Dec, 1947

The effect of the intravenous injection of atropine and of tetraethyl ammonium chloride was observed in a patient in whom pressure on the carotid sinus provoked bradycardia, fall in blood pressure, giddiness, and

syncope Atropine prevented the slowing of the pulse rate but not the fall in blood pressure Tetraethyl ammonium chloride prevented both the bradycardia and hypotension The inhibition of the vegetative system by tetraethyl persisted for only 30 to 40 minutes, and the drug is therefore not recommended for treatment of this type of case *R T Grant*

Hypertensive Vascular Disease Duration of Life in a Selected Series D W Blood and G A Perera *Amer J Med*, 4, 83–88, Jan, 1948

In order to assess the prognosis in cases of "benign," hypertension 50 patients were studied who, when first seen, had not significant symptoms but consistently had blood pressures of over 140/90 mm Hg Their ages varied from 22 to 57, the average being 42, and 41 were females and 9 males The average length of observation was 17 years and varied from 10 to 27 years Sixteen patients died, the majority as a result of cardiovascular complications or cerebral vascular accidents, 24 were free from significant symptoms when last seen It was not possible to correlate prognosis with initial height of blood pressure, symptoms of headache or palpitation, the presence of cardiac enlargement, albuminuria, minor electrocardiographic changes, or retinal arterio-venous compression Symptoms of cardiac failure appeared late in the course of the disease, 8 of the 22 patients developing such symptoms died after an average of 8 years from the first symptom On the other hand, only one of the 9 patients developing cardiac pain survived, the average duration of life from the onset of pain being 5 years *C Bruce Perry*

Severe Hypertension in Young Persons A Study of 50 Cases R Platt *Quart J Med*, 27, 83–93, Jan, 1948

As a result of investigation into the cause of 64 cases (14 more are contained in an addendum) of severe hypertension in patients under the age of 40, the author concludes that the impression that one of the outstanding features of malignant hypertension is its frequent occurrence in young adults and even in children, is erroneous Although he did not personally select his cases, he is careful to point out that as his interest in this subject is known by practitioners he has been sent a disproportionate number of rarities He emphasizes the great difficulty of distinguishing essential hypertension from hypertension due to demonstrable causes, and states that at times the diagnosis cannot be made with certainty even microscopically For example, it may be impossible to distinguish atrophic pyelonephritis with hypertension from essential hypertension with pyelonephritis A cause of the hypertension was discovered in 48 of the 64 cases Of the remaining 16 cases of essential hypertension only 5 were malignant Essential malignant hypertension was not encountered in patients under the age of 34, young persons with the malignant type of hypertension are nearly always suffering from secondary hypertension, especially that due to pyelonephritis It was thought probable that benign and malignant hypertension begin at about the same age, the ages at which they were encountered clinically in this series was 45 2 years for malignant hypertension and 53 2 years for benign hypertension *S Oram*

The Relationship of Chronic Alcoholism to Atherosclerosis S L Wilens *J Amer med Ass*, 135, 1136–1139, Dec 27, 1947

This is a study of necropsy findings in 519 persons aged 35 or older, with chronic excessive alcoholism at Bellevue Hospital, New York, during the past 12 years In approximately one-half of these addicts the daily consumption was known to have exceeded 1 pint (568 ml) of whisky or its equivalent for many years In all the others consumption was known to have been excessive for long periods of time The incidence of atherosclerosis is compared with that in a control group of 600 consecutive necropsies of total abstainers and moderate consumers of alcohol, aged 35 or older In the alcoholic group atherosclerosis was less common and less severe than in the control group, as also were lesions of the coronary and cerebral arteries An explanation may be found in the fact that although three-fourths of the control group were 55 years or older at death, only one-half of the alcoholic men and one-fourth of the women survived beyond the age of 55 Of the alcoholics 28% had cirrhosis, but this did not increase the incidence of atherosclerosis In age groups the incidence of atherosclerosis in the 423 alcoholic and 434 non-alcoholic men was almost identical The author considers that the differences in incidence of atherosclerosis in the two groups depend not on alcoholism itself but on associated differences in age, blood pressure, and nutrition Hypertension, diabetes, and obesity were all less common in the alcoholics His conclusion is that substitution of alcohol for ordinary foods in the diet has no appreciable effect on the development of atherosclerosis *Donald Hall*

PATHOGENESIS OF LEFT BUNDLE BRANCH BLOCK

BY

HAKON RASMUSSEN AND TORJUS MOE

From the Rikshospital, Med Dept B, Professor H A Salvesen, and from Ulleval Hospital, Dept VIII, Chief Physician Carl Muller, Oslo, Norway

Received February 21 1947

In 1909 Eppinger and Rothberger showed that characteristic changes in the electrocardiogram arose after section of the right and left branches of the bundle of His in dogs, and the following year these experimental results were applied to human pathology, so that bundle branch block became a clinical concept Since that time the electrocardiogram originally designated right branch block has come to be regarded as indicative of a left-sided lesion, and vice versa, and this new conception must be considered as well-founded (Rasmussen, 1942) Apart from this correction, current opinion holds as in 1910, that the bundle branch block cardiogram is an indication of local damage to the right or left branch of the bundle of His However, in the last ten years especially, the great similarity between the so-called *electrocardiogram of left ventricular hypertrophy* and that of left bundle branch block has often been emphasized, and it has been suggested that the latter, like the former, may be due to great enlargement of the left ventricle, without any local lesion of the branch being present

In an investigation of the electrocardiogram in essential hypertension, Rasmussen and Thingstad (1939) concluded that great enlargement of the left ventricle was the common cause of the left bundle branch block cardiogram In cases of hypertension with gross cardiac enlargement they found the left bundle branch block cardiogram as a sequence of the *left ventricular hypertrophy curve* This view has been confirmed by further investigations In a series of 100 patients with aortic insufficiency, a similar concordance between the type of cardiogram and cardiac enlargement was found as in hypertension (Rasmussen, 1944) By producing dilatation of the right and of the left heart in experiments on dogs it was possible to produce typical bundle branch block electrocardiograms (Rasmussen, 1942) On re-examination of a group of hypertensive patients, it was found that the cardiogram of left ventricular hypertrophy and of left bundle branch block developed gradually, *pari passu* with increase in the size of the heart (Rasmussen and Bøe, 1945) It was also shown that as the cardiogram changed from a normal pattern to that of left hypertrophy, the duration of QRS increased so that the curve reached the left bundle branch block type, which is characterized by a QRS of at least 0 12 sec

Master and his associates (1940) investigated 100 patients with either left or right bundle branch block, and some with complete A-V block, and concluded that " chronic bundle branch block, in most instances, is the result of an increase in the size of the heart and of myocardial damage, with diffuse involvement of the bundle branch system " If enlargement of the left heart, by retarding the impulse to that side, can produce in the electrocardiogram a left ventricular hypertrophy curve or a left bundle branch block, is it hypertrophy or dilatation that is the essential factor? Further, it may be asked whether retardation of the impulse is due simply and solely to lengthening of its path, or to damage to the subendocardial network resulting from increased strain or distension? While for the present we may leave the latter question unanswered, we think there are grounds for believing that dilatation of one half of the heart is a decisive factor This view is based partly upon the above-mentioned experiments relating to dilatation of the right or left heart, partly upon the well-known phenomenon that a pulmonary embolism not infrequently produces a right bundle branch block curve, presumably due to dilatation of the right heart, and also partly upon clinical observations

We may illustrate this point of view by a few examples Fig 1 shows radiograms of the heart of a patient with hypertension, taken before and after sympathectomy, with an interval of about two

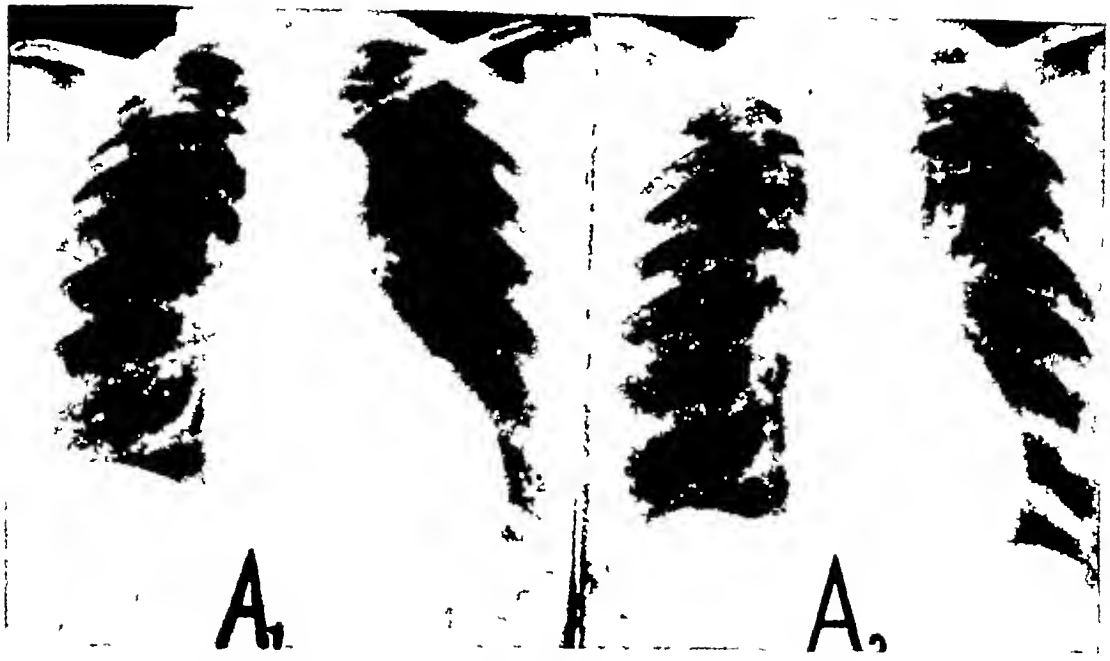

FIG 1 —Telecardiograms from case of hypertension (A1) before, and (A2), two months later, after sympathectomy

months between the photographs After operation the size of the heart is seen to have decreased considerably The blood pressure before operation was 240/130, afterwards 120/75 mm Fig 2 shows the cardiograms from this case, before and after operation Coincident with a decrease in the size of the heart the typical left ventricular hypertrophy curve has changed to a normal pattern It seems probable that we are here concerned with dilatation which has subsided and not with hypertrophy Fig 3 and 4 show cardiograms and radiograms taken at an interval of 7 months from a woman

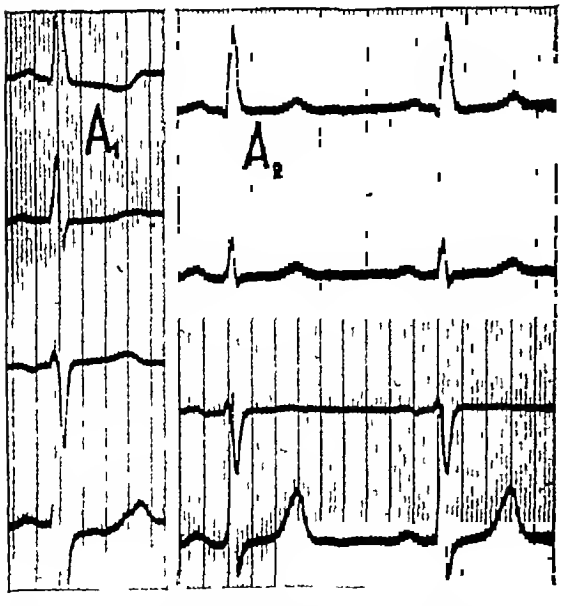

FIG 2 —Electrocardiograms from same case as Fig 1 (A1) before sympathectomy shows "left ventricular hypertrophy curve" (A2), two months later, after sympathectomy, showing return to normal curve

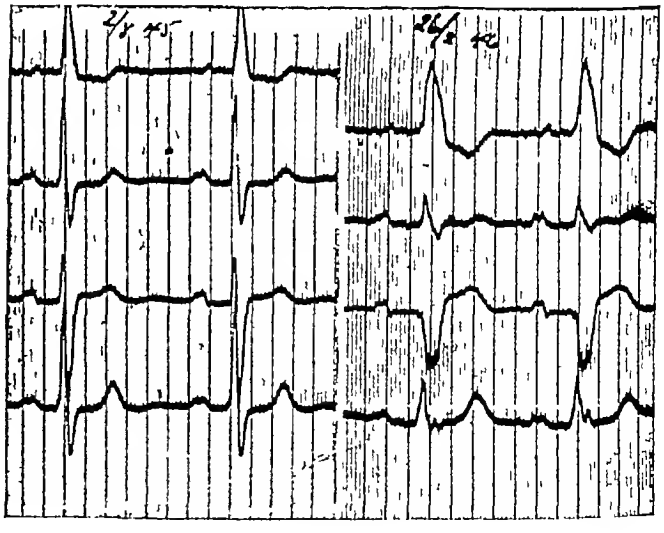

A B

FIG 3 —Electrocardiograms from case of aortic stenosis (A) showing "left ventricular hypertrophy curve", (B) 6 months later, showing a left bundle branch block curve

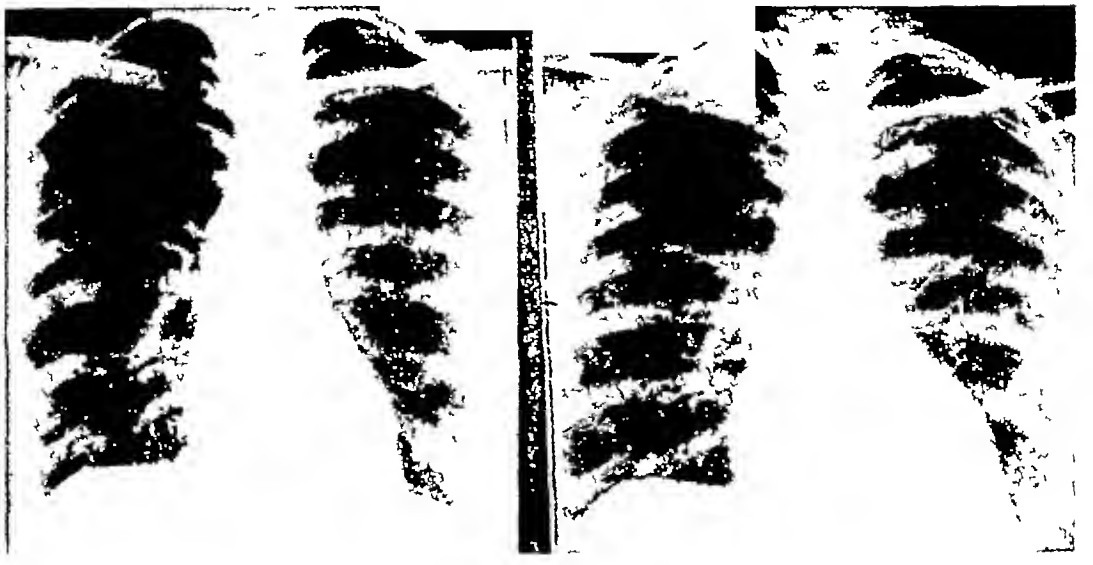

A B

FIG 4 —Telecardiograms from same case as Fig 3, showing (A) normal sized heart, and (B) 6 months later, considerable enlargement to the left

aged 57 with aortic stenosis The cardiogram has changed from a left ventricular hypertrophy curve to a left bundle branch block curve, coincident with a considerable increase in size of the heart, seen in the radiograms In this case also, it seems reasonable to suppose that the enlargement occurring in the course of seven months is due to dilatation rather than to hypertrophy

We have investigated a series of 100 patients with permanent left bundle branch block cardiograms, assembled from the Rikshospital and from Ulleval Hospital From the clinical data, radiograms and autopsies in these cases we have attempted to determine how often left bundle branch block is associated with heart diseases causing enlargement of the left ventricle and, further, how often conditions occur that may be supposed to produce a local lesion of the branch

The types of left bundle branch block curves found in our cases are shown in Fig 5 The first type, with high voltage, and discordant and diphasic ventricular complexes, was found in 78 patients, the characteristic præcordial leads are also shown The second type, where Q or S is a prominent feature, was found in 5 patients The third type, with lower voltage, although higher than 0 5 mv , sometimes with diphasic sometimes with monophasic ventricular complexes, as in the figure, was seen in 17 patients We have omitted from the series cases of intermittent and transient bundle branch block, the Wolff-Parkinson-White type, and bundle branch block associated with complete A-V block The duration of QRS in our cases is given in Fig 6 We have taken 0 12 sec as the lower limit of QRS in bundle branch block, and the upper limit in our cases was 0 2 sec Fourteen patients had auricular fibrillation, two auricular flutter, and six incomplete and partial A-V block

TABLE I

AGE DISTRIBUTION IN 100 PATIENTS WITH LEFT B B BLOCK ELECTROCARDIOGRAM

Age	Men	Women	Total
years			
20–29	1	0	1
30–39	0	1	1
40–49	2	1	3
50–59	6	9	15
60–69	23	14	37
70–79	17	15	32
80–89	4	5	9
90–99	1	1	2
Total	54	46	100

The age distribution of our cases is shown in Table I The youngest was 25, the oldest 91 years of age Seventy-seven patients had dyspnœa on exertion, 31 angina pectoris on exertion, 18 anginal attacks at rest, and 17 had congestive heart failure Nocturnal dyspnœa, sometimes with pulmonary œdema, was noted in 41 cases, indicating a very high frequency of left ventricular failure In 5 or 6 cases, cardiac symptoms were absent or slight, the

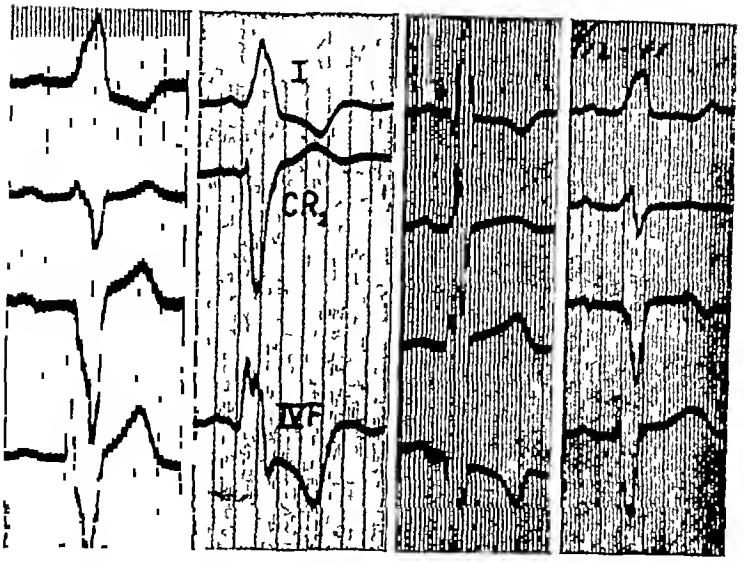

FIG 5 —Types of left bundle branch block curve encountered. (A) The most common type and (B) typical præcordial leads, (C) rarer type with Q wave, (D) rare type with positive T wave in lead I and without high voltage (Time marker 0 1 and 0 02 second)

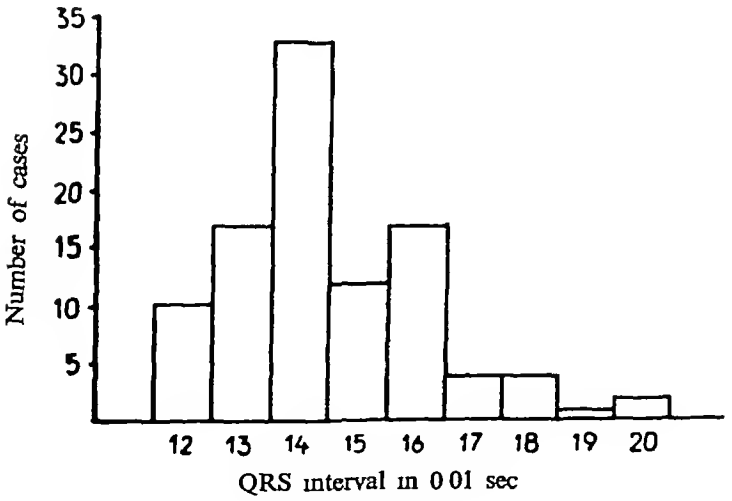

FIG 6 —Distribution curve of duration of QRS deflections in left bundle branch block cases

bundle branch block cardiogram being here an accidental finding in patients with other diseases (melanosarcoma, cancer of the stomach, etc)

Table II gives the cardiac diagnoses, based upon clinical findings and autopsies, and the size of the heart in the different groups In classifying these cases, difficulty arose mainly in regard to the hypertensive and arteriosclerotic groups We believe that the incidence of hypertension has been underestimated, as past hypertension could not be determined from the case records In the arteriosclerotic group have been placed patients of relatively advanced age, with moderately raised or normal blood pressure, with moderate or no enlargement of the heart, and those with signs of severe arteriosclerosis The group with uncertain ætiology includes four patients with systolic and one with diastolic hypertension, one with syphilis, one with thyrotoxicosis, one with leukæmia, and one with pulmonary embolism

The size of the heart, given in Table II, was assessed partly from teleradiograms and partly at

TABLE II

CLINICAL DIAGNOSIS OF HEART DISEASE (PARTLY BASED ON AUTOPSIES) AND CARDIAC ENLARGEMENT IN 100 PATIENTS WITH LEFT B B BLOCK

Heart Disease	Number of cases	Cardiac Enlargement: Gross	Medium severe	Slight and moderate	Not enlarged	No roentgenogram or autopsy
Aortic stenosis	13	7	3	2	0	1
Aortic insufficiency (luetic aortitis 3)	6	5	1	0	0	—
Hypertensive	39	19	7	7	1	5
Probable hypertensive	3	—	1	1	1	—
Renal disease with hypertension	6	2	2	2	—	—
Hypertensive with myocardial infarction	9	6	1	0	1	1
" Left-sided " heart disease	76	—	—	—	—	—
Myocardial infarction	3	1	0	0	1	1
Arteriosclerotic	6	1	0	3	1	1
Uncertain or unclassifiable	14	4	4	4	1	1
No heart disease (melanosarcoma)	1	0	0	0	1	—
Total	100	45	19	19	7	10

autopsy The grouping was done by making a rough estimate of the size of the heart in two planes, and comparing it with the cardiothoracic index This rough estimate is thought to be more valuable than the cardiothoracic index alone Hearts weighing up to 350 grams are regarded as normal, those up to 500 grams as slightly enlarged, from 500 to 599 grams as moderately enlarged, and those weighing more than 600 grams as greatly enlarged

It is evident from Table II that conditions involving increased work for the left ventricle greatly predominate in our material Altogether, such conditions were present in 67 cases In the combined group, hypertension with cardiac infarction, left bundle branch block was certainly present before the occurrence of infarction in 3 cases and in only 4 of the 9 cases in this group could the bundle branch block be attributed to the infarction Including the remaining 5 cases from this group, there were 72 cases in all in which an affection of the left heart was regarded as the dominant pathogenic factor in the causation of bundle branch block In addition, there were several cases of slight hypertension in the arteriosclerotic group and the group of uncertain ætiology

The possibility of local damage to the branch exists in the three cases with infarction, in the six with arteriosclerotic heart disease without certain infarction, in four of the nine with hypertension and infarction, and possibly in the case with metastatic melanosarcoma, even though myocardial metastases were not found at autopsy, that is to say in 14 cases altogether

Having thus established a high incidence of left ventricular heart disease in our cases, namely over 70 per cent, we may now consider how often the left heart was sufficiently enlarged to account for the left bundle branch block Reference to Table II shows that out of 90 cases in which X-ray or autopsy data were available, there were 45 with gross and 19 with moderately severe cardiac enlargement, or altogether 64 cases (71 per cent) with enlargement of a degree that we may suppose sufficient to explain the bundle branch block

Both radiographic and post-mortem examination revealed enlargement which affected the left heart predominantly, and in only 4 or 5 cases was any considerable degree of co-existent right-sided enlargement found It may be noted that a heart may enlarge, as proved by serial radiographs, and yet remain within the upper normal limit of size Here the electrocardiogram may often give better information in the form of the characteristic picture of left ventricular hypertrophy

Fig 7 shows how 71 radiographically examined hearts are distributed in relation to the cardiothoracic index While 7 cases (+5) show normal values, 43 of the 71, or 60 per cent have a lower index than 1 80 The average cardiothoracic index is 1 74 If we compare this graph for the size of the heart in cases of left bundle branch block with that drawn

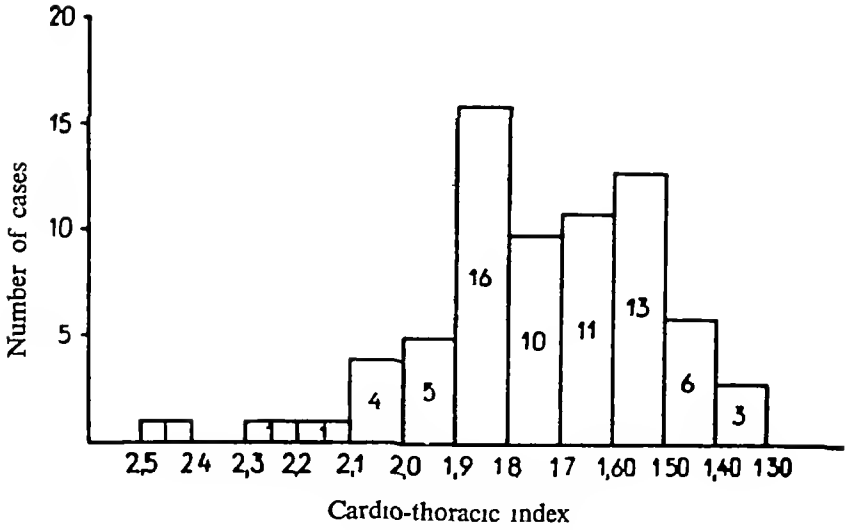

FIG 7—Distribution curve of cardiothoracic indices in 71 patients with left bundle branch block

by Ottar Müller (1942) for the left ventricular hypertrophy curves (see Fig 8), we see that there is some displacement to the right, i e towards the larger hearts, in cases of left bundle branch block, otherwise the two graphs are very similar Of the left bundle branch block patients 60 per cent had an index below 1 80, compared with 48 per cent of Müller's cases with left ventricular hypertrophy curves We may add that many of the largest hearts found post-mortem in cases of left bundle branch block were not radiographically examined *The cardiothoracic index is an insufficiently accurate* standard of heart size to permit more elaborate statistical analysis

The weight of the heart in 31 cases examined post-mortem is given in Table III, which shows that we are dealing with extremely large hearts, 17 of them weighing more than 600 grams and the average being 652 grams The largest heart, weighing 1780 grams, was from a 25-year-old man with aortic insufficiency and stenosis, as well as slight mitral disease and great thickening of the pericardium White states in his textbook that the largest heart *known to have existed weighed 1755 grams (Smith,*

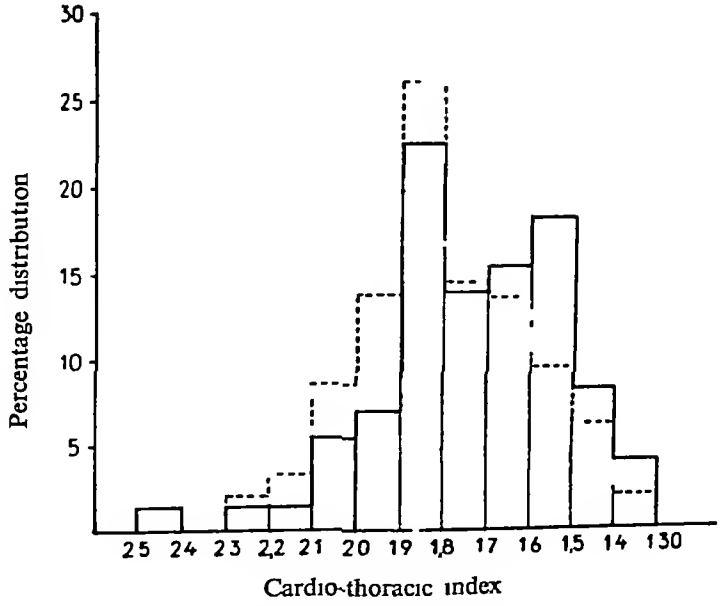

FIG 8—Percentage distribution of cardiothoracic indices in left bundle branch block (continuous line) compared with those in left ventricular hypertrophy (dotted line)

TABLE III

HEART WEIGHTS IN AUTOPSIES FROM 31 PATIENTS WITH LEFT B B BLOCK

Heart weight	Number of cases	Remarks
350 g and smaller	2	320 and 350 g
351–449 g	3	
450–499 g	5	
500–599 g	4	
600–799 g	11	
800–999 g	4	
1000 g and more	2	1030 and 1780 g
Total	31	

1855), so that we have in this series the *largest heart in the world*, but as in most of such huge hearts, there was great thickening of the pericardium For two of the hearts the weight was reckoned to be normal

In identifying the electrocardiogram of left ventricular hypertrophy, weighing the heart (and particularly the two ventricular muscles separately) has played a certain role (Lewis, 1913–14, Hermann and Wilson, 1921) We have given reasons for assuming that dilatation is of greater importance than hypertrophy of the muscle, and one of our two cases with a heart of normal weight may be cited to illustrate this point A woman, aged 58, who had a heart affection of uncertain ætiology with angina pectoris, increased basal metabolism and leukæmia, was found six months before death to have a considerably enlarged heart in radiographs, the heart volume being estimated at 985 ml, yet at autopsy the heart was found to weigh only 320 grams

It is obvious that many of the hearts from patients in these age groups will show arteriosclerotic changes in the coronary vessels The significance of reported post-mortem findings, such as "some sclerosis, no stricture," "highly sclerotic, no distinct obstruction," "extreme sclerosis," etc, cannot be judged in relation to the organic or functional disturbances that may be occasioned by a reduced blood supply to the heart muscle

SUMMARY AND CONCLUSIONS

In the course of previous investigations relating to the electrocardiogram in hypertension and in aortic incompetence, we reached the conclusion that the left bundle branch block cardiogram might be caused by gross enlargement of the left ventricle apart from any local lesion of the bundle branch

In the present investigation we have sought to test this hypothesis further by an analysis of the clinical, radiological, and necropsy findings in a series of 100 cases, presenting permanent left bundle branch block in the cardiogram It was found that diseases affecting the left ventricle, such as hypertension and aortic valvular disease, predominated in this material, occurring in 72 per cent of cases, and that a considerable degree of left ventricular enlargement occurred with about the same frequency In 14 cases there were reasons for presuming the existence of local damage to the left branch of the bundle, of which the most important cause was probably cardiac infarction involving the ventricular septum

Our investigation suggests that the left bundle branch block electrocardiogram is five times more often due to enlargement of the left heart than to a local lesion of the left branch of the bundle In this connection dilatation is deemed to be more important than hypertrophy

We have reason to believe that the *left ventricular hypertrophy curve* and the *left bundle branch block curve* represent different degrees of retarded conduction to the left heart, and that, therefore, no sharp distinction between them is necessary Both imply, in most but not in all cases, a considerable degree of left ventricular enlargement, and both are found in association with diseases that affect the left heart The terminology at present applied to these electrocardiograms is inadequate and the comprehensive term *electrocardiogram of left-sided retardation* might with advantage be employed to designate all patterns of electrocardiogram that indicate retarded conduction to the left heart, of which the bundle branch block type represents the most extreme grade

REFERENCES

Eppinger, H, and Rothberger, C J (1909) *Wien Klin Wschr*, **22**, 1091

Hermann, G R., and Wilson, F N (1921–2) *Heart*, **9**, 91

Lewis, T (1913–14) *Ibid*, **5**, 367

Master, A M, Kalter, H, Dack, S, and Jaffe, H L (1940) *Amer Heart J*, **20**, 186

Müller, O (1942) *Nord med Tidskr*, **28**, 2327

Rasmussen, H, and Thingstad, R (1939) *Acta med Scand*, **101**, 237

—— (1942) *Nord med Tidskr*, **13**, 436

—— (1942) *Acta med Scand*, **110**, 32

—— (1944) *Ibid*, **118**, 385

——, and Boe, J (1945) *Ibid*, **120**, 12

EROSION OF RIBS IN COARCTATION OF THE AORTA

A NOTE ON THE HISTORY OF A PATHOGNOMIC SIGN

BY

WILLIAM DOCK

From Long Island College of Medicine, Brooklyn, N Y

Received February 12, 1948

The reader of Bramwell's excellent study of coarctation of the aorta (1947) will have obtained a somewhat incomplete and faulty impression of the place of rib erosion in the diagnosis and in the medical history of that anomaly, for he is referred to " Roesler's classical paper " of 1928, and " similar observations " of Railsbach and Dock published " the following year " In an earlier paper describing the study of the distribution of notching of the ribs, Bramwell and Jones (1941) had not dealt with the historical side

Erosion of the ribs due to coarctation was first emphasized by English clinicians—Craigie (1841) and Walshe (1873)—as a regularly observed anatomical lesion It was completely overlooked by early radiologists, and in Roesler's long paper on coarctation (1928) the presence of erosions in one case was noted in passing As Roesler did not refer to the reports of Meckel (1827) and Jordan[1](1830), or to the English literature, he failed to draw attention to rib erosion as an important point in diagnosis Rib erosion is not referred to in the title of the paper, which did not attract the attention of radiologists This paper was in the December 1928 issue of *Wiener Archiv für Innere Medizin*, which, like many Austrian publications, came out weeks after its date of issue

The paper of Railsbach and Dock (1929) entitled *Erosion of the Ribs in Stenosis of the Isthmus (Coarctation) of the Aorta* appeared in *Radiology*, January 1929, and was in the hands of subscribers during that month Since most of these readers had in their files cases showing this lesion, but undiagnosed, and cases of known coarctation in which the erosions had been missed, it is safe to say more erosions were first correlated with the ætiological factor in the first three months of 1929 than in any similar period in history Awakening of interest in coarctation among radiologists dates from that article As the authors were familiar with the nineteenth century literature, they emphasized that these erosions were pathognomonic, and they minimized the diagnostic value of study of the cardiac and aortic silhouettes With this, all subsequent authors have agreed Roesler's paper is a classic on the cardiac silhouette in coarctation, but later authors failed to corroborate his views on its diagnostic value Railsbach and Dock's paper, which appeared simultaneously, stressed erosion of the ribs, summarized older anatomical knowledge, reproduced Meckel's original picture of rib erosion (1827) and has been confirmed by all subsequent students In routine chest films more cases of coarctation are detected by rib notching than by all other methods of physical examination put together No cases are diagnosed by the cardiac silhouette in such routine films Many cases, overlooked by physicians who recorded elevated blood pressure, have been picked up from rib erosions seen in 35 mm films of employees or college students, or in the routine films of the American draftees and enlisted personnel

For the English reader it may be of interest that a fact known to the great English cardiologists was confirmed and its practical value in the Roentgen era brought to the attention of radiologists by a California physician Just as Cesalpino's fellow-countrymen ignored his discovery and description of the circulation of blood, Craigie's and Walshe's fellow-countrymen were unaware of the classic descriptions of rib erosion as a result of coarctation of the aorta, and those who spoke the same language as Meckel were not aware of Meckel's paper on this subject Priority of discovery belongs to Meckel

EDITORIAL NOTE

An interesting point in connection with Meckel's original illustration of the collateral vessels in coartation of the aorta is that the erosions are shown on the upper borders of the ribs, though as we now know they actually occur only on the lower borders Meckel's figure shows erosions on the upper borders of the third and fourth ribs on the right side, none being shown on the left side It seems probable that the artist was responsible for this remarkable error

Dr Dock refers to Crighton Bramwell's paper on coarctation, and it is interesting to find that the only contemporary reference to Walshe's statement that the dilated collateral vessels might wear away the ribs is in Byrom Bramwell's *Diseases of the Heart* published in 1884

Maude Abbott (1928), in her monograph on coarctation of the aorta in the *American Heart Journal*, April 1928, published a radiograph in which erosion of the ribs is well seen, and a few pages later reproduced Meckel's original anatomical figure together with a legend in which the rib erosions are specified, yet the radiographic notches escaped her notice

At the meeting of the Cardiac Club in 1930, I presented "a case of coarctation of the aorta showing Roesler's sign" This was a patient under the care of Dr G E Beaumont at the Middlesex Hospital in whose radiograph notching of the ribs was noticed by Dr Maurice Weinbren in May 1929 In seeking an explanation, he came across the paper of Railsbach and Dock, to which he drew my attention Before presenting the case, I discovered Dr Roesler's reference to rib erosion and discussed it with him in Vienna, which explains my use of the eponym at the time

The merit of drawing attention to the diagnostic significance of rib erosion certainly belongs to Railsbach and Dock, who first portrayed it and correlated it with previously recorded anatomical observations which had been generally overlooked Dr Dock emphasizes the importance of Meckel's original description, even though Meckel portrayed the rib notches incorrectly

D EVAN BEDFORD

REFERENCES

Bramwell, C, and Jones, A M (1941) *Brit Heart J*, 3, 205
—— (1947) *Ibid*, 9, 100
Railsbach, O C., and Dock, W (1929) *Radiology*, 12, 58 (earlier literature cited here)
Roesler, H (1928) *Wien Arch inn Med*, 15, 521

COARCTATION OF THE AORTA

REVIEW OF TWENTY-THREE SERVICE CASES

BY

MAURICE NEWMAN

Received May 8, 1948

In Maude Abbott's series of 200 autopsied cases of coarctation of the aorta published in 1928, there were only 21 cases in which the diagnosis had been made during life Since Lewis' paper (1933), and especially since the radiological features of coarctation were described by Roesler (1928) and by Railsback and Dock (1929), the clinical diagnosis has been made far more frequently

The purpose of this paper is to present a brief analysis of 20 cases of coarctation of the aorta who served in the recent war, that have been collected in going through the records of the Ministry of Pensions service documents These cases have not been examined personally, but their records contain full details of pre-war occupation, examination prior to enlistment, duration and nature of service, clinical and radiological signs of coarctation found, and sometimes the after history To these 20 cases have been added 3 who served in the 1914–18 war where the diagnosis of coarctation was made in later years One of these has been described by Lewis (Case 2) but it has been included here because the service documents provide additional information of interest

Service History

Age Table I shows the age when coarctation of the aorta was first diagnosed in the recent war cases The youngest was 19 and the oldest 37 five were over 30 years of age All were males

Body Build Table I also shows the height and weight on entry into Service, at a younger age than that recorded in column 2, when the coarctation was diagnosed The striking feature was the good physical development and nourishment in the majority In about half of the series the recorded weight on entry into the services was over 140 lb Remarks such as "sturdy build," "heavily built," "powerful physique" were recorded in many cases, and all but 3 were graded fit for general service, or Grade I on entry In the three exceptions, the lowered category was due to the condition of the feet in one (Case 11), to the eyes in another (Case 18), and only once to the heart, in Case 6, diagnosed as mitral regurgitation on grounds of a systolic murmur heard in the mitral and aortic areas, the body weight in this case was 167 lb

It is interesting to note at this stage that in four other cases (10, 11, 12, and 19) a systolic murmur was noted at examination on entry, which was not regarded of such significance as to justify lowering the category Case 12 was graded I after a cardiologist's report diagnosing a slight congenital defect In five out of the twenty cases, therefore, a cardiac murmur was known to be present prior to the diagnosis of coarctation

Pre-Service Occupation It will be seen (Table I) that in only two of the series was the occupation sedentary Of the non-sedentary occupations about half may be considered as involving heavy work Case 5 was an athlete who played rugby football and was a quarter mile runner Case 7 played all games well at school and played football when he joined the Navy Case 19 was a county hockey player

Pre-Service history of Rheumatism On examination prior to entry into Service all are questioned, and the answer recorded, as to whether he or she has suffered from rheumatic fever or rheumatism in the past In the series of 20 recent war cases there was a history of rheumatic fever, rheumatism or chorea in 4 Case 2 recorded chorea at the age of 12, with 4 months absence from school, Case 4 muscular rheumatism in adolescence, Case 5 rheumatic fever when aged 7 and a recurrence at age 10, and Case 18 rheumatic fever when aged 18 This series, however, is too small to come to any conclusion as to whether cases of coarctation of the aorta are more vulnerable than normal to rheumatic infection In Abbott's series of 70 cases, only 8 had a history of rheumatism

Service prior to Cardiac Breakdown The majority

TABLE I

TWENTY CASES SERVING IN RECENT WAR

Case	Age when first diagnosed	Height	Weight	Pre-Service occupation	Examination on enlistment
		ft in	lb		
1	24	5 10	150	Grocer's assistant	Fit for service in any part of the world
2	24	5 4½	116	Fish fryer	Physical development good. Grade I
3	23	No record		Labourer	Well developed A 1
4	24	5 9¾	164	Grocer	Sturdy build Grade I
5	21	5 10	145	Motor-driver's mate	Athletic A 1
6	20	5 8	167	Builder's labourer	Systolic murmur Mitral regurgitation Grade III
7	20	No record		General labourer	Large man Grade I
8	33	5 8	152	Labourer	Grade I
9	32	5 6	139	Lorry driver	Grade I
10	25	5 10½	—	Clerk	Heavily built Systolic murmur Grade I
11	35	5 7	130	Bill-poster	Systolic murmur at apex Grade IIa (feet)
12	19	5 11	136	Transport mechanic	Well developed, soft systolic murmur Slight congenital defect Grade I
13	27	5 4	120	Labourer	Grade I
14	20	5 7	146	Electrician	Powerful physique Grade I
15	37	5 5½	123	Labourer	Grade I
16	20	No record		Model-maker	A.1
17	24	5 5½	126	Apprentice moulder	Fit for general service
18	35	5 7½	152½	Dock labourer	Grade IIa (vision)
19	20	5 9½	147	Surveyor	Slight mitral murmur Compensation good Grade I
20	29	5 9	147	Draper's assistant	Physical development good Grade I

served for several years as Grade I men, doing intensive training, and subjected to all the stress and strain of war, including overseas service Two (Cases 11 and 15) were only discovered on routine examination for service overseas after two years' in the forces This clearly demonstrates that men with coarctation may have the capacity to withstand severe physical strain for prolonged periods without any symptoms or signs of heart failure appearing

CLINICAL FINDINGS

Table II gives an analysis of the clinical findings in 22 cases including 3 of the 1914–18 war (Cases 21, 22, and 23) Case 20, only diagnosed at autopsy, is not included

Arterial Blood Pressure A raised blood pressure in the upper limbs is one of the most constant signs in coarctation of the aorta From Table II it will be seen that this was raised in every case in this series The lowest pressure recorded was 144/90 mm (Case 19), but this man was only 20 years of age when the coarctation was diagnosed He was aware that he had a " leaking heart " as a lesion had been discovered on routine examination at school, when aged 15 As there were no symptoms, no restriction on activity was imposed, he played strenuous games and was a county hockey player When examined a slight mitral murmur was detected but compensation was stated to be good and he was passed fit for general duties After two years' service, coarctation of the aorta was diagnosed but in the absence of symptoms he was retained in Category C He remained well for another three years until subacute bacterial endocarditis supervened and rapidly proved fatal

Where the blood pressure is recorded separately in each arm it will be noted that there is sometimes a difference between the two readings Usually it is lower in the left arm owing to the diminished circulation that results from the coarctation encroaching upon the orifice of the left subclavian artery In four cases, where the blood pressure in both arms was recorded, it was lower in the left arm than in the right, and once (Case 6) it was lower in the right

Blood Pressure in the Legs In every case there was a marked lowering of the arterial pressure in the lower limbs compared with the upper, and in many there was absence of the femoral pulse This emphasizes the importance of always palpating the femoral pulse in hypertension, especially in young people As the result of deficient circulation to the lower limbs symptoms of intermittent claudication may occur, as happened in Case 7 four years after coarctation had been diagnosed

TABLE II

ANALYSIS OF CLINICAL FINDINGS IN 22 CASES

Case	Blood pressure		Murmurs	Pulsation root of neck	Collateral circulation	Cardiac enlargement
	Brachial	Femoral				
1	RA 185/110 LA 150/90	102/?	Loud, blowing systolic axilla and back	+	−	+
2	200/140	—	Soft systolic and blowing diastolic, loud systolic medial to scapula	+	+	−
3	156/92	104/80	Harsh loud systolic all areas and back	+	+	Slight
4	225/120	—	Systolic—also over internal mammary and supra scapula arteries	+	+	+
5	RA 250/160 LA 210/120	—	Loud systolic præcordium and back	+	+	Slight
6	RA 195/110 LA 225/115	—	Systolic apex and aortic area	−	−	+
7	RA 204/120 LA 188/110	—	Systolic præcordium	+	+	+
8	210/100	—	Soft systolic apex diastolic base	−	−	+
9	225/115	175/120	Systolic all areas	+	+	+
10	190/100	—	Loud apical systolic	+	+	+
11	200/110	140/120	Loud systolic præcordium	+	+	+
12	200/110 R and L	110/?	Soft systolic over præcordium and paravertebral region near scapula	−	−	+
13	200/105	—	Loud systolic over præcordium	−	−	−
14	210/110	—	Rough basal systolic	−	−	−
15	230/120 R and L	130/?	Rough basal systolic maximal pulmonary area	+	+	−
16	168/100 R and L	?	Blowing systolic over pulmonary area	−	−	−
17	RA 195/105 LA 185/95	80/2	Harsh aortic systolic and blowing diastolic	+	+	+
18	180/110	—	Loud systolic all areas best heard over 3rd left space	−	−	+
19	144/90	—	Loud systolic all areas Loud diastolic 2nd and 3rd right space	+	+	+
21	190/110	130/?	Systolic apex and 2nd right space	+	+	+
22	178/102	—	Loud blowing systolic at apex conducted widely	+	+	+
23	276/120	156/120	Systolic over all areas including back	+	+	+

Murmurs The characteristic murmurs of coarctation of the aorta are systolic in time, sometimes loud and harsh in intensity, and heard all over the præcordium, often at the back in the region of the scapula, and over the dilated arteries forming the collateral circulation Systolic murmurs were recorded in every case in this series In 7 the murmur was heard posteriorly Reifenstein *et al* (1947) in reviewing 104 autopsied cases state that systolic murmurs were heard in all 60 in which mention was made of physical examination of the heart, and in 23 of them the murmur was heard posteriorly A systolic murmur is, therefore, to be regarded as one of the most constant findings in coarctation

In four (Cases 2, 8, 17, and 19) a diastolic murmur was also present Reifenstein *et al* state that a diastolic murmur is not found in uncomplicated coarctation of the aorta, but only when there is an associated aortic valvular deformity, including bacterial endocarditis or patency of the ductus arteriosus In Case 2 of my series, the diastolic murmur was most likely due to acquired rheumatic aortic incompetence, dating from an attack of chorea when he was 12, which necessitated four months absence from school In Case 8 the diastolic murmur was also likely due to an associated aortic regurgitation, for there was a history of rheumatism, and though the Wassermann reaction during Service was strongly positive, it was not considered to have any connection with the cardiac lesion In Case 17 radiological examination showed calcification of the aortic arch and probably an aneurysmal dilatation, which would explain the diastolic murmur Case 19 is the one already described which developed bacterial endocarditis, and an aortic valvular defect was probable Con-

genital bicuspid aortic valve is a common associated lesion in coarctation of the aorta, occurring in 24 per cent of Abbott's series (1928)

Pulsation at the root of the Neck Bramwell has pointed out that excessive arterial pulsation at the root of the neck should be included as one of the classical signs of coarctation of the aorta In my series this sign was noted in 15 and not noted in 7 of the 22 cases Once (Case 21) the association of marked visible pulsation in the suprasternal notch with a murmur in the aortic area, transmitted to the neck, led to an initial diagnosis of aortic aneurysm

Collateral Circulation Dilated collateral vessels were not observed in 9 of the 22 cases in this series, and therefore are not to be regarded as a sign that is essential for diagnosis of coarctation Campbell and Suzman (1947) have recently described a special method of demonstrating the collateral vessels when they are not normally evident

Radiological Diagnosis Although coarctation of the aorta may be diagnosed on clinical signs alone, many more cases have been diagnosed during life since erosion or notching of the lower borders of the ribs was described by Roesler (1928) and by Railsback and Dock (1929) Notching of the ribs depends on the development of the collateral circulation inside the thorax, and is not present in every case If there is a patent ductus arteriosus, rib notching is usually absent (Bramwell, 1947)

In the 22 cases of my series, rib erosion was recorded in 16, and was probably present in a further case (Case 6) in which coarctation of the aorta was diagnosed radiologically, though details were not given In Case 1, although no rib erosion was detected, there was some erosion seen at either end of the left clavicle This leaves only 4 out of 22 cases in which no erosion occurred (Cases 4, 9, 10, 21), and in these collateral vessels were present In Bramwell's series of 26 cases rib notching was absent in 4 cases On the other hand, 6 cases showed notching of the ribs without clinical evidence of a collateral circulation (Cases 8, 12, 13, 14, 16, and 18) It must be concluded, therefore, that rib notching is a valuable diagnostic sign of coarctation of the aorta

Absence or smallness of the aortic knuckle also appears to be a valuable sign of coarctation of the aorta, for in only two cases (Cases 10 and 14) was the aortic knuckle not reduced in size In Perlman's series of 13 cases, the aortic knuckle was absent in every case, and all of them showed some rib erosion

Radiological enlargement of the heart, usually the left ventricle, was noted in 16 of 21 cases of this series (In Case 6, details of radiological findings were not recorded) Enlargement of the heart did not appear to have any relation to the blood pressure In 4 of the 5 cases with no enlargement the systolic blood pressure in the arms was 200 mm or over (Cases 2, 13, 14, and 15) Unlike essential hypertension, the high blood pressure in coarctation of the aorta does not necessarily cause cardiac enlargement, as Lewis has emphasized

In five (Cases 1, 4, 5, 6, and 16), the diagnosis was made by the radiologist Case 1 was at first diagnosed as mitral stenosis In Case 4 no cardiac disability was suspected prior to a routine X-ray examination of the chest whilst convalescing from diphtheria Case 5 was X-rayed following a collapse whilst playing rugby football Case 6 was at first thought to be one of polycythæmia vera with hypertension In Case 16 the chest was X-rayed on account of bronchitis and asthma

In Case 10 there was no radiological evidence of coarctation of the aorta This man was a clerk before he joined the Royal Air Force in July 1940 At his medical examination prior to enlistment a systolic murmur was noted but was not regarded as of any significance and he was graded I There was no history of rheumatic fever or chorea but he was unable to play games during his last four terms at school owing to shortness of breath In March, 1941, he was examined for fitness for a commission as a pilot and was rejected A systolic murmur was noted at the apex and his blood pressure was 188/92 mm The diagnosis of hyperpiesia with cardiac bruit was made He was re-examined in October, 1941, owing to complaints of dyspnoea and attacks of pain over the heart, and his blood pressure was then 200/100 mm , he was still Grade I He was referred to a specialist who diagnosed mitral disease with hypertension He continued to serve until October, 1944, when he collapsed and was found unconscious at a railway station whilst being posted He was transferred to Middlesex Hospital where, after complete investigations, coarctation of the aorta was diagnosed, although there was no radiological evidence of it No erosion of the ribs was present and the aortic knuckle was prominent and high Tomograph of the aorta revealed no narrowing The barium swallow showed no enlargement of the left auricle but the left ventricle was slightly enlarged However, all the characteristic clinical signs of coarctation were present, namely increased blood pressure in the upper limbs (190/100 mm), absence of femoral pulsation, marked arterial pulsation in the neck and below the outer third of the clavicle, a loud systolic murmur at the apex of the heart and a collateral circulation in the axilla and scapular regions

Electrocardiographic examinations were recorded

in several cases but were not of diagnostic help In Case 19 a conduction defect was shown

Prognosis Bramwell concluded that patients with coarctation of the aorta whose symptoms date from childhood are unlikely to reach the age of 30, whereas in those who are free from symptoms until 30, the outlook is much more favourable

All of the recent war cases under discussion have reached adult life, the youngest case was aged 19 and the oldest aged 37, fifteen were under 30 years of age As already stated, the majority were of good physical development and fit enough to be graded I It would appear, therefore, that if symptoms do not become manifest in childhood there is no retardation of physical development or diminished fitness, and that such subjects are able to perform heavy physical work for a prolonged period without any symptoms or signs of cardiac failure, though eventually prolonged stress may cause cardiac symptoms

Table III shows the history of the 20 recent war cases after discharge Three deaths are recorded Case 20 died suddenly, at the age of 29, from rupture of the aorta whilst on leave after five years' army service as a Grade I man Neither prior to, nor during his five years' service, had there been any symptoms or signs of heart trouble He was examined on entry, and had twice been passed fit for overseas service without the detection of any cardiac disability The autopsy findings were as follows —

"Very well-developed, well-nourished man

TABLE III

HISTORY OF RECENT WAR CASES AFTER DISCHARGE

Case	Date of diagnosis	Date of discharge	
1	5 1 40	16 4 40	Worked as N A A F I manager Developed pulmonary tuberculosis 21 10 45 October, 1947, well and working
2	November, 1945	24 3 46	Working as a fitter, only symptom slight shortness of breath on exertion
3	11 8 43	23 3 44	Clerical work Complained of fainting attacks Admitted to Royal Infirmary, Edinburgh, 18 12 46 for operation Died from cardiac failure at close of operation
4	3 8 43	11 12 43	Resumed pre-service occupation has occasional days off
5	December, 1940	10 1 41	17 9 46 Worked as light vehicle driver and later as fitter Short of breath, headache, occasional dizziness
6	17 2 41	2 4 41	No further history no claim for pension
7	15 2 42	31 3 42	15 10 46 Working general handyman in building trade Shortness of breath on exertion intermittent claudication
8	26 6 44	11 6 40	Invalided from service, diagnosis myocardial degeneration Coarctation diagnosed by medical board 26 6 44 On 13 12 46 working in grocery business B P 200/120 No congestive failure
9	22 3 45	4 10 45	No further history
10	3 10 44	21 4 45	Working in radio trade
11	14 2 44	13 6 45	4 2 47 Complains of headaches, easily tired, short of breath on exertion Works at pre-war occupation—bill poster
12	6 4 45	19 8 45	21 1 47 Shortness of breath, occasional pain in the chest, dizziness Worked for three months after discharge then gave it up
13	November, 1945	19 11 45	5 12 46 Pain across upper part of chest at night lasting half hour Works as refuse collector for council no loss of time B P 190/120 No evidence of enlargement of left ventricle
14	23 6 41	28 3 44	24 1 47 Shortness of breath on exertion, feels tired General condition good B P 225/110
15	11 5 44	7 6 45	July, 1947 Pains over præcordium Works as lorry driver Heart not enlarged Visible pulsation in neck
16	22 12 44	16 3 45	7 10 46 Short of breath on exertion Joiner, March, 1945 to May, 1946, then lighter work as telephone wireman General condition good
17	27 8 45	9 1 46	11 3 47 Shortness of breath and dizzy attacks Clerk, loses one day a week B P 235/115 Heart enlarged, marked visible pulsation in neck
18	30 5 45	13 3 41	Invalided as rheumatic endocarditis Coarctation diagnosed by medical board, 30 5 45 Working as cinema doorman Electrocardiogram shows myocardial damage
19	14 8 41	11 4 44	7 5 44 Developed symptoms and signs of subacute bacterial endocarditis from which he died
20	27 8 45	—	Died suddenly whilst on leave Autopsy showed coarctation with rupture of the aorta

Pericardial sac distended with blood clot, ragged aperture at the back of the aorta - Heart very large, 700 g Left ventricle much hypertrophied, muscle firm Moderate degree of coarctation of the aorta and patchy atheroma above the aortic valves A ragged triangular tear in the intima just above the right coronary artery This opens into a dissecting aneurysm which has stripped off the intima over the greater part of the ascending aorta and arch Considerable amount of blood in the coats of the vessel, and rupture has occurred into the pericardium through the back of the ascending aorta There is nothing in any way suggestive of specific disease Extensive atheroma of the vessels at the base of the brain

"*Conclusions* Coarctation of the aorta with hypertrophy of the left ventricle and a dissecting aneurysm of the first part of the aorta which has ruptured into the pericardium"

According to Blackford (1928) sudden death from rupture of the aorta during or following severe exertion is not uncommon in coarctation of the aorta Case 3 died on the operating table from cardiac failure during operation for the coarctation At the operation coarctation was found immediately distal to the left subclavian artery, and the intercostal vessels were much dilated The other patient who died, Case 19, developed subacute bacterial endocarditis, after having served for 6 years He was diagnosed as coarctation in August, 1941, but as he had no symptoms he was retained in service in a low category Three years later subacute infective endocarditis supervened

All the other recent war cases, as far as is known, are still living Case 1 developed pulmonary tuberculosis with positive sputum in October, 1945, —five and a half years after discharge—but when examined for review of pension in October, 1947, was working and feeling well Case 7, when examined in October, 1946, had developed typical symptoms of intermittent claudication, but was working as a general handyman in the building trade Most of the remaining cases are able to carry on light work, although complaining of symptoms such as shortness of breath on exertion, pains in the chest, and giddiness

The 1914–18 war cases which have now been followed for a long period of years will be described more fully

Case 21 (Case 2 in Lewis' series) was examined for enlistment in the Royal Field Artillery in January, 1915 His occupation was described as a carman and washer in a garage and he gave his age as 35, though later documents show that his actual age on enlistment was 38 years Physical development is recorded as good and he was passed fit for general service He served for three and a half years including three months in France and two and a half years in Salonica. In 1916 and 1917 he was admitted to hospital on several occasions for malaria, but there is no record of any other complaints On Nov 26, 1917, whilst convalescing at Corfu from an attack of malaria, he was admitted to the British Military Hospital complaining of shortness of breath on exertion and slight pain in the region of the heart The bood pressure on admission was 240 mm Examination of the heart showed a systolic murmur at the apex transmitted to the axilla and a systolic murmur in the aortic area transmitted into the neck The pulse was collapsing "D A H" was diagnosed On invaliding home he was transferred to hospital and in February, 1918, examination showed a soft systolic musical murmur over the tricuspid area, and a second systolic murmur in the aortic area There was also a "soft murmur above the notch, also audible over both sides of the back from apices to level of fourth dorsal vertebra, 4 in beyond middle line on left side and 3 in on right side" Visible pulsation in the suprasternal notch was noted and a distinct diastolic shock over left upper front On X-ray examination no pulsation was seen but shadow of the large vessels seemed enlarged The Wassermann reaction was positive on Feb 20, 1918, but negative on April 10, 1918 On June 21, 1918, he was invalided from the Service with the diagnosis of aortic aneurysm

It is clear from the above clinical notes that many of the characteristic signs of coarctation of the aorta were present at this early date, 1917–18, as shown by the high blood pressure of 240 mm , the systolic murmur over the præcordium, also heard at the back, and visible pulsation in the neck above the sternum

When examined by a Medical Board including a cardiologist in November, 1919, it was stated there were no signs of aneurysm The blood pressure recorded was 250 mm The man was next medically boarded in 1922 when the blood pressure was still 250 mm , and the heart was recorded as enlarged The urine showed albumin and casts and the diagnosis was changed to nephritis with enlarged heart In November, 1925, he was admitted to hospital under Sir Thomas Lewis who diagnosed coarctation of the aorta on the grounds of a collateral circulation and weakening of the femoral pulse In September, 1939, he had an operation for removal of a renal calculus with no untoward effects On March 2, 1940, he collapsed whilst trying to sweep the snow from the front of his house He complained of severe pain in the left arm and back, and shortness of breath Examination showed marked pulsation above and below both clavicles, an irregular heart due to extrasystoles and the blood pressure in the arm was 190/110 mm and in the legs 130 mm systolic

In November, 1942, he was admitted to hospital with pain in the chest and hæmoptysis He had had eight attacks of loss of consciousness during the preceding two weeks, and heart block was found He improved with treatment and when seen by a Ministry of Pensions Medical Officer in January, 1944, he was keeping fairly

well He died, however, in October of the same year, at the age of 68

Case 22 was a greengrocer He enlisted in June, 1915, at the age of 20, and was found fit He served for a year and was then discharged with V D H (mitral obstruction) The clinical notes recorded a presystolic thrill and murmur at the apex, increase of cardiac dullness and tumultous action of the heart Examination a year later recorded a slight systolic murmur not conducted On lying down various murmurs were heard He had given up work as a stores-porter, as he found it too heavy In 1922 a medical board reported symptoms of pain over the left side of the chest and back The heart was enlarged clinically, the heart sounds irregular with a presystolic murmur at the apex The diagnosis was mitral stenosis with fibrillation When examined in 1924, complaints were giddiness, shortness of breath, and præcordial pain The heart was moderately enlarged, rhythm normal (quinidine had been given) and there was a short diastolic murmur at the apex In 1929 it was recorded that the man had done no work for the last year There was some cyanosis, the heart was enlarged with systolic and diastolic murmurs at the apex, and the rhythm irregular

In April, 1932, the man was admitted to Roehampton Hospital where coarctation of the aorta was diagnosed by the radiologist The clinical notes recorded the apex beat an inch outside the nipple line, and a loud blowing apical systolic murmur conducted widely No collateral circulation was detected Marked pulsation in the vessels of the neck was present Blood pressure in arms 178/102 mm , femoral pulse not felt The radiological report was " Heart considerably enlarged in all diameters, aortic arch small Bilateral irregularity of lower margins of ribs Appearance of coarctation of the aorta "

When seen in December, 1940, he was confined to bed with influenza He stated he had been keeping fairly well since he had been in hospital and had been working as a shop-porter Examination showed evidence of heart block The pulse was regular rate 42 The blood pressure in the arms was 195/100 mm He was last seen in September, 1941, when he was confined to bed, dyspnœic and cyanosed Pulse rate 42 Blood pressure 180/100 mm There was evidence of congestive failure, namely, râles at the lung bases and some œdema of the legs This was twenty-five years after the onset of symptoms

Case 23 This man enlisted in October, 1916, at the age of 24 and went to France In May, 1918, he was admitted to hospital with the diagnosis of pyrexia of unknown origin He complained of pains, shivering and vertigo Examination revealed a loud systolic murmur over the præcordium, best heard at the apex and conducted to the axilla, and also heard at the back at the level of the second to fifth dorsal vertebræ There was marked pulsations at the root of the neck Radiological examination showed enlarged root shadows, no aneurysm, and a very greatly enlarged heart The man was invalided with the diagnosis of V D H In 1922 the man was complaining of shortness of breath, pain over the heart, and faintness at times A systolic bruit was noted at the apex and base of the heart, but no presystolic or diastolic murmur In 1925 his symptoms were worse The blood pressure, recorded for the first time, was 200/90 mm A harsh systolic murmur was noted at the apex and base

In 1931 the man was admitted to Roehampton Hospital It was stated he had been doing his usual work as a labourer He complained of giddiness and faintness The apex beat was forcible and outside the nipple line A systolic murmur was present over the aortic and mitral areas, no diastolic murmur was present There was forcible pulsation at the root of the neck Blood pressure was 255/120 mm , the radiologist's report was as follows —

> " Enlargement of the left side of the heart, usual projection of the aortic arch not shown, irregularity of the lower rib margins on both sides from the third rib downwards Appearance that of coarctation of the aorta "

In 1935 he was only able to do light work owing to pain across the chest and fainting attacks The blood pressure in the arm was 230/110 mm The femoral pulse could not be felt The Wassermann reaction was negative The cardiogram showed left ventricular preponderance and slight widening of the QRS complexes

In 1937 he was working as a casual labourer There was visible pulsation under the left clavicle No collateral vessels were detected The brachial blood pressure was 260/145 mm The right femoral pulse was just palpable but there was no pulsation in the left

When last seen, in December, 1946, aged 54, he could not walk far There was triple rhythm at the apex but no congestive failure

These records show that patients with coarctation of the aorta may live for many years after the first appearance of signs and symptoms, and in spite of persistent hypertension For example, Case 21 survived for 27 years after signs of coarctation and a blood pressure of 240 mm were first recorded, and Case 23 was alive and free from congestive failure 21 years after his blood pressure had been recorded as 200/90 mm

Summary

A review is given of 23 cases of coarctation of the aorta, 20 of which served in the recent war, and 3 in the 1914–18 war

These men had been fit prior to enlistment and were of good physical development They were able to withstand the severe stress of war service for long periods before symptoms occurred

The most constant clinical signs of coarctation were a raised blood pressure in the arms associated with a diminished femoral pulse, evidence of a collateral circulation, a systolic murmur audible over the front and back of the chest, and abnormal pulsation at the root of the neck The

most constant radiological signs were erosion of the ribs and absence or smallness of the aortic knuckle

Severe hypertension may persist for many years in these cases without causing heart failure and some may live a normal span of life The later the symptoms appear the better the prognosis

I wish to thank Dr Prideaux, Director General of Medical Services of the Ministry of Pensions, for his permission to publish this paper

REFERENCES

Abbot, M E (1928) *Amer Heart J*, **3**, 574
—— (1936) *Atlas of Congenital Cardiac Disease*, New York
Blackford, L M (1928) *Arch intern Med*, **41**, 702
Bramwell, C (1947) *Brit Heart J*, **9**, 100
Campbell, M, and Suzman, S (1947) *Ibid*, **9**, 185
Dock, W (1932) *J Amer med Ass*, **99**, 2024
Eppinger, E C, and Mittelfart, P A H (1933) *Amer J med Sci*, **185**, 528
Lewis, T (1933) *Heart*, **16**, 205
Perlman, L (1944) *Amer Heart J*, **28**, 24
Railsback, O C, and Dock, W (1929) *Radiology*, **12**, 58
Reifenstein, G H, Levine, S A, and Gross, R E (1947) *Amer Heart J*, **33**, 146
Roesler, H (1928) *Wein Arch inn Med*, **15**, 521

THE RIGHT PRÆCORDIAL LEAD

BY

HARRY VESELL AND BENJAMIN SHORR*

From the Cardiological Laboratory, Beth Israel Hospital, New York City

Received January 15, 1948

Recent studies in clinical electrocardiography have indicated the desirability of taking multiple præcordial leads as a general routine practice In their secondary supplementary report (1943) the Committee of the American Heart Association for the Standardization of Præcordial Leads stated that they believed that three is the least number of præcordial leads that can be regarded as satisfactory for general purposes They suggested that those who wished to reduce the number of such leads to a minimum take leads from the C 1, C 3, and C 5 positions All were urged to take additional leads whenever possible Though a right præcordial lead, C 1, is recommended for general use, sufficient data have not yet been obtained on this lead either in regard to the range of normal or concerning its various abnormalities Furthermore there is no agreement as to what is the best distal electrode for general use, a matter of considerable practical importance The Wilson central terminal electrode, the right arm, the left leg, and the right scapula has each been preferred by different investigators

In an attempt to gain further information on the right præcordial lead C 1 and to assess its value for general use we (1) have reviewed previous reports in which such a lead was employed , (2) have taken a series of electrocardiograms including this lead on patients without heart disease to determine the range of normal variations , and (3) have also noted characteristic alterations in CF_1 in certain cardiac conditions particularly posterior wall infarction, in which the use of this lead may be helpful

Kossman and Johnson in 1935 reported on the normal variations in multiple præcordial leads Their subjects were 30 medical students They used the central terminal distal electrode and the right pectoral † position With this lead V 1 they found no Q wave, R, 1 0 to 9 6 mm , S, 3 4 to 24 mm , T from −4 0 to +5 6 mm and RS (intrinsic inflection) 6 6 to 26 8 mm An electro-negative T wave was found in 3 out of the 30 cases in V 1

Wood and Seltzer (1939) examined the right pectoral lead using both the right arm and the left leg as sites for distal electrodes In regard to the QRS complex they found S dominant in 75 per cent with the use of the right arm and 95 per cent when the proximal electrode was paired with the left leg When the right arm was used the T wave remained upright, but when the left leg was used the T wave often became inverted Thus in CF_1, T was inverted in 65 per cent of normal children and 56 per cent of normal adults With progressive enlargement of the left ventricle they found the incidence of negative T waves fell from 58 per cent to nil in grade III enlargement In other words if there was significant enlargement of the left ventricle T was upright Hearts displaced by a high diaphragm to give left axis deviation in the standard leads did not act in the same way Of twelve normal pregnant women with left axis deviation in the limb leads, ten had inverted T waves and two diphasic T waves in CF_1 These authors concluded that in the right pectoral lead (CF_1) one has a means of distinguishing left ventricular enlargement from displacement of the heart due to a high diaphragm They indicated also that dominance of the right ventricle may be better ascertained in the right pectoral lead by the use of the left leg, rather than the right arm for the distal electrode In the former an R taller than S was more certain of this interpretation In cases of posterior myocardial infarction they stated they derived no help from the chest leads for the limb leads required no support and the chest leads had but little to give Deeds and Barnes (1940), Shanno (1940), and Sigler (1944), have also described characteristics of lead CF_1 These are summarized in the Table

Wilson and his associates in 1944 published

* Fellow in Cardiology

† Right præcordial and right pectoral are used synonymously for the C_1 position in this paper

TABLE

RIGHT PRÆCORDIAL LEAD CF_1

	Cases	P, mm Minimum	P, mm Maximum	R,* mm Minimum	R,* mm Maximum	R absent	S, mm Minimum	S, mm Maximum	T, mm Minimum	T, mm Maximum	Percentage with negative T
Deeds and Barnes, 1940	100	−1 7	+0 5	0 2	9 8	—	6 0	35 0	−6 0	+6 7	—
Shanno, 1940	100	−2 0	+2 0	4 0	7 0	4·0	2 0	30 0	−6 0	+7·0	70
Sigler, 1944	100	−1 8	+0 6	0 2	10 0	—	4 0	35 0	−4 5	+5 5	51
Vesell and Shorr †	265	−2 8	+0 8	0 2	7 4	4 9	2 8	25 0	−4 6	+4 2	69
Wood and Seltzer, 1939	—	—	—	—	—	—	—	—	—	—	58

* Q was absent in all

† RS–T was often elevated up to a maximum of 1 8 mm

multiple præcordial lead electrocardiograms taken with the Wilson central terminal electrode in patients with myocardial infarction The right pectoral lead V 1 was included, and they observed that with this lead in cases of high lateral, plain posterior and postero-lateral infarcts R and T of V 1 (and V 2) were unusually prominent This was not so in postero-inferior infarction In an article in 1946 he and his associates noted in the single case of high postero-lateral myocardial infarction that T waves became taller in leads from the right side of the præcordium

The following is an analysis of the normal variations of the præcordial electrocardiogram taken in the right pectoral position CF_1 The subjects were 265 adults There were two groups In the first, all tracings were taken with the patient in the sitting position This group consisted of 200 working men between the ages of 30 and 68 years, and only 11 were in the seventh decade The majority were labourers, all were ambulant No clinical evidence of heart disease was found in an ordinary history and physical examination and the routine four lead cardiogram (standard limb leads I, II, III, and CF_4) was normal by usual criteria * In many a teleradiogram was taken and was normal In the second group the cardiogram was taken with the patient in the recumbent position The subjects were 65 men and women They were patients in the hospital or office patients in private practice, their ages were from 20 to 58 years As in the first group the heart was considered to be normal after an ordinary history, physical examination and four lead cardiogram In the majority a cardiac fluoroscopy was done and was normal In some the CF_1 lead was taken in both the recumbent and sitting position

The cardiograph used was a string galvanometer, either the Cambridge mobile unit or Cambridge simplitrol The electrodes were the conventional ones, 3 5 × 6 cm, of german silver A circular electrode 3 cm in diameter was often used for the præcordial leads and was kept in place by an elastic rubber belt The chest electrode was placed in the fourth intercostal space at the right margin of the sternum, and the distal electrode just above the left ankle A suitable electrode paste was employed Standardization of the string, 1 cm for 1 mv, was made and recorded with each lead Measurements recorded were usually the average of several deflections or segments Frequently a magnifying lens was used

In view of the fact that the normal variations in CF_1 revealed little or no difference in the two groups, they were considered as one group of 265 cases to include males and females, and sitting and recumbent positions P ranged from −2 8 to +0 8 mm, 88 per cent were negative, 9 per cent diphasic, and only 3 per cent positive, the average negative P was −1 3 mm, the average positive T was +0 5 mm Q, interpreted to mean an initial negative QRS deflection followed by a positive, R, deflection, was not observed in any of the 265 In 13 (5 per cent) there was (see Fig 3) an absent R wave (i e monophasic negative QRS wave) In several other instances where the R wave was very small, about 0 2 mm, there were occasional complexes in the same tracings in which no R was visible also forming a monophasic negative QRS (S) complex This monophasic negative wave, S, ranged from −4 5 to −17 0 mm with an average of −10 8 mm R ranged in amplitude from 0 2 to 7 4 mm The average was 2 mm Occasionally there was some slurring of R, this was usually in small deflections and was slight S, ranged in amplitude from −2 0 to −25 0 mm with an average of −13 2 mm There was infrequent slurring and this was usually with waves of low voltage and was only slight R^1, was

* Criteria Committee of the New York Heart Association (1939), New York

THE RIGHT PRÆCORDIAL LEAD

BY

HARRY VESELL AND BENJAMIN SHORR*

From the Cardiological Laboratory, Beth Israel Hospital, New York City

Received January 15, 1948

Recent studies in clinical electrocardiography have indicated the desirability of taking multiple præcordial leads as a general routine practice In their secondary supplementary report (1943) the Committee of the American Heart Association for the Standardization of Præcordial Leads stated that they believed that three is the least number of præcordial leads that can be regarded as satisfactory for general purposes They suggested that those who wished to reduce the number of such leads to a minimum take leads from the C 1, C 3, and C 5 positions All were urged to take additional leads whenever possible Though a right præcordial lead, *C 1*, is recommended for general use, sufficient data have not yet been obtained on this lead either in regard to the range of normal or concerning its various abnormalities Furthermore there is no agreement as to what is the best distal electrode for general use, a matter of considerable practical importance The Wilson central terminal electrode, the right arm, the left leg, and the right scapula has each been preferred by different investigators

In an attempt to gain further information on the right præcordial lead C 1 and to assess its value for general use we (1) have reviewed previous reports in which such a lead was employed , (2) have taken a series of electrocardiograms including this lead on patients without heart disease to determine the range of normal variations , and (3) have also noted characteristic alterations in CF_1 in certain cardiac conditions particularly posterior wall infarction, in which the use of this lead may be helpful

Kossman and Johnson in 1935 reported on the normal variations in multiple præcordial leads Their subjects were 30 medical students They used the central terminal distal electrode and the right pectoral † position With this lead V 1 they found no Q wave, R, 1 0 to 9 6 mm , S, 3 4 to 24 mm , T from −4 0 to +5 6 mm and RS (intrinsic inflection) 6 6 to 26 8 mm An electro-negative T wave was found in 3 out of the 30 cases in V 1

Wood and Seltzer (1939) examined the right pectoral lead using both the right arm and the left leg as sites for distal electrodes In regard to the QRS complex they found S dominant in 75 per cent with the use of the right arm and 95 per cent when the proximal electrode was paired with the left leg When the right arm was used the T wave remained upright, but when the left leg was used the T wave often became inverted Thus in CF_1, T was inverted in 65 per cent of normal children and 56 per cent of normal adults With progressive enlargement of the left ventricle they found the incidence of negative T waves fell from 58 per cent to nil in grade III enlargement In other words if there was significant enlargement of the left ventricle T was upright Hearts displaced by a high diaphragm to give left axis deviation in the standard leads did not act in the same way Of twelve normal pregnant women with left axis deviation in the limb leads, ten had inverted T waves and two diphasic T waves in CF_1 These authors concluded that in the right pectoral lead (CF_1) one has a means of distinguishing left ventricular enlargement from displacement of the heart due to a high diaphragm They indicated also that dominance of the right ventricle may be better ascertained in the right pectoral lead by the use of the left leg, rather than the right arm for the distal electrode In the former an R taller than S was more certain of this interpretation In cases of posterior myocardial infarction they stated they derived no help from the chest leads for the limb leads required no support and the chest leads had but little to give Deeds and Barnes (1940), Shanno (1940), and Sigler (1944), have also described characteristics of lead CF_1 These are summarized in the Table

Wilson and his associates in 1944 published

* Fellow in Cardiology

† Right præcordial and right pectoral are used synonymously for the C_1 position in this paper

TABLE

RIGHT PRÆCORDIAL LEAD CF_1

	Cases	P, mm Minimum	P, mm Maximum	R,* mm Minimum	R,* mm Maximum	R absent	S, mm Minimum	S, mm Maximum	T, mm Minimum	T, mm Maximum	Percentage with negative T
Deeds and Barnes, 1940	100	−1 7	+0 5	0 2	9 8	—	6 0	35 0	−6 0	+6 7	—
Shanno, 1940	100	−2 0	+2 0	4 0	7 0	4 0	2 0	30 0	−6 0	+7 0	70
Sigler, 1944	100	−1 8	+0 6	0 2	10 0	—	4 0	35 0	−4 5	+5 5	51
Vesell and Shorr †	265	−2 8	+0 8	0 2	7 4	4 9	2 8	25 0	−4 6	+4 2	69
Wood and Seltzer, 1939	—	—	—	—	—	—	—	—	—	—	58

* Q was absent in all
† RS–T was often elevated up to a maximum of 1 8 mm

multiple præcordial lead electrocardiograms taken with the Wilson central terminal electrode in patients with myocardial infarction The right pectoral lead V 1 was included, and they observed that with this lead in cases of high lateral, plain posterior and postero-lateral infarcts R and T of V 1 (and V 2) were unusually prominent This was not so in postero-inferior infarction In an article in 1946 he and his associates noted in the single case of high postero-lateral myocardial infarction that T waves became taller in leads from the right side of the præcordium

The following is an analysis of the normal variations of the præcordial electrocardiogram taken in the right pectoral position CF_1 The subjects were 265 adults There were two groups In the first, all tracings were taken with the patient in the sitting position This group consisted of 200 working men between the ages of 30 and 68 years, and only 11 were in the seventh decade The majority were labourers, all were ambulant No clinical evidence of heart disease was found in an ordinary history and physical examination and the routine four lead cardiogram (standard limb leads I, II, III, and CF_4) was normal by usual criteria * In many a teleradiogram was taken and was normal In the second group the cardiogram was taken with the patient in the recumbent position The subjects were 65 men and women They were patients in the hospital or office patients in private practice, their ages were from 20 to 58 years As in the first group the heart was considered to be normal after an ordinary history, physical examination and four lead cardiogram In the majority a cardiac fluoroscopy was done and was normal In some the CF_1 lead was taken in both the recumbent and sitting position

The cardiograph used was a string galvanometer, either the Cambridge mobile unit or Cambridge simplitrol The electrodes were the conventional ones, 3 5 × 6 cm , of german silver A circular electrode 3 cm in diameter was often used for the præcordial leads and was kept in place by an elastic rubber belt The chest electrode was placed in the fourth intercostal space at the right margin of the sternum, and the distal electrode just above the left ankle A suitable electrode paste was employed Standardization of the string, 1 cm for 1 mv , was made and recorded with each lead Measurements recorded were usually the average of several deflections or segments Frequently a magnifying lens was used

In view of the fact that the normal variations in CF_1 revealed little or no difference in the two groups, they were considered as one group of 265 cases to include males and females, and sitting and recumbent positions P ranged from −2 8 to +0 8 mm , 88 per cent were negative, 9 per cent diphasic, and only 3 per cent positive, the average negative P was −1 3 mm , the average positive T was +0 5 mm Q, interpreted to mean an initial negative QRS deflection followed by a positive, R, deflection, was not observed in any of the 265 In 13 (5 per cent) there was (see Fig 3) an absent R wave (i e monophasic negative QRS wave) In several other instances where the R wave was very small, about 0 2 mm , there were occasional complexes in the same tracings in which no R was visible also forming a monophasic negative QRS (S) complex This monophasic negative wave, S, ranged from −4 5 to −17 0 mm with an average of −10 8 mm R ranged in amplitude from 0 2 to 7 4 mm The average was 2 mm Occasionally there was some slurring of R, this was usually in small deflections and was slight. S, ranged in amplitude from −2 0 to −25 0 mm with an average of −13 2 mm There was infrequent slurring and this was usually with waves of low voltage and was only slight R^1, was

* Criteria Committee of the New York Heart Association (1939), New York

noted 46 times and ranged in amplitude from 1 0 to 7 5 mm It was frequently slurred QRS duration was the same as in CF_4 or in the limb leads, no noticeable difference was seen RS–T segment was often elevated, up to 1 8 mm , RS–T depression was not seen T ranged from −4 6 to +4 2 mm , it was negative in the majority of tracings, 183 of the 265, or 69 per cent 46 were diphasic, +−, most of these were preponderantly negative There were only 34 of the 265 (13 per cent) in which T was positive Only 3 of the 37 females (8 per cent) had a positive T In these three the amplitude of T was +4 0, +2 2 and +1 6 mm with an angle alpha of +55°, +74° and +20° In the whole series of 265 there were only 5 with T of +3 mm or more, the average of the positive T waves was 1 8 mm

In 15 cases in which T was negative with the patient in the sitting position a tracing was also taken, at the same time, with the patient in the recumbent position In all 15 the T remained negative with little variation in depth In 4 patients (2 male and 2 female) with a positive T in CF_1 in the recumbent position the tracing was also taken in the sitting position In the latter position the T remained the same in two and in the other two was slightly reduced, from 1 2 to 1 0 mm and from 1 6 to 1 2 mm

The relationship of deviation of the electrical axis of QRS to negative T waves in CF_1 was examined Axis deviation of QRS was expressed by angle alpha measured on a Dieuaide chart In the 265 cases angle alpha ranged from −35° to +115° No correlation of T wave negativity with deviation of the electrical axis of QRS was noted, positive and negative waves were observed almost as frequently in the range of 0° to −35° as in that of +70° to +115°

Tracings in which a Q wave was present in limb lead III were examined, there were 123 No correlation was noted with respect to T in CF_1 in that both negative and positive T waves were observed in this group There were 11 of the series of 265 in which the Q III was prominent, 25 per cent of the largest R in the three limb leads, with no S III, and without right axis deviation Here also both negative and positive T waves were noted in CF_1 In five, T in CF_1 was negative, in five diphasic, +−, and in one it was positive Thus in normal subjects a negative T in CF_1 may occur with a prominent Q III This is of significance in the light of the T wave findings with posterior wall infarction described later

The effect of axis deviation on the RS deflection was the following in 51 cases the angle alpha was between 0 and −35° R averaged 1 4 mm and S averaged 8 0 mm , the relationship of R to S varied considerably in this group, from 1 to 2 to 1 to 28, with the exception of one case in which R was larger than S and R S was as 1 to 0 4 In the group (24) with angle alpha of +80° to +115° the average for R was 1 76 mm and for S 12 0 mm the ratio R to S ratio ranged from 1 2 to 1 18 Thus for the whole group of 265 normals, in the axis range most to the right (clockwise), R averaged 25 per cent larger and S 50 per cent deeper than in the axis range most to the left (counter-clockwise) There was only one tracing in the whole series of 265 where R was larger than S, R=3 2, S=−1 5 mm and angle alpha −17°

There was some correlation between R and S in CF_1 and CF_4 It has been pointed out that in normals R increases in amplitude as one goes from CF_1 to CF_4 or CF_5 and that S decreases This was generally found to be so and R was larger in CF_4 than in CF_1 in all but 5 of the 265 cases, usually the difference in amplitude was considerable In the 5 exceptions where R in CF_1 was larger it was 4 0, 4 8, 3 9, 4 8, and 4 7 mm , while R IV was 2 0, 3 0, 2 5, 3 6, and 3 0 mm with angle alpha of +55°, +68°, +50°, +77°, +75° respectively S was not infrequently larger in CF_4 than in CF_1

No correlation was noted between negative T waves in CF_1 and amplitude of T in CF_4 except that T in the latter was always positive while T in CF_1 was negative in 69 per cent

Fifteen cases with the cardiographic pattern of left ventricular strain were examined The pattern of left ventricular strain consisted of a tall R I, deep S III, depressed RS–T I (often RS–T II) and frequently inversion of T I and occasionally of T II In all 15, T was upright in CF_1 except for one in which the T was diphasic, − 4 and +1 0 mm The average for T was +2 2 mm These findings are largely in accord with those of Wood and Seltzer who found T wave negativity in CF_1 to be reduced in left ventricular enlargement and absent when the enlargement was marked In the cases with the cardiographic pattern of left ventricular strain, enlargement of the left ventricle was practically always present In this group R tended to be smaller than in normals, the average was 0 97 mm compared with 2 0 mm for the series of normals, in seven of the fifteen, R=O and R^1 was present three times S in this group tended to be deeper than in the normal, the average was 18 4 mm compared with 13 2 mm for the normals

CF_1 in Posterior Wall Infarction

A white woman, 64 years of age, for several years a private patient of one of the authors, was examined at his office on April 17, 1941 Her medical condition was essential hypertension and chronic osteo-

arthritis involving the joints of the arms, legs, feet, and spine There was no chest pain related to effort, no mid-chest pain and no undue shortness of breath Heart sounds normal, blood pressure, 168/110, lungs clear, liver not palpable, and no œdema of the lower extremities Fluoroscopy revealed the heart to be of normal size, shape, and position, the thoracic aorta was somewhat tortuous A cardiogram, taken with the patient recumbent, showed some left axis deviation, angle alpha was −15° The tracing was within normal variations The T waves in leads I, II, and IV were upright, 3 4, 2 0, and 5 4 mm respectively The RS–T segment was elevated, 0 5 mm in lead I, and depressed 0 4 mm in lead III In lead CF_1, P was −0 8 mm , R, 0 4 to 0 8 mm , S−6 5 mm , RS–T, elevated 0 2 mm , and T inverted, −0 5 to −0 8 mm (Fig 1) Four days later (April 21, 1941) while at home she suddenly developed severe prolonged substernal pain with the clinical picture of acute myocardial infarction The cardiogram taken that day (Fig 1) showed changes from the one taken four days before RS–T in lead II became slightly elevated, with shouldering as it continued into the coved and inverted T wave Lesser changes were present in leads I and III CF_1 was not taken Two days later, April 23, the second day of the acute attack, another cardiogram revealed progressive cardiographic changes in leads II and III characteristic of the pattern of recent posterior wall infarction In CF_1, T, which 6 days before was inverted, was now on the second day of the acute attack upright and of moderate amplitude, 2 8 mm , moderately tall for CF_1 P remained unchanged while R became taller, 2 4 mm compared with 0 4 to 0 8 mm before the attack, S became slightly deeper, −8 0 mm compared to −6 5 mm , RS–T which was elevated 0 2 mm prior to the attack was now depressed to 0 2 mm below the isoelectric line T remained upright in tracings taken ten days, 59 days and 136 days after the onset of the attack though gradually decreasing in amplitude, 2 5, 1 5, and 0 8 mm respectively (Fig 1) In this last tracing (136th day) T in lead II had become upright and was 0 8 to 1 0 mm in amplitude

Fourteen months later T in CF_1 again became inverted, 1 6 mm , R reduced to 0 0 to 0 2 mm , and RS–T isoelectric The standard limb leads were similar to those taken before the attack with the exception of the presence of a small Q in lead II, 0 5 to 1 0 mm , R I was slightly taller, R III correspondingly smaller, and T IV 2 5 mm smaller A cardiogram five years later (October 1947) revealed little change A large Q wave was present in the augmented unipolar left leg lead

Cardiograms including CF_1 were taken on another patient before and after an attack of acute myocardial infarction (Fig 2) Leads II and III after the attack were characteristic of the pattern of posterior wall infarction In lead CF_1, T which was negative before the attack became positive after the attack, R became taller

These findings indicated that with acute posterior wall infarction certain changes occurred in lead CF_1 The changes in the T wave in this lead were striking and it was thought they might be expressive of the specific cardiac lesion and helpful in diagnosis Accordingly, electrocardiograms in cases with the clinical picture of recent myocardial infarction and with the electrocardiogram in the limb leads characteristic of the pattern of posterior wall infarction were examined All had a prominent Q II and Q III with inverted T II and T III, none had right axis deviation There were 35 cases, all were patients in the hospital, 31 males and 4 females, ages ranged from 41 to 78 years The measurements in lead CF_1 were P, −0 3 to −2 0 mm , 3 were +−, there were no positive P waves and none of unusual or abnormal configuration Q waves were not present R, 0 5 to 9 0 mm , no absent R, the average was 3 9 mm and taller than in the series of normals where the average was 2 0 mm S, 0 0 to −19 2 mm , average −8 2 mm smaller than in the normal series where the average was −13 2 mm R^1 was present twice, each 2 0 mm QRS duration appeared unaltered RS–T was depressed in 6, 0 2, 0 8, 1 0, 1 0, 1 5 and 1 5 mm below the isoelectric base line, in two, J was the lowest point of the segment and the ascending limb of the T wave gradually rose from it In nine, RS–T was elevated 0 2 to 1 8 mm T was positive in all 35 cases and the range was from 1 0 to 9 0 mm with an average of 3 1 mm T was generally taller than in normals where the average positive T was 1 8 mm and in only 5 of the 265 normals was T 3 mm or taller Negative T waves were not observed The configuration and duration of the T did not appear abnormal

Observations were not made on the duration of these changes in CF_1 in the 35 patients after their discharge from the hospital However, in the first case described above the T wave changes were noted to last at least 4 months In a cardiogram 14 months after the attack the T wave was again negative

Thus it appears that lead CF_1 reflects changes in the posterior wall of the heart, exhibiting characteristic alterations with infarction of this area The cardiographic changes are of opposite sense to those observed in the unipolar left leg lead in this condition, and may be contributed at least in part by the left leg component R became taller and S

deeper RS–T often was depressed below the base line This did not occur in normals The most striking alteration was in the T wave which was positive in all such cases though in the normal T was positive in only 12 per cent and even less in females This T wave alteration in CF_1 could be

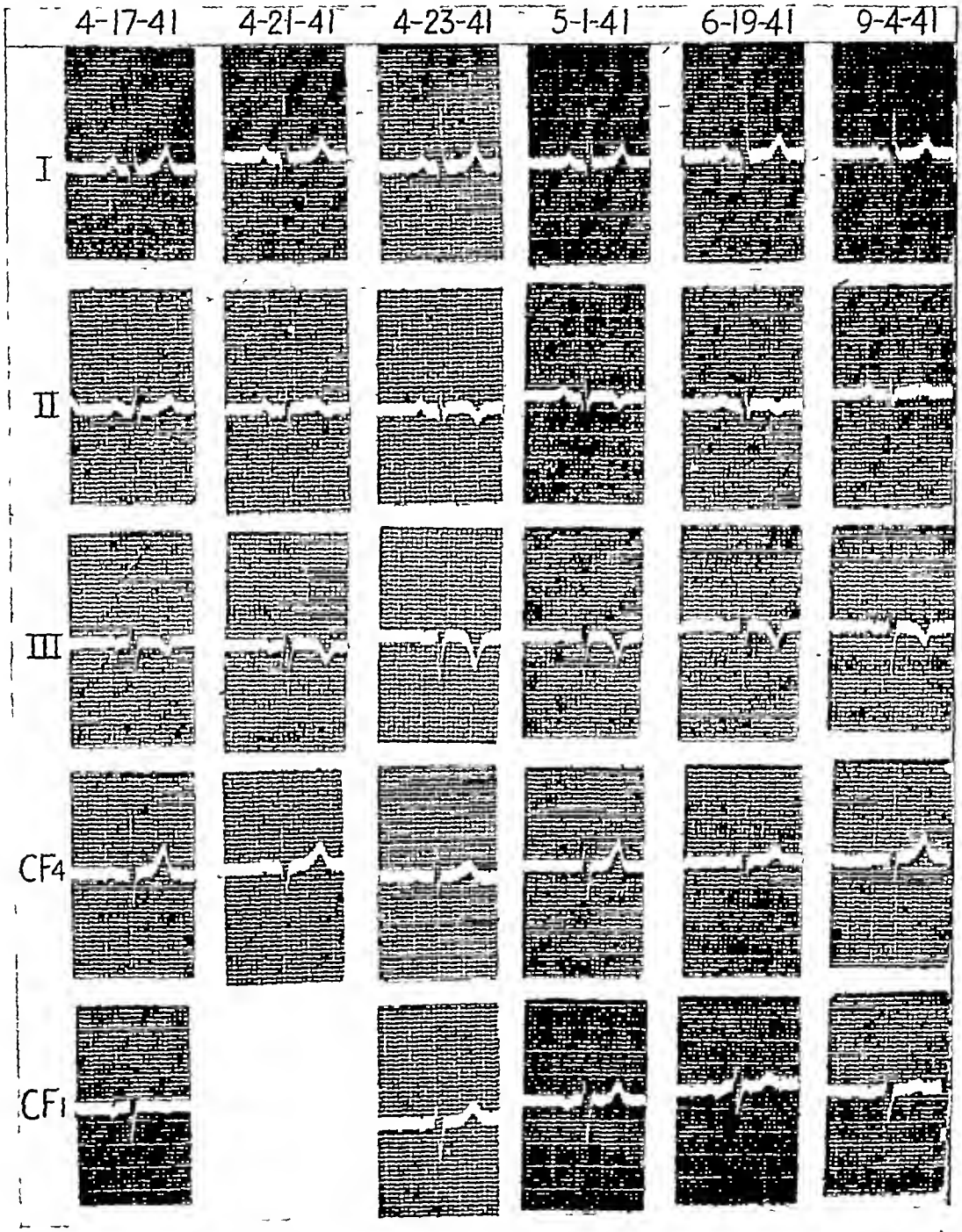

FIG 1 —Cardiograms of a patient who had acute myocardial infarction on April 21, 1941 Serial changes in the limb leads II and III of subsequent tracings conformed to the cardiographic pattern of posterior wall infarction The cardiogram on the day of the attack, April 21, 1941, did not include CF_1 In CF_1, four days before the attack T was inverted, R small, two days after the attack, April 23, 1941, T was upright 2 8 mm, gradually becoming smaller in the tracings on the tenth, fifty-ninth, and one hundred and thirty-sixth day after the attack R was taller after the attack

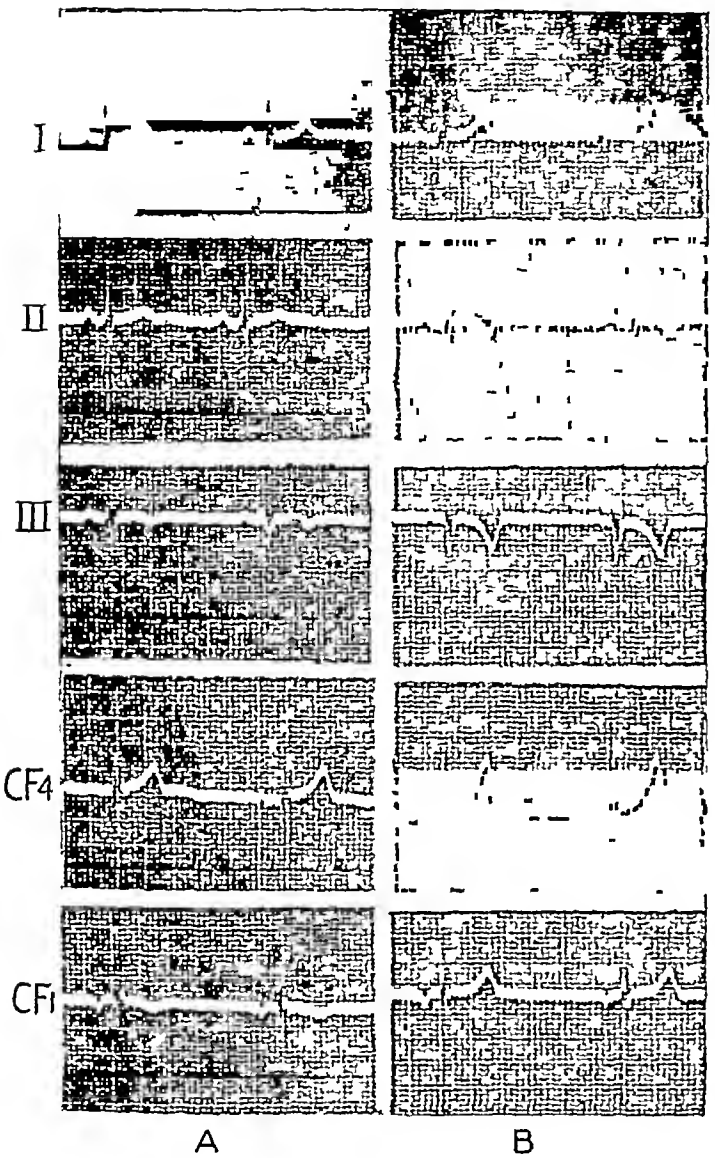

FIG 2 —Cardiograms (A) before and (B) after attack of acute myocardial infarction Serial changes in limb lead II and III and CF_4 conform to the cardiographic pattern of posterior wall infarction In A lead CF_1, R=O and T is inverted, in B lead CF_1, R is upright, 3 8 mm , and T is upright, 4 mm



FIG 3 —Cardiogram showing absent R in CF_1, also inversion of T In 15 cases in the series without heart disease R=O in CF_1, frequently with inversion of the T in this lead.

of use in the diagnosis of recent posterior myocardial infarction It may be particularly helpful where changes in the limb leads especially lead II, are equivocal or absent and also in the evaluation of Q III A negative T wave in CF_1, which occurs in about 70 per cent of normal adult electrocardiograms, would, from the above, be important evidence against the presence of recent infarction of the posterior wall of the heart

SUMMARY AND CONCLUSION

Data on the right præcordial lead CF_1 have been reviewed The characteristics of CF_1 in a group of 265 patients without heart disease have been described

Variations of the T wave, in particular, in CF_1 are described in relation to changes in position of the patient, electrical axis of QRS, presence of a prominent Q III, and in left ventricular strain

In two patients, CF_1 was taken before and after the occurrence of a posterior myocardial infarction and revealed the development of characteristic changes These characteristic changes in CF_1 were found in each one of a series of 35 cases of recent myocardial infarction of the posterior wall The use of lead CF_1 in the diagnosis of posterior wall infarction is discussed

Usefulness of CF_1 has been indicated in (1) locating the side of bundle branch block, with CF_4 or CF_5 (Wilson), (2) evaluation of left ventricular enlargement, particularly from displacement by the diaphragm, (3) possibly of right ventricular enlargement (Wood and Seltzer), and (4) in posterior wall infarction It has also been used for better recording of auricular activity and by Ellis and Brown (1946) as an aid in the diagnosis of tricuspid insufficiency

The information obtained from a right præcordial lead C 1, and in particular CF_1, described above, indicate it to be of sufficient value to recommend its regular use with other præcordial leads in routine electrocardiography for general purposes

REFERENCES

Deeds, D, and Barnes, A (1940) *Amer Heart J*, **20**, 261

Ellis, G M, and Brown, N W (1947) *Ibid*, **32**, 364

Kossman, C E, and Johnston, F D (1935) *Ibid*, **10**, 925

Nomenclature and Criteria for Diagnosis of Disease of the Heart by the Criteria Committee of the New York Heart Association 4th ed (1939) New York

Rosenbaum, F F, Wilson, F N, and Johnston, F D (1946) *Amer Heart J*, **32**, 135

Second Supplementary Report by the Committee of the American Heart Association for the Standardization of Præcordial Leads (1943) *Amer Heart J*, **25**, 535

Shanno, R L (1940) *Ibid*, **19**, 713

Sigler, L H (1944) *The Electrocardiogram* New York

Wilson, F N, Johnston, F D, Rosenbaum, F F, Erlanger, H, Kossman, C E, Hecht, H, Cotrin, N, Menezes de Oliviera, R, Scarsi, R, and Barber, P S (1944) *Amer Heart J*, **27**, 19

Wood, P, and Seltzer, A (1939) *Brit Heart J*, **1**, 49

CORONARY ARTERY ANEURYSM WITH OCCLUSION DUE TO A CALCIFIED THROMBUS

BY

NORMAN ASHTON AND MARY MUNRO

From the Central Pathology Laboratory, Middle East Land Forces, and the British Military Hospital, Cyprus

Received February 12 1948

Case Report

Clinical History In January 1947 a Cypriot officer, 23 years of age, fell unconscious whilst playing football, and was dead when examined by a doctor five minutes later His unit medical officer had known him for five years and stated that, apart from appendicectomy in 1945 and bacillary dysentery and folliculitis of the face and neck in 1946, he had been well and had led a normal active life He had had further trouble with his folliculitis for two weeks before his death and was attending daily for local treatment, but he did not complain in any way about his general health and played football regularly

Post-mortem examination A well encapsulated loculated hydatid cyst, 4 cm in diameter, was situated in the upper part of the right lobe of the liver and the peritoneum covering the cyst was thickened Apart from the findings in the cardiovascular system the other viscera were normal

The left coronary artery, 5 mm from the aortic orifice, contained a pear shaped mass, 1 8 cm long and varying in width from 0 3 to 1 0 cm , which was calcified peripherally to form a cyst-like structure and centrally it consisted of organizing laminated blood clot In this region the artery was dilated and the walls thinned forming a cavity or recess in which the cyst lay with its broader distal end impacted in the narrow lumen beyond There was very little atheroma and the vessel walls showed a few scattered plaques only (Fig 1)

The right coronary artery, about 1 cm from its origin was also dilated locally and there was a small indentation or pocket in the wall where marked atheromatous changes had developed The vessel was patent The myocardium showed softening in the posterior part of the wall of the left ventricle but there was no evidence of old infarction All the valves were normal Unfortunately the specimen was accidentally destroyed before histological preparations could be made There can be no doubt that sudden impaction of the calcified cyst had caused occlusion of the artery and led to death

Discussion

It was at first thought that the calcified cyst might be related to the hydatid cyst of the liver, but a

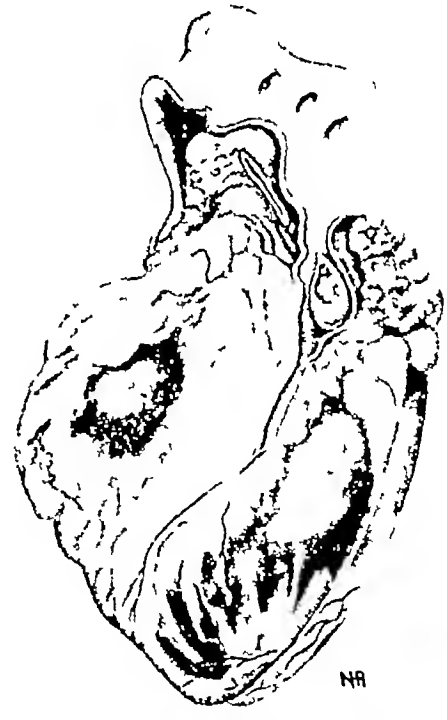

Fig 1 —Diagrammatic drawing of the anterior aspect of the heart The pulmonary artery has been removed and the aorta pulled forward to demonstrate the whole length of the left coronary artery Within 5 mm of the ostium there is an aneurysmal dilatation containing a pear-shaped calcified cystic mass

hydatid seedling would be unlikely to lodge in a large artery, it would be swept on into the smaller capillaries supplying the myocardium A hydatid cyst of the myocardium is rare, a hydatid cyst within a coronary vessel would seem to be an impossibility The germinal epithelium would be found within the cyst but it contained old blood clot only Furthermore the condition of the right coronary artery made it clear that the case was one of bilateral aneurysm Within the left aneurysm a thrombus must have developed and subsequently became partially calcified Monoher (1938) reported a case in which an oval coronary aneurysm arising 3 mm beyond the aortic opening contained laminated clot

Aneurysms of the coronary vessels are well known rarities but we have been unable to discover any other reported instance of sudden death following coronary artery occlusion by a foreign body lying within the lumen of the vessel The first case of coronary aneurysm was reported by Bougon in 1812, and Packard and Wechsler (1929) collected 29 reported cases and added one of their own From an analysis of these cases they concluded that the condition is three times as common in men as in women and that in the vast majority of cases the aneurysm is single and is usually situated on the left coronary artery within 2 5 cm of its ostium Sudden death is common and practically always due to rupture of the aneurysm, gradual heart failure is the cause of death in the others They found no typical symptoms referable to the aneurysm itself, indeed in many cases no complaints of illness were known at the time of their sudden death In a consideration of the ætiology they classified the cases into a mycotic-embolic group, occurring in association with acute or subacute endocarditis of the aortic valve and into an arteriosclerotic group where a marked coronary sclerosis was present Aneurysms due to periarteritis nodosa were carefully excluded from the review Syphilitic mesaortitis was responsible for three cases in the series In the second group they believe that the situation of the aneurysms, immediately beyond the orifice, suggests that arteriosclerosis probably precedes the aneurysmal dilatation, but when one considers the frequency of coronary sclerosis and the rarity of aneurysms, such an ætiology, even with associated hypertension, is difficult to accept Harris (1937) in reporting a case of circoid aneurysm of the right coronary artery advanced a deficiency in the elastic lamella as a probable cause of the dilatation More recently Rigdon and Vandergriff (1943), reviewing reported cases, consider the possible ætiology in young persons may be a solitary arteriosclerosis of the coronary vessels, though they favour congenital anomalies as more probable They instance the work of Forbus (1930) who studied the aneurysms that develop at the point of bifurcation of the medium sized cerebral arteries, and demonstrated defects in the vessel walls, he found similar deficiencies in coronary vessels Rigdon and Vandergriff conclude that coronary aneurysms develop in association with defects in the muscular coats located at either the point of bifurcation or at a point where a branch leaves the parent vessel

In our case there was no evidence of syphilis, mycotic-emboli, or periarteritis nodosa, and it was clear from the advanced calcification of the thrombus that it was older than the early atheroma and it is considered that the latter was rather a resultant than a causative factor In the absence of histological proof the exact ætiology must remain a matter for speculation but we are of the opinion that the bilateral aneurysms were probably due to congenital defects in the vessel walls

Summary

A case of bilateral coronary aneurysm in a man aged 23 is reported Sudden death was due to impaction of a calcified thrombus in the left coronary aneurysm The ætiology is discussed, and reasons are given for regarding it as congenital

We wish to thank Major General F Harris, Director of Medical Services Middle East Land Forces, for permission to publish this case and Brigadier C G Parsons, Consultant in Medicine, for his help and advice

REFERENCES

Bougon, (1812) *Biblioth med*, 37, 183
Forbus, W D (1930) *Johns Hopk Hosp Bull*, 47, 239
Harris, P N (1937) *Amer J Path*, 13, 89
Monoher K O (1938) *Arch Pathol*, 26, 1131
Packard, M, and Weschler, H F (1929) *Arch intern med* 43, 1
Rigdon, R H, and Vandergriff, H (1943) *Amer J Surg*, 41, 407

HEART BLOCK IN OSTEITIS DEFORMANS

BY

C V HARRISON AND BERNARD LENNOX

From the Department of Morbid Anatomy, British Postgraduate Medical School

Received June 1 1948

The simian figure of the country gentleman from the north of England, who was Sir James Paget's first reported case (1877) of osteitis deformans, hobbles still through all accounts of this disease he exemplifies most of the known complications Paget himself learnt little more from the twenty-two other cases he saw (1882, 1889), and since then a forest of at least 700 articles, covering over 2000 cases, has added little wholly new to the original description

The basic problem of the ætiology still eludes us Schmorl (1926, 1930, 1932) has shown the disease to be less rare than Paget thought, and with many others (Higbee and Ellis, 1911, Knaggs, 1926, and Jaffe, 1933, the chief) has extended our knowledge of the morbid anatomy Da Costa *et al* (1915) questioned, and Koller (1946) seems to have refuted, Paget's denial of all hereditary element Packard *et al* (1901) and Knaggs (1926) questioned, but Coley and Sharpe (1931) established beyond question, Paget's claim of a relationship to bone sarcoma Of perhaps more fundamental importance are the demonstrations, by methods not available to Paget, of the high blood phosphatase by Kay (1930) and of the extraordinarily high blood flow through affected bones by Edholm, Howarth, and McMichael (1945)

The interest in the vascular relations of the disease following the latter work encourages us to report two cases of a complication that has so far been overlooked In both cases calcification of the interventricular septum, consequent we believe upon the Paget s disease, interrupted the bundle of His and produced heart block This seems to be no coincidence a recent series (Windholz and Grayson, 1947) of 12 cases of heart block (in all of which septal calcification was demonstrated radiologically) included 2 cases of Paget's disease

Case Notes

Case 1 An unmarried woman of 71 who worked as a chambermaid was admitted under the care of Dr Paul Wood in January 1936 She stated that since youth she had suffered from pains in her legs In 1919, at the age of 54, this pain became much worse and her legs became bowed, and at the same time her left clavicle enlarged She was able to get about with difficulty but continued working for two years, after which she was only able to move with crutches The disease progressed and when admitted in 1936 she was quite unable to get about *On examination* she showed the typical picture of Paget's disease with bowing and thickening of both femora and tibiæ and the right ulna and clavicle There was a hard mass in the connective tissues just lateral to the crest of the left ilium The skull and spine were not deformed Skiagrams confirmed the diagnosis of Paget's disease and showed the subcutaneous mass to be calcarious The blood count was within normal limits, blood calcium was 9 2 mg per 100 ml, blood phosphorus 9 1 mg per 100 ml, and blood phosphatase was 52 King-Armstrong units but later fluctuated between 60 and 70 units The pulse was 80, the B P 175/85 The apex beat was forceful four and a half inches from the midline There was a rough systolic murmur at the apex and a soft systolic murmur at the aortic area She was transferred to the chronic block and about 18 months later began to have attacks of unconsciousness preceded by a sensation of fluttering in the abdomen A cardiogram during these attacks showed complete heart block (Fig 1) with a ventricular rate of 30 and an auricular rate of 120 Between attacks there was right bundle branch block These Stokes-Adams attacks continued intermittently until December 1937 when she died in one

Autopsy was carried out 39 hours after death Advanced Paget's disease was seen in the right femur, tibia, clavicle, pelvis, and sternum There was Paget s disease without significant deformity in the spine There was no apparent disease in the ribs (Fig 2), right fibula, skull, or left clavicle Other bones were not excised In the right clavicle

the disease had progressed to almost ivory-like sclerosis but in all the other affected bones osteoporosis was in advance of sclerosis and the bones were soft and extremely vascular

The mass in the subcutaneous tissues proved to be a focus of amorphous calcification 8×6×3 cm The heart weighed 585 g and showed muscular hypertrophy The coronary arteries were injected

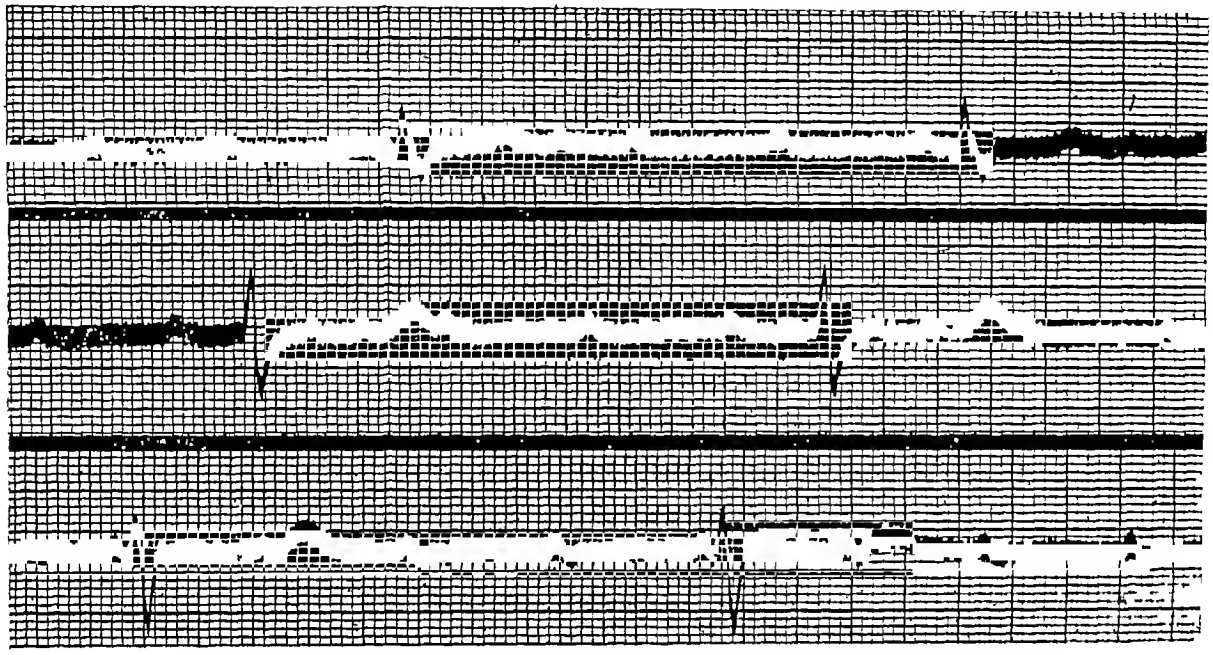

FIG 1 —Case 1 Electrocardiogram during a Stokes-Adams attack

FIG 2 —Case 1 Rib, showing osteoblastic and osteoclastic activity, vascular fibrous marrow, and irregular cement lines Stained with H and E Magnification ×112.

with barium gelatine mixture and skiagrams showed normal lumina At the base of the mitral valve, in the connective tissues at its attachment, there was a bar of calcification extending the length of the posterior cusp and spreading on to the base of the interventricular septum to involve the pars membranacea septi (Fig 3) Apart from this the mitral leaflets were healthy as were those of the other valves

Microscopic section confirmed the gross findings The calcification in the heart was amorphous and was surrounded by fibrosis There was Monckeberg sclerosis in the iliac artery The kidneys did not show hypertensive changes and the degree of cardiac hypertrophy (585 g) remained unexplained In the light of Case 2, one is tempted to suggest that this too may have been an example of high output hypertrophy due to a vascular shunt through bones

Case 2 An old-age pensioner, aged 74, was admitted in October 1947 under Professor

FIG 3 – Case 1 X-ray of the septum after barium gelatine injection of vessels showing the intact blood supply and calcification involving the pars membranacea

FIG 4 —Case 2 X-ray of lower end of femur (post-mortem specimen) showing advanced Paget's disease

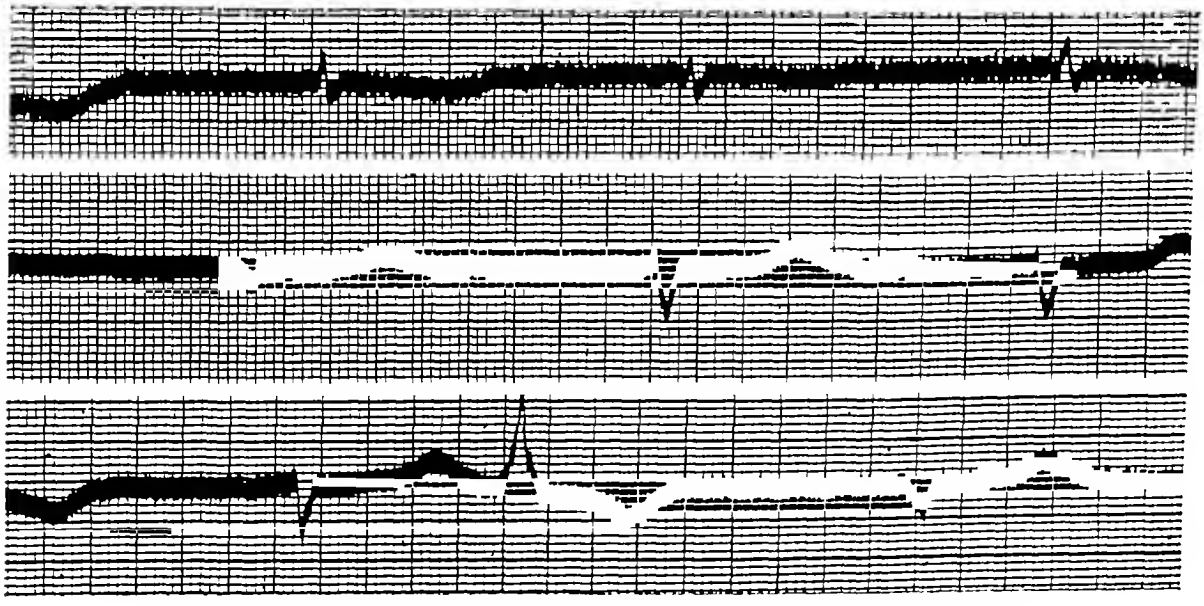

FIG 5 —Case 2 Electrocardiogram showing complete heart block with ectopic beats

J McMichael A known case of Paget's disease for many years he had been bedridden for 2 to 3 years There had been dyspnœa, orthopnœa, and mental changes for three weeks, and œdema for one week *On examination*, there was orthopnœa, widespread œdema, an enlarged tender liver, fluid at the right base, and jugular venous pressure 10 cm above the sternal angle The skeleton showed gross deformity of the skull, limbs, and clavicle radiographs confirmed extensive Paget's disease (Fig 4) and showed also extensive arterial calcification Pulse rate, 34, B P 120/60 Apex beat four and a half inches to left of midline A blowing systolic murmur over whole præcordium A cardiogram (Fig 5) showed complete block with coupled ectopic beats (Dr Paul Wood) Alkaline phosphatase 132 units (King-Armstrong) Blood urea 54 mg , bilirubin 1 5 mg each per 100 ml Cardiac catheterization was only partially successful, but an abnormally high oxygen content of the venous blood, especially in the jugular vein, was demonstrated Treatment of the cardiac failure proved ineffective and he died on Nov 3, 1947, twelve days after admission

Autopsy was carried out 11 hours after death The skeletal changes of Paget's disease were gross and typical, involving the cranium, all bones of the trunk, and all long bones except the fibulæ

Microscopically the bone changes were typical and indicated widespread activity (Fig 6) Vascularity was obvious both macro- and microscopically The heart weighed 435 g there was moderate hypertrophy of both left (1 8 cm) and right (0 7 cm) ventricles The posterior mitral cusp was contracted into a solid calcified ball all cusps of the aortic valve, with both the aortic and the mitral rings, were thickened and patchily calcified the process had extended into the upper posterior two-thirds of the membraneous septum The extent of the lesions is best seen in an X-ray of the specimen (Fig 7) The anterior descending coronary branch was blocked near its origin and the block calcified, but there was no infarct Histological examination of the heart added little to the naked eye findings in the region of the calcification the bundle of His was quite unrecognizable, though Purkinje fibres in the muscular septum appeared healthy There was extensive medial calcification with relatively mild atheroma in arteries everywhere (Fig 8) Findings in other systems included cystitis and an old pyelonephritic atrophy of the right kidney (55 g), calcification of the right cupola of the diaphragm, and an old collapse of the lower lobe of the right lung The thyroid, pituitary, and adrenals were normal The parathyroids were of average size but showed an almost complete absence of oxyphile cells



Fig 6 —Case 2 Rib showing active Paget s disease Stained with H and E Magnification 112

Discussion

Calcification of the heart valves and rings, though often described, has not been shown to be significantly commoner in Paget's disease than in controls of the same age We have, therefore, collected some data on this point

Our departmental records contain 13 cases of generalized Paget's disease Six of their hearts showed valvular calcification (see Table I) To this we have added 30 reported cases Adequately detailed accounts are rare most articles are purely clinical (including nearly all the larger series—Gutman and Kasabach, 1936, Newman, 1946, Kay *et al*, 1934, Sugarbaker, 1940, O'Reilly and Race, 1932, Looser, 1926, and others (especially Schmorl) deal only with the bones A search of 170 of the readily available articles,

FIG 7 —Case 2 X-ray of a transverse slice of the heart containing the valves, showing irregular calcification involving especially the posterior part of the mitral ring and extending on to the membranous septum

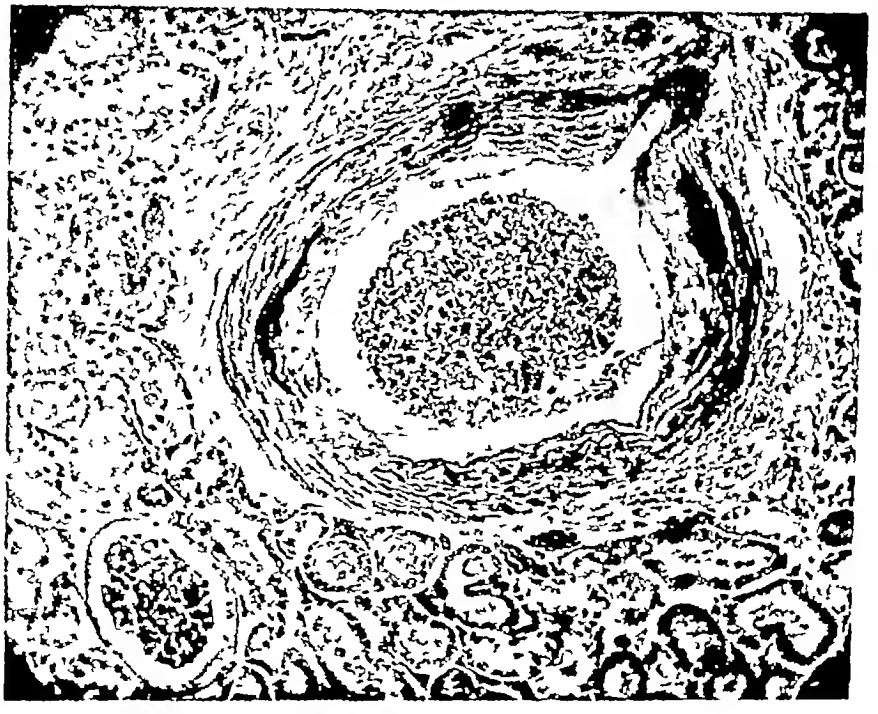

FIG 8 —Case 2 Left kidney, showing medial calcification in a small artery Stained with H and E Magnification × 112

covering some 820 cases, has yielded only 30 autopsied cases in which the disease was generalized, the diagnosis clear, and the heart either described or reasonably to be assumed normal, several of these showed calcification (Table II) Combining our 13 with the 30 reported cases of Paget's disease we find that 17 out of the 43 (39 per cent) showed valvular calcification In a control series of 223 autopsies of similar age distribution from our departmental records 17 showed valvular calcification (8 per cent) A more detailed analysis of these figures is shown in Fig 9, which also gives the figures for non-calcarious valvular sclerosis

The two tables give details of the cases from which Fig 9A was constructed The eleven cases in Table I make, with the 2 already described, a total of 13 seen in twelve years at this hospital among 4300 autopsies (0 3 per cent) No special search for the disease had been made during this time and all the cases listed were extensive and unmistakeable cases with small and doubtful lesions have not been included It may be mentioned in passing that the absence of oxyphile cells in otherwise normal parathyroids, noted by Davie and Cooke (1937), has been confirmed in four cases of five examined

In all those cases in Table II where calcification of valves has not been specifically noted it has been assumed absent but in several of the older cases (e g Goodhart's and Silcock's) the wording leaves some room for doubt

Two conclusions can be drawn from this comparison Cardiac calcification is about five times as common in Paget's disease as in controls, and the total incidence of valve disease is about the same (the difference between the two sets of figures is statistically significant but in view of the mixed nature of our data this is perhaps not to be relied on) The implication of this is that whilst collagenous sclerosis of the heart valves is fairly common in old people, those with Paget's disease have an exaggerated tendency to calcify Necrotic tissue or hyaline collagen have a natural tendency to calcify possibly because of their low CO_2 tension but in Paget's disease there is evidence of an additional factor in the form of an unduly labile calcium metabolism Wells and Holley (1942) recorded a case of Paget's disease in which heavy doses of Vitamin D produced fulminating metastatic calcification, and Seligman and Nathanson (1945) recorded a similar but slower result following relatively small doses Furthermore, Reifenstein and Albright (1944) recorded two cases of Paget's disease in which immobilization by fracture combined with an ordinary hospital milk diet produced a dangerous elevation of blood calcium This last observation

TABLE I

PERSONAL CASES OF OSTEITIS DEFORMANS

No	Sex and Age	Bone changes	Cause of death	Weight of heart (g)	Valve lesions	Arterial calcification noted
3	F, 56	Generalized	Carc rectum	Normal	—	—
4	F, 60	Generalized	Renal calculi	235	—	—
5	M, 65	Pelvis only	Fracture of spine	340	—	—
6	M, 67	Generalized	Staphylococcal endocarditis	600	Fibrous thickening of posterior cusp of mitral valve, with large recent vegetations	Aorta
7	M, 68	Generalized	Paraplegia (due to Paget's disease of vertebræ)	400	One aortic cusp calcified	—
8	M, 70	Generalized	Multicentric tumour and high output heart failure	475	Calcified aortic ring	Aorta
9	F, 70	Generalized	Meningioma	300	—	Aorta
10	F, 71	Long bones of legs only	Carc bladder	185	(Brown atrophy)	—
11	M, 75	Generalized	Carc rectum	335	Calcified aortic ring	Posterior tibials
12	M, 83	Skull and vertebra only	Coronary thrombosis terminal femoral artery thrombosis with gangrene	410	—	Aorta
13	M, 86	Generalized	Urethral stricture	350	Aortic and mitral rings and aortic cusps calcified	Aorta

TABLE II
REPORTED CASES OF OSTEITIS DEFORMANS

Author	Sex and Age	Cause of death	Valve lesions
Davie and Cooke, 1937 (II)	M, 42	Multiple sarcomata	—
Gilles *et al*, 1894	M, 49	Unexplained heart failure	—
von Albertini, 1928	M, 51	Sarcoma of femur	—
Askanazy, 1904	F, 51	Multiple fractures	"Whitish thickening of single valve cusps"
Robinson, 1886	M, 52	Cerebellar tumour	—
Bartlett, 1910	F, 53	Broncho-pneumonia	Slight thickening of mitral cusps
Gruner, *et al*, 1912	M, 56	Sarcoma of humerus	—
Ely, 1923	M, 57	Gallstones and cholangitis	—
Wells and Holley, 1942	M, 59	Metastatic calcification	Calcification of aortic and mitral valves, septum and atrial endocardium
Wilks, 1869	M, 60	Cor pulmonale and pericarditis	—
Goodhart, 1877	F, 60	Multiple sarcomata	"Pulmonary valves were thick and aortic valves had a few vegetations on them"
Packard *et al*, 1901	M, 62	Sarcoma of skull	—
Levi, 1897	F, 62	Heart failure	Thickened mitral and tricuspid valves, calcified aortic valve
Higbee and Ellis, 1911	M, 63	Heart failure	Calcified aortic and mitral valve and septum
Robin, 1894	M, 64	Heart failure	"Mitral insufficiency"
Clegg, 1937	M, 64	Heart failure	Calcification of aortic and mitral valves
Davie and Cooke, 1937 (I)	F, 64	Sarcoma of tibia	—
Cayley, 1877	M, 65	Carcinoma of lung	Calcification of aortic and mitral valves
Jamieson, 1897 (II)	M, 65	Heart failure	Calcification of aortic cusps
Paget, 1877 (I)	M, 68	Sarcoma of radius	Calcification of mitral valve
Lunn, 1887	M, 68	Bulbar palsy	Thickening of mitral valve
Stilling, 1890 (II)	F, 70	?	—
Miller, 1943	F, 73	Meningioma	—
Jamieson, 1897 (I)	F, 73	Gangrenous leg ulcer	Calcification of aortic cusps
Hudelo and Heitz, 1901	M, 75	Pericarditis	—
Stilling, 1890 (I)	M, 77	Emphysema and cor pulmonale	—
Smith, 1928 (I)	F, 81	Heart failure following fracture of hip	Calcification of aortic and mitral valves
Silcock, 1884	F, 84	Strangulated hernia	"Chronic degenerative changes"
Cone, 1922	M, 85	Papilloma of bladder with stone	Calcification of aortic and mitral valves
Stilling, 1890 (III)	F, 92	?	Calcification of aortic cusps

suggests that when Paget's disease is sufficiently crippling to immobilize the patient the risk of metastatic calcification is enhanced—a factor that was present in both of our cases It seems to us probable that the presence of calcification in the fibrous tissue at the base of the valves may well excite further fibrosis in the neighbourhood and thus become a progressive lesion This would explain the extension of the process to the membranous septum and justify us in regarding the heart block as a true complication of Paget s disease and not a mere coincidental calcification in a patient with heart block due (a well recognized occurrence) to simple fibrosis We hope that by drawing attention to these cases we may stimulate a further study that will confirm or refute this

THE VASCULAR SYSTEM IN PAGET'S DISEASE

Vascular disease is extremely frequent in Paget's disease Any collection of case histories makes this obvious—Kay *et al's* especially well The vascular lesions have been supposed responsible for the bone disease Leri (1926) believes the lesions of the nutrient arteries to be responsible, Cone (1933) regards the lesion as a sort of chronic venous congestion of bone But many of the younger cases show Paget's disease without any vascular lesion (e g our Cases 3 to 5 in Table I) and clinically it has often been clearly demonstrated that the heart lesion develops long after the bone lesion (Paget's first case, for instance, also those of Haguenau *et al*, 1934, and of Thibierge 1893)

The assaults of Paget's disease on the heart and

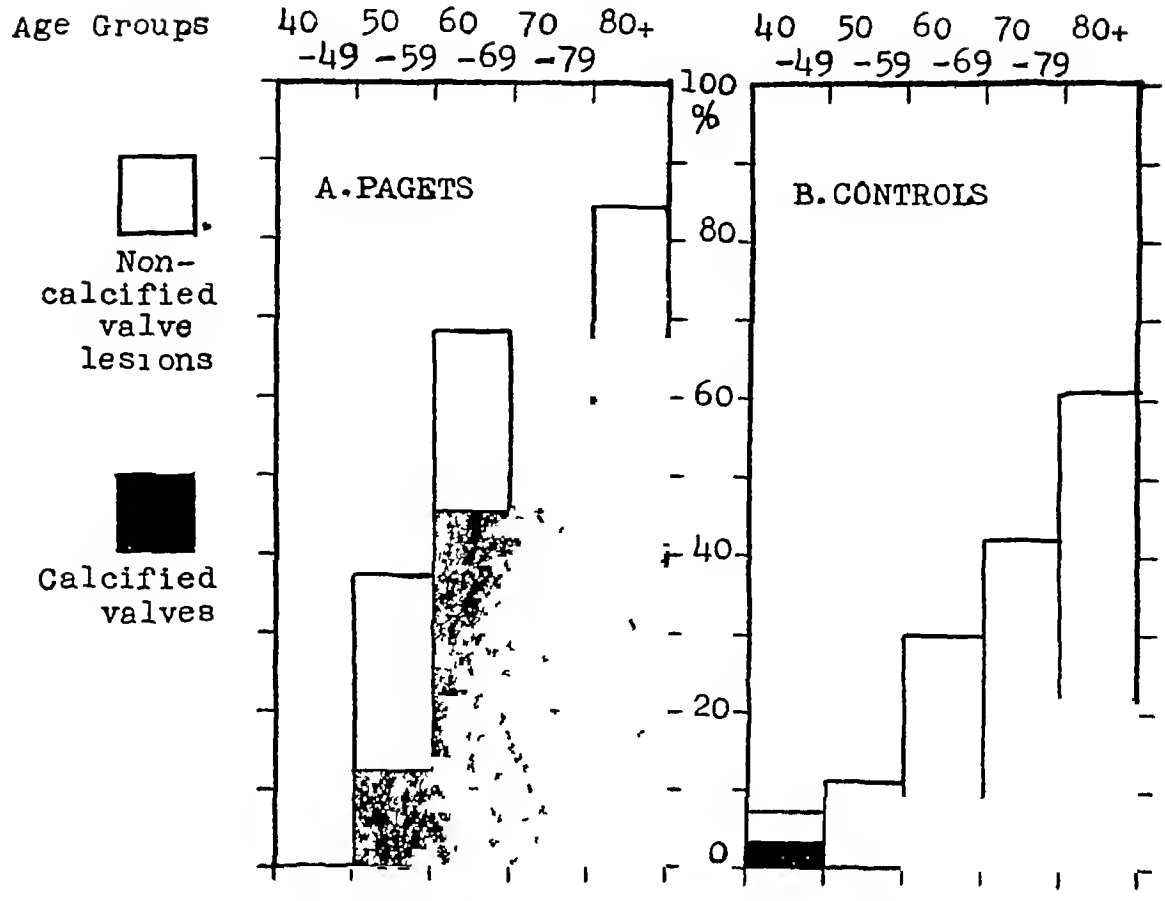

	A. Paget's					B. Controls				
No. of cases	2	8	16	11	6	27	53	73	52	18
Cases with any valve lesion	0	3	11	5	5	2	6	22	22	11
Cases with calcification	0	1	7	5	4	1	0	7	5	4

FIG 9 —The histograms show the percentage incidence by age groups of calcarious and non-calcarious valve lesions in 43 cases of Paget's disease and 223 controls The actual number of cases is given below

vessels are various indeed it is surprising that so many patients reach extreme old age We believe the principal damaging factors to be as follows

(a) *High cardiac output* caused by the shunt through the very vascular bones, implicit in the observations of Redman (1889) on the pulse and of Klippel and Weil (1911) on localized hyperthermia over affected bones, but first clearly demonstrated by Edholm *et al* (1945)

(b) *Arterial calcification*, as first demonstrated radiologically by Beclère in 1901 O'Reilly and Race (1932) found it in 43 per cent of their cases and although they give no control figures they were satisfied that this represents a significant increase above what might be expected in patients of the same age The finding has been commonly called " arteriosclerosis " and might be supposed to consist of either Monckeberg's sclerosis or calcarious atheroma Since, however, occlusive vascular disease is certainly not unduly frequent in Paget's disease (there is only one certain arteriosclerotic gangrene in our 820 collected cases and no coronary death in our 43 autopsies) it seems reasonable to assume that the increased incidence of radiological shadows is due to Monckeberg's sclerosis

(c) *Thoracic deformity* producing cor pulmonale This is surprisingly rare, though one of the earliest cases (Wilks, 1869—which is also Paget's Case 4 of 1877) died in this way, and perhaps also Stilling s Case 1 (1890)

(d) *Valve calcifications* discussed in this paper

(e) *Heart block* This is perhaps not so rare as

the lack of reported cases would indicate Cases of Paget's disease in time join the chronic sick and, though they may be studied well at some stage of their progress, they do not usually die under supervision unless they have a sarcoma or some such dramatic lesion Heart block in a heart already embarrassed by a high output and calcified valves is probably rapidly fatal there are quite a number of unexplained heart failures among published cases (Clegg, 1937, Higbee and Ellis, 1911, and S Paget, 1884) which it is tempting to think may have been fatal Stokes-Adams attacks With increasing interest in the causes of death in old people more cases may well come to light

SUMMARY

Two cases of osteitis deformans are reported in which calcification of the membranous interventricular septum caused complete heart block

A survey of published papers has revealed only two similar cases but there are reasons for suggesting that this complication may be more frequent than this indicates

In 30 published and 11 further personal cases of Paget's disease, calcification in the heart was found to be significantly commoner than in a control series

Our thanks are due to Professor J McMichael and Dr Paul Wood for much help with the clinical aspects of these cases, and to Mr J R Baker and Mr J Griffin for the sections and Mr E V Willmott for the photographs used in illustration

REFERENCES

Askanazy, M (1904) *Arb Geb Path Anat Tübingen*, **4**, 398
Bartlett, C J (1910) *Yale med J*, **16**, 367
Cayley, W (1877) *Trans Path Soc*, **29**, 172
Clegg, J L (1937) *Lancet*, **2**, 128
Coley, B L, and Sharp, G S (1931) *Arch Surg Chicago*, **23**, 918
Cone, S M (1922) *J Bone Jt Surg*, **4**, 751
—— (1935) *Ibid*, **15**, 190
Da Costa, J C, Funk, E H, Bergeim, O, and Hawk, P B (1915) *Pub Jefferson Med Coll Hosp*, **6**, 1
Davie, T B, and Cooke, W E (1937) *Brit J Surg*, **25**, 299
Edholm, O G, Howarth, S, and McMichael, J (1945) *Clin Sci*, **5**, 249
Ely, L W (1923) *Arch Surg Chicago*, **7**, 532
Gilles de la Tourette, and Magdelaine, L (1894) *Bull Mem Soc med Hôp Paris*, **7**, 1
Goodhart, J F (1877) *Trans Path Soc*, **29**, 175
Gruner, O C, Scrimger, F A C, and Foster, L S (1912) *Arch intern Med*, **9**, 641
Gutman, A B, and Kasabach, H (1936) *Amer J med Sci*, **191**, 361
Haguenau, J, Gully, L, and Daum, —, (1934) *Bull Mem Soc med Hôp Paris*, **43**, 931
Higbee, W S, and Ellis, A G (1911) *J med Res*, **24**, 43
Hudelo, L, and Heitz, J (1901) *Nouv iconog Saltpet*, **14**, 415
Jaffe, H L (1933) *Arch Pathol*, **15**, 83
Jamieson, S (1897) *Aust med Gaz*, **16**, 14
Karsner, H T, and Koletsky, S (1947) *Calcific Disease of the Aortic Valve*, Philadelphia
Kay, H D (1930) *J biol Chem*, **89**, 249
——, Simpson, S L, and Riddoch, G (1934) *Arch intern Med*, **53**, 208
Klippel, —, and Weil, — (1908) *Rev Neurol*, **16**, 1228
Knaggs, R L (1926) *Brit J Surg*, **13**, 206
Koller, F (1946) *Helv med act*, **13**, 389
Léri, A *Les affections des os et des articulations* Paris 1926 (quoted by O'Reilly and Race, 1932)
Levi, L (1897) *Nouv iconog Saltpet*, **10**, 113
Looser, E (1926) *Schwelz med Wschr*, **7**, 598
Lunn, J R, (1887) *Trans Path Soc*, **39**, 265 (repeated in *Ill Med News*, **2**, 182, 1889)
Miller, J (1943) *Canad med Ass J*, **49**, 13
Moehlig, R C, and Adler, S (1937) *Surg Gynec & Obstet*, **64**, 737
Newman, F W (1946) *J Bone Jt Surg*, **28**, 798
O'Reilly, J J, and Race, J (1932) *Quart J Med*, **25**, 471
Packard, F A, Steele, J D, and Kirkbride, T S (1901) *Trans Ass Amer Phys*, **16**, 666
Paget, J (1877) *Med chir Trans*, **60**, 37
—— (1882) *Ibid*, **65**, 225 (repeated in *Med Class*, **1**, 29, 1936)
—— (1889) *Ill Med News*, **2**, 181
Paget, S (1884) *Trans Path Soc*, **36**, 382
Redman, W E (1889) *Ill Med News*, **2**, 189
Reifenstein, E C, Jr, and Albright, F (1944) *New Engl J Med*, **70**, 295
Robin, A (1894) *Nouv Iconog Saltpet*, **7**, 15
Robinson, A H (1886) *Trans Path Soc*, **38**, 262 (repeated *Lancet*, **1**, 826, 1887)
Schmorl, G (1926) *Verh dtsch path Gesh*, **21**, 71
—— (1930) *Ibid*, **25**, 205
—— (1932) *Virchows Arch*, **283**, 694
Seligman, B, and Nathanson, L (1945) *Ann intern Med*, **23**, 82
Silcock, A Q (1884) *Trans Path Soc*, **36**, 383 (repeated *Brit med J*, **1**, 595, 1885, and *Lancet*, **1**, 519, 1885)
Smith, L H (1928) *J Nerv ment Dis*, **68**, 578
Stilling, H (1890) *Virchows Arch*, **119**, 542.
Sugarbaker, E D (1940) *Amer J Surg*, **48**, 414
Thibierge, — (1893) *Bull Mem Soc méd Hôp Paris*, *3rd S*, **10**, 116
von Albertini, A (1928) *Virchows Arch*, **268**, 259
Wells, H G, and Holley, S W (1942) *Arch Pathol*, **34**, 435
Wilks, S (1869) *Trans Path Soc*, **20**, 273
Windholz, F, and Grayson, C (1947) *Amer J Roentgen*, **58**, 411

VENTRICULAR COMPLEXES IN HEART BLOCK

BY

H B KAY*

From the National Heart Hospital

Received February 3 1948

In electrocardiograms of complete A-V block, the ventricular complexes may be of normal supraventricular type, of typical bundle branch block (B B block) type or may exhibit lesser degrees of widening and notching of QRS and T wave changes The association of B B block with complete A-V block is recognized as common Campbell (1944) found B B block in 19 of 64 cases of complete block Similar findings have been recorded by White and Viko (1923) who found evidence of intraventricular block in 15 out of 27 cases of complete heart block, and by Fatzer (1946) who described intraventricular block in 60 per cent of cases, Mouquin and Macrez (1947) in a series of 124 cases of complete heart block, found normal ventricular complexes in only 25 instances Graybiel and Sprague (1933) record 17 cases of complete A-V block in 395 cases of B B block and Freund and Sokolov (1939) found complete A-V block in 5 per cent of 210 cases of B B block It is also recognized that the form of QRS during complete A-V block may differ from that recorded during sinus rhythm in the same case

For purposes of investigating the form of the ventricular complexes, a series of 100 cases of complete A-V block has been assembled, comprising patients seen at the National Heart Hospital during the last few years, and others seen at the Middlesex Hospital or in practice by Dr Evan Bedford, at whose suggestion this investigation was undertaken The cases were unselected and as far as possible consecutive from both sources Fifteen patients have been under personal observation during the past year

ÆTIOLOGY

The ætiology of the heart block in this series of 100 cases is shown in Table I

The cases of uncertain ætiology included five patients with a history of "heart trouble in childhood, six with a history of rheumatic fever but without clinical evidence of rheumatic valvulitis four in whom there was a possible cardiac infarction two with a family history of complete heart block and two in whom the block followed surgical operation

TABLE I

ÆTIOLOGY AND SEX INCIDENCE

	Number of cases	Male	Female
Coronary heart disease			
(a) Chronic	43	30	13
(b) Associated with recent cardiac infarction	9	8	1
Congenital	20	9	11
Rheumatic heart disease	3	2	1
Diphtheric heart disease	2	1	1
Syphilis	1	1	—
Pneumonia	1	1	—
Associated with neurological disease	2	2	—
Ætiology uncertain	19	7	12
Total	100	61	39

* Nuffield Foundation Fellow, National Heart Hospital

There were eight cases in which complete A-V block was transient In seven of them there was associated coronary heart disease, one having recent cardiac infarction, and the other case was of doubtful ætiology In only two of these cases was the P–R interval prolonged during the phase of sinus rhythm

The Ventricular Complexes

The ventricular complexes have been classified into three groups (1) Supraventricular pattern (2) Bundle branch block pattern (3) Varying complexes

(1) Supraventricular Pattern

Ventricular complexes of normal duration, 0 06–0 10 sec, and with normal S–T and T segments, including cases in which axis deviation was the only abnormality, occurred in 47 of the 100 cases Of these 47 cases, 19 were congenital, 11 had coronary heart disease, 4 followed rheumatic fever or diphtheria, 1 was associated with neurological disease, 1 followed pneumonia, and 11 were of doubtful ætiology, of this latter group, 5 had a previous history of rheumatic fever and 4 gave a history of heart trouble in early life Fig 1 shows the electrocardiograms of two cases of congenital A-V block, with QRS–T complexes of supraventricular pattern

In addition, in 6 patients with coronary heart disease, the electrocardiograms showed left ventricular preponderance, with QRS complexes of normal duration Four of them had associated hypertension with systolic blood pressure greater than 200 mm, the blood pressure in the other cases being 170/90 and 180/70 mm of mercury

The pulse rate in these cases with normal ventricular complexes varied between 25 and 60 a minute As shown in Table II, in most of them the rate was relatively high, between 36 and 60 a minute, especially in the cases of congenital heart block, whereas in cases with widened ventricular complexes the rate was slower, between 26 and 40 a minute The readings recorded in Table II are the average pulse rates, but in individual patients the rate actually varied when observed over a period, for instance, with an average rate of 30 beats a minute, the rates actually recorded varied between 26 and 34

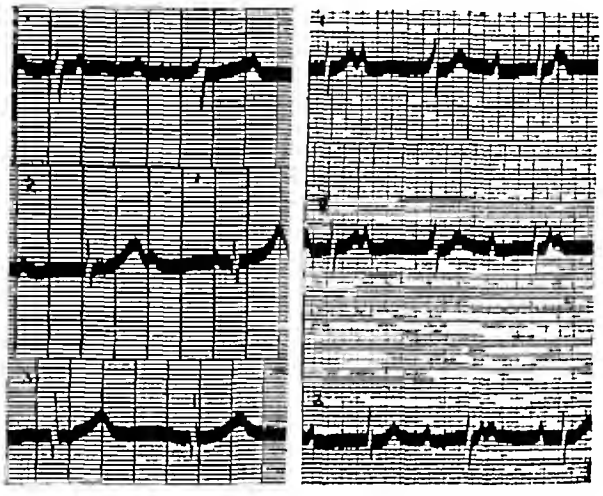

A B

Fig 1 —Complete A-V block with normal QRS complexes
(A) From a baby six days old, ventricular rate 75 a minute
(B) From a man aged 18 years, ventricular rate 42 a minute

The ventricular complexes of complete heart block are usually of supraventricular pattern when the pacemaker is situated in the main bundle and the bundle branches function normally This is the rule in congenital heart block, and all but one of the 20 cases in this series classed as congenital showed normal QRS complexes, whereas in the cases with coronary heart disease normal QRS complexes occurred in only one-third

Supraventricular QRS complexes may also occur in complete heart block due to lesions of both

TABLE II
Average Pulse Rate

Pulse rate per minute	21–25	26–30	31–35	36–40	41–45	46–50	51–55	56–60
Congenital								
Normal complexes	—	1	1	—	5	4	6	2
Widened complexes	—	—	—	—	1	—	—	—
Coronary heart disease (chronic)								
Normal complexes	1	—	—	3	4	4	0	3
Widened complexes	2	5	7	7	2	5	0	1
Total cases								
Normal complexes	1	3	3	8	15	9	7	7
Widened complexes	3	8	13	14	3	5	—	1

bundle branches (illustrated schematically in Fig 5A) Wilson and Hermann (1921) found that, in experimental section of both bundle branches, the ventricular complexes might be of the form indicating a right-sided pacemaker, of the form indicating a left-sided pacemaker, or might be of relatively normal outline To explain the occurrence of relatively normal QRS complexes, they postulated the existence of two pacemakers, one in each bundle branch, acting synchronously, the summation of a lævocardiogram and dextrocardiogram resulting in a ventricular complex of normal outline and duration In support of this view is the fact that cardiograms showing a change in site of the pacemaker from one side to the other also show transitional forms of QRS complex resembling the normal supraventricular pattern Cases of complete heart block in which these changes were demonstrated have been reported by Gilchrist and Cohn (1928), and by Bain (1941)

As an alternative explanation, Yater (1936) believes that there is probably a single pacemaker in one or the other bundle branch, sending impulses directly through the interventricular septum into the Purkinje network of the contralateral, as well as into that of the homolateral ventricle

Mahaim (1931) and Yater (1936) describe cases of complete A-V block in which detailed histological examination of the conducting system showed lesions confined to the bundle branches, and a normal appearance of the A-V node and the main bundle According to Mahaim (1932), the two branches of the bundle of His are not isolated in their course along the interventricular septum, but are connected by branches as high as the top level of the musculature The common trunk of the bundle of His is likewise connected with the ventricular myocardium Because of these high connections, auriculo-ventricular conduction may be normal in spite of destruction of the branches—" bilateral missed block "

In interpreting electrocardiograms of complete A-V block exhibiting QRS complexes of supraventricular pattern, the following points may be considered in favour of bilateral B B block as the underlying mechanism (a) heart disease of coronary ætiology, (b) a relatively slow inherent rate of the pacemaker, (c) the association of supraventricular QRS complexes with those of widened type, or the occurrence of periods of sinus rhythm with B B block, especially when the ventricular complexes alternate between right and left branch block

In two cases of this group widened QRS complexes changed to QRS of normal duration, without any alteration in the pulse rate, which was slow, namely 30 to 36 a minute in both cases (Fig 2)

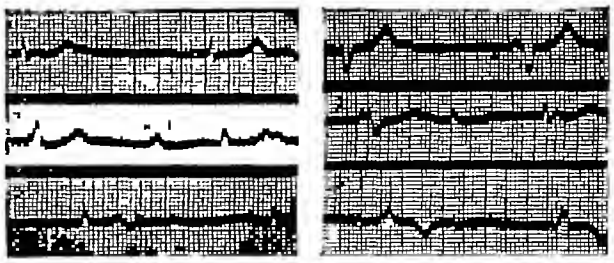

A B

FIG 2 —Complete A-V block with variation in QRS complexes in a man aged 51
(A) On 24/8/42 shows QRS complexes of normal duration, rate 36 a minute
(B) On 27/8/42 shows widened QRS complexes, rate 34 a minute

In another case with widened QRS complexes, the pulse rate was 28 a minute, but increased to 40 a minute when the QRS complexes became normal in duration

(2) VENTRICULAR COMPLEXES OF BUNDLE BRANCH BLOCK PATTERN

The B B block pattern of ventricular complex is characterized by axis deviation, widening of the QRS, and T waves directed oppositely to the main deflection of QRS Wilson *et al* (1944) consider that when QRS has a duration of 0 12 sec or more and, in lead I, is monophasic and consists of a broad, slurred, flat-topped or bifid R deflection, the præcordial curves almost always show left B B block But when QRS is similarly widened and, in lead I, is biphasic or triphasic and tends to a broad slurred or notched S deflection, the præcordial curves are mainly characteristic of right B B block The occasional exceptions to this general rule may be due to (a) a vertical position of heart, when limb leads suggest right B B block and præcordial leads left B B block, and vice versa, (b) arborization block, most often seen with extensive myocardial infarction, and due to general depression of conductivity of Purkinje tissue or to local lesions involving the subendocardial Purkinje network over a considerable area In some cases there is no obvious relation between the form of QRS in præcordial leads and that in limb leads, in these the position of the heart must be classed as indeterminate

In the present series, 47 per cent of cases showed widened ventricular complexes, with a QRS interval of 0 12 seconds or more, in the presence of complete heart block (see Table III) In the earlier cases, præcordial leads were not available to confirm the type of B B block

(a) In 29 cases the ventricular complexes were of

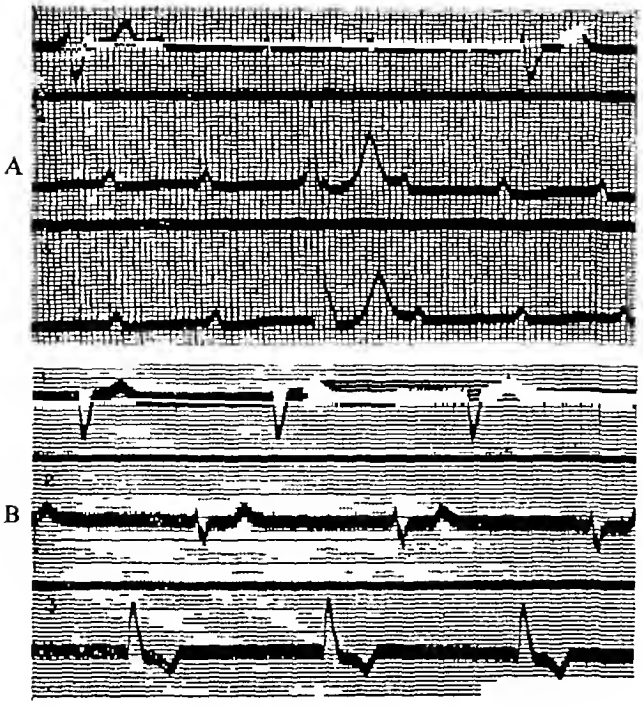

FIG 3—Complete A-V block with widened QRS complexes
(A) QRS complexes 0 14 sec duration and of right B B block pattern (Wilson type)
(B) QRS complexes 0 14 sec duration and of right B B block pattern

right B B block type, 23 being of the Wilson or S type, and 6 of the uncommon type (Fig 3) Of these, 20 had coronary heart disease, 5 had associated cardiac infarction, 1 was in association with neurological disease, and 3 were of doubtful ætiology

TABLE III

THE TYPE OF VENTRICULAR COMPLEX IN CASES WITH WIDENED QRS

Right bundle branch block	(a) S type	23
	(b) Uncommon type	6
Left bundle branch block	Common type	6
Concordant pattern		2
Both right and left bundle branch block		4
Varying complexes		6
	Total	47

(b) In 6 cases the ventricular complexes were of left B B block type Of these, 3 had coronary heart disease, 1 had congenital heart block, 1 was associated with rheumatic aortic and mitral valvular disease as confirmed by necropsy, and 1 was of doubtful ætiology

(c) In 2 cases the ventricular complexes were of the concordant type, one of the common and one of the uncommon type No præcordial leads had

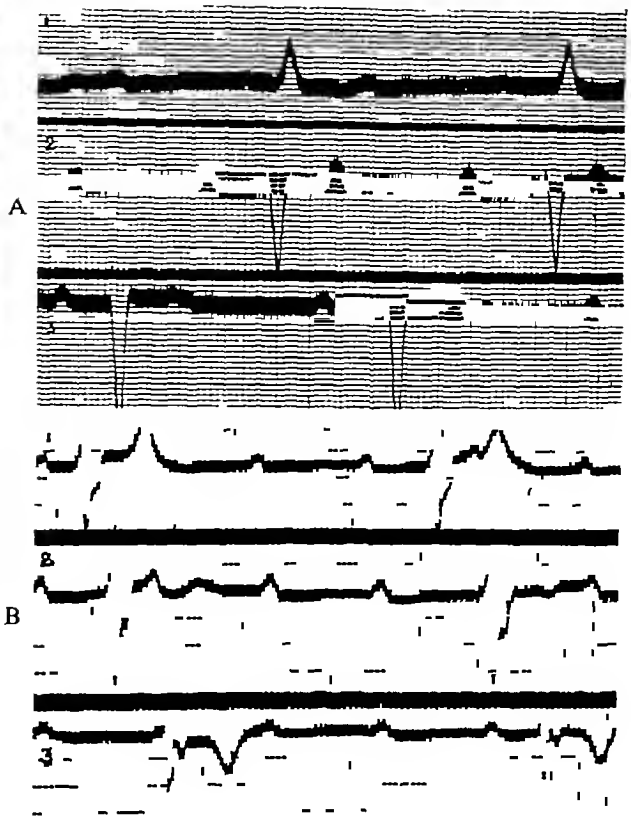

FIG 4—Complete A-V block with variation of QRS complexes in a man aged 71
(A) On 27/7/42 the complexes were of left B B block pattern
(B) On 3/9/42 they were of concordant right B B block pattern

been recorded, so that further elucidation of the block was impossible

(d) In 4 cases, observed for periods of 1–5 years the site of the pacemaker varied between left and right ventricle Of these, one had coronary heart disease and the others were of uncertain ætiology An example of the cardiograms in this group is given in Fig 4, which shows (a) QRS complexes of left B B block pattern, rate 34 a minute, and (b), four weeks later, QRS complexes of concordant right B B block pattern rate 25 a minute

(e) Finally, in 6 cases, the widened ventricular complexes assumed varying patterns in the same tracings

THE RELATION OF BUNDLE BRANCH BLOCK TO COMPLETE A-V BLOCK

The original interpretation of the B B block pattern of QRS, based on experiments in dogs, has in recent years been reversed, largely by the work of Wilson and his associates Histological investigation of the bundle system in diseased hearts has failed to supply convincing proof of either the

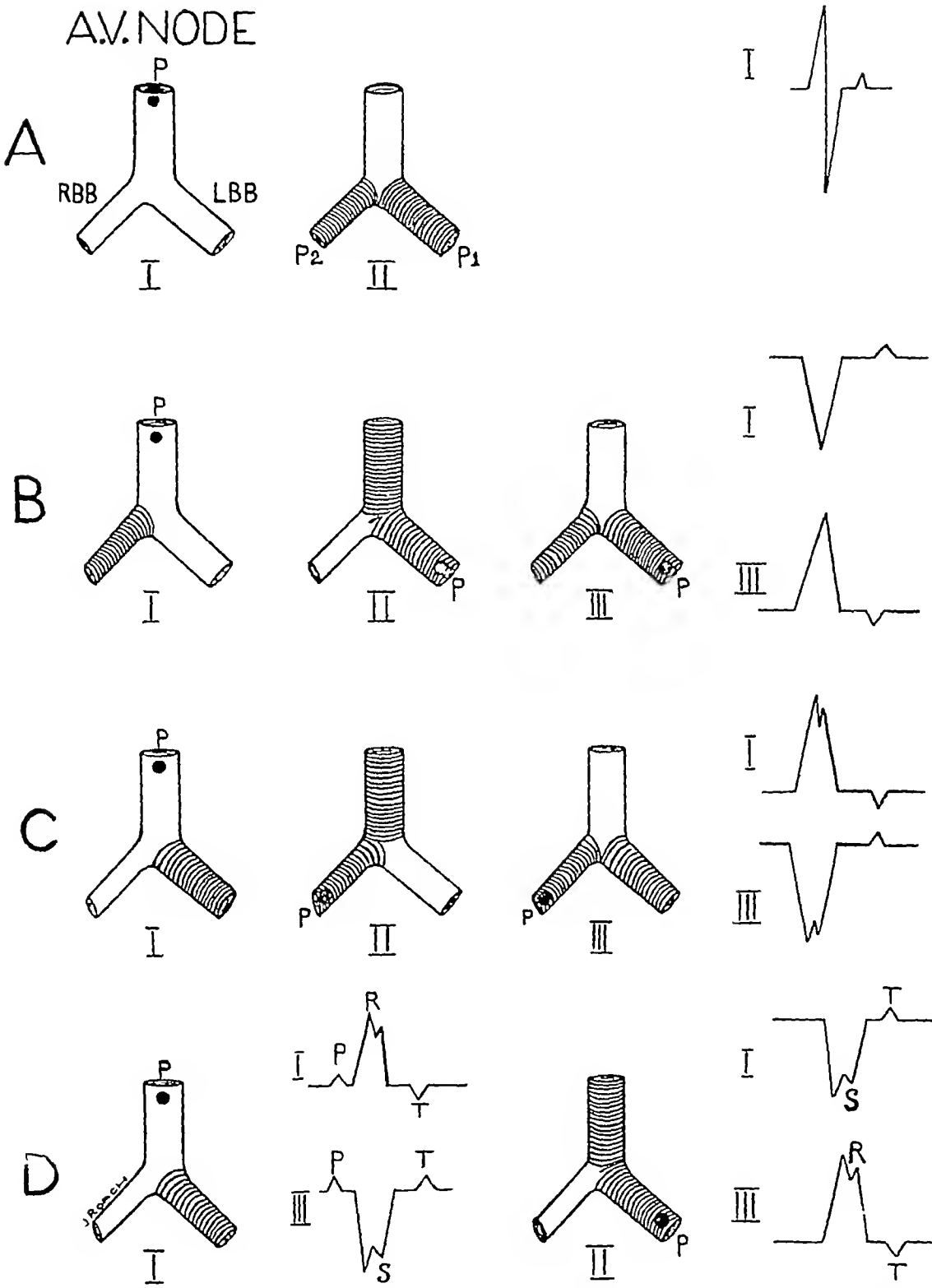

FIG 5 —Diagram of bundle showing location of ventricular pacemaker (P) site of lesion (shaded zone), and ventricular complexes of electrocardiogram R B B right bundle branch L B B left bundle branch

(A) Production of QRS complexes of normal duration P 1 and P 2 are simultaneous pacemakers in right and left ventricle

(B) and (C) Production of widened ventricular complexes

(D) (I) Sinus rhythm, ventricular pacemaker in A-V node, lesion involves the left branch of bundle, cardiogram shows left B B block complex

(II) Complete A-V block, ventricular pacemaker in left branch distal to lesion, now involving also main stem of bundle, cardiogram shows right B B block complex

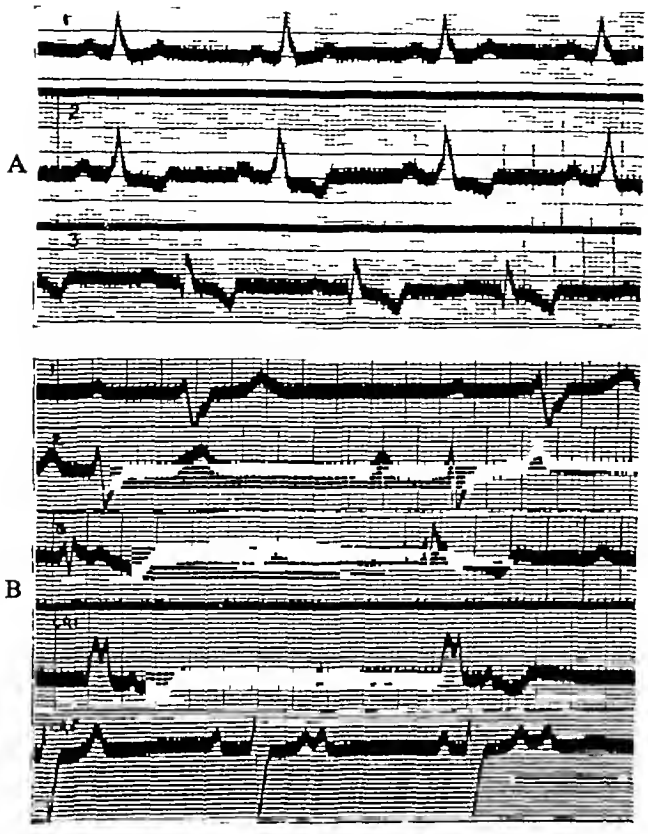

FIG 6 —Alteration of QRS complexes with change in rhythm
(A) On 10/1/45, sinus rhythm, rate 50 a minute, P–R interval normal, and QRS complexes of left B B block pattern
(B) On 7/8/47, complete A-V block, rate 30 a minute, and QRS complexes of right B B block
This patient, a woman aged 32, died suddenly on 22/8/47

old or the new view Master *et al* (1940) believe that the B B block curve is more often due to diffuse myocardial damage associated with great enlargement of the corresponding ventricle than to a localized lesion of a bundle branch, and Rasmussen and Thingstead (1939) have supported a similar view

When a lesion of the ventricular septum involves the main stem of the bundle it is likely to extend to the bundle branches and, therefore, we should expect to find complete A-V block sometimes associated with B B block in the cardiogram In fact, QRS of B B block pattern occurred in 47 per cent of the present cases of complete block We may consider this association in relation to the pathogenesis of the B B block cardiogram It is usually assumed that ventricular complexes of, say right B B block pattern indicate defective conduction in the right branch of the bundle, but an alternative explanation is to assume that the ventricular pacemaker is located in the left branch of the bundle This is illustrated schematically in Fig 5 (B and C)

Variations in the form of QRS may accompany the change from sinus rhythm to complete heart block, or vice versa, and these are of particular interest in regard to locating the ventricular pacemaker and to fixing the site of the bundle lesion In 6 cases where records of both sinus rhythm and of complete A-V block were obtained, significant changes in the form of QRS occurred In five of them, complete A-V block was combined with QRS of right B B block pattern, and sinus rhythm with a QRS of left B B block pattern (see Fig 6) This may be explained by supposing that there is a lesion of the left branch and that during sinus rhythm the right branch only conducts When the lesion extends from the left branch to the main stem of the bundle, causing complete A-V block, the ventricular pacemaker shifts to the left branch distal to the site of the lesion, thus producing right B B block pattern in the cardiogram This hypothesis is illustrated schematically in Fig 5 (D) Fig 7 shows the cardiograms of a man aged 54, during sinus

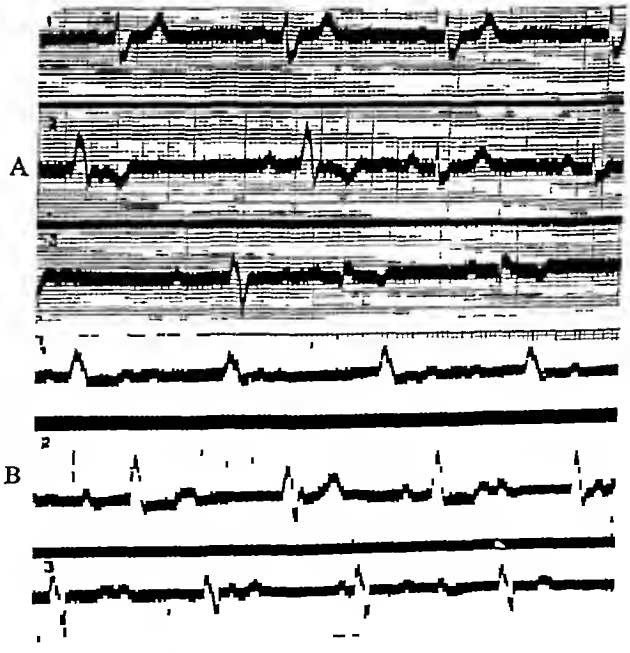

FIG 7 —(A) Electrocardiogram on 5/10/43, shows in lead I, and latter part of leads II and III, sinus rhythm, rate 48 a minute, and normal P–R interval, the QRS complexes are of the Wilson type of B B block In the first half of leads II and III there is complete A-V block, rate 34 a minute, QRS complexes being of left B B block pattern
(B) On 14/10/43, shows complete A-V block, with QRS complexes of left B B pattern

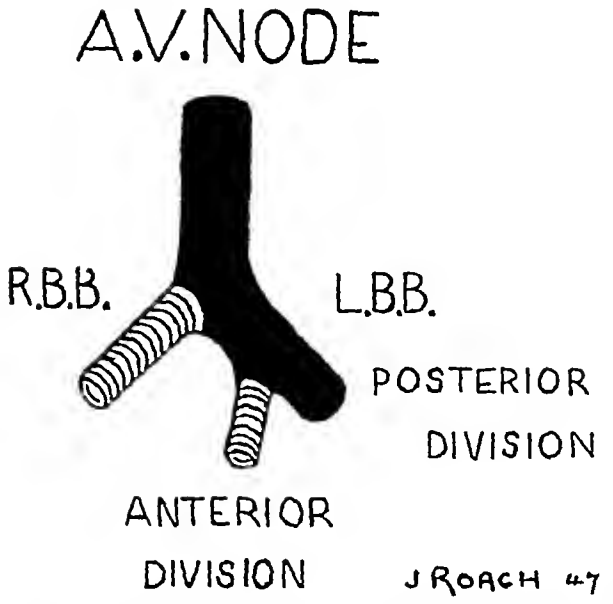

FIG 8 —Schematic illustration of the blood supply of the junctional tissues The area supplied by the posterior perforating branches is shown in black, and the shaded area represents the area supplied by the anterior branches

rhythm the QRS complexes are of right B B block pattern and during complete A-V block, of left B B block pattern

THE BLOOD SUPPLY TO THE BUNDLE

Gross (1921) describes the blood supply to the A-V node and the main bundle as being mainly from a special artery, the ramus septi fibrosi arising from the posterior interventricular artery, which is a branch of the right coronary artery in 90 per cent of hearts, the posterior division of the left bundle branch is also supplied from the same source The right bundle branch and the anterior division of the left bundle branch are supplied mainly by anterior perforating septal branches of the anterior interventricular artery, a branch of the left coronary artery, the terminal part the right bundle branch may receive some supply from the posterior perforating arteries The blood supply of the junctional tissues is illustrated schematically in Fig 8 In normal hearts, the anastomoses between the anterior and posterior perforating septal arteries are very fine, but with the slow obliteration of these arteries by coronary vascular disease, the anastomoses undoubtedly become more effective Blumgart *et al* (1940) consider that, irrespective of age, anastomoses measuring 40 micra or more in diameter between the right and left coronary arteries rarely exist in the absence of partial or complete arterial occlusion Permanent complete A-V block is usually associated with slow and progressive diminution of the blood supply of the posterior portion of the heart, which is through the posterior perforating septal arteries, and it has been shown that these vessels, besides supplying the main bundle, also supply the posterior division of the left bundle branch The common occurrence of QRS of right B B block pattern in complete heart block has been noted, in 5 such cases there were intervals of sinus rhythm with left B B block It is postulated that, with gradual diminution of blood supply, there is functional block of part of the left bundle branch and eventually of the main bundle and that, with the occurrence of complete A-V block, the new pacemaker is situated in the area of irritable tissue below the block, giving rise to a right B B block pattern of ventricular complex

VARYING VENTRICULAR COMPLEXES

The appearance of varying ventricular complexes in complete heart block may be associated with

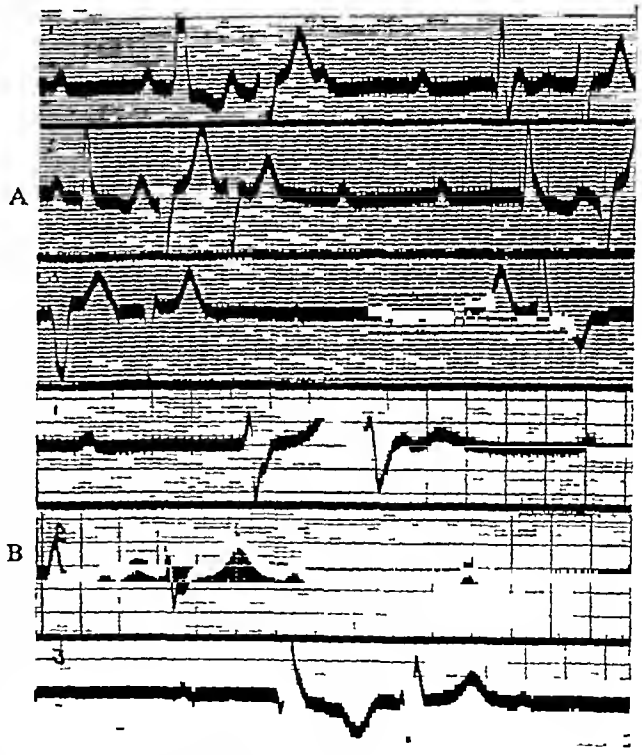

FIG 9 —Complete A-V block with varying ventricular complexes in the same tracing

(A) On 19/1/44, shows widened QRS complexes varying in shape in lead I, and multiple extrasystoles producing coupling

(B) On 18/4/45, showing QRS complexes of right B B block pattern Coupling due to extrasystoles still persists

This patient, a woman aged 47, was seen again in July 1947, the ætiology of the heart block was unknown

(a) changing site of the pacemaker, (b) the conduction of occasional auricular impulses, or (c) the occurrence of ventricular extrasystoles

(a) *Changing site of the pacemaker* There were six cases in which the ventricular complexes varied in the same tracing (see Fig 9) indicating either a changing site of the pacemaker, or a varying path of the impulses In only one of them were transitional complexes between the dextro- and lævo-cardiogram types detected Five of the cases had coronary heart disease, and the other was of uncertain ætiology As already described under group 2, there were also 4 cases in which, during observation over a period, the complexes varied between left B B block and right B B block pattern (see Fig 4)

(b) *The conduction of auricular impulses* was clearly responsible for variation in the ventricular complexes in records of only three cases (Fig 7) In one, each of the left B B block complexes was closely related to a P wave, although the P–R interval was variable, i e 0 24 to 0 36 seconds (Fig 10)

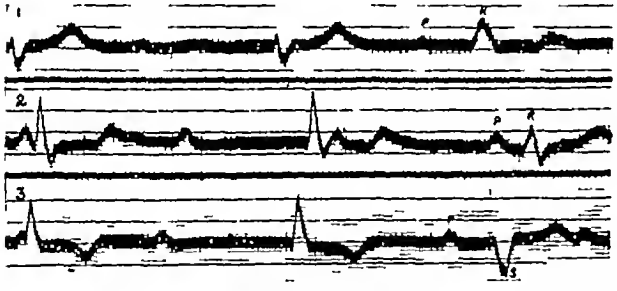

Fig 10 —Variation in the QRS complexes due to conducted auricular impulses in which the P–R interval varies

(c) *Ventricular extrasystoles* were recorded in 20 cases, originating in the right ventricle in 7, in the left in 8, and from both ventricles in 5 cases When ventricular extrasystoles occur in association with widened ventricular complexes the site of origin of the extrasystoles is usually in the same ventricle as the pacemaker Thus there were 6 cases with a left-sided pacemaker and extrasystoles, and in 5 of them the extrasystoles arose in the left ventricle (Fig 11) In one case with a right-sided pacemaker extrasystoles arose in both ventricles Coupling due to ventricular extrasystoles was recorded in 6 cases of which only one was receiving digitalis When complexes suggesting both left and right-sided pacemakers are seen, it is necessary to consider the possibility of intermittent auriculo-ventricular conduction, especially if there are no transitional complexes In this case, the conducted ventricular complex bears a certain relation to the P wave although the P–R interval may show some variation According to Katz this is a more common cause of variation in form of the QRS complexes than is the occurrence of extrasystoles Fig 12 shows a tracing in which, in lead III, the

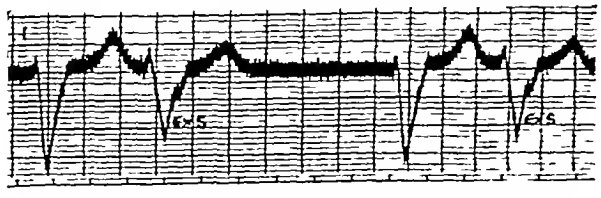

Fig 11 —Complete A-V block with ventricular extrasystoles resembling the main complexes

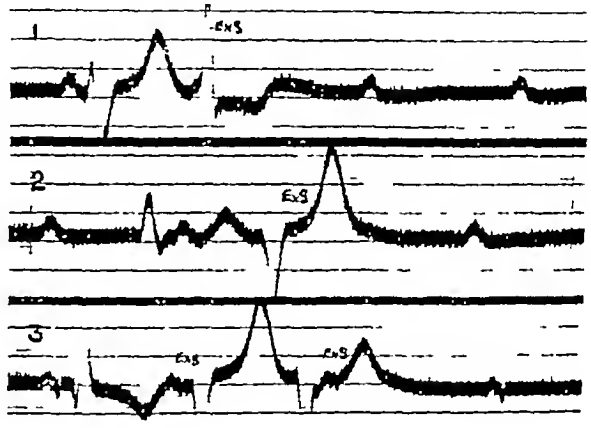

Fig 12 —The second and third complexes in lead III of this tracing are ventricular extrasystoles bearing no relation to P waves

second and third complexes are definitely extrasystolic, as they bear no relation to P waves

When varying complexes, due to a changing site of pacemaker, accompany complete heart block the lesions are more likely to be found in the bundle branches than in the main bundle according to the work of Wilson and Hermann, though destructive lesions of the terminal portion of the main bundle were found by Don, Grant, and Camp (1932)

As already stated, to explain the appearance of variable complexes, Wilson and Hermann (1921), and Gilchrist and Cohn (1928) postulate the existence of two pacemakers, with a change in leadership from one to the other Yater *et al* (1936) while accepting this concept, also consider that the site of the pacemaker may change from time to time in the same bundle branch and in addition that the path of the excitation wave may vary after leaving the pacemaker Clinically, bilateral bundle branch lesions can only be diagnosed with certainty when there are intervals of sinus rhythm with alternate right and left B B block complexes

The Ætiology of Complete Heart Block in Relation to the Form of the QRS Complexes

(a) *Congenital Heart Block* According to Yater (1929), complete heart block may be regarded as congenital when a slow pulse has been found at an early age, and when there is no history of infection such as diphtheria, rheumatic fever chorea or congenital syphilis A history of syncopal attacks early in life, though rare, and the presence of signs of congenital heart disease are supporting evidence of a congenital ætiology

In 20 cases of this series, heart block was regarded as being congenital on the grounds of its recognition in childhood or adolescence, of the absence of any relevant history of infection, and, in four cases, of the presence of signs of congenital heart disease In eleven of them, electrocardiograms showed QRS complexes of characteristically normal supraventricular form and of short duration (0 06–0 08 sec) without any axis deviation In the four cases with associated congenital heart disease, there was right axis deviation with QRS complexes of normal duration Four cases showed somewhat wider QRS complexes (0 08–0 1 sec) which were slightly notched, and one case showed widened QRS complexes (0 12 sec) of left B B block pattern Thus in congenital heart block the QRS complexes are commonly of supraventricular type, and the ventricular rate is relatively rapid between 40 and 60 a minute Similar findings have been reported by Leech (1930) On this evidence, we may assume that in congenital complete block the lesion usually involves the main bundle

(b) *Cardiac Infarction* There were nine cases of complete A-V block associated with clinical evidence of cardiac infarction and six of them showed QRS complexes of right B B block type (1) In three cases definite cardiographic changes indicative of acute infarction were recorded, it was posterior in two (see Fig 13) and anterior in the other (2) In one case progression from partial to complete A-V block was recorded and the T waves in leads II and III were observed to become inverted and later upright again, the QRS complexes were of normal duration (3) In the remaining five cases there was a reliable history of cardiac infarction but no definite electrocardiographic evidence of it All of them exhibited widened ventricular complexes which were of right B B block pattern in four, and of concordant uncommon B B block pattern in the other

Whilst heart block is common with gradual ischæmia of the junctional tissues, it is uncommon in cardiac infarction in which it is more often temporary, lasting hours or days, than permanent Levine found only two cases of complete block in a series of 145 cases of cardiac infarction with autopsy control, Schwartz (1936) described 15 cases, and Cookson (1942) described 5 cases in a review of 200 cases of cardiac infarction Complete heart block is usually associated with posterior infarction involving the septum when, as shown in this series, it is often associated with QRS complexes of right B B block pattern Antero-septal infarcts are rarely associated with complete heart block unless the infarct extends to the upper part of the septum

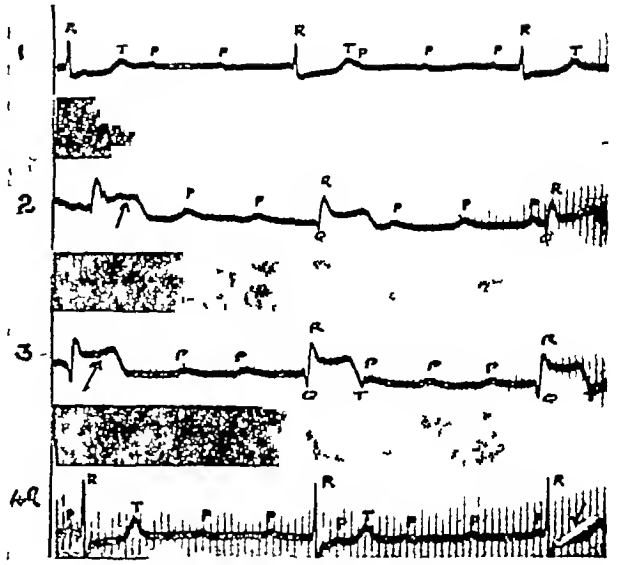

Fig 13 —Complete A-V block, rate 37 a minute, associated with recent posterior cardiac infarction in a man aged 65, who suddenly collapsed with præcordial pain and dyspnœa The electrocardiogram was recorded several hours later (Time marker 0 05 sec)

In the presence of bundle branch lesions, the electrocardiographic changes of cardiac infarction may be obscured, especially in the case of left B B block Wilson *et al* (1944) have found that right B B block does not obscure the changes characteristic of posterior infarction in the limb leads, though it may cause inversion of the T waves in right-sided præcordial leads and occasionally in lead III (Wolferth and Levezey, 1947) The cardiogram in Fig 14, from a patient giving a history of cardiac infarction, shows complete A-V block with QRS complexes of right B B block pattern and sharply inverted T waves in leads CR 3 and CR 4, suggesting anterior septal damage

The Prognostic Significance of the QRS Pattern

In cases of complete A-V block exhibiting normal QRS complexes in which the lesion is located high up in the bundle stem and is often congenital in

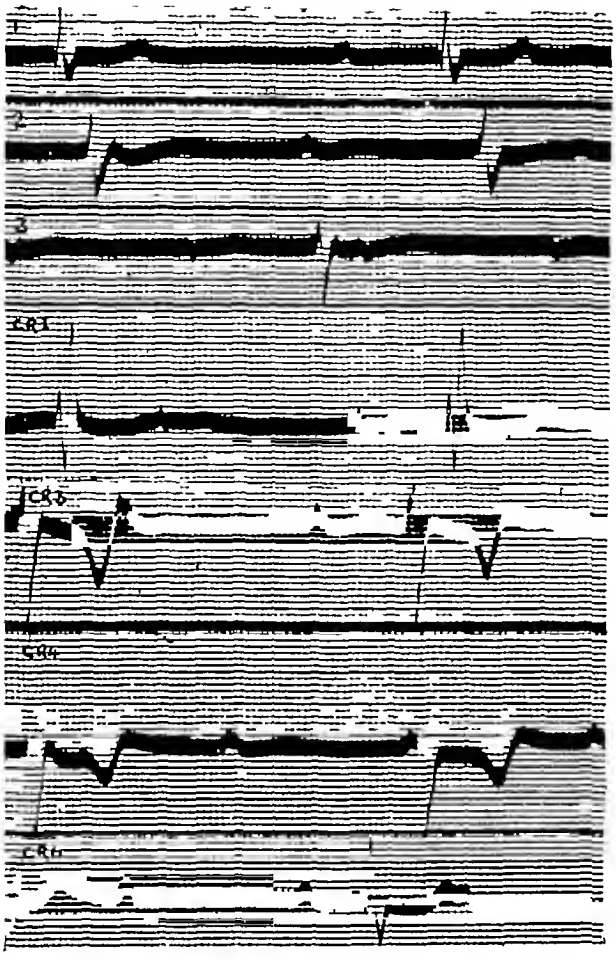

FIG 14 —Complete A-V block, rate 25 a minute, in a man aged 43, with a history of cardiac infarction The limb leads show QRS of right B B block pattern, leads CR 3 and CR 4 show sharp deeply inverted T waves, suggesting anterior septal damage

origin, the heart rate is faster and the liability to Adams-Stokes attacks is far less than in cases exhibiting widened QRS complexes, in which the lesion involves the bundle branches, often due to coronary disease, and the heart rate is slower Thus in my 53 cases with normal QRS complexes, only 20 (38 per cent) were recorded as having Adams-Stokes attacks compared with 31 (66 per cent) of the 47 cases with widened QRS complexes

Katz considers that the expectation of life is seldom longer than a year or two in complete block with widened QRS complexes Three of my cases of this type died suddenly before the age of 40, though four others had been under observation for a period of five years In general terms, however, the prognosis in complete A-V block may be assessed on the basis of the underlying heart disease, being relatively good when the ætiology is congenital and more serious when it is coronary

SUMMARY

A series of 100 cases of complete heart block has been investigated with special regard to the form of the ventricular complexes exhibited in electrocardiograms The most frequent ætiological cause of complete heart block was coronary heart disease which occurred in 52 cases, and next a congenital origin which was probable in 20 cases

The ventricular complexes found in complete heart block may be classified as follows —

(1) *Supraventricular pattern* (a) due to block in the main bundle stem, (b) occasionally due to bilateral bundle branch block

(2) *Bundle branch block pattern* (a) due to block in a bundle branch, (b) due to block in the main stem associated with bundle branch block

(3) *Varying pattern* (a) due to shifting pacemaker, (b) due to conducted auricular beats, (c) due to extrasystoles

In coronary heart disease, complete heart block is usually associated with obstruction of the posterior blood supply, and occurs more often with posterior than with anterior cardiac infarction The frequency of associated right B B block in coronary disease can be explained in terms of the blood supply to the conducting system In congenital complete heart block, the QRS complexes were of supraventricular pattern in 19 out of 20 cases

In complete block exhibiting QRS complexes of B B block pattern, the pacemaker is situated lower in the bundle, its inherent rate is slower, Adams-Stokes attacks occur more often, and the expectation of life is less than in cases of complete block exhibiting normal ventricular complexes

I have to thank members of the staff of the National Heart Hospital for permission to publish records of their cases, and Dr Evan Bedford for putting at my disposal cases seen at the Middlesex Hospital and in practice

REFERENCES

Bain, C W (1941) *Brit Heart J*, 3, 75
Blumgart, H L, Schlesinger, M J, and Davis, D (1940) *Amer Heart J*, 19, 1
Campbell, M (1944) *Brit Heart J*, 6, 69
Cookson, H (1942) *Brit Heart J*, 4, 163
Don, C S D, Grant, R T, and Camp, P D (1932) *Heart*, 16, 145
Fatzer, G (1946) *Cardiologia*, 10, 307

Freund, H A, and Sokolov, A (1939) *Arch intern Med*, **63**, 318
Gilchrist, A R, and Cohn, A E (1928) *Amer Heart J*, **3**, 146
Graybiel, A, and Sprague, H B (1933) *Amer J med Sci*, **185**, 395
Gross, L (1921) *The Blood Supply of the Heart*, New York
Katz, L N (1941) *Electrocardiography*, Philadelphia
Leech, C B (1930) *Amer J Dis Child*, **39**, 131
Levine, S A (1929) *Medicine*, **8**, 245
Mahaim, I (1931) *Les maladies organiques du faisceau de His-Tawara*, Paris
—— (1932) *Ann de Méd*, **32**, 347
Master, A M *et al* (1940) *Amer Heart J*, **20**, 186
Mouquin, M, and Macrez, Cl (1947) *Arch Mal Cœur*, **40**, 8
Rasmussen, H, and Thingstead, R (1939) *Acta med Scand*, **101**, 237
Schwartz, S P (1936) *Amer Heart J*, **11**, 554
Wilson, F N, and Hermann, G R (1921) *Heart*, **8**, 229
—— *et al* (1944) *Amer Heart J*, **27**, 19
White, P D, and Viko, L D (1923) *Amer J med Sci*, **165**, 659
Wolferth, C C, and Levezey, M M (1947) *Amer Heart J*, **34**, 1
Yater, W M (1929) *Amer J Dis Child*, **38**, 112
——, Cornell, P H, and Claytor, T (1936) *Arch intern Med*, **57**, 132

THE REGENERATIVE CAPACITY OF MAMMALIAN HEART MUSCLE

BY

E W WALLS

From the Department of Anatomy, Middlesex Hospital Medical School, London

Received June 5 1948

King in 1940, in this journal, described appearances that he believed to be those of myocardial regeneration in a case where death had occurred four days after a stab wound of the chest A review of the literature, however, shows the opinion most generally held is that hyperplasia of cardiac muscle does not occur Another consideration prompted the present study Le Gros Clark (1946) showed that considerable regeneration of skeletal muscle took place in the rabbit following experimental injury It therefore seemed desirable that the regenerative power of the rabbit myocardium should be studied

Methods and Results

It is very difficult to produce by crushing comparable lesions in rapidly beating hearts, and as burning had been employed successfully by Thomas and Harrison (1944) for functional recovery tests in rats, it was decided to use this type of lesion

In adult rabbits the heart was exposed under anæsthesia, with full aseptic precautions, and a severe burn made in the lower third of the left ventricle by the application of the head of a nail, 5 mm in diameter, heated to a dull redness The chest wound was closed and the animals allowed to survive for periods ranging from 3 days to 3 months The hearts were then examined microscopically

The appearances in the injured area were at first simply those of severe inflammatory reaction with destruction of tissue Later a progressive organization into scar tissue occurred, but there was no evidence of regeneration of cardiac muscle

At first the site of injury showed as a deep crater (Fig 2) filled with fibrin clot and necrotic tissue to which pericardial adhesions had become attached Surrounding this was an area containing damaged muscle fibres invested by macrophages of different kinds Amongst these cells monocytes were prominent (Fig 4), a point which has been noted by pathologists in acute muscle infections generally The damaged muscle fibres showed fragmentation (Fig 5), the lines of cleavage seeming to be at the intercalated discs, and their transverse striations and nuclei stained less strongly Very early on there were great numbers of fibroblasts to be seen within the injured area which was soon invaded by capillaries from the neighbouring healthy tissue (Fig 1) After a month there was a clear line of demarcation between undamaged muscle and scar tissue (Fig 3) although here and there fragments of muscle with attendant phagocytes could still be seen At no stage was sprouting of myoblasts detected nor were mitotic figures found, although it must be admitted that Le Gros Clark (1946) found nuclear division took place as a general rule by amitosis in regenerating skeletal muscle The longitudinal splitting of fibres described by King (1940) was not observed

Discussion

Compared with skeletal muscle cardiac muscle is much less easy to trace in serial sections, but even so it is felt that no signs of regeneration were missed The explanation of the difference in regenerative capacity of the two classes of muscle, as shown in the rabbit, may be histological, or it may be that in the heart rest cannot be enjoyed by the damaged fibres Distinguishing features of cardiac muscle are the ill-defined or absent sarcolemma, centrally placed nuclei, branching fibres, well marked longitudinal striation, granular sarcoplasm which somewhat masks the transverse striations, and the presence of intercalated discs It is usually stated that there is continuity of myofibrils through the discs Fig 6 shows this, but I am not satisfied that such continuity exists through all discs and it may be that the discs, whatever their physiological significance may be, act as an impediment to regeneration It might be argued that burning is



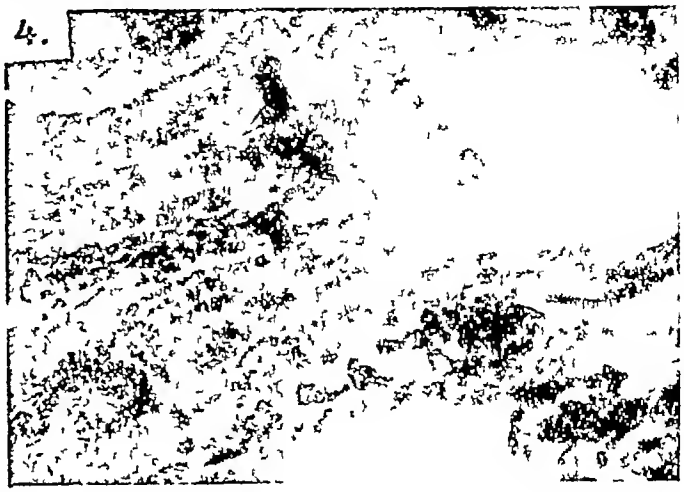



FIG 1 —Section 1 2 3 of rabbit heart (R 7) three days after operation Healthy fibres above and to left Numerous fibroblasts are shown within the damaged area which is becoming revascularized Magnification ×500

FIG 2.—Section 32 2 3 of rabbit heart (R 4) seven days after operation A general view of the crater produced by the burn is shown Magnification ×7

FIG 3 —Section 3 2 2 of rabbit heart (R 10) one month after operation Healthy tissue to left, scar tissue to right The line of demarcation is sharp Magnification ×650

FIG 4 —Section 32 2 3 of rabbit heart (R 4) seven days after operation Damaged myocardial fibres are shown surrounded by great numbers of phagocytes A large monocyte is especially pronounced Magnification ×530

FIG 5 —Section 1 2 3 of rabbit heart (R 7) three days after operation To show fragmentation of the muscle fibres Magnification ×650

FIG 6 —Section of undamaged rabbit heart muscle To show continuity of myofibrils through an intercalated disc Magnification ×1375

too severe a lesion for a fair assessment of results, but Harrison (1947) who carried out similar experiments also showed that skeletal muscle in rabbits did regenerate after burning by diathermy

SUMMARY

Following experimental injury of the rabbit heart by burning there is no evidence of regeneration of cardiac muscle

To Professor C M West, University College, Cardiff, in whose department this work was started, and to Professor John Kirk, my present chief, I wish to express my gratitude for much helpful advice The photomicrographs are the work of Mr S R Scarfe

REFERENCES

Harrison, R G (1947) *J Anat Lond*, **81**, 365
King, E S J (1940) *Brit Heart J*, **2**, 155
Le Gros Clark, W E (1946) *J Anat Lond*, **80**, 24
Thomas, W C, and Harrison, T R (1944) *Amer J med Sci*, **208**, 436

INCIPIENT SYMMETRICAL PERIPHERAL GANGRENE COMPLICATING PAROXYSMAL TACHYCARDIA

BY

D GORDON ABRAHAMS

Received February 11, 1948

Bilaterally symmetrical incipient gangrene of all the bodily extremities is sufficiently rare to merit the report of the following case

Case Report

Mrs H, a housewife, aged 47 years, was admitted to hospital in January 1947 She had been married 27 years, and had two healthy adult sons Three days previously she was suddenly taken ill with diarrhœa and sickness, accompanied by faintness and a "fluttering feeling around the heart" Her doctor recommended her admission to hospital because her pulse was extremely rapid, and because her general condition deteriorated swiftly Her history revealed two similar attacks, the last six weeks previously This began with temporary loss of consciousness and lasted about two days, and on the second day she noticed that her hands and feet were very cold However, she soon made an uneventful recovery For the last year she had been conscious of a fluttering in the chest on exertion, which had lately been lasting longer and had been more easily provoked

On admission, she was obviously a very ill woman The hands, feet, nose and ears were very cold, extremely cyanosed, painful, but anæsthetic to light touch The skin of the extremities did not blanch on pressure The radial, ulnar, and dorsalis pedis pulses were imperceptible The brachial and popliteal pulses were palpable The systolic blood pressure was 65 mm in the arms, and 85 mm in the legs, the diastolic was unobtainable The pulse rate was extremely rapid Clinically, the heart was enlarged to right and left, but the limits were difficult to define An apical thrill and murmur were noted, but they could not be timed owing to the tachycardia The neck veins were markedly distended and

Fig 1 —Ventricular tachycardia, rate 230 a minute



Fig 2 —Normal rhythm, rate 97, P–R interval 0·16 sec, S–T segment depressed



Fig 3 —Ventricular asystole, ventricular rate 90

quivering, being engorged up to the ears, whilst the arm veins were so empty of blood that they could not be seen at all The liver was just palpable, ascites and pitting œdema were absent, but there were a few moist sounds at the lung bases Throughout all this time the patient remained co-operative, calm, alert, and in full possession of her mental faculties

A portable chest X-ray provided no useful information An electrocardiogram showed a regular paroxysmal ventricular tachycardia at a rate of 230 a minute (Fig 1)

Thus the clinical picture was that of extreme circulatory failure of which the immediate precipitating cause was the tachycardia It was imperative to slow the heart rate and to raise the blood pressure as soon as possible, and quinidine was given intravenously for this purpose After a test dose of 3 grains had excluded idiosyncrasy to the drug, a solution containing one gram of quinidine sulphate in 100 ml of glucose saline was administered by slow intravenous drip Half an hour later, when the patient had received approximately 60 ml of the solution (0 6 g quinidine), she suddenly became distressed and lost consciousness The drip was discontinued and a further electrocardiogram was taken (Fig 2) This was thought to show regular rhythm at a rate of 97 a minute, the QRS complexes were less widened A period of ventricular asystole then ensued, with an auricular rate of 90 a minute (Fig 3) This was followed by cardiac standstill and death four hours after her admission

Post-mortem examination The cardiovascular system alone showed relevant pathological changes There was extensive syphilitic aortitis, with aneurysmal dilatation of the ascending part and arch of the aorta The coronary arteries were

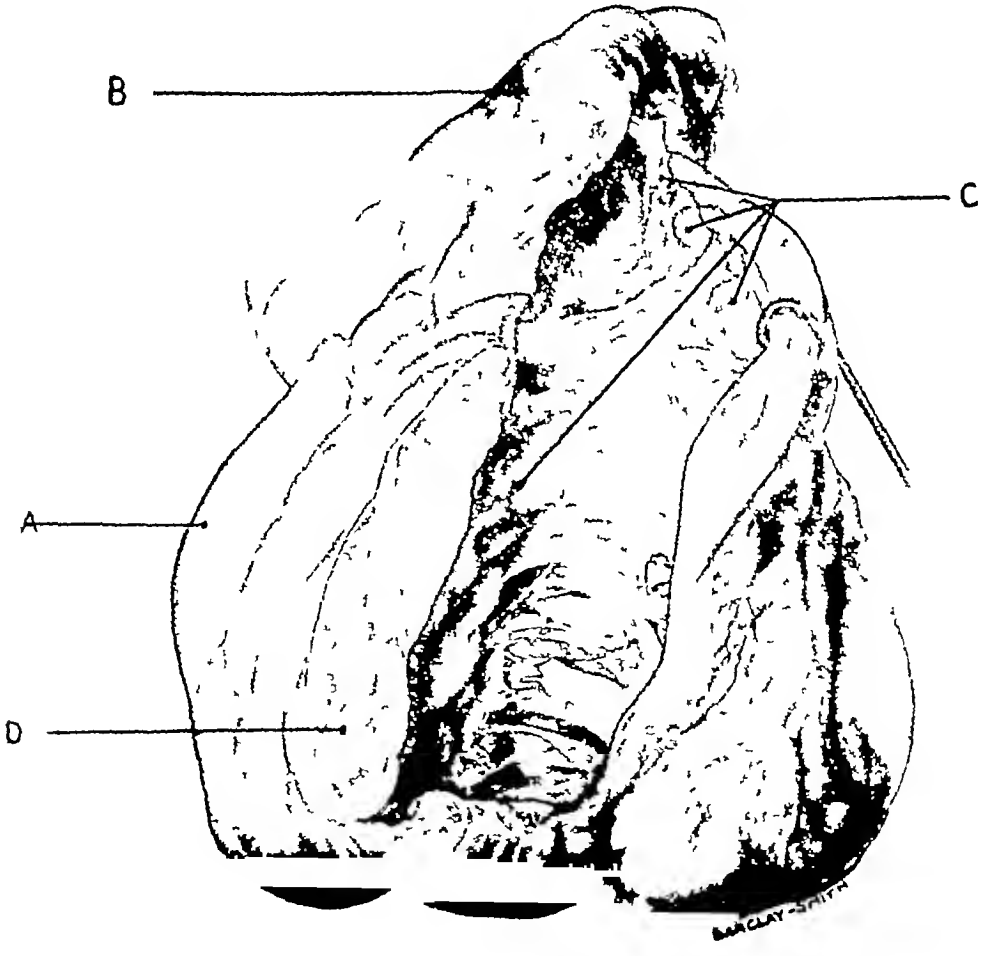

Fig 4 —Drawing of heart with right ventricular cavity open (A) Right auricle (B) Pulmonary artery, (C) Granulomatous masses in right ventricle and pulmonary artery, and (D) Gummatous infiltration of the wall of the right ventricle



FIG 5 —Gumma of myocardium Magnification ×125

healthy and showed no sign of narrowing of their orifices The left auricle and ventricle appeared normal, but the muscle of the right ventricle and also the interventricular septum showed diffuse fibrotic infiltration There were, in addition, numerous large, discrete, granulomatous lesions distributed over the internal surface of the right ventricle, one particular mass lying under the tricuspid valve measured three-quarters of an inch in diameter The pulmonary artery was similarly affected (Fig 4) The arteries to the upper and lower extremities showed no abnormality throughout their lengths Section and microscopic examination revealed that both the diffuse infiltration and the granulomatous masses were syphilitic in nature (Fig 5 and 6)

DISCUSSION

The case presents several points of interest Gumma of the heart is comparatively rare In fourteen years of extensive study of syphilitic cardiovascular disease Maynard (1943) stated that this lesion had been encountered only once at necropsy When present, gummata usually occur in the left ventricular myocardium and particularly in the basal portion of the septum (Sohval, 1935) Sohval also states that diffuse gummatous myocarditis is extremely rare by itself, being usually associated with gumma of the heart, as it was in this case Syphilis of the pulmonary artery is also rare, though in a review of cases showing aneurysm of the pulmonary artery, Boyd (1941) stated that syphilis was the ætiological factor in thirty-three cases (31 per cent)

A paroxysm of ventricular tachycardia usually lasts no more than an hour (Cooke and White, 1943), but longer attacks, lasting 1 to 3 weeks have been recorded (Dubbs and Parmet, 1942, Beers and de la Chapelle, 1947) In the present case, the paroxysm lasted just over three days

Symmetrical peripheral gangrene is mentioned by Fishberg (1944) as occurring in occlusion of the mitral valve by a ball thrombus, and in massive cardiac infarction I can find no other references concerning its occurrence in cardiac infarction, but Abramson (1924) recorded it in a review of ball thrombi of the heart He stated that severe disturbances of the general circulation were the rule, and that gangrene of the extremities sometimes occurred, which he thought was usually due to peripheral arterial emboli Tight or button-hole stenosis of the mitral valve frequently gives rise to intense cyanosis, and coldness of the extremities, but not to gangrene

Fishberg (1938) noted the co-existence of "collapsed" veins in the extremities with engorged jugular veins, in extreme failure of the right heart This he attributed to compensatory vaso-constriction in the extremities evoked reflexly by extreme diminution in cardiac output In this connection he observed symmetrical peripheral incipient gangrene on two occasions

Bruce Perry and Davie (1939) reported bilateral symmetrical peripheral incipient gangrene in the lower limbs in a case of hypertensive heart disease, terminating in congestive failure, and agreed with Fishberg that excessive peripheral vasoconstriction was responsible Chatterjee (1940) noted peripheral symmetrical incipient gangrene during the course of

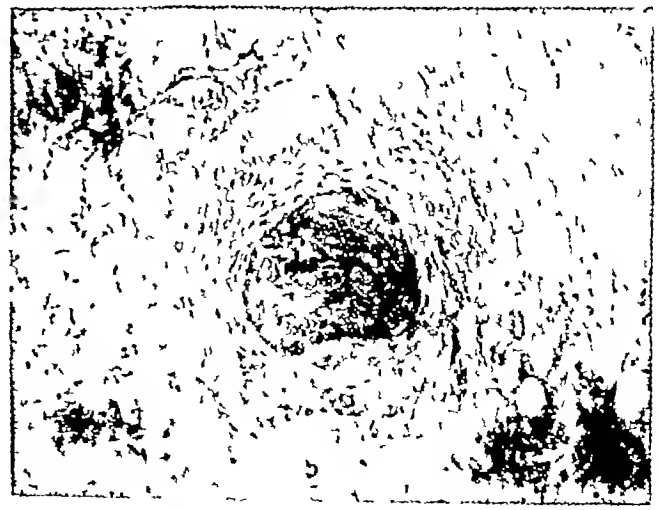

FIG 6 —Obliterating endarteritis of myocardial vessel Magnification ×125

lobar pneumonia, and concluded that it was due to acute circulatory failure, probably reflex in origin

In the present case, neither arterial emboli, nor luetic arteritis played any local part in the genesis of the gangrene It seems certain, therefore, that reflex peripheral vasospasm as indicated by Fishberg, was responsible, and that this was evoked by a critically low cardiac output, due to persistent ventricular tachycardia

Summary and Conclusions

A case of incipient symmetrical peripheral gangrene is described, associated with extreme heart failure due to persistent ventricular tachycardia Necropsy revealed the presence of discrete gummata of the heart and pulmonary artery, and diffuse gummatous infiltration of the right ventricle and interventricular septum Similar cases are briefly reviewed, and it is concluded that the incipient gangrene was due to compensatory peripheral vasoconstriction

I wish to thank Dr J H Gubbin and Dr R G M Longridge for permission to publish this case, and Dr G W D Henderson who performed the autopsy I am indebted to Dr J W Shackle for the photomicrographs and to Miss Barclay-Smith for the drawing of the heart I have to thank Dr Paul Wood for much helpful criticism in the preparation of this report

REFERENCES

Abramson, J L (1924–5) *Ann clin Med*, **3**, 327
Beers, S D, and de la Chapelle, C E (1947) *Ann intern Med*, **27**, 441
Boyd, L J (1941) *Modern Concepts of Cardiovascular Disease Amer Heart Assoc*, **10** 2
Chatterjee, S C (1940) *Calcutta med J*, **37**, 221
Cooke, W T and White, P D (1943) *Brit Heart J*, **5**, 33
Dubbs, A W and Parmet, D H (1942) *Amer Heart J*, **24**, 272
Fishberg, A M (1938) *J clin Invest*, **17**, 520
——— (1944) *Heart Failure* London, 3rd ed, p 656
Maynard, E P (1943) *Modern Concepts of Cardiovascular Disease, Amer Heart Assoc* **12**, 1
Perry, C B, and Davie, T B (1939) *Brit med J*, **1**, 15
Sohval, A R (1935) *Arch Pathol*, **20**, 431

TUBERCULOUS PERICARDITIS*

BY

A A FITZGERALD PEEL

From the Cardiac Department Victoria Infirmary, Glasgow

Received June 28 1948

The incidence of tuberculous pericarditis in this country seems to have been underestimated in the past The role of tuberculosis as one of the ætiological factors in chronic constrictive pericarditis is being increasingly recognized (White, 1935, Sellors, 1946), yet relatively few studies of the onset or acute stage of the disease have been published, and the majority of these hail from overseas

Incidence of Tuberculous Pericarditis

Osler (1893) analysed 1000 autopsies, of which 215 were cases of tuberculosis and 7 had tuberculous pericarditis, giving an incidence of 0 7 per cent in the U S A Norriss (1911), also in the U S A, found 1780 cases of tuberculosis in 7219 consecutive autopsies, 82 of the tuberculous cases had pericarditis, an incidence of 1 1 per cent As compared with these figures Suzman found an incidence of 0 4 per cent in autopsy records at Guy's hospital, 1500 autopsies yielded 102 cases of tuberculosis, of whom 6 had pericarditis American writers agree in stating that the condition is more frequent in coloured patients than in whites, this, no doubt, has helped to enhance the impression that it is " rare in Europeans" (White, 1935) High susceptibility appears to extend also to coloured African races, for Heimann and Binder (1940) succeeded in collecting 31 examples in Bantu natives in Johannesburg

Ellman (1945) published a series of 6 cases and suggested that the disease is less infrequent in this country than had hitherto been supposed Autopsy statistics may be misleading because tuberculous pericarditis sometimes undergoes complete resolution (Ellman, 1945, also Cases 3 and 6 of present series) or because the tuberculous nature of a chronic pericarditis is not always recognizable histologically on examination of excised pericardium or autopsy material White (1935) had a case in which pericardium excised at operation showed non-specific fibrosis, the patient died shortly after the operation, and at autopsy tubercles were found in the remainder of the pericardium Dr T Semple (personal communication) had a patient with constrictive pericarditis whose excised pericardium was reported histologically as showing non-specific fibrous thickening, four months after the operation the patient developed tuberculosis of an elbow joint It is certain, therefore, that in addition to the recognized cases of constrictive pericarditis, others are tuberculous in origin despite a non-specific histological picture Furthermore failure to find tubercle bacilli in a pericardial effusion should not be allowed to cast doubt on a diagnosis of tuberculous pericarditis if there is other evidence, clinical or radiological, pointing to a tuberculous ætiology, Fine and Katz (1944) report an instance of primary tuberculosis of the pericardium in which the pericardial fluid was negative on guinea-pig inoculation, nevertheless the patient died a month later from miliary tuberculosis with meningitis, and tuberculous pericardial thickening was found at autopsy

Excluding 3 seen in consultation on a single occasion, 8 cases of tuberculous pericarditis have been under my personal observation during the past 13 years, 7 were males, 3 were in hospital during the single year 1947 The incidence would therefore seem to be considerably greater in this country than has previously been suspected The youngest was an infant of 18 months, three were boys aged 11, 14, and 15, three were men aged 23, 27, and 43, and the woman was aged 20 All writers agree that the incidence is considerably greater in males than in females Harvey and Whitehill (1937) found 90 per cent males in a series of 95 cases admitted to the Johns Hopkins Hospital during a period of 45 years Their maximum age incidence was between 20 and 30

* This article includes material used in communications to the British Cardiac Society, May 1948, and the 111 Inter-American Cardiological Congress, June 1948

(25 per cent of cases), but every decade in life was represented and several patients were over 50

Stage at which Pericarditis Develops

Paget (quoted by Ellman, 1945) has stated that most cases arise in the stage of early dissemination following the primary infection Harvey and Whitehill's findings (1937) are consistent with this view, of their 37 bacteriologically proved cases, only one had previous hæmoptysis The present series amply bears out Paget's suggestion Two patients (Cases 1 (Fig 1–3) and 2 (Fig 4–6)) developed pericarditis in the presence of an active primary Ghon lesion with hilar gland involvement, one of them had early secondary infiltration as well Two (Cases 3 (Fig 7–9) and 7) had pericarditis accompanying an apparently primary tuberculous pleurisy Three (Cases 4, 6, and 8) occurred in the absence of any demonstrable lung or pleural lesion In Case 4 the ætiology was obscure at the onset of his acute attack, but a pleural effusion appeared after a month, pericardial constriction followed and the tuberculous ætiology was proved by histological examination of excised pericardium nine months later Case 6 was never proved tuberculous beyond doubt, but his initial pericarditis was followed by a right-sided pleural effusion after five months, and by a left-sided pleural effusion with recrudescent pericarditis four months later Case 8 is recent, suspected though as yet unproved, and still under observation Only once (Case 5) did pericarditis complicate pulmonary disease of longer standing, this was a male, aged 43, with an old calcified lesion at his right apex he developed a pleural effusion with tubercle bacilli in the fluid and in his sputum, though X-ray failed to reveal signs of activity of his pulmonary lesion, four months later, when he was regarded as convalescent and due for discharge from hospital, a pericardial effusion suddenly developed, the pericardial fluid contained tubercle bacilli

Mode of Infection of Pericardium

Riesman (1901) classified tuberculous pericarditis into four groups (1) with generalized miliary tuberculosis, (2) with serous membrane tuberculosis, (3) by extension from neighbouring foci (regarded by him as the commonest) and (4) primary Most writers question the existence of anatomically primary tuberculosis of the pericardium Clinically primary pericardial tuberculosis has been regarded as uncommon in the past, Clarke (1929) stated that careful search revealed only 11 such reported cases in which the diagnosis could not be questioned, Fine and Katz (1944) found only one case reported in children under 15 (by Blatt and Greengard, 1928), they add one of their own The revival of interest in pericardial constriction, brought about in recent years by the possibilities of surgical treatment, has led to the general belief that clinically primary cases must be less infrequent than these reports would suggest

No less than three in the present series (Cases 4, 6, and 8) fall into the category of "clinically primary", yet it seems almost certain that they are, in fact, secondary to tuberculosis of the mediastinal

Fig 1—Case 1 Teleradiogram, 13/12/47 Pericardial effusion with Ghon focus

Fig 2—Case 1 Teleradiogram 20/1/48 Effusion largely absorbed, Ghon focus persists



FIG 3—Case 1 Teleradiograms Enlarged view of Ghon focus with hilar glands on 13/12/47 and 16/2/48

FIG 4—Case 2 Teleradiogram, 28/11/47 P–A view

FIG 5—Case 2 Teleradiogram, 20/1/48 Right oblique view

lymph glands, from which the pericardium has become infected by extension Failure to visualize enlarged mediastinal glands radiologically cannot be held to exclude tuberculosis of these glands In the two cases where pericarditis accompanied an active primary Ghon lesion, the radiological picture strongly suggests direct extension from hilar glands as the probable route of infection (Fig 3 and 6)

In another patient (Case 3) where pericarditis accompanied a right-sided pleural effusion, serial X-rays revealed transient enlargement of the glands in the left hilum (Fig 7) Heimann and Binder (1940) found tuberculous mediastinal glands in all their cases but pulmonary lesions were present only in 16 of the 28 autopsies Harvey and Whitehill (1937) and Hannesson (1941) also regard extension

from mediastinal glands as the most important route of infection

While miliary tubercles may form in the pericardium during the course of miliary tuberculosis, this form of pericarditis is clinically unimportant, the course of the disease is not modified It must be borne in mind that tuberculous pericarditis can terminate in miliary tuberculosis, Heimann and Binder (1940) had several cases in which miliary tuberculosis followed tuberculous pericarditis, but they failed to find a single instance in which pericarditis was secondary to miliary tuberculosis, they were dealing with cases of "clinically important" pericarditis



FIG 6—Case 2 Teleradiograms Enlarged view of Ghon focus and secondary infiltration on 22/11/47 and 25/4/48

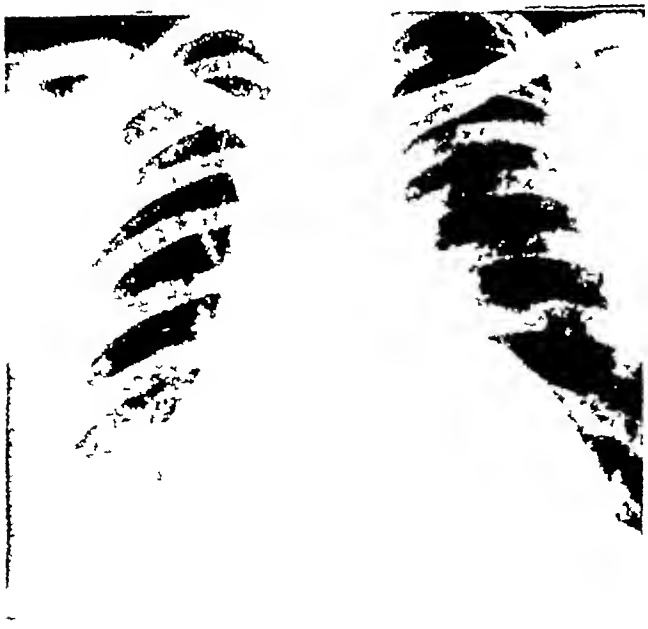

FIG 7—Case 3 Teleradiogram, 1/5/47, with pericardial and right pleural effusions

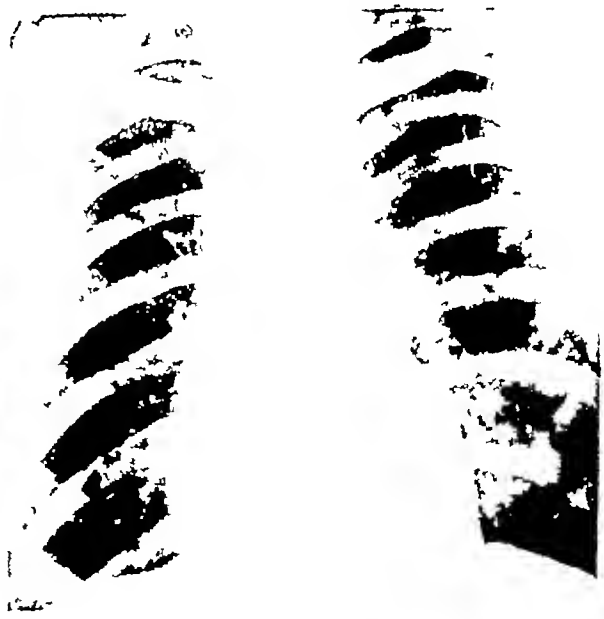

FIG 8—Case 3 Teleradiogram, 19/5/47, with left hilar enlargement

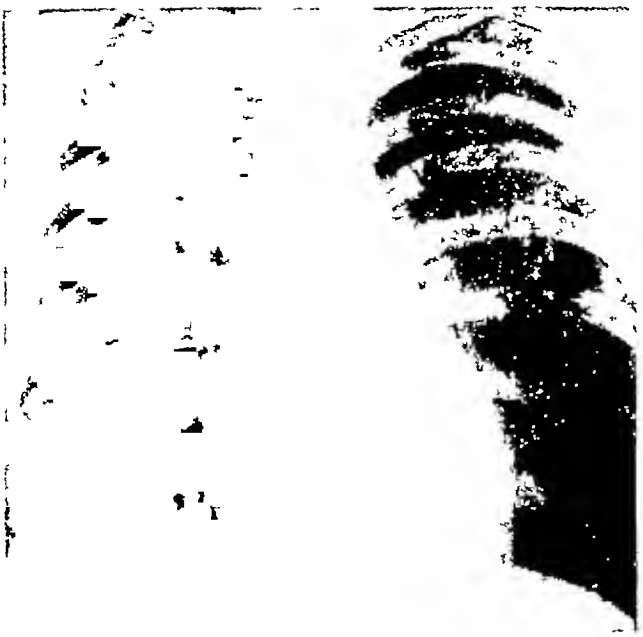

FIG 9—Case 3 Teleradiogram, 8/9/47, showing complete resolution

SYMPTOMATOLOGY

American writers (Harvey and Whitehill, 1937, Hannesson, 1941) differentiate two groups of cases, in one of which the clinical features suggest acute tuberculosis or other acute infection, pericarditis is an incidental finding and is "clinically unimportant" Only one case in the present series falls into this group, this was a young woman of 20, a member of the W A A F who was admitted to an E M S hospital with fever, tachycardia, flushing, sweating, and signs of a large right-sided pleural effusion from which tubercle bacilli were recovered, there were no cardiac or circulatory symptoms, pericardial friction and effusion being found incidentally It seems likely that, under conditions obtaining in Great Britain, such cases are more likely to be encountered in fever hospitals or sanatoria than in general hospitals

The second group is that in which the pericarditis is "clinically important" that is to say the clinical features point to cardiac disease and pericarditis is the presenting symptom One of the most striking characteristics of this group is the relative insignificance of constitutional symptoms Almost all writers comment on this (Harvey and Whitehill, 1937, Hannesson, 1941, Suzman, 1943, Barrett and Cole, 1944, Ellman, 1945), and it has been noteworthy in the present series Loss of weight and night sweats have been conspicuous by their absence Case 2 was afebrile (Fig 10), while in Case 3 fever was virtually absent (Fig 11), a temperature of 99° F having been recorded only on four occasions during the course of the illness In the absence of cardiac tamponade the pulse rate rarely exceeds 110 while the sleeping pulse rate has usually been between 80 and 95 Thus Case 1 who had fever (Fig 12), friction, pericardial effusion, cardiographic evidence of myocarditis, and radiological evidence of an active Ghon lesion, had a sleeping pulse rate between 90 and 95 with a waking pulse rate between 100 and 110, Case 3 with friction and effusion but no fever had a pulse rate between 60 and 70, in Case 2 the pulse rate remained unaltered (sleeping pulse 80, waking pulse 90 to 100) when pericardial friction appeared In this respect tuberculous pericarditis presents a marked contrast to rheumatic pericarditis Pallor was present in the four children in the series, the facial appearance being similar to that in rheumatic carditis, but despite the pallor there was remarkable absence of lassitude—the patients being bright, active and alert, almost euphoric in their insistence that they felt nothing wrong at times when they were febrile with friction or signs of effusion Appetite has generally remained unimpaired

Subjective symptoms, when present, have consisted of præcordial pain (Case 3), of circulatory embarrasment from cardiac tamponade (Case 5), of pressure cough (Case 1), or have been attributable to a coincident pleurisy (Case 7)

An interesting physical finding has been the persistence of loud pericardial friction over the entire præcordial area in two instances (Cases 1 and 3) in the presence of a moderately large effusion This feature has previously been noted by Harvey and Whitehill (1937) and by Ellman (1944), though no explanation of such an apparent anomaly has been attempted In both cases the effusion has seemed of sufficient size to ensure separation of the parietal and visceral layers of the pericardium (see Fig 1 and 7), and it seems likely that the sound has been produced in the parietal layer itself In the chronic constrictive stage of tuberculous pericarditis the parietal layer is usually much thickened, often to a considerably greater extent than the visceral layer, it seems reasonable to suppose that this layer will be the seat of inflammatory thickening in the acute stage also In these circumstances the alternating tension and relaxation which must be communicated to the parietal layer through the inelastic fluid content of the sac at each cardiac diastole and systole, may perhaps be responsible for the production of the friction sound

MYOCARDIAL LESIONS

With the exception of Heimann and Binder (1940), who found myocardial lesions in 10 of their 28

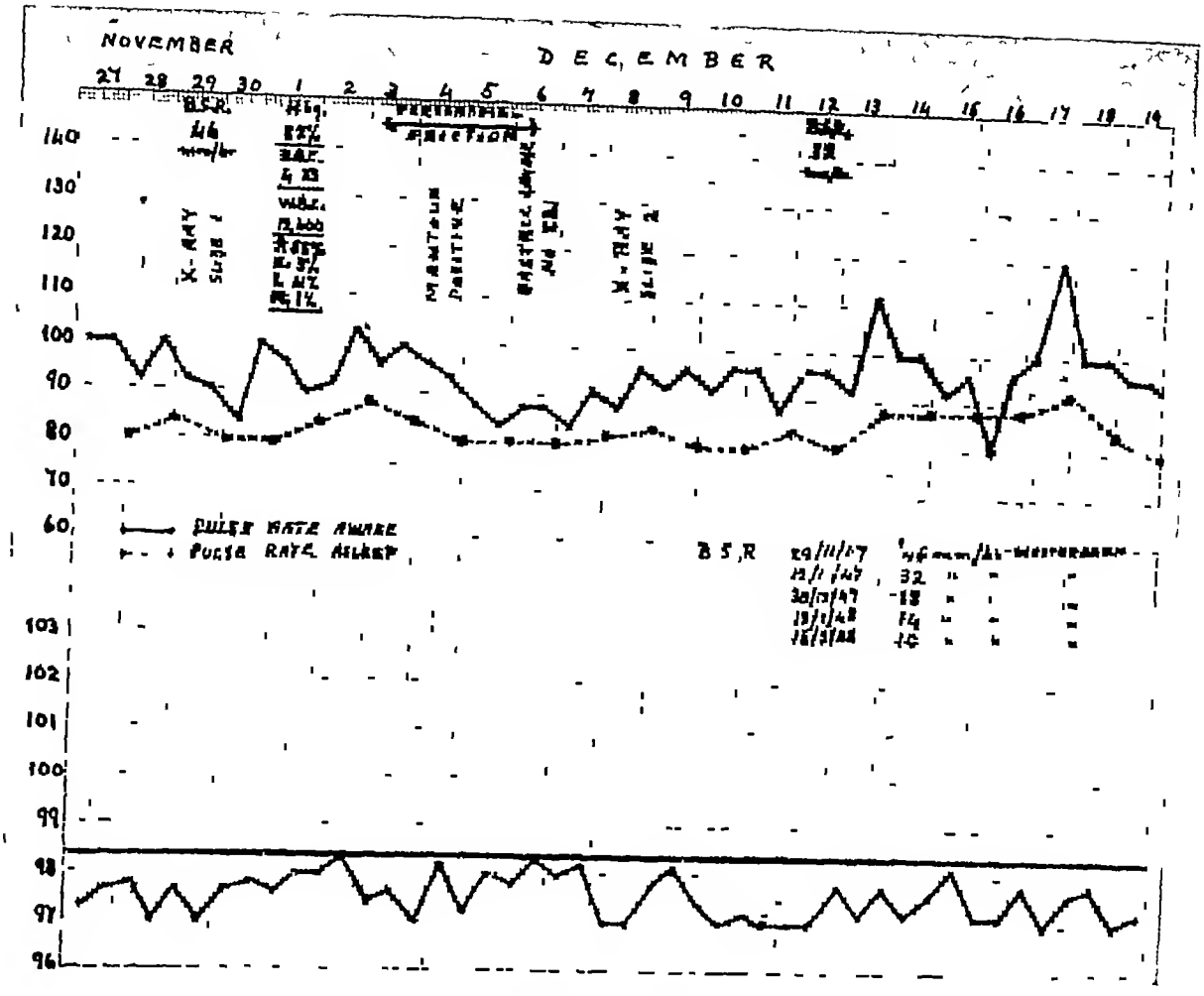

FIG 10 —Case 2 Temperature and pulse chart

autopsies in Bantu natives (36 per cent), most writers regard myocardial tuberculosis as rare Thus Harvey and Whitehill (1937) encountered only two instances of infiltration of the myocardium apart from the presence of miliary tubercles in one patient with miliary tuberculosis, the left auricle was involved in one, the ventricles in the other One patient in the present series (Case 1) had cardiographic evidence of myocardial involvement, there was M-shaped notching of QRS in lead CR 2 suggesting a lesion of the right bundle branch (Fig 13) this persisted for a month, then gradually disappeared, in addition, there was T wave inversion in leads I, II, CR 2, CR 4, and later CR 6, this likewise persisted for fully a month after the effusion had completely absorbed

Harvey and Whitehill found that arrhythmias were confined to patients who had received digitalis, auricular fibrillation occurred in two, latent heart block in two, partial heart block once, complete heart block once, and nodal rhythm once Case 5 of the present series had auricular fibrillation for a time, he had previously been treated with digitalis and mercurial diuretics None of the remaining patients received digitalis, and none showed any arrhythmia while under my observation, though one was stated by his doctor to have had cardiac irregularity (the type of which was not specified) at the onset of his illness (Case 6)

Endocardial Lesions

Tubercles have been found in the endocardium and valves in some recorded cases, but there is no evidence to suggest that chronic valvular disease ever results (Hannesson, 1941), thus tuberculosis was found only once in a series of 300 cases of mitral stenosis Conversely White states that mitral stenosis is extremely rare in cases of tuberculosis A previous history of rheumatism was unusual in Harvey and Whitehill's series (1937), three of their patients gave a vague story of joint pains from 6 to 11 months before the onset of their present illness, but the description was not that of a typical rheumatic polyarthritis, and in no instance had there been

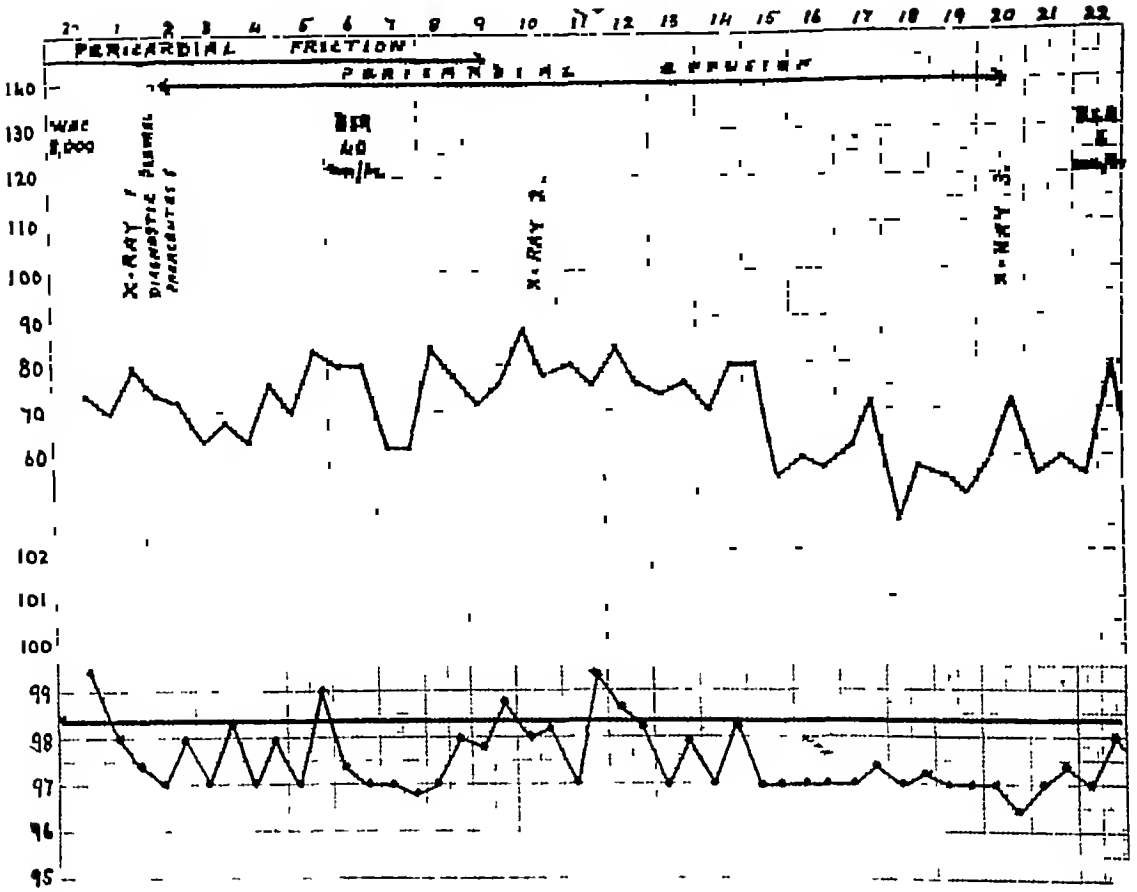

FIG 11 —Case 3 Temperature and pulse chart

symptoms of myocardial insufficiency All writers are in substantial agreement in regarding absence of valvular lesions as an important diagnostic point in the differentiation of tuberculous and rheumatic pericarditis

Errors in diagnosis might arise from the fact that pericardial thickening can produce exaggeration of the auricular impression on the œsophagus similar to that seen in mitral stenosis (Rubin, 1948), but clinical signs of the valvular lesion are absent Pericardial effusion, at one stage during its absorption, appears to be capable of producing a similar radiological picture Thus Case 3, whose first X-ray showed a fairly large pericardial effusion, was reported as a case of mitral stenosis by the radiologist when his second X-ray was examined, there was, however, never any clinical justification for this diagnosis, and the radiological signs that simulated mitral stenosis had vanished completely a month later Case 4 was also regarded incorrectly as having mitral stenosis by two independent radiologists

In these circumstances Case 2 of the present series is all the more remarkable, and appears to be unique This boy had atypical rheumatism at the age of 11, there was no sore throat and pains were confined to the metatarso-phalangeal and hip joints Three years later he had a second attack identical with the first, but on this occasion endocardial murmurs were recognized in the mitral area He was referred to the outpatient department after 8 weeks when he had a mid-diastolic mitral murmur with slight prominence of the left auricle and the pulmonary artery radiologically There was also an active primary Ghon lesion with hilar gland enlargement on the right side, and early secondary infiltration of the base of the right upper lobe Pericarditis appeared a week later, while he was under observation in hospital, it was not accompanied by any disturbance in temperature or pulse rate, and symptomatically it resembled a tuberculous as opposed to a rheumatic pericarditis, it occurred at a time when there was ample evidence of active tuberculosis (radiological,

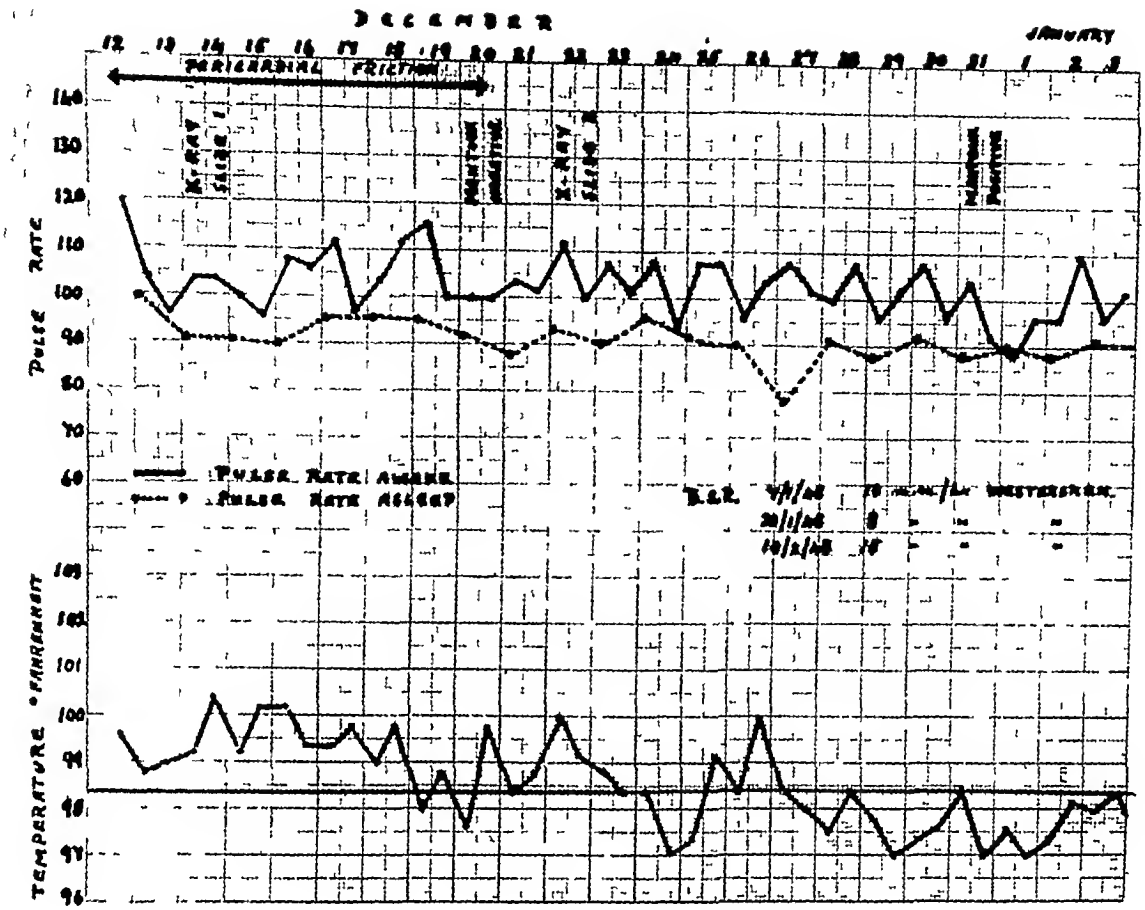

FIG 12 —Case 1 Temperature and pulse chart

skin reactions, and lymphocytosis), while there had been no symptoms of active rheumatism for two months There can be little doubt that the pericarditis was tuberculous Six months afterwards, the classical presystolic murmur of mitral stenosis was present The nature of the endocarditis is open to greater doubt It might be argued that the atypical rheumatism was in reality an example of tuberculous rheumatism, and that the endocarditis was likewise tuberculous However the first attack of joint pains had occurred three years previously, and the mitral stenosis was more consistent with a 3-year than an 8-week history, whereas the Ghon lesion was undoubtedly his primary tuberculous infection and is unlikely to have been present for more than a few weeks I believe therefore, that this boy had a rheumatic endocarditis with tuberculous pericarditis secondary to his Ghon lesion

With the exception of the foregoing case, signs of endocarditis were never found in the series, and none of the remaining patients gave a history of rheumatic manifestations

COURSE AND PROGNOSIS

The presence or absence of tubercle bacilli in the pericardial fluid is of the utmost importance in prognosis Harvey and Whitehill (1937) had a mortality of 83 per cent in their 37 bacteriologically proved cases, Blalock and Levy (1937) also quote a mortality of 83 per cent in a series of 24 bacteriologically proved cases Contrasting with this, the death rate was only 6 per cent in Harvey and Whitehill's 34 bacteriologically negative cases, which resembled their proved cases in all other respects None of the latter group showed signs of pericardial constriction on discharge from hospital Seventeen were followed for periods varying from six months to seven years one developed signs of adhesive mediastinitis with portal obstruction seven years after having made an apparently complete recovery,

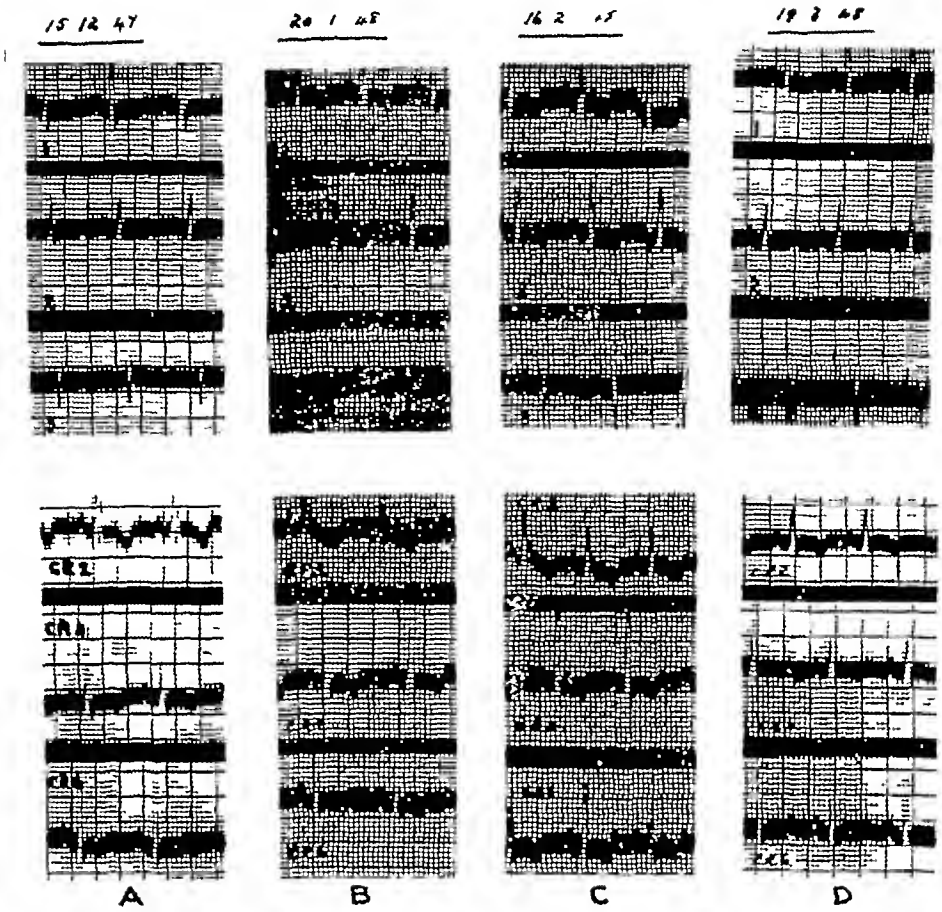

FIG 13 —Case 1 Serial electrocardiograms (A) 15/12/47 (B) 20/1/48 (C) 16/2/48 (D) 19/3/48

two developed tuberculous lesions elsewhere, nine remained well Ellman (1945) also believes that the disease may become arrested during its course, and that some cases result in a cure at the stage when the effusion has been absorbed

Two cases in the present series were bacteriologically proved, tubercle bacilli being recovered from the pericardial fluid in one that proved fatal in 12 months, and from the pleural fluid in one whose subsequent fate is unknown Of the remaining six cases one died, two have apparently recovered (observed for 3 years and 1 year respectively) while three are recent, two of them seemingly recovering

The various courses which the disease may pursue are well illustrated in the series In its fully-fledged form it passes through (1) a dry stage, (2) a stage of effusion, (3) a stage of absorption, and (4) a stage of pericardial constriction Case 4 was observed through all four stages, he was admitted with a dry pericarditis of obscure ætiology and he developed an effusion while under observation, although the effusion absorbed completely before his discharge from hospital he had signs of commencing pericardial constriction in the shape of persistent enlargement of the liver, during the ensuing three months venous distension and œdema appeared and liver enlargement increased A pericardectomy was followed by a pleural effusion and gave no immediate relief, though there was temporary improvement two months later, nevertheless he relapsed and died six months after the operation Case 5 illustrates an alternative course that may be followed as the disease becomes chronic This patient developed a pericardial effusion suddenly while he was convalescent from a tuberculous pleurisy, tubercle bacilli being recovered from the pericardial fluid, the effusion gave rise to venous distension, œdema and liver enlargement At first it was possible to aspirate up to 500 ml from a single puncture, but as time went on the effusion became loculated so that only a few ml could be obtained from any one puncture The cardiac failure became

chronic and he died a year after the onset of the effusion

On the other hand, arrest and cure seem to be possible either before the development of an effusion or after its absorption Case 6 had pericarditis without demonstrable pericardial effusion on two occasions in 1943–4 in the interval he had a right-sided pleural effusion and co-incidentally with the second attack of pericarditis he had a left-sided pleural effusion He appears to have made a complete recovery, examination three years after the second attack failed to reveal any abnormality in the heart or lungs Case 3 had tuberculous pleural and pericardial effusions in May 1947 he made a relatively rapid recovery, returning to work in September 1947, examination in May 1948 showed no evidence of any residual lesion Of the more recent cases, one (Case 3) seems to have become arrested after a dry stage without effusion, and one (Case 1) shows no cardiac lesion six months after an effusion with myocardial involvement One case was lost sight of when she was transferred to a tuberculosis hospital in accordance with service regulations The remaining case is still under observation with a pericardial effusion which has persisted for three months

The rapidity with which a tuberculous effusion can make its appearance is worthy of mention Case 3 was seen one evening with pericardial friction his apex impulse was well-defined and localized, 9 cm from the midline, the cardiac percussion dullness was not increased, Fig 7 was obtained on the following forenoon when he was admitted to hospital The rate of absorption is very variable, in Case 3 the effusion had almost completely absorbed in three weeks (Fig 8), in Case 5 there was still effusion after eight months despite repeated aspirations

The features of the chronic constrictive stage have been adequately described by many authors (Pick, 1896, Volhard and Schmieden, 1923, Beck, 1931, White, 1935, Hannesson, 1941, Sellors, 1946), and are outwith the scope of this article I would agree with Ellman in suggesting that many patients with constrictive pericarditis who give no history of an acute attack have in fact had such an attack, which has been overlooked because of the mildness of the constitutional symptoms This appears to apply with particular emphasis to those where pericarditis accompanies a primary Ghon lesion, in which subjective symptoms are particularly mild Thus Case 2 was symptom-free Case 1 had a pressure cough as his only subjective symptom, I have frequently heard equally severe coughs in children going about the streets, many of whom probably fail to come under medical supervision at all I have found only one reference to pericarditis complicating an active primary Ghon lesion, and the circumstances are entirely different from those of the present cases Seligman and Lederer (1940) describe a case in which a secondary hæmolytic streptococcal infection gave rise to an abscess that ruptured into the gland draining a Ghon focus, the gland in turn ruptured into the pericardium producing a suppurative pericarditis The symptoms in their case were dramatic, simulating either a coronary occlusion or a perforation of an abdominal viscus, the illness was fatal

Treatment

Conservative treatment has been employed in most of this series during the acute stage One (Case 5) who had a persisting pericardial effusion with chronic cardiac tamponade, was repeatedly aspirated in addition to receiving digitalis and mercurial diuretics, he died in 12 months One other (Case 8), an infant, has had aspiration attempted unsuccessfully, his effusion is slowly absorbing One case was transferred elsewhere for treatment The remaining five have been treated conservatively, two are well after 3 years and 1 year respectively, two are convalescent and free from signs of effusion or pericardial thickening after six months, one developed pericardial constriction for which operation was undertaken, but he died six months after the operation

Treatment by aspiration and air replacement (artificial pneumo-pericardium) is being recommended by some authors, assessment of the value of this procedure will have to await more precise knowledge of the recovery rate in cases treated on purely conservative lines, a rate which would appear to be greater than has hitherto been admitted

Summary

The incidence of acute tuberculous pericarditis has been underestimated in this country hitherto It arises in the early stage of dissemination of tuberculosis it may be found with the primary Ghon lesion, with an apparently primary tuberculous pleurisy, or in absence of any demonstrable lung or pleural lesions Infection of the pericardium takes place by spread from the adjacent lymph glands Constitutional symptoms are mild, sometimes insufficient to lead the patient to seek medical advice, owing to the mildness of symptoms, the diagnosis is apt to be unsuspected Evidence of myocardial involvement was obtained in one case out of eight

The disease passes through fibrinous, effusive, and constrictive stages, but it may become arrested and apparently complete recovery may occur

either before the development of an effusion or after its absorption The effusion may become chronic and loculated giving rise to chronic cardiac tamponade, alternatively absorption of the effusion and apparent recovery may be followed by the development of constrictive pericarditis The prognosis is extremely poor in cases from whose pericardial effusion tubercle bacilli are isolated, but with a sterile effusion the prognosis is hopeful Recoveries are by no means uncommon with conservative treatment, care is therefore required in assessing claims for specific therapeutic measures

Appendix

Case 1 M aged 11 Health good till November 1947 when harsh cough developed and widespread pericardial friction found, temperature 99° to 101° until admission 14 days later A sparely built, pale youngster, alert and active, with unimpaired appetite A harsh metallic pressure cough was his only subjective symptom throughout Friction persisted over the entire præcordial area for 23 days in all, despite a pericardial effusion of moderate size Serial cardiograms (Fig 13) showed evidence of myocardial involvement Low grade pyrexia (Fig 12) with slight tachycardia (sleeping pulse 90 to 95) X-rays (Fig 1 to 3) showed pericardial effusion and an active primary sub-pleural Ghon lesion in left upper lobe with enlargement of left hilar glands Absorption of the effusion began in 4 weeks and was complete in 6 to 8 weeks, no radiological evidence of pericardial thickening remained Venous pressure normal throughout, and signs of congestive failure absent Ghon lesion slow in resolving and still active 6 months after admission B S R (Westergren) fell from 16 to 8 mm in 6 weeks, but rose again to 18 mm /hr

Case 2 M aged 14 Pains in metatarso-phalangeal and hip joints without sore throat or involvement of remaining joints when 11, confined to bed for several weeks Identical attack September 1947 at age 14, mitral endocardial murmurs recognized Referred after 8 weeks in bed A sparely built, pale youngster, but bright, active and cheerful like Case 1, insisting that he felt perfectly well Mid-diastolic mitral murmur and pulse 110, admitted with diagnosis of rheumatic carditis Afebrile with sleeping pulse 80 (Fig 10) X-ray (Fig 4 to 6) showed active primary sub-pleural Ghon lesion in right upper lobe with hilar gland enlargement and secondary infiltration of base of right upper lobe, slight prominence of pulmonary artery and in oblique view distinct prominence of left auricle consistent with early mitral stenosis

A week after admission pericardial friction present for four days without disturbance of pulse or temperature Vollmer patch test positive Absolute lymphocytosis present (W B C 12400, lymphocytes 44%=5500) No tubercle bacilli on gastric lavage The Ghon lesion disappeared in between 3 and 4 months The secondary infiltration extended first, then receded By April 1948 there remained only a small effusion in lesser fissure with slight pleural thickening, now has a typical presystolic mitral murmur but no signs of pericardial thickening Serial cardiograms showed no characteristic abnormality

Case 3 M aged 27 Dysentery and quinsy in Army, but well and category A1 on demobilization February 1946 April 1947, noted attacks of slight præcordial pain and tightness, lasting half an hour at a time, but not preventing work as van driver After 2 weeks a more severe attack with breathlessness, muffled heart sounds and elevated temperature reported by doctor Two days later (30/4/47) pain gone, insisted he felt well, but widespread coarse pericardial friction present without cardiac enlargement or displacement of impulse, small pleural effusion present at right base On admission next day a large pericardial effusion had developed (Fig 7) There was never venous distension, liver enlargement or œdema He was virtually afebrile (Fig 11) and had no tachycardia, bradycardia during convalescence Despite effusion pericardial friction persisted several days Pleural fluid contained 1100 cells per cu mm, 86 per cent lymphocytes, no tubercle bacilli seen in films, cultures sterile Præcordial pain not severe, recurred once a week later for half an hour, otherwise he had no subjective symptoms Absorption of pleural and pericardial effusions began within 3 weeks and was complete in 6 weeks Transient enlargement of the left hilar glands (Fig 7 and 8) occurred while effusion absorbing, at this stage left auricle and pulmonary artery were prominent, and radiologist reported mitral stenosis but there was never clinical justification for this diagnosis, and radiological appearances vanished later Discharged from hospital end of June and resumed work September 1947 On re-examination in May 1948 no abnormality in heart or lungs, and symptom-free

Case 4 M aged 23 No previous illness, 2 years' active service Coryza and cough 14 days before onset On 10/8/41 pain across chest, breathlessness, increased severity of cough and intermittent headache, occasional vomiting Oedema of legs developed and lasted 5 days but had subsided when admitted to E M S hospital on 27/8/41 Pericardial friction and small pericardial effusion, pulse 100 to 110, B S.R 50 mm /hr , afebrile Left pleural effusion appeared a fortnight later, X-ray now reported to show " enlargement of heart with mitral configuration ", no endocardial murmurs detected at any time Cardiogram showed R–T elevation followed by T inversion in all limb leads Pericardial effusion absorbed a month after admission, but small right-sided pleural effusion developed By December convalescent, B S R 9 mm /hr , effusions absorbed, but liver enlargement present Discharged from army and hospital, 17/12/41

Cough, breathlessness, and œdema soon recurred Admitted to Victoria Infirmary 21/3/42 with small heart, feeble impulse, distant sounds, enlarged liver, distended neck veins, and venous pressure 24 5 cm Feeble cardiac pulsations on cardioscopy, prominence of pulmonary

artery and left auricle again noted, and a second radiologist diagnosed "mitral stenosis with pericardial thickening" Pericardial resection performed by Mr Bruce Dick on 10/4/42 was followed by jaundice, then right pleural effusion, œdema became considerable Improvement began after a month and he was up after two months On 6/10/42 he was convalescent and chest radiologically clear Four days later severe pain in left chest with breathlessness and cyanosis, pleural effusion developed rapidly and he died next day with an effusion of 2300 ml in left pleural cavity At autopsy heart was small and there was no mitral stenosis The excised pericardium showed tuberculous granulation tissue

Case 5 M aged 43 Admitted to fever hospital in spring 1935 with bilateral pleurisy, pleural fluid and sputum positive for tubercle bacilli Old apical scar on X-ray but no obvious fresh lesion After 4 months, effusions absorbed, sputum negative for tubercle bacilli, no active lesion radiologically Discharge from hospital arranged, but meantime breathlessness developed and large pericardial effusion found, aspirated several times and tubercle bacilli recovered from fluid Transferred to Victoria Infirmary two months later, afebrile with large pericardial effusion and small pleural effusion on each side, breathless, enlarged liver, ascites, and slight œdema. Pericardium aspirated on two further occasions, no tubercle bacilli found, yet tuberculosis of larynx and palate developed 5 weeks after admission Paroxysmal auricular fibrillation appeared, and œdema became gross requiring Southey's tubes as well as salyrgan Oedema cleared but heart size remained unchanged and effusion was now loculated so that only 15 to 30 ml could be withdrawn from any single puncture Throat also improved and sputum was negative Three months after transfer he was up and allowed home prior to entering a sanatorium where he died three months later, the circumstances of his death are not known

Case 6 M aged 15 History of sore throats periodically but no acute rheumatism July 1943 fell from bicycle striking chest against pavement, but seemed none the worse after October 1943 developed præcordial pain and fever, doctor reported cardiac irregularity, was kept in bed 3 weeks and referred a week later A thin youngster with unhealthy tonsils, "pink and white" complexion, but no clinical signs of heart disease, heart shadow and lung fields normal radiologically, poor voltage QRS in cardiogram, B S R 32 mm /hr Westergren. Regarded as convalescent from acute pericarditis and sent to E M S hospital

Improved slowly and B S R dropped to 3 mm /hr after 10 weeks Tonsillectomy on 11/2/44 followed by severe hæmorrhage requiring transfusion. On 28/2/44 he had pain in right side of chest with fever (T 103°), and signs of patchy consolidation followed by a massive effusion, the fever failed to respond to sulphonamides The pleural fluid contained lymphocytes and polymorphs in equal numbers and was negative on examination for tubercle bacilli After aspiration resolution was rapid, a trace of fluid remained in right costo-phrenic angle when discharged from hospital on 4/4/44, having gained 15 lb in weight

Twelve days after discharge he had slight staining of sputum with tiredness, flatulence, and a little pallor, but no fresh clinical or radiological findings in heart or lungs, and weight was maintained A month later again tired, listless, off his food, breathless, and slight cough, fainted, when next seen on 8/6/44 pericardial friction and left pleural effusion found. Readmitted for 5 weeks

Well since, though there is mild effort syndrome and occasional tendency to faint On 30/10/47 no abnormality in heart or lungs clinically, cardiogram physiological, on X-ray, heart shadow a little displaced to left but otherwise normal, traces of former pleurisy at left base without any remaining fluid, and slight residual fibrosis on right side Tuberculous ætiology in this case is unproved but seems highly probable

Case 7 F aged 20 A girl, serving in the W A A.F, previously healthy, admitted with acute pleurisy, febrile and flushed with tachycardia and signs of large right-sided pleural effusion Pericardial friction noted on admission, and pericardial effusion appeared a day or two later Pleural exudate was lymphocytic and positive for tubercle bacilli Transferred to a service tuberculosis hospital and further course is unknown.

Case 8 M aged 18 months Acute poliomyelitis at 13 months, September 1947, involving left arm and leg Admitted orthopædic unit 29/10/47 Leg recovered during next two months but arm remained paralysed and in abduction plaster splint Cough with signs of bronchitis noted from time to time

February 1948, listless and refused food, large pericardial effusion found on X-ray, no abnormality in lung fields Transferred to medical ward under Dr A M Scott A well nourished youngster, pale, but mentally alert, heart sounds distant, no friction heard, liver enlarged, two finger-breadths below costal margin on admission, down to umbilicus six weeks later There was no œdema, breathlessness, nor distension of neck veins He was virtually afebrile, a temperature of 100° having been recorded on two occasions and 99° once, pulse 110 to 120 Cardiogram shows low T waves in leads I and II with inverted T III, and left axial deviation Mantoux test negative on 1/3/48 and 26/4/48 An attempt to aspirate pericardium on 5/4/48 yielded blood only X-ray appearances remained unaltered until 25/5/48 when commencing absorption of effusion was noted, it has now reappeared (July 1948) with œdema of arms and legs

He is still under observation Tuberculosis is suspected as the cause, but is as yet unproved.

REFERENCES

Barrett, A M, and Cole, L (1944) *Brit Heart J*, **6**, 185
Beck, C S (1931) *J Amer med Ass*, 97, 824
Blalock, A, and Levy, S E (1937) *J Thoracic Surg*, **7**, 132
Blatt, M L, and Greengard, J (1928) *Amer J Dis Child*, **35**, 631
Clarke, J A, Jr (1929) *Amer J med Sci*, **177**, 115
Ellman, P (1945) *Brit Heart J*, 7, 147
Fine, M J, and Katz, S (1944) *Dis of Chest*, **10**, 60
Hannesson, H (1941) *Tubercle*, **22**, 79
Harvey, A M, and Whitehill, M R (1937) *Medicine*, **16**, 45
Heimann, H L, and Binder, S (1940) *Brit Heart J*, **2**, 165
Norriss, G W (1911) *Cardiac Pathology*, Saunders, Philadelphia
Osler, W (1893) *Amer J med Sci*, **105**, 20
Pick, F (1896) *Zeit klin med*, **29**, 385
Riesman, D (1901) *Amer J med Sci*, **122**, 6
Rubin, E L (1948) *Rep proc Liverpool med Inst*, *Brit med J*, **1**, 513
Seligman, B, and Lederer, M (1940) *New York State med J*, **40**, 130
Sellors, T H (1946) *Brit J Surg*, **33**, 215
Suzman, H (1943) *Brit Heart J*, **5**, 19
Volhard, F, and Schmieden, U (1923) *Klin Woch*, *ii*, 5
White, P D (1935) *Lancet*, **2**, 539 and 597

ABSTRACTS OF CARDIOLOGY

The Coronary Circulation O D RATNOFF and M PLOTZ *Medicine, Baltimore*, 25, 285–342, Sept., 1946

A review of previous work on the coronary circulation, e g various factors affecting coronary flow, the nervous control and the pharmacology of the coronary circulation, and the coronary blood flow in disease Because of the lack of methods suitable for application to man or even to intact animals, the coronary circulation has been studied mainly on isolated animal hearts or heart-lung preparations The results so far are therefore mainly of academic interest The authors point out that differences in anatomy and physiology of the coronary vessels among various species as well as among individuals of the same species have not hitherto been adequately stressed Discretion must be used in applying information derived from artificial preparations to the intact animal, from species to species and even among individuals of the same species Conclusions with regard to human coronary physiology have been drawn freely from animal experiment *R. T Grant*

Cardiac Murmurs in Infancy N Cox *Brit med J*, 1, 148–150, Jan 24, 1948

In a preliminary report on the significance of cardiac murmurs in infancy the author records observations on 630 ostensibly healthy children examined at the ages of about 6 weeks, 3, 6, 9, and 12 months, and thereafter at 6-monthly intervals, most of them for about 3 years Regular 6-monthly radiographic examinations were made in all children Thirty-two (5%) had murmurs which were classified according to the age when first noticed and are described as transient, temporary, or persistent No diastolic murmurs were observed Of the 32 murmurs 23 were not detected until after the child was 9 months old There was a relatively greater number of transient murmurs among infants observed in the early weeks of life Six out of 8 murmurs appearing at the age of 18 months remained permanent. With the exception of 2 cases, no associated symptoms or signs could be observed No correlation between clinical findings and radiographic appearances could be established The results are as yet too few to allow any conclusions to be drawn *H Herlinger*

Syndrome of Aberrant Right Subclavian Artery with Patent Ductus Arteriosus H P BREAN and E B D NEUHAUSER *Amer J Roentgenol*, 58, 708–716, Dec, 1947

Aberrant right subclavian artery is the most common congenital anomaly of the aortic arch In such cases the right subclavian artery emerges from the extreme left side of the aortic arch, posteriorly and to the left of the origin of the left subclavian The aberrant vessel runs obliquely upwards and to the right, usually passing behind the œsophagus as it crosses the midline This anomaly is often accompanied by other congenital anomalies of the large vessels at the base of the heart Five cases of this syndrome are reported, 3 were accompanied by a patent ductus arteriosus, 1 by a tetralogy of Fallot, and 1 by a cardiac anomaly of uncertain nature The radiographic features of anomalous right subclavian artery and of patent ductus arteriosus are reviewed and the value of a barium "swallow" during the radioscopic examination of the heart is stressed *A Orley*

The Syndrome of Thrombotic Obliteration of the Aortic Bifurcation R LERICHE and A MOREL *Ann Surg*, 127, 193–206, Feb, 1948

Thrombotic obliteration of the aortic bifurcation must not be confused with the well-known "saddle embolism" Important features are said to be (1) sexual disturbances —poor erection and ultimate impotence, (2) intermittent claudication due to fatigue in the limbs rather than to actual pain, (3) symmetrical atrophy and pallor of both legs, (4) no pulses at groins or below, (5) no oscillometric readings in lower limbs, (6) ultimately gangrene Aortography may be used to confirm the diagnosis

Treatment is aimed at (1) Excision of the thrombotic segment to prevent spread of clot and production of vasoconstrictor impulses (2) Improvement of collateral circulation in the lumbar region by high lumbar ganglionectomy In good-risk patients this should be accomplished by excision of the thrombosed aortic segment and obliterated branches through a left iliac incision Left lumbar ganglionectomy is performed at the same time, and upper right lumbar ganglionectomy at a later stage If the condition is due to thromboangiitis obliterans unilateral adrenalectomy is advised In poor-risk patients ganglionectomy should be performed first and aortectomy later if the patient's condition will allow *J B Kinmonth*

A New Anomaly of the Aorta Left Aortic Arch with Right Descending Aorta. R N PAUL *J Pediat*, 32, 19–29, Jan, 1948

From Johns Hopkins University, the author reviews the common anomalies of the aorta, classifying them and commenting on some, with particular reference to 2 cases of a previously unreported anomaly, that of left aortic arch with right descending aorta.

He differentiates between right aortic arch with right descending aorta and right aortic arch with retro-œsophageal aorta (right and left) He describes the

double aortic arch and comments on the common variations in the subclavian artery He then presents, in great detail, his cases of the new anomaly Each patient had been considered to have the tetralogy of Fallot, and both were candidates for the Blalock-Taussig operation

The first, a 7-year-old white female gave a history of cyanosis from early infancy and extreme dyspnœa on the slightest activity Radioscopy of the œsophagus showed (1) indentation of the left margin by the aortic arch, establishing the fact that a left-sided arch existed, (2) absence of any vascular or cardiac shadow to the left of the barium column between the aortic knuckle and the upper left border of the heart, (3) descent of the œsophagus far to the left of the midline At operation the course of the aorta was demonstrated, but no anastomosis was performed as the pressure in the pulmonary artery was considered too great The second, an 11-year-old white male, had had cyanosis from the age of 1 Radiographs had the same characteristics as in Case 1 An anastomosis was performed, but the course of the aorta could not be clearly demonstrated, though by inference this case appears to have also been one of left aortic arch with a right descending aorta

Morag L Insley

The Surgical Relief of Severe Angina Pectoris Methods Employed and End Results in 83 Patients J C WHITE and E F BLAND *Medicine, Baltimore*, 27, 1–42, Feb, 1948

This paper reviews the methods of interrupting the afferent pain fibres from the heart in cases of angina pectoris, and presents the clinical results in 83 cases

The methods available are (1) Paravertebral injection of procaine followed by 95% ethyl alcohol around the upper four thoracic sympathetic ganglia (2) Sympathetic ganglionectomy The stellate and upper three thoracic ganglia are resected extrapleurally on one side only, the other side being dealt with later if necessary (3) Posterior rhizotomy The upper four thoracic posterior spinal nerve roots are sectioned on both sides This is undoubtedly the most effective way of cutting off all afferent impulses from the heart at one operation, but it is a major and time-consuming operation and carries the risk of ischæmic transverse myelitis

Surgical treatment should be reserved for those whose pain, after adequate observation, cannot be controlled effectively on a medical regime, and especially for angina decubitus Patients with good cardiac reserve and bilateral pain are suitable for laminectomy and thoracic root section For patients in whom the risk is slightly greater, with unilateral pain, thoracic ganglionectomy is preferred Where the risk is very great, paravertebral block with alcohol is the only possible routine

Clinical results in 75 patients treated with paravertebral alcohol block are reviewed, 56% were completely relieved of pain, in 21% partial relief only was obtained, 8% died as a direct result, 10% developed severe intercostal neuralgia Of the group in whom initial results were good there was recurrence of pain due to recovery of nerve conduction in 19% after periods varying from 2 months to 5 years Eight cases have been treated by left-sided thoracic ganglionectomy Complete relief of pain on the denervated side was obtained in all There was 1 death (from empyema) In 1 case there was slight recurrence of pain after 6 years, due to nerve regeneration One patient was treated by posterior root section with complete relief

Although the number of cases is not large enough to be statistically significant, results show that prognosis as regards life in cases of severe angina is not altered by cardiac denervation In angina decubitus with loss of sleep, worry, and threatened drug addiction relief from pain and anxiety has been effective After complete division of all afferent nerves the place of anginal pain as a warning signal is taken by constriction or oppression referred to the suprasternal notch, and painless dyspnœa Occasionally a pain referred to the jaw of the same side becomes evident, the mechanism of this is not understood The authors consider that thoracic ganglionectomy should be the operation of choice whenever possible

F B Cockett

The Efficiency of Maintenance Doses of Digitalis in Preventing the Recurrence of Congestive Heart Failure. J S LAUDE and S B CARTER *Ann intern Med*, 27, 923–928, Dec, 1947

Doubt is cast upon the value of estimations of the vital capacity, circulation time, venous pressure, and body weight as indications of the extent of cardiac reserve in patients who have been safely brought through a phase of congestive heart failure It would appear that a careful evaluation of symptoms and clinical signs is a better guide Patients who have been relieved of congestive heart failure, even with regular sinus rhythm, should always be placed upon maintenance courses of digitalis leaf The present study of 104 patients shows that patients given such maintenance doses are much less likely to relapse than are similar patients not given maintenance doses A suggested maintenance dose is 0 1 to 0 3 g of digitalis leaf daily

G F Walker

Lanatoside C in the Treatment of Persistent Paroxysmal Auricular Tachycardia. A S WEISBERGER and H FEIL. *Amer Heart J*, 34, 871–877, Dec, 1947

In a series of cases of persistent paroxysmal auricular tachycardia, the tachycardia ceased abruptly within 40 minutes after the intravenous injection of 0 8 mg "lanatoside C" No toxic reactions or undesirable side-effects occurred

R T Grant

Hyperpiesis with Atheromatous Obstruction of the Renal Arteries G T COOK and R S B PEARSON *J Path Bact*, 58, 564–567, Sept, 1946

This is a brief single case report of a 29-year-old man with developmental anomalies and hypoplasia of the vascular system, who showed severe hypertension (300/150 mm) and cardiac failure (heart weighing 560 g.), although the histological changes in the kidneys were very slight. The right subclavian and right common carotid arteries showed recanalization following complete obliteration No changes were noted in the fundi, and the Wassermann reaction was negative Comparison is made with the results of experimental occlusion of renal arteries

A C Lendrum

Differential Diagnosis of Retrocardiac Shadows S S NEMEC *Radiology*, 50, 174–183, Feb, 1948

The most obscure thoracic lesions are those in the retrocardiac space where there is ample room and where consequently a lesion may reach considerable size before it causes clinical signs of compression Retrocardiac shadows may be produced by lesions of the œsophagus, stomach, lungs, spine, paravertebral tissues, and aorta The author describes a diagnostic sign consisting of multiple convex lines within the cardiac shadow, indicating the presence of the stomach in the retrocardiac region. He also describes a simple double-contrast method (gas-distension of stomach and barium filling of œsophagus) for the study of the cardio-œsophageal junction and of the relation of the lower third of the œsophagus to the stomach Finally, the author asserts that a diagnosis of asymptomatic retrocardiac lesions may be made from observation of abnormal retrocardiac shadows in routine radiographs of the chest *A Orley*

Penicillin in Subacute Bacterial Endocarditis Report to the Medical Research Council on 269 Patients Treated in 14 Centres Appointed by the Penicillin Clinical Trials Committee R V CHRISTIE. *Brit med J*, 2, 1–4, Jan 3, 1948

Penicillin can now be expected to control the infection in about 90% of patients suffering from subacute bacterial endocarditis, but about 35% of these die of heart failure or other complications

Early schemes of treatment showed that, at least with smaller courses of penicillin, such as a total of 5 million units, the duration of treatment was of greater importance than the amount of penicillin given daily For this reason, in a later group of 158 previously untreated patients, the duration of treatment was established at 28 days—of 17 who received 100,000 units daily, 7 relapsed or died of infection, of 83 receiving 250,000 units daily 13 relapsed, and of 58 who received 500,000 units daily 4 relapsed Only occasionally can failure be explained as due to a highly resistant organism, but when the coefficient of resistance of the organism is more than about 8, it is important to give larger doses, possibly over an extended period

Of 42 patients who had relapsed after a long course of treatment, 59% again relapsed or died infected Acquired resistance to penicillin is seldom an important factor in this high incidence of failure, it may be that these patients belong to a naturally resistant group or that the infecting organisms are buried in avascular tissue A course of 2 million units a day for 8 weeks is suggested for patients who have relapsed Relapses seldom occur more than a month after treatment, but a small risk remains even after a year or more of good health It is sound practice to remove foci of infection, particularly in the teeth, while the patient is receiving penicillin The majority of deaths occurred either during treatment or soon after its completion Heart failure caused 40% of the deaths and was a major factor in another 16% At necropsy apparently living organisms were found in the heart valves of one-third of those whose infection, according to the usual clinical criteria, had been controlled

In prognosis the nature of the initial endocardial lesion is of slight importance, the highest death rate was found in combined aortic and mitral lesions, and the lowest in septal defects Evidence of heart failure is much more significant, in a group of patients where this was absent 36 4% died, of those with moderate failure 75% died, and of those who had severe heart failure when treatment was started all died Of those recently infected 34% died, while of those infected for 6 months or more over 60% died The state of nutrition is another significant factor, this emphasizes the need for an adequate calorie intake as with other prolonged fevers Only in the group over 50 should age influence the prognosis *T Semple*

Further Observations of Prothrombin Determinations and Vitamin K Therapy in Acute Coronary Occlusions H McG DOLES *Sth med J*, 40, 965–973, Dec, 1947

The author carried out frequently repeated determinations of prothrombin level in 64 cases of acute coronary occlusion and in 657 controls free from coronary disease, and found significant hypoprothrombinæmia in the coronary cases—that is, with a level below 70% of normal This stage is considered as heralding an episode of bleeding in general, and of coronary subintimal hæmorrhage in particular, thus precipitating coronary thrombosis The frequent relation between gall-bladder disease and coronary disease, with the known hypoprothrombinæmia in the former, is commented upon Cases of coronary occlusion were treated with intramuscular doses of vitamin K (50 to 72 mg every 6 to 8 hours) until the prothrombin level reached 100% of normal Rapid cessation of pain under this regime was observed In some cases prothrombin levels of 100% of normal were encountered immediately after the onset of the coronary occlusion, but in these cases a fall of from 30 to 50% below the first reading was encountered 6 to 8 hours later The initial high level in these cases is regarded as a compensatory mechanism that becomes exhausted within a few hours A mortality rate of 4% in this series is arrived at by excluding 8 patients dying before adequate treatment could be given and 3 whose treatment was considered inadequate The author makes no attempt to reconcile his claims with those of workers who use heparin and dicoumarol *G Schoenewald*

Complications of Blood-letting in Hypertension L WALTERSKIRCHEN *Wien klin Wschr*, 59, 822–824, Dec 19, 1947

In recent years venesection has been less used in the treatment of hypertension, and is now condemned by many authorities as dangerous Angiospasm, angiospastic hemiplegia, and collapse are some of its dangers Two cases are reported in which electrocardiographic findings are given before and after venesection in hypertensive patients with anginal symptoms From these findings and from experimental data it is concluded that venesection may lead to acute coronary insufficiency by causing a sudden fall in aortic pressure The prognosis in these cases is otherwise better than in patients who have anginal symptoms with a low blood pressure *Harold Jarvis*

Tetraethyl Ammonium Bromide in Hypertension and Hypertensive Heart-failure G W HAYWARD *Lancet*, **1**, 18–20, Jan 3, 1948

Tetraethylammonium bromide (T E A B) was given by slow intravenous injection in a 10% solution in doses of 0 3 to 0 5 g (4 to 6 mg per kilo body weight) The effects were compared with those of "sodium amytal" in a preliminary group of 30 patients with essential hypertension With T E.A B the average fall in blood pressure was 58 mm Hg systolic and 28 mm diastolic, with sodium amytal it was 74 mm and 35 mm, respectively T E.A B produced no ill effects, and its action was transient Ten patients were operated on (removal of sympathetic chain and ganglia from D6 to L1), and in 7 cases pre-operative depression with T.E A B agreed to within 10 mm Hg with diastolic depression recorded 2 weeks after completion of the second stage of the operation Sodium amytal gave similar agreement in 9 cases Four patients were further investigated after operation, and in each case T E A B gave a level lower than that in the pre-operative test. Six patients with hypertensive heart failure were treated with T E.A.B, some by intramuscular injection of 1 g All patients showed temporary subjective improvement, often for some hours Electrocardiograms showed no change, and no cardiac pain or infarction has been reported after injections The speed and safety of the test with T E A.B is not associated with an accuracy equal to that of the sodium amytal test, and this is attributed to the fact that the former drug produces only partial ganglionic paralysis, as indicated by its increased action after sympathectomy The beneficial effects of T E A.B in hypertensive heart failure are attributed to decrease in pulmonary congestion similar to that following venesection, and last 2 to 8 hours after intramuscular injection Since venous pressure falls in hypertensive cases to an equal extent with or without failure, the fall is considered to be due to a lowering of peripheral resistance The drug is thus of use in the emergency treatment of acute left ventricular failure or paroxysmal nocturnal dyspnœa In the treatment of chronic congestive failure the fall in urinary output which results from the lowering of blood pressure makes its use inadvisable at present *W A Bourne*

Paroxysmal Diaphragmatic Flutter with Symptoms Suggesting Coronary Thrombosis. F H MOORE and C SCHOFF *Amer Heart J*, 34, 889–893, Dec, 1947

A brief description is given of a patient suffering from severe anginal pain associated with flutter of the diaphragm On præcordial auscultation a loud booming noise was heard, its frequency being about 200 a minute, palpation of the lower thorax conveyed a marked throbbing sensation synchronous with the sounds On radiological examination both leaves of the diaphragm were seen to be fluttering rapidly, in time with the palpable impulses and the sounds Morphine, gr ¼ (16 mg), relieved the anginal pain but the flutter continued, this ceased several hours later and did not recur The patient, a psychopath, was recognized as the individual who, under various aliases, had been admitted to other hospitals with the same complaint from time to time since 1936 References are given to 4 other published accounts of the case *R T Grant*

Radiological Differentiation between Pericardial Effusion and Cardiac Dilatation. J ARENDT *Radiology*, **50** 44–51, Jan, 1948

The pericardial space in health is fairly lax and has an appreciable capacity for accumulating fluid without presenting the characteristic contours When accumulation is rapid, the cardiac contours are obliterated and the spherical form with a short pedicle is seen Slow accumulation of fluid gives time for some accommodation of the pericardium and then differentiation from cardiac dilatation may not be easy The author has found Valsalva's test followed by forced expiration a useful means of differentiation The dilated heart responds, first by becoming smaller, and then by notable increase in size with enlarged amplitude of pulsation In the presence of a pericardial effusion there is little or no variation in size or visible behaviour The bifurcation of the trachea may be a further useful index In cases of dilatation, especially when the left auricle is enlarged, the bifurcation angle is widened from the normal 75 degrees to over 100 degrees When enlargement of the heart shadow is due to fluid there is only slight widening, if any A further useful point is that, in the latter condition, fluid tends to obscure the carina, while in cardiac dilatation the bifurcation is usually clearly visible Pericarditis with effusion may displace the barium-filled œsophagus to a disproportionately slight extent and the curvature is wide and smooth. The dilated heart is likely to displace and impress the œsophagus more definitely, the impression being sharper and of a more localized nature Kymography may give more precise evidence of the diminution in pulsation occasioned by fluid *A M Rackow*

Roentgen Demonstration of Calcifications in the Interventricular Septum in Cases of Heart Block F WINDHOLZ and C GRAYSON *Amer J Roentgenol*, 58, 411–421, Oct, 1947

Calcification in the membranous septum of the heart, sometimes associated with heart block, can be demonstrated radiologically The authors' views are based on 61 patients who showed radiological calcification in the mitral or aortic rings, of these, 12 had some degree of heart block In the left oblique view the mitral ring is projected in its most open form and the posterior limb, when calcified, clearly shown The authors regard as evidence of probable septal involvement (1) caudal extension of aortic ring calcification (see in 2 cases with heart block), (2) complete calcification of the mitral ring (see in 8 cases with heart block), (3) incomplete calcification of the mitral ring with an aggression of calcium at the medial end of the posterior limb (see in 2 cases of heart block) The last type was observed also in cases without heart block, and is considered to be a less specific sign than the first two *A M Rackow*

Chronic Auricular Fibrillation. Its Treatment with Quinidine Sulfate. R L McMillan and C R Welfare *J Amer med Ass*, **135**, 1132–1136, Dec 27, 1947

This paper, based on a study of 50 unselected cases, is a plea for a wider use of quinidine sulphate In the authors' view the only definite contraindications to its use are severe conduction defects, subacute bacterial endocarditis, and angina pectoris, previously relieved by the onset of fibrillation All their patients were admitted to hospital and complete digitalization was effected before quinidine therapy was instituted An average increase of 270 ml in vital capacity followed return to normal rhythm in 18 patients, and an average decrease in venous pressure of 20 mm of saline solution in 13 patients The average decrease in circulatory time in 14 patients was 6 7 seconds After a test dose of 0 2 g, quinidine was given every 4 hours day and night The dosage began at 0 5 g and was increased by 0 2 g every 12 hours until normal sinus rhythm occurred, toxic symptoms appeared, or 0 8 g was reached Further increase of dosage was slow, usually by 0 1 g per dose every 24 hours After reversion to normal rhythm quinidine was given in the same dosage at 6-hour instead of 4-hour intervals

In 35 patients for whom a satisfactory maintenance dosage was worked out, the average amount necessary for reversion was 0 45 g every 4 hours, and the average maintenance dose was 0 28 g every 6 hours Sinus rhythm was restored in 44 patients, of whom 14 had maintained normal rhythm for from 4 months to 2 years, half of them being on maintenance doses of quinidine In the 5 cases of thyrotoxic heart disease treatment was unsuccessful until hyperthyroidism had been corrected Apart from the 2 patients under 20, best results were obtained in the 40-to-49-year age group, in rheumatic heart disease, and in those in whom the adequate 4-hourly dose did not exceed 0 3 g It is claimed that restoration of normal rhythm may do much to prevent the development of a cardiac neurosis Eleven of the 50 patients studied died, during the time of observation which was apparently a period of 2 years

The authors consider that this study indicates that much larger doses of quinidine sulphate may safely be administered than has been thought practicable [It is obvious (as in the 3 fatal cases quoted) that the range of patients treated was much wider than that considered suitable by most British cardiologists]

Donald Hall

Blood Volume in Congenital Heart Disease. D E Cassels and M Morse *J Pediat*, **31**, 485–495, Nov, 1947

A shunt occurs in cases of auricular and ventricular septal defect, and in patency of the ductus arteriosus These communications should have an effect on the circulation similar to that of a peripheral fistula, initiating an accessory circulation that requires a certain volume of blood to fill it Theoretically this blood can be supplied by (1) reduction of blood flow distal to the fistula, (2) increase in total blood volume, or (3) both

Several investigators have found an increased blood volume in patients with arteriovenous fistulæ The present authors contribute blood volume estimations (by the blue-dye method of Gibson and Evans) on normal children and patients with congenital heart disease The latter were studied in three general groups (1) patent ductus arteriosus, (2) acyanotic congenital heart disease, not including coarctation of the aorta or aortic stenosis, since abnormal shunts do not occur in these cases, (3) cyanotic congenital heart disease of varying type In 13 patients with uncomplicated patent ductus the blood volume was elevated—considerably in 4, while 1 had a blood volume below the mean normal In 7 of 8 instances where the blood volume was estimated before and after ligation there was a decrease in blood volume following surgery The blood volume in acyanotic intracardiac arteriovenous shunts was elevated by a smaller amount. It is tempting to attribute this to the smaller volume of blood passing through the fistula, since in intracardiac shunts the flow is probably intermittent, while in extracardiac shunt the flow is continuous, though uneven In the cyanotic type of congenital heart disease blood volume was greatly increased, the increased red cell volume being usually associated with diminished plasma volume This resulted in a rise in viscosity

M Baber

AUSCULTATION OF THE HEART*

BY

SAMUEL A LEVINE†

From the Medical Clinic of the Peter Bent Brigham Hospital and the Department of Medicine of the Harvard Medical School, Boston, Massachusetts

Received July 21 1948

Advances in our knowledge of heart disease in recent decades have generally been the result of the introduction of new techniques, either diagnostic or therapeutic The discovery of the string galvanometer by Einthoven and the pioneering work of Sir Thomas Lewis in the field of electrocardiography clarified many problems of cardiac physiology and helped particularly to elucidate the various disturbances in the mechanism of the heart beat Later the work of F N Wilson enabled us to resolve many aspects of heart muscle injury and added greatly to the diagnostic accuracy of myocardial infarction and other types of cardiac pathology The increased use of the X-ray obviously facilitated the study of heart disease by portraying the actual size, movements, and configuration of the heart its various chambers, and the neighbouring blood vessels A further advance was made mainly by Sosman when calcified valves were visualized in living patients Quite recently the electrokymograph has been introduced and although its application in clinical medicine is in its infancy, it promises to reveal interesting data about the normal and abnormal function of the heart During the past several years venous-catheterization of the heart has been employed it is already clear that certain diagnoses, especially in the field of congenital heart disease, can be made by this elaborate method, that were impossible without it

Apart from the above, there are other important measurements that are often made in studying patients suffering from heart disease Amongst these are the determination of the arterial and venous pressure the velocity of blood flow, the vital capacity of the lung the blood volume etc Sometimes one or another of these various tests proves valuable and even decisive in guiding the physician to the correct diagnosis There are times when the serological test for syphilis or the determination of the basal metabolism prove to be the main clue in establishing a sound diagnosis and in directing effective treatment Many of these examinations are time-consuming and expensive, but they are often indispensable Diagnoses can now be made by the use of one or more of these procedures that were completely beyond the scope of our most learned predecessors Nor has this advance been entirely theoretical or academic There are numerous instances in which modern methods of study have enabled us to recognize and even to cure conditions that are amenable to effective treatment which were formerly either unrecognized or incurable It is the function of the wise physician to choose from amongst all these procedures the one or more, preferably the simplest, that are essential in guiding his treatment

During this period of rapid advance in technology and in therapeutics as it pertains to heart disease, one method of examination has suffered—auscultation of the heart The interest and energy expended in these other fields although extremely profitable, have detracted from the attention given to the use of the stethoscope In addition, there was a more legitimate reason for attaching less importance to auscultatory findings During the period before the first World War, physicians attributed too great importance to certain cardiac irregularities and murmurs Largely as a result of the teaching of Sir James MacKenzie, the significance of the symptoms of heart failure (congestive or anginal) began to be appreciated He convinced the medical profession that many cardiac murmurs and irregularities were benign and compatible with long and vigorous lives Physicians were prone to administer digitalis and to

* The St Cyres Lecture of the National Heart Hospital, London, July 8, 1948

† I wish to express my great indebtedness to Dr W Proctor Harvey, Assistant in Medicine, Peter Bent Brigham Hospital Boston for his help in obtaining numerous phonocardiograms and in other ways

restrict greatly the activities of patients, even confining them to bed, because of the detection of abnormalities that we now know were entirely harmless The change in viewpoint that took place some thirty or forty years ago was a great step forward

However, all this led to discrediting the use and value of the stethoscope I recall hearing MacKenzie say that the stethoscope should be thrown away, because it had done more harm than good To be sure, auscultation sheds very little light on whether the heart is failing or not The only stethoscopic finding that indicates heart muscle incompetency is a diastolic gallop or possibly an alteration of ventricular systole But what must not be overlooked is that many patients have organic heart disease, especially valvular disease, for many years before they have heart failure They often want to know and need to know, during these early years, whether they do or do not suffer from heart disease In some of them auscultation is the simplest and occasionally the only method of answering this question, which is important notwithstanding the fact that during the period of normal compensation one would not advise cardiac medication or unduly restrict activities if a faint murmur of rheumatic aortic insufficiency is found Such a patient might need prophylactic penicillin therapy for the extraction of teeth to protect him against bacterial endocarditis if aortic insufficiency were present, and would not if the heart were perfectly normal This and other matters of considerable importance to the health of the patient depend upon the accurate diagnosis of apparently minor abnormalities that auscultation may reveal

It is surprising that so little direct experimentation has been carried on concerning auscultatory findings Our interpretation of the significance of cardiac murmurs has largely depended upon the correlation of physical findings in the sickroom with observations carried out post-mortem This method has been very valuable but has definite limitations We are unable to trace back and study the anatomical and pathological changes that were present years before the patient died, and explain the findings that were present when the heart was well compensated Furthermore, at the autopsy table we see the atonic heart and cannot readily picture what the position of the valve leaflets might have been when the heart performed its function with the existing pressure relationships Valves that appear normal or essentially so when observed directly, may have been incompetent when functioning in the living heart We know that the aorta can be considerably dilated when viewed fluroscopically and yet show normal dimensions post-mortem This has been called the hyperdynamic aorta May not similar changes be taking place within the chambers of the heart?

Another point about which accurate data are lacking is the relationship between the size of a defect and the loudness of a murmur that may result Under what circumstances does a loud murmur represent a slight valvular defect and when is the reverse true? It would seem logical that a very loud systolic murmur of aortic stenosis would accompany a high degree of stenosis and a similarly loud mitral systolic murmur might indicate a slight mitral insufficiency, because in each case we would expect the intensity of the turbulance to be greatest when the blood stream suddenly flows through a very narrow orifice The situation does not appear to be the same with regard to aortic insufficiency, for here it seems that a faint diastolic murmur is present with a slight regurgitation Some of these questions could be readily answered by direct animal experimentation

The exact position and movements of the valves, especially the auriculo-ventricular valves, during various phases of the cardiac cycle is of considerable importance in the discussion to be taken up later Most physicians look upon the closure of the mitral and tricuspid valves as occurring in a hinge-like fashion, like the closing of a door If that were true, it would appear that during the very early part of ventricular systole, as the valve leaflets were being approximated, there would necessarily be some regurgitation before the valve actually closed Yandel Henderson (1912) reported some ingenious experiments many years ago, supporting the view that closure of the A-V valves took place in a manner that would prevent this possible reflux He believed that as a result of a "jet effect" the A-V valves were drawn close together directly after auricular systole, and with ventricular systole they finally closed by a mechanism similar to the unrolling of a carpet In this fashion there would be no regurgitation during ventricular contraction Furthermore, it is a matter of some importance whether the valve leaflets are driven deeper into the ventricular cavity and spread more widely apart by auricular systole or whether they attain a higher position and are drawn nearer together It may be debatable whether the experiments of Henderson can be translated directly to events that occur in the normal human heart and whether they apply with equal significance to abnormal states In any case, there seems to be little doubt but that auricular contraction alters the exact position of the A-V valves and will have a determining effect on the position of these valves at the very moment ventricular systole occurs

The First Heart Sound

Although many points about the mechanism of cardiac sounds and murmurs are still vague and meagrely understood, there are some clinical correlations of auscultatory findings with practical application that are not generally appreciated or utilized Amonst these is the significance of the intensity of the apical first heart sound It is generally taught that the first sound has two components, valvular and muscular Experiments performed by Dock (1933) led him to the view that the first sound is entirely valvular Observations to be discussed here indicate that if there is a muscular component it is so faint that it is essentially inaudible on ordinary auscultation For present purposes, therefore, it can be assumed that the apical first sound is valvular in origin

There are many occasions on which the heart sounds are decreased in intensity It is obvious that in patients who are dying or moribund, when the heart is extremely feeble, the heart sounds become very faint Likewise, patients with much obesity, emphysema, or pericardial effusion may have very distant heart sounds In fact, any condition that interposes excessive tissue between the heart and the skin will necessarily decrease the intensity of the sounds as heard with the stethoscope In all those conditions, both first and second sounds will be diminished Excessive amounts of air or tissue between the heart and the external thorax will not affect one sound without producing a similar effect upon the other What is more important is that the first sound can be altered (increased or decreased) without a simultaneous change in the intensity of the second sound It is this phenomenon that deserves particular attention, for its detection enables the physician to make certain bedside diagnoses by simple auscultation that formerly were regarded as impossible without elaborate graphic methods

The loudness of the first sound depends upon several factors The vigor of ventricular systole is one of these, but by no means an important one Many patients have serious organic heart disease and even failing hearts with perfectly good heart sounds Contrariwise, a decreased first sound is common in perfectly healthy subjects Of greater significance is the quickness or abruptness of ventricular systole Hyperactive or loud sounds, particularly the first sound, are often heard in hyperthyroidism (Fig 1 and 2), anæmia (Fig 3), after a brief exercise, during certain infections (particularly rheumatic fever), and with some emotional states In most of these conditions, if not in all, the ventricles contract briskly On fluoroscopic examination one can often see a "snapping or hyperactive type of beat" With this there is likely to be an increase in the velocity of blood flow Generally this is determined by measuring the circulation time from a vein in the arm to an artery in the head What determines the effect on the loudness of the first sound, and for that matter on the production of cardiac murmurs, is not the total speed of flow but the velocity of the blood stream within the chambers of the heart and the neighbouring great vessels It is quite likely that this may be accelerated even when the total speed of flow as measured in the ordinary way is little, if at all, affected One would expect that the duration of mechanical systole would be slightly shortened in these hyperactive states, and the increased intensity of the first sound would result from the abruptness of closure of the A-V valves Many years ago Samuel Gee (1908), in discussing murmurs, stated "The loudness of the sound depends upon the swiftness of the flow the quality of the fluid and the size of the orifice are of import only inasmuch as they exert an influence upon the swiftness of the flow" This mechanism not only affects the intensity of murmurs, but also of heart sounds

Another condition in which the first sound is notably increased in intensity is mitral stenosis The cause of this peculiarity has been a matter of much speculation One naturally suspects that the anatomical changes in the valve itself may influence the loudness of the sound However, there are other influences involved In mitral stenosis, the papillary muscles are hypertrophied and the chordæ tendineæ are shortened The valve leaflets are probably deeper in the ventricular cavity than normally Furthermore, the left auricle is generally dilated or hypertrophied, and with the obstruction of the valve, the filling of the ventricle occurs more slowly and gradually Finally, the ventricle may contract with a slightly smaller volume and more abruptly The result of these various factors is that the valve may be at an abnormal position the moment ventricular systole occurs and, as we shall discuss shortly, this influences the intensity of the first heart sound

A final factor that determines the loudness of the first sound, and one that I believe to be the most important, is the exact position of the A-V valves at the instant the ventricles contract It was stated above that there is some difference of opinion whether the A-V are driven deeper and wider apart or higher and closer together by auricular systole Although I assume the first of these two premises, the fact that auricular systole changes the position of the valves can hardly be doubted The observations to be discussed and the arguments involved are equally applicable on the basis of either theory, for the main point is that the first sound is different



FIG 1—Normal heart sounds Normal male, 40 years old Note first sound (S–1) is louder than second sound (S–2) at apex, but the relationship is reversed at the base of the heart This is the *customary finding in normal hearts,*

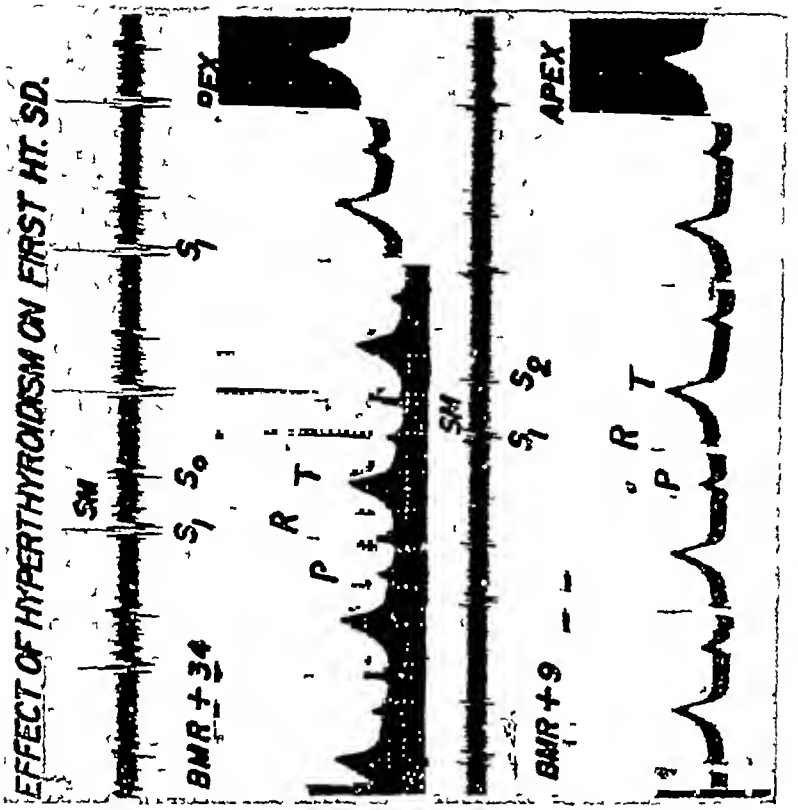

FIG 2—Girl, aged 18 years Diagnosis thyrotoxicosis Upper tracing while BMR was +34 Lower tracing about one month later, after propyl thiouracil therapy BMR +9 Note great decrease in intensity of first sound (S–1) and also of systolic murmur (SM)

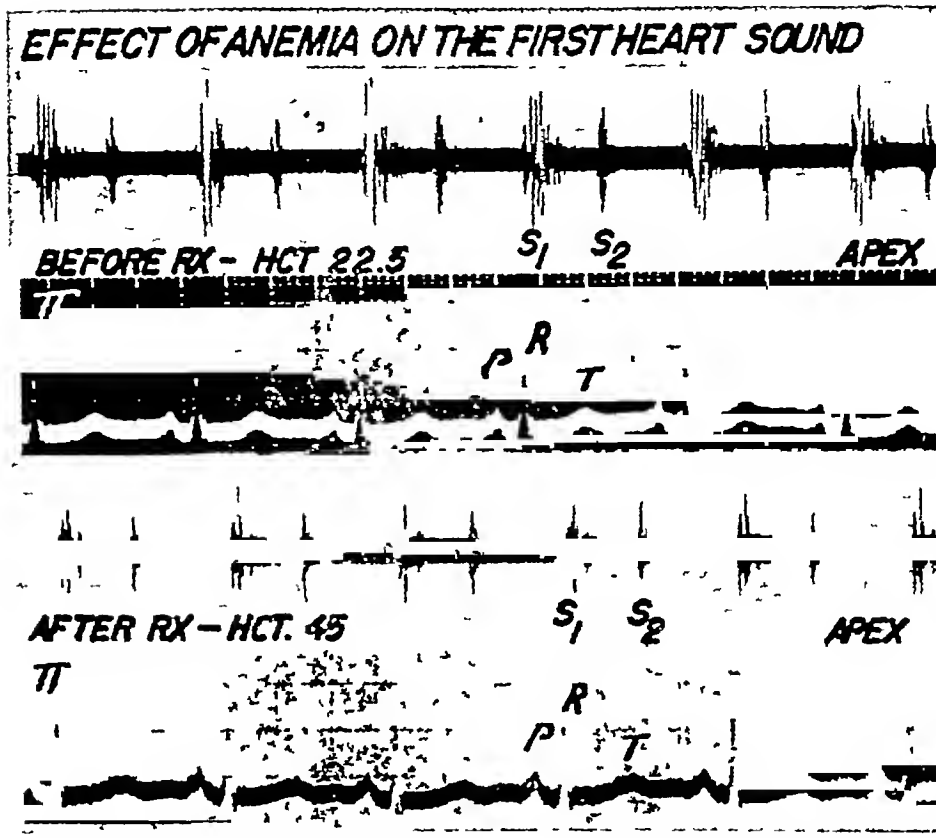

FIG 3 —Woman, aged 68 years Diagnosis pernicious anæmia Upper tracing hæmatocrit was 22 8 Lower tracing Several months later, hæmatocrit 45·0 Note decrease in intensity of first sounds (S–I)

if the valves are in one position from what it is if they are in another It will be assumed that the first sound is louder if the valves are deep in the ventricles and wide apart and is fainter when higher up and closer together

If this theoretical speculation is correct, it should follow that the relation between the time of auricular and ventricular systole will have a profound effect upon the loudness of the first sound Normally the ventricles contract 0 16 to 0 18 sec after the auricles Auricular systole, it may be assumed, propels the A-V valves into the ventricular cavities, and as the ventricles partially fill, the valves move upwards to a mid-position and then are abruptly closed as ventricular systole occurs If the ventricles contract 0 08 sec after the auricles, the valves will be caught at a lower position and the snap that results with ventricular contraction will be louder However, if ventricular contraction occurs 0 22 sec after auricular, the ventricles will have had a longer time to fill and the valves will be higher and more closely approximated Closure will then result in a more feeble sound In a word, the loudness of the first sound, according to this reasoning, ought to reflect to some degree the length of the P–R interval

We have, therefore, a means of estimating the P–R inverval by auscultation of the heart If conditions cited above like mitral stenosis, hyperthyroidism, anæmia, etc, which may increase the intensity of the sound, can be eliminated, an accentuation of the first sound at the apex strongly suggests that the P–R interval is shorter than normal It has been found that the sound is loudest when the interval is about 0·04 to 0 08 sec (Wolferth and Margolis, 1930) Contrariwise, if the sound is fainter than normal, the P–R interval is full or unduly prolonged (0 20 to 0 24 sec or more) It does not follow that the first sound becomes increasingly weak as the P–R interval lengthens more and more The intensity may be decreased just as much or more when the P–R interval is 0 22 sec as when it is 0 30 sec. In estimating an increase or decrease in the loudness of the first sound it is well to compare it with the second sound None of the above inferences can be drawn if both sounds are much decreased One should compare the

loudness of the first sound with what one would expect to hear in that particular case, considering the intensity of the second sound, the shape and thickness of the chest wall, and whatever other conditions may affect the heart sounds

Many auscultatory findings are often missed because auscultation is not carried out methodically One should spend several seconds deliberately listening to one point at a time First, one should listen to the first sound for several seconds, dismissing everything else from one's mind Then the same procedure should be carried out for the second sound This is continued for the interval between the first and second sound (systole) and finally for the interval between the second and first sound (diastole), listening for additional sounds or murmurs In no other way can fine points in auscultation be detected, except by concentration on one of these four components at a time Normally, the first sound is generally louder than the second at the apex, and the reverse is true at the base of the heart (Fig 1)

It is surprising how accurate one can become in guessing what the P–R interval will be on the basis of the intensity of the first sound (Fig 4) Repeatedly I have been able to predict this interval to within 0 01 sec This information, so readily obtained by simple auscultation, has considerable practical importance There is no other way of eliciting it except by the use of graphic methods or other complicated techniques It would require obtaining daily electrocardiograms to detect some of the transient changes in the P–R interval that occur in myocarditis of rheumatic or diphtheritic origin Furthermore, many hearts with a slight delay of the P–R interval may otherwise appear quite innocent, so that the general practitioner is not tempted to obtain electrocardiographic records

The following is an illustrative experience A man about 50 years old came to the out-patient department because he had fainted a few times He was otherwise well, having no breathlessness or pain in the chest He could work and walk quite well Physical examination revealed nothing abnormal

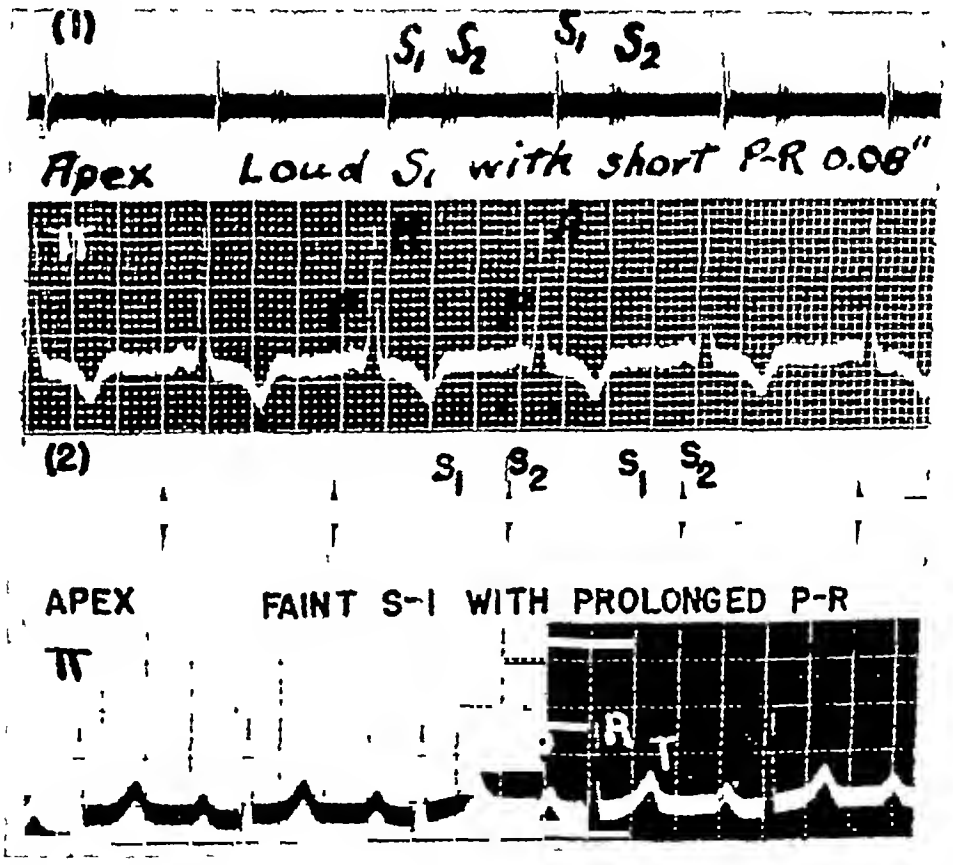

FIG 4 —Upper tracing shows loud first sound (S–1) with short P–R interval (0 08 sec) Patient was a man 24 years old, with essential hypertension. Lower tracing shows almost inaudible first sound (S–1) with only slightly prolonged P–R (0 22 sec) Patient was a 24 year old woman with Gaucher's disease

The blood pressure was normal, the heart showed no enlargement, arrhythmias, or murmurs, and the carotid sinus was not unduly sensitive On careful auscultation the apical first sound was extremely faint, though the second sound was normal This important finding was entirely overlooked by the physicians who first examined him When the same physicians were asked to re-examine the patient, paying particular attention to the first sound, they quickly realized that it was strikingly decreased in intensity Then followed a further misinterpretation of the significance of this finding When asked what a decreased first sound signified, the reply was that it indicated heart muscle weakness However, this patient seemed fit and gave no evidence of myocardial incompetency

It is obvious that many patients have grave myocardial insufficiency with normal first heart sounds and may have poor or even inaudible first sounds with perfect heart function The old concept that a poor first sound means a weak heart muscle is entirely fallacious In the case cited above, the interpretation was made that the P–R interval was delayed, possibly to 0 21 to 0 22 sec An electrocardiogram was then taken directly, which showed the interval to be 0 22 sec The practical point of this experience is that a simple auscultatory finding led me to suspect that the previous attacks of syncope were due to Adams-Stokes disease Only later did we learn that he had previously been observed in a hospital during one of these spells, and there showed transient complete heart block

Similarly it is possible to suspect that the P–R interval is unusually short If the common causes for an accentuated first sound like mitral stenosis, hyperthyroidism, etc , can be eliminated from consideration, a snapping first sound is very likely to mean that the P–R interval is less than normal (Fig 4) It may be only 0 14 sec , but more frequently 0 12 sec or less It has been somewhat surprising that the first sound in cases of the Wolff-Parkinson-White syndrome, though somewhat accentuated, is not as loud as one might have expected with P–R intervals as short as 0 08 to 0 10 sec This may be due to the fact that in this condition early excitation occurs generally in the right ventricle, and that closure of the mitral valve (the more important one of the two A-V valves) takes place at a normal interval after auricular systole In any event, there are other instances of short P–R interval that are associated with attacks of paroxysmal rapid heart action and, therefore, simple auscultation may lead the physician to recognize such cases

There is abundant proof available that changes in the P–R interval *per se* have a profound effect on the intensity of the first sound In an experiment in which the heart rate happened to remain unchanged after the intravenous injection of 1 0 mg of atropine, the P–R interval was markedly decreased while the first sound became greatly accentuated (Fig 5) In this experiment the microphone and stethocardiographic mechanism was not disturbed in any way, so that the loudness of the registered sounds could be accurately compared A very feeble sound, which was present because the P–R interval was delayed (0 28 sec), became quite loud fifteen minutes later when the interval shortened to 0 18 sec

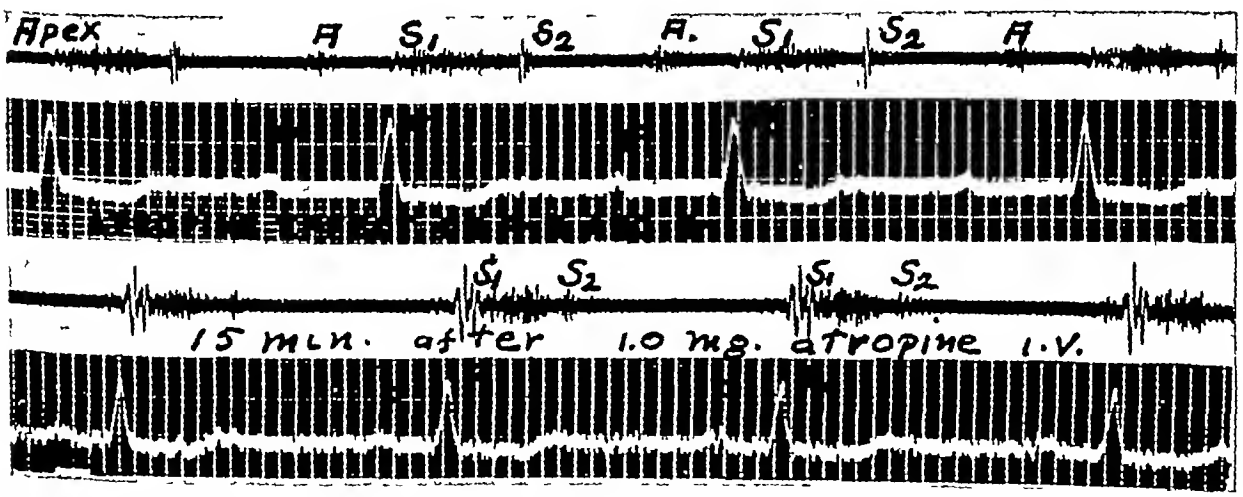

FIG 5 —Upper tracing shows faint first sound (S–1) with long P–R interval (0 28 sec) Lower tracing shows loud first sounds (S–1) 15 minutes after 1 mg atropine i v when P–R interval was normal (0 18 sec) Auricular sounds (A) were detected in upper tracing

Complete A-V Block

Another and more important observation that affords proof of this general premise is the changing intensity of the first sound in cases of complete dissociation of the auricles and ventricles (complete heart block) This auscultatory phenomenon was first observed by Strazhesko (1906) and independently by Wardrop Griffith of Leeds (1912) The true explanation of the changing first sound was at first not understood In the course of time this finding became known as the "bruit de canon" because of the explosive quality of the first sound in occasional cardiac cycles Even when Lewis (1915 and 1925) published phonocardiograms of this mechanism (1925), he erroneously ascribed the loud sounds to the simultaneous contraction of the auricles and ventricles, inferring that a summation effect caused the accentuation Wolferth and Margolis (1930), however, clearly demonstrated that the greatest intensity of the sound occurred when the P–R interval was between 0 04 to 0 08 sec and not when auricular and ventricular contractions took place simultaneously

When the ventricles are beating slowly and regularly and the auricles more rapidly, regularly, and independently, we have an opportunity of observing the effect of changing P–R relationships from cycle to cycle without any other disturbing influence It will be found that the sounds are loudest when the interval is unusually short and fainter when long (Fig 6) In fact, there may be occasions when the first sound is almost inaudible

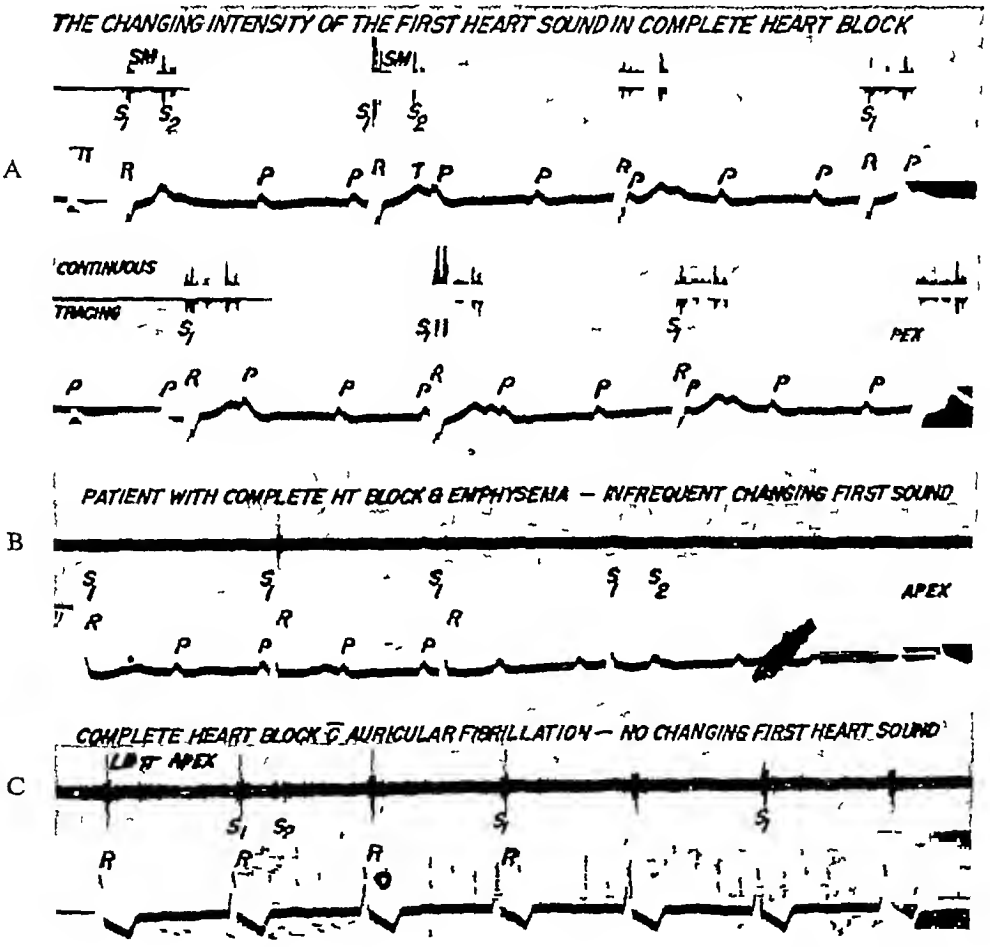

Fig 6 —(A) Upper two strips are continuous Man, 33 years old, with Adams-Stokes disease with complete A-V dissociation Note changing intensity of first sounds (S–1), loudest sounds coming with very short P–R intervals Intensity of systolic murmur (SM) remains constant (B) Second patient, aged 60, had complete heart block and emphysema Note that although most sounds are distant, when the P–R interval is very short, S–1 is loud (C) Lowest tracing Man, aged 72 years Diagnosis complete heart block with auricular fibrillation or idioventricular rhythm Note constant intensity of first sounds (S–1)

and at other times strikingly accentuated This changing intensity of the first sound in a slow, regular beating heart is practically pathognomonic of complete heart block Our medical internes have been sufficiently alert in recent years to make the bedside diagnosis of complete block by means of this sign, even in cases in which the ventricular rate was not 30 to 40 but 50 to 75, as occurs occasionally in acute coronary thrombosis The marked diminution, and at times the complete absence of the first sound in occasional cycles when the P–R interval is delayed, afford additional proof that the muscular component must be of very little importance in the causation of the first sound These cycles are just as vigorous, and are accompanied by a peripheral pulse of the same volume as those producing a loud sound

One would predict that if there were complete heart block and the auricles were fibrillating the first sound would maintain a constant intensity This would necessarily follow because, although the ventricles are beating independently, the auricles are not contracting, and therefore would not alter the position of the A-V valves at the time of ventricular systole That this is the case is well illustrated in Fig 6C

Paroxysmal Ventricular Tachycardia

There are other conditions in which the contractions of the auricles should produce alterations in the intensity of the first sound In most cases of paroxysmal ventricular tachycardia, the auricular rhythm is independent of the ventricular and controlled by the normal sinus pacemaker As would be expected, the intensity of the first sound varies in different cycles (Fig 7) This auscultatory sign was described some years ago (Levine, 1927), and may enable the examiner to distinguish the auricular from the ventricular type of paroxysmal tachycardia In the common variety of paroxysmal auricular tachycardia (without heart block) the heart sounds are not only rapid (150–250) and regular, but are constant in quality and intensity In ventricular tachycardia, the rate is also rapid (150–250), generally regular (though frequently slight irregularities may be present) but the intensity of the first sound may vary considerably In fact, obvious alteration in the first sound may be detected when the ventricular cycles are perfectly regular This feature, together with the failure to influence the ventricular rate by vagal stimulation, helps to distinguish, on simple bedside examination, the ventricular from other types of paroxysmal rapid heart action

Auricular Flutter

The character of the first heart sound has recently been investigated in auricular flutter In many cases of auricular flutter before therapy is instituted, the ventricular rate is exactly one-half of the auricular Under these circumstances every other impulse from the auricles is blocked The rhythm of the auricles is perfectly regular though rapid (250–350), and the ventricular response is also perfectly regular (125–175) The interval between the auricular impulse that is not blocked and the subsequent ventricular contraction is constant from cycle to cycle The result is that the first heart sound is constant in character, just as it is in paroxysmal auricular tachycardia or in normal sinus tachycardia (Fig 8) However, there are instances of flutter in which the ventricular rate, though rapid,

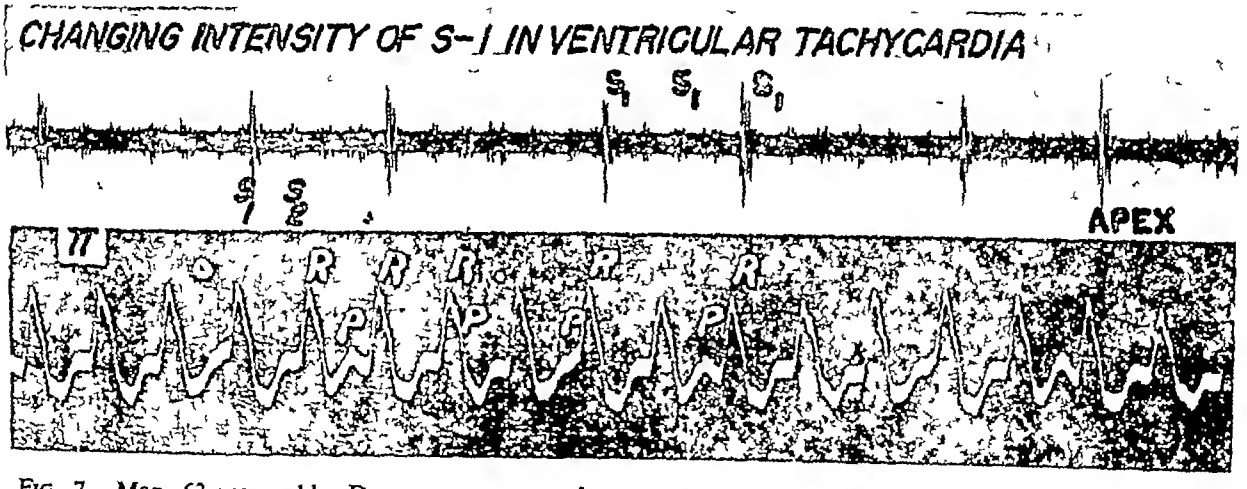

Fig 7—Man, 63 years old Diagnosis paroxysmal ventricular tachycardia Note changing intensity of first sounds (S–1) with auricles and ventricles beating independently Note loudest first sounds come with short P–R intervals

is not absolutely regular Slight differences may be detected in the interval between the auricular and ventricular impulses in different cycles This would necessitate alterations in the intensity of the first sound (Fig 8 and 9) Such changes have been observed, and have been shown to be due to the variation in the A-V relationships and not to the length of the diastolic pause (Harvey and Levine, 1948)

A further auscultatory finding in auricular flutter is the detection of auricular contractions Not only may these faint sounds be audible during the long diastolic pauses when the ventricles have slowed, but they may be heard during systole (Fig 9) Occasionally they are quite loud and confusing so that the observer may be misled into considering the mechanism as due to auricular fibrillation A well known simple bedside method of distinguishing the irregularity of flutter from that of fibrillation is the effect of exercise When the heart accelerates after a brief effort, the irregularity of flutter is likely to change to a more rapid but regular rhythm while that of fibrillation continues to be irregular though more rapid

A peculiarity of auricular flutter that is less well known is the response to vagal stimulation When the heart rate as auscultated over the præcordium is perfectly regular and rapid (140–175), it is often possible to slow the ventricular rate temporarily by carotid sinus pressure or other means of vagal stimulation, such as holding a deep breath In auricular flutter, after a brief period of slowing, the original rapid rate is often resumed in a *jerky* fashion (Fig 9) In paroxysmal auricular tachycardia without block, vagal stimulation will have no effect whatever or completely arrest the attack In normal sinus tachycardia, if any effect is produced, there will be temporary slowing with a *gradual* return to the previous rate, and in ventricular tachycardia carotid sinus pressure will never alter the rate The temporary slowing and the *jerky* return of the previous tachycardia is fairly characteristic of auricular flutter, and helps the physician to diagnose this condition by simple bedside examination

The above auscultatory findings prove very useful, not only in the original recognition of auricular flutter but in following its progress under treatment While administering digitalis or quinidine, it is often important to increase, decrease, or omit the drug depending upon the changes in the arrhythmia It might be necessary to take frequent cardiograms to know whether flutter is still present or whether the rhythm has reverted to normal or to fibrillation A day or two after administering quinidine or digitalis to a patient with flutter, for example, the heart may be found quite regular at a rate of 70 One might readily conclude that the mechanism is normal, but in point of fact flutter may still be present with an auricular rate of 280 and a pure 4 1 block A brief exercise test is likely to clarify the diagnosis If flutter is still present, the rate may quickly jump to 140 and remain regular for a short interval or become temporarily irregular and rapid (Fig 9) If the original slow regular rate had been due to a normal sinus rhythm, temporary acceleration would have occurred smoothly and could only by accident have reached the rate of 140, which is an exact multiple of the original rate of 70 These simple guides may quickly enable the physician to make decisions, and will save considerable time and expense

Pulsus Alternans

Pulsus alternans is a phenomenon detected in the peripheral arteries in which the pulse, though perfectly regular, alternates in volume It is generally believed to indicate a fairly grave disturbance in myocardial function It is even more easily detected on auscultation below the pressure cuff when determining the blood pressure Here the sounds will alternate in intensity, and when the condition is very marked, only the stronger of the alternate beats will be audible at the very highest levels of pressure What has not been currently appreciated is that the same phenomenon may be detectable on auscultation of the heart Not infrequently the intensity of the heart sounds or of an accompanying systolic murmur may alternate from cycle to cycle (Fig 10) When this is heard, it has the same significance and is due to the same disturbance in contractility as obtained when pulsus alternans is observed in the peripheral arteries

Gallop Rhythm

In identifying a gallop rhythm by auscultation, it is always important to distinguish the systolic from the diastolic type Whereas a gallop in which the extra sound occurs between the second and first normal heart sounds is almost always a pathological finding and of grave significance, when the extra sound occurs between the first and second sounds, it is a benign phenomenon (mid-systolic click or gallop) It may be heard in some normal subjects, and when it accompanies organic disease, it does not add to the seriousness of the prognosis There is a simple method of determining the fact that the sound is present in mid-systole After identifying the three sounds at the apex of the heart, the stethoscope is rhythmically placed higher and higher over the præcordium The middle one of the three sounds will be found to wane gradually and finally disappear on approaching the aortic

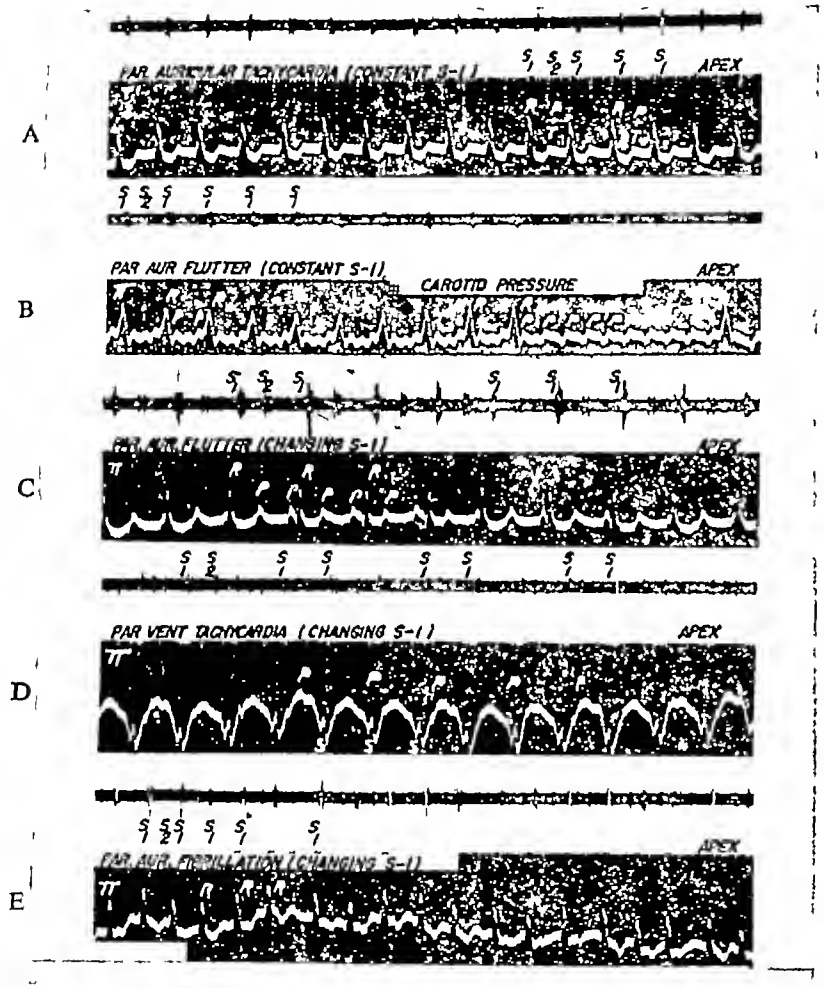

FIG 8 —The first heart sound in various tachycardias (A) Note constant intensity of first sound (S–1) in upper tracing (par aur tachycardia) (B) Second tracing shows constant S–1 with aur flutter having regular 2 1 block (C) Third tracing shows auricular flutter with slightly irregular ventricular rate with changing intensity of the first sound (D) Fourth tracing (par vent tachycardia) shows changing S–1 with perfectly regular ventricular rate (E) Lowest tracing shows changing first sound with auricular fibrillation

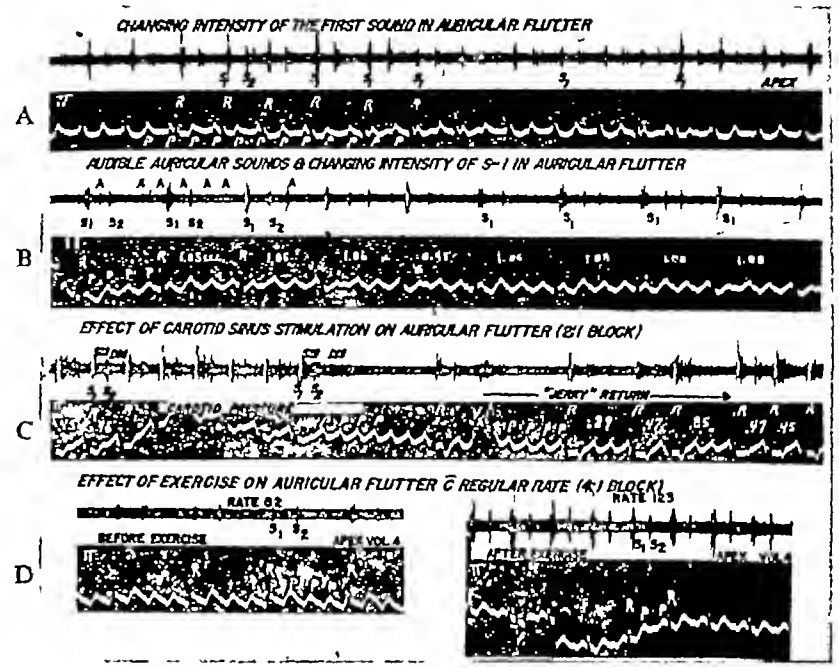

FIG 9 —Four different cases of auricular flutter (A) Upper tracing shows changing intensity first sound (S–1) with changing P–R relationships Intensity of S–1 is not related to previous diastolic pause (B) Second tracing shows changing S–1 (due to alteration in P–J interval) with almost regular ventricular rate Note auricular s nds (a) even during systole (C) Third tracing shows slowing of ventricular rate following carotid pressure with jerky return to original tachycardia (D) Lowest tracings show a regular ventricular rate of 62 exactly doubled (123) after brief effort

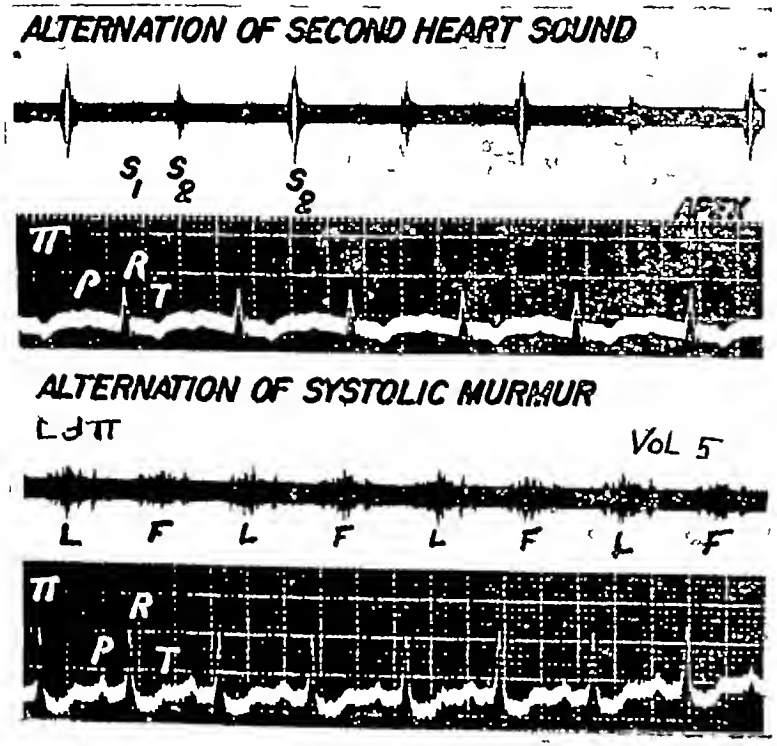

FIG 10 —Upper tracing Man, aged 61 years, with hypertensive heart disease Note marked alternation of apical second sound (S–2) Lower tracing Woman with calcific aortic stenosis Note alternation of systolic murmur (SM) Loud = L Faint = F

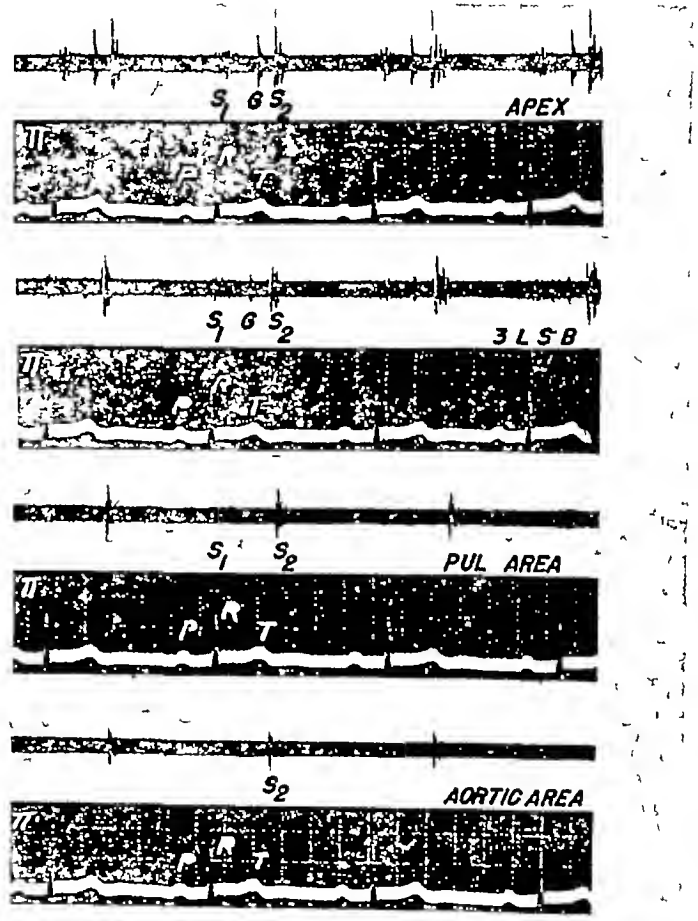

FIG 11 —Systolic gallop disappearing at base (Timing of gallop by "inching") Woman, aged 26, with question of epilepsy No organic heart disease Note benign systolic gallop sound (G) occurs between first (S–1) and second sound (S–2), loudest at apex and gradually disappearing on reaching base S–1 decreased because of long P–R (0 24 sec)

area (Fig 11) One will be left with the two normal sounds, making it clear that the sound that was audible at the apex and lost at the base of the heart occurred in mid-systole This method of "inching" is helpful not only in identifying the types of gallop but also other events that occur in different parts of the cardiac cycle

Systolic Murmurs

The interpretation and significance of a systolic murmur still remains a puzzling problem It is quite true that many systolic murmurs (generally of slight intensity) are heard when there is no abnormality of the heart and, in fact, in those who have no structural disease whatever In others, though there may be minor abnormalities, normal health and life expectancy is maintained However, it is also true that many systolic murmurs detected in otherwise healthy people and regarded as benign or inconsequential, in later years have proved to be due to some structural abnormality I look back at instances of this sort in which a congenital abnormality such as pulmonary stenosis or auricular septal defect was subsequently found by venous catheterization, which explained the "functional" basal systolic murmur Others, ten or twenty years later, proved to have calcific aortic stenosis Still others that had a slight apical systolic murmur developed unequivocal evidence of mitral stenosis or bacterial endocarditis I believe it is fair to say that, whereas much too great emphasis was attached to the presence of a systolic murmur a few decades ago, too little attention has been paid to it in recent years

It is not the purpose of this discussion to go into the mechanism or interpretation of the systolic murmur However, I would urge that consideration be given to its detection and its possible significance, and that particular attention be paid to its intensity Although faint systolic murmurs may be heard in otherwise healthy subjects, loud ones almost always denote some disease, generally of the cardiovascular apparatus For this reason, I have become accustomed to grade the intensity of systolic murmurs from one to six Grade one is the faintest and will generally not be audible until the examiner has listened for several cycles Grade six is the murmur that is sufficiently loud to be heard with the stethoscope just removed from the chest wall The intervening grades (2 to 5) are of intermediary intensity Although at first glance this may seem a cumbersome terminology, it is surprising how quickly different observers will fall in line with each other, and rarely differ in their terminology by more than one gradation The result of the use of such terminology is that one observer can more readily understand and compare the findings of another with his own Furthermore, it enables the physician to divide systolic murmurs into those that are likely to be associated with organic disease (grade three or louder), and those that commonly are found without structural disease of the heart (grade one or two)

There appears to be certain misconceptions in our current teachings concerning the transmission of murmurs There is a prevailing opinion that murmurs are transmitted by or with the blood stream One frequently is told that a particular systolic murmur heard at the base of the heart is transmitted to the carotid artery, or another at the apex region is transmitted to the axilla These observations are made as added evidence that the murmur in the first instance is due to aortic stenosis, and in the second instance is due to mitral insufficiency There is now abundant proof that the transmission of murmurs is mainly a function of its intensity, and that bony structures are the best peripheral conductors Very loud murmurs, no matter what their origin may be, are propagated in all directions, and may be well heard over the carotid arteries or in the axilla A loud systolic murmur of Roger's disease or pulmonary stenosis may be well heard in the carotid arteries (Fig 12) Here the flow of blood producing the turbulence is within the heart or chest and not out into the peripheral circulation, and yet the resultant murmur is transmitted to the neck In fact, very loud murmurs (systolic or diastolic) are easily audible over the olecranon process of the elbow, even when arterial flow to the arm is completely occluded (Fig 13) This is convincing evidence that the propagation of murmurs is through bones The conclusions from these observations is that the murmur of aortic stenosis is transmitted to the neck because the point of maximum intensity of the murmur is near the neck, and that the mitral systolic murmur is well heard in the axilla because it is near the axilla

Miscellaneous Observations

There are numerous other auscultatory findings of practical importance that can be easily elicited, which are beyond the scope of this discussion Careful attention to the exact timing of the murmurs of mitral stenosis throws light on many otherwise baffling problems in diagnosis The importance of the degree and duration of ventricular filling on the murmur of mitral stenosis has not been sufficiently emphasized The presystolic murmur of mitral stenosis can disappear even when the auricles are contracting normally, if the diastolic interval is sufficiently long (Fig 14) Not infrequently patients are observed who show no murmur whatever in



FIG 13 —Murmur of patent ductus arteriosus Woman, 23 years old, with patent ductus arteriosus Note loud continuous murmur in upper tracing from pulmonic area Middle strip shows systolic murmur (SM) at olecranon process with blood pressure cuff inflated to 250 mm Same murmur readily heard at elbow with cuff uninflated (lower tracing)



FIG 12 —Woman, 29 years old, with tetralogy of Fallot Upper tracing shows loud pulmonic systolic murmur Lower tracing shows same systolic murmur over left carotid artery

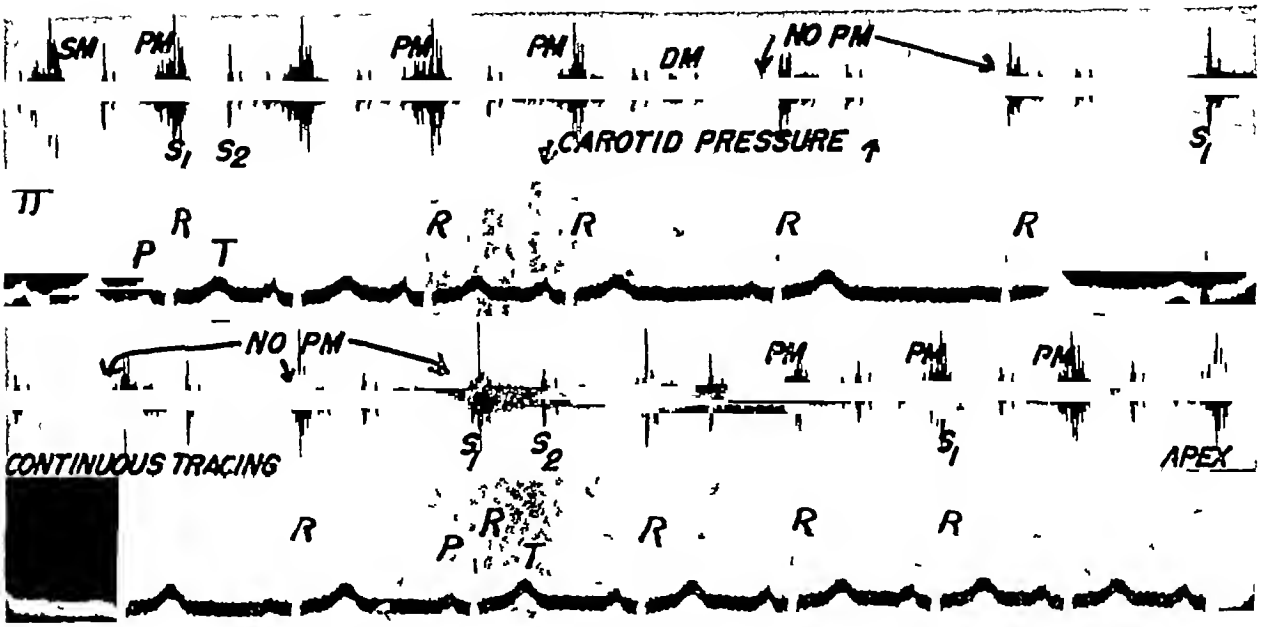

FIG 14 —Effect of long diastole on presystolic murmur of mitral stenosis Woman, 26 years old Diagnosis mitral stenosis Note classical presystolic murmur (PM) disappears with long diastolic pauses following carotid pressure

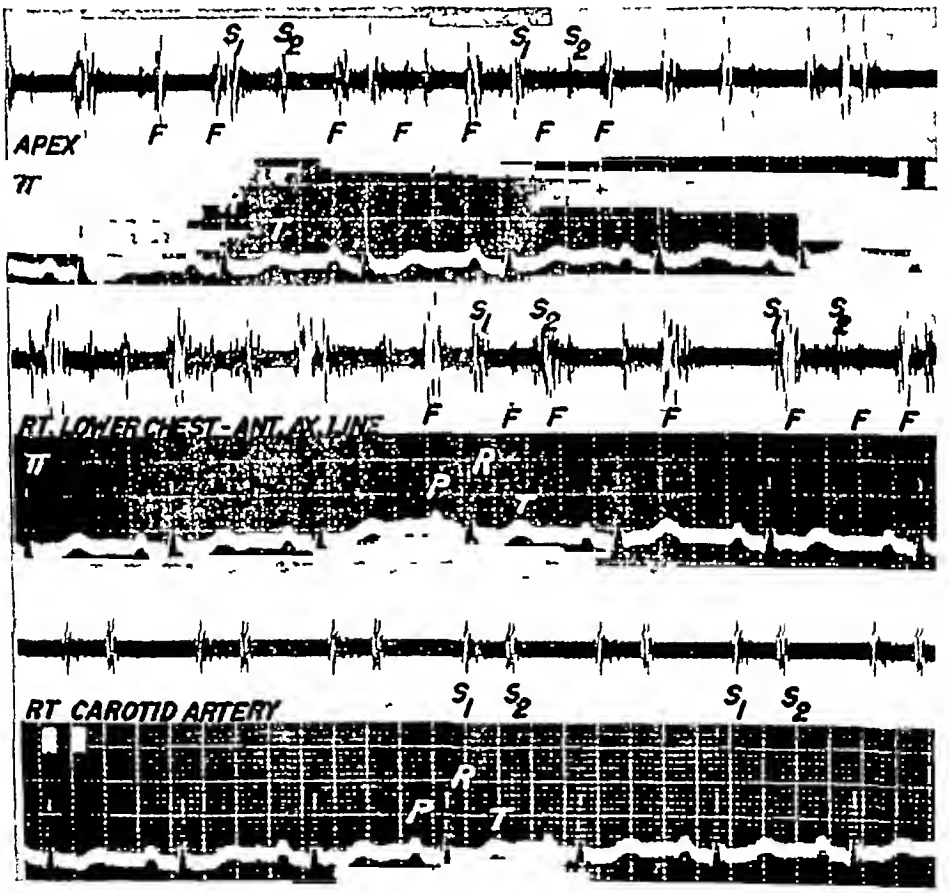

FIG 15 —Diaphragmatic flutter Woman 32 years old with mitral stenosis and diaphragmatic flutter Upper tracing from apical region shows numerous sounds, a combination of normal heart sounds (S–1, S–2) and flutter sounds (F) This was at first clinically interpreted as auricular fibrillation Note that flutter sounds (F) were very prominent in right axilla (middle tracing) and were entirely absent over right carotid artery

diastole on most careful auscultation, and yet have unequivocal evidence of mitral stenosis, as shown by the finding of a calcified valve on fluoroscopic examination Such cases are likely to be in the advanced stages of heart failure with auricular fibrillation The absence of a diastolic murmur is then probably the result of the very slow velocity of blood flow and the large volume of residual blood in the various chambers of the heart

Just to mention an occasional reward the physician may obtain as a result of intelligent auscultation, I may mention the following experience In this particular patient who had obvious evidence of mitral stenosis, on one occasion very peculiar heart sounds were heard They seemed baffling, and it first made one think that auricular fibrillation was present On listening over different parts of the chest, it quickly became clear that regular sounds at a rate of about 120 could be heard far removed from the heart, even in the right axilla (Fig 15) They were entirely independent of the pulse which was also regular, but 75 to the minute At other times, these aberrant sounds were absent The tentative diagnosis of diaphragmatic flutter was made This was confirmed by fluoroscopic examination, at which time regular rapid contractions of the diaphragm could readily be seen

I hope I have commented sufficiently on various aspects of auscultation to lend some support to the proposition that this method of examination is valuable and simple I also have reason to believe that much of the knowledge that is at present available is not being utilized to the full I may urge that greater emphasis be placed on this subject in our medical schools, so that this valuable and inexpensive method of diagnosis be not neglected It is also hoped that further interest and study will clarify many problems in auscultation at present poorly understood

Finally, I wish to thank my British friends and physicians for the privilege and honour of coming here to address you Many of the leading students of heart disease in the United States obtained their early inspiration and training here in your country, under your great teachers This will always remain a debt quite difficult to repay But in a broader sense there are no debts or credits for the medical profession is truly universal in its brotherhood

References

Dock, W (1933) *Arch intern Med*, 51, 737

Gee, S J (1908) *Auscultation and Percussion*, 6th ed, Oxford Medical Publication, London, p 84

Griffith, T W (1912) *Heart*, 3 143

Harvey, W P, and Levine, S A (1948) *Amer Heart J*, 35, 924

Henderson, Y, and Johnson, E (1912) *Heart*, 4, 69

Levine, S A (1927) *Amer Heart J*, 3, 177

Lewis, T (1915) *Lectures on the Heart*, Paul B Hoeber, 1915, p 60

—— (1925) *The Mechanism and Graphic Registration of the Heart Beat*, 3rd ed, Shaw & Sons, Ltd, p 181

Strazhesko, N D (1906) *Russ Vrach S Peterb*, 5, 603

Wolferth, C C, and Margolis, A (1930) *Arch intern Med*, 46, 1048

HEART-VECTOR AND LEADS PART III

GEOMETRICAL REPRESENTATION

BY

H C BURGER AND J B VAN MILAAN

From the Physisch Laboratorium der Rijks Universiteit te Utrecht, Holland

Received May 31, 1948

In 1947 Wilson, Johnston, and Kossmann gave a generalization of the triangle-rule of Einthoven In this paper they describe the use of a tetrahedron, their method is based on the same assumption as Einthoven's We have tried to give a rational description of the relation between heart-vector and leads, based on firmly established physical principles (Burger and van Milaan, 1947)

It is not self-evident that the electric action of the heart can be represented by *one* heart-vector This is only correct if one is allowed to consider the dimensions of the heart as very small compared with those of the trunk As a matter of course this *can* only be a useful approximation if the electrodes are applied far from the heart In that case it does not matter very much whether the electric action originates in the one or in the other part of the heart muscle As can be shown by mathematical analysis, the electric action of the heart can then be represented by *one* vector, acting in the " centre " of the heart But for præcordial leads, i e electrodes near the heart, this simplification is certainly not entirely correct, and we shall return to this point at the end of this paper

The formulation of the relation between heart-vector and leads can be based on well-founded physical laws It is then possible to say with certainty what is known *a priori* and what must be found by *measurement* The linear relation between

$$Lead = aX + bY + cZ \qquad (1)$$

each lead and the rectangular components X, Y, Z of the heart-vector is certain

We have related these components to a "natural" co-ordinate-system, of which the Z-axis is parallel to the axis of the body and of which the Y-axis is perpendicular to the frontal plane (Burger and van Milaan, 1946, 1947)

As we have explained in the papers mentioned, the coefficients a, b, c, which are independent of the heart-vector, must be determined experimentally For this one can use a phantom or measure on a cadaver We have done the former ourselves (l c) the latter method is used by others (Fahr and Weber, 1915, de Waart and Storm, 1935, Storm, 1936, Wilson *et al*, 1947 But whichever method is used one must proceed objectively and leave the decision to the experiments We have, therefore, provisionally accepted the values of the coefficients a, b, c, for a number of leads as the experiments gave them By repeating the measurement and by varying the conditions we have tried to improve on their reliability

With our phantom we have tried to reproduce the human body as closely as possible but are fully aware of the numerical imperfection of the result We took as a basis our measurements of the electric conductivity of the living human body (Burger and van Milaan, 1943) In these measurements we have not noticed the influence of membranes that by their high resistance could determine the course of the electric current Nor did preliminary measurements on (dead) membranes give a high value for this resistance either

From various sides other systems are proposed instead of the Einthoven triangle, all of them rectangular In these cases the electrodes are applied on the body in such a way, that the lines connecting them are mutually perpendicular and parallel to the axes of the above mentioned "natural" co-ordinate system (Schellong, 1939, Sulzer and Duchosal, 1945, Trocmé, 1946) As an argument in its favour it is sometimes put forward, that it is simpler, but it is not always realized that these systems are just as arbitrary as the equilateral triangle of Einthoven Measurements on a phantom indicate that from a quantitative standpoint, these systems do not improve matters In our opinion the lucky hit of Einthoven comes nearer to

the true state of affairs than the rectangular systems mentioned above

From some sides objections are raised against phantom measurements Indeed we shall appreciate every suggestion for improvements on our phantom Taking into account the internal structure of the human body, this might be a rational way to approach the truth nearer and nearer as regards the numerical values of the coefficients a, b, c

The attempts made by physicians to give the relation between heart-vector and leads have always led to geometrical representations (triangle rule, rectangular systems, equilateral tetrahedron) From these representations the analytical conclusions are drawn only in the second place and the result is given as a formula This, however, is a non-physical line of thought The physical laws, governing the electric current density in the trunk as a consequence of the heart action, are of an analytical nature and this is also the case with their general consequence equation (1) One can proceed from this equation and it suffices in practice to find the heart-vector

It cannot be denied, however, that a geometrical representation can be useful for the sake of an easy survey, but it has to be based on equation (1) Mathematically one has to derive from (1) the *general* geometrical representation, which is equivalent to this equation

Those, who are acquainted with the vector calculus can deduce this representation from (1) The lead (=potential difference) is a scalar (undirected) quantity, i e a quantity characterized by only one single number, independent of the choice of the direction of the co-ordinate axes * The quantities X, Y, Z are vector components determining together the heart-vector The value of each of these quantities depends on the choice of the direction of the axes With another choice of the axes, therefore, we have three other components X', Y', Z' Their resultant, however, is the same heart-vector Choosing other directions of the axes, the components X, Y, Z will vary, while $aX+bY+cZ$ must remain the same Therefore, a, b, c must vary too, i e depend on the direction of the axes It can be proved that they are the components of a vector $\overrightarrow{(a, b, c)}$ The relation between this vector $\overrightarrow{(a, b, c)}$, the heart-vector $\overrightarrow{(X, Y, Z)}$ (or $\vec{H}$) and the scalar lead can be represented geometrically The lead is the product of the projection of $\vec{H}$ on $\overrightarrow{(a, b, c)}$ and the length $\overrightarrow{(a, b, c)}$ of this last vector φ being the angle between the two vectors, this relation can be denoted in a more symmetrical form

$$\text{Lead} = \vec{H} \quad \overrightarrow{(a, b, c)} \cos \varphi \qquad (2)$$

This formula is analogous to the well-known relation

$$work = force \times displacement \times \cos \varphi$$

The work is the scalar product of force and displacement just as in our case the lead is the scalar product of the vector $\overrightarrow{(a, b, c)}$ and heart-vector $\vec{H}$

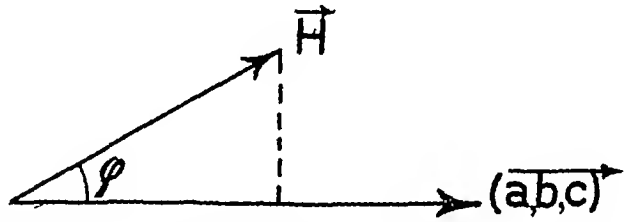

FIG 1 —A lead is the product of the projection of the heart-vector $\vec{H}$ on the vector $\overrightarrow{(a,b,c)}$ and the length of the latter

To determine X, Y, Z (i e $\vec{H}$) we need three equations of the type (1) and, therefore, three leads (mutually independent) For simplicity we shall suppose that they have one electrode in common, for which as a rule the left leg (F) is taken If the potential differences between three electrodes and F are known, we have three equations (1) to solve the three unknowns X, Y, Z Interpreted geometrically, this means that there are three vectors $\overrightarrow{(a, b, c)}$, originating in a common point, corresponding to F (Fig 2) The end points of these vectors correspond to the other three electrodes 1, 2, and 3, the position of which can be chosen arbitrarily The points F 1 2 3 form a non-equilateral tetrahedron, the shape of which depends on the position of the electrodes on the body The position of the tetrahedron, i e the direction of its edges with respect to the body is fixed, but it is obvious that its place may be chosen arbitrarily

This tetrahedron makes it possible to represent geometrically the relation between heart-vector and leads In order to determine lead (12), for example, the heart-vector must be projected on the edge (12) and the projection must be multiplied by the length of this edge (formula 2)

For a description of a general relation between heart-vector and leads a restriction to the three points 1, 2, 3 is not allowed With each point on the surface of our body corresponds a point in the space of the tetrahedron F 1 2 3 All those points, 4, 5, 6, together form a surface, on which are also situated the points F 1 2 3 An arbitrary point, say 10, can

* Other examples of scalar quantities are temperature, mass, time

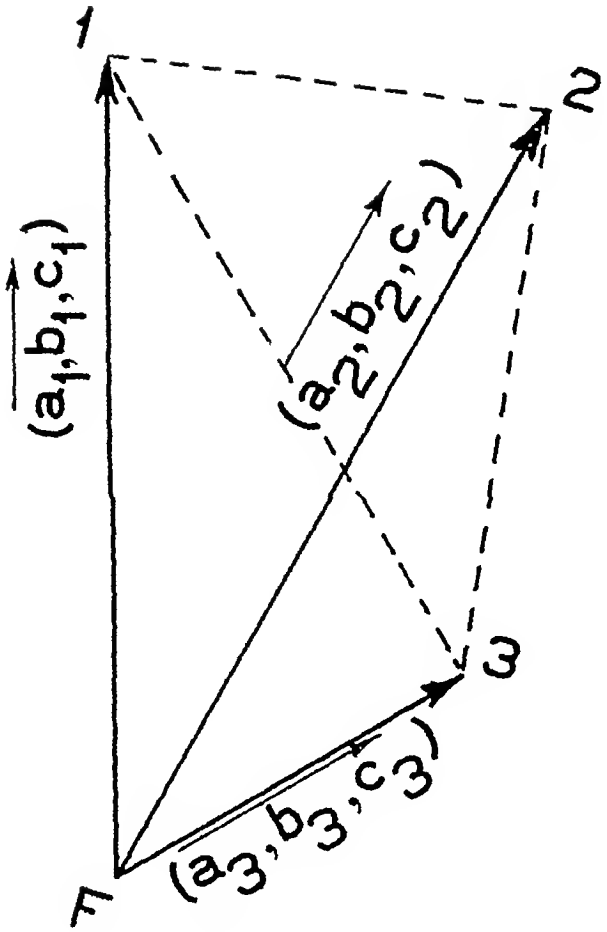

FIG 2—Three vectors $\overrightarrow{(a_1b_1c_1)}$ $\overrightarrow{(a_2b_2c_2)}$ and $\overrightarrow{(a_3b_3c_3)}$ determining a tetrahedron with which the relation between the heart-vector and three leads can be described

be determined with the aid of the phantom in the following way In this phantom an electrode is applied in a position corresponding to the position of the electrode 10 on the body of the patient On the phantom lead 10 F, i e the potential difference of the electrodes 10 and F, arising from the known components X, Y, Z of the vector of the artificial heart, is measured The proportionality of actors being a_{10}, b_{10}, c_{10}, the lead is given by

$$Lead\ 10\ F = a_{10}X + b_{10}Y + c_{10}Z$$

In the space of the tetrahedron F 1 2 3 the vector $\overrightarrow{a_{10}, b_{10}, c_{10}}$ is drawn, the end-point of which has the co-ordinates a_{10}, b_{10}, c_{10} This point is the "image" of the position of the electrode 10 on the surface of the body of the patient The above mentioned surface, formed by all image-points (Fig 3) can be used as follows, to find the relation between the heart-vector and any lead Let p and q be two arbitrary positions of electrodes on the surface of the

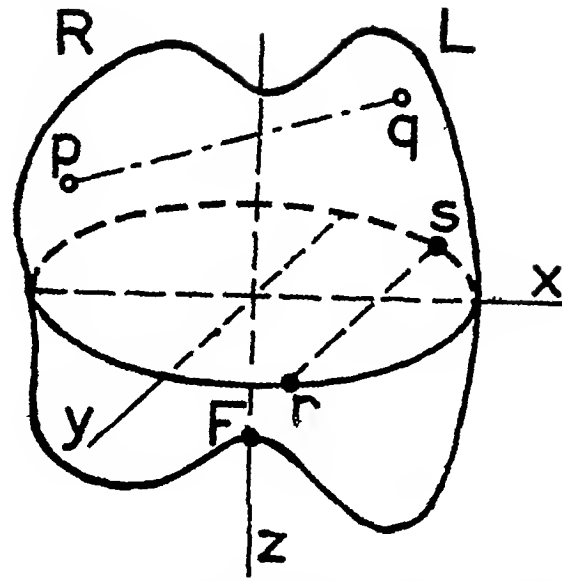

FIG 3—Surface in the image-space, corresponding to the surface of the human body X, Y, Z=co-ordinate axes, r and s=images of two electrodes, which give a potential difference, depending on the Y-component of the heart-vector only.

body These give on the surface of Fig 3 the "image-points" p, q Now, lead pq equals the product of the projection of the heart-vector, drawn in the correct direction in the image-space, on the line pq and the length of this line (formula 2) It is possible to reverse this process and to deduce in a way, which we shall not explain here, the heart-vector from three leads, the image-surface of Fig 3 being given

An electrode within the body has also an image-point which can be found with the aid of the phantom Such points are situated in the image-space outside the surface of Fig 3 so that, the nearer the electrode inside the human body is to the heart, the farther away they lie

In a preceding paper (Burger and van Milaan, 1947) pairs of electrodes on the surface of the human body are mentioned, giving a potential difference that depends on one component of the heart-vector only Then in equation (1) two coefficients are zero e g $Lead = aX$ The geometrical representation enables us to take a simple view of the problem If a lead for example has to be found depending only on the postero-anterior component Y of the heart-vector, the projections of the X and Z component on the line joining-the image-points of the electrodes must be zero This line, therefore, *in the image* must be parallel to the Y-axis In Fig 3, r and s are the images of electrodes, fulfilling this requirement. The relation between the position of the electrodes and the image-point

being known, the place where the electrodes must be applied is determined It follows from the figure, that an infinite number of combinations *rs* meet the requirement It is possible to choose one electrode for instance arbitrarily The other one (*s*) is found as the point of intersection of the line *rs* (parallel to the *Y*-axis) and the surface of the image To use this method efficiently a practical combination must be chosen out of the infinite number of possibilities

This geometrical representation can serve also for elucidating the meaning of the central terminal, introduced by Wilson (1935) This electrode is not applied on the surface of the body, but is the junction *CT* (Fig 4) of the ends of three equal resistances connected to the electrodes *R*, *L*, and *F* If these resistances are high enough, it is easily proved, that the potential of *CT* is the mean of the potentials of the electrodes *R*, *L*, and *F* As it is not the potential itself that matters, but only the potential differences, it is formulated better by saying that the potential difference of *CT* and an arbitrary electrode is the mean of the potential differences of *R*, *L*, and *F* and this electrode

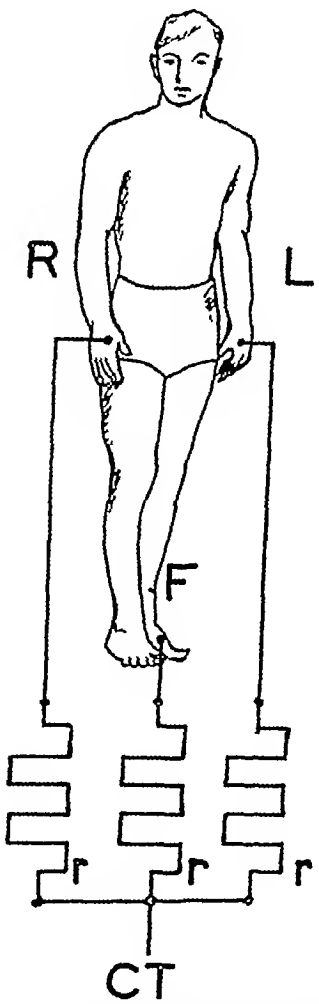

Fig 4 —The central terminal *CT* is the junction of the ends of three equal resistances *r*, connected to the electrodes *R*, *L*, and *F*

It can be proved, that it is possible to indicate a point in the image-space (Fig 3) corresponding to the central terminal This image-point is the centre of gravity of triangle *RLF* This point can be used for the geometrical determination of leads just as was explained above for points on the image-surface

The image-point of the central terminal is situated inside that part of the image-space, that is enclosed by the image-surface It is a point, that does not possess the special properties of the upper or lower side, the right or the left side of the image-surface Inside this it occupies a more or less central position, ignoring the fact that the surface image at the front of the plane *RLF* (and of *CT*) has a much greater extension than at the back The image has a pigeon breast

Interpreted geometrically in this way, the central position of Wilson's central terminal seems to be explained satisfactorily A more exact definition of a central point, in which not only the points *RLF* are involved, but all the points of the surface of the body, is possible but seems to be hardly worth while

It may be asked whether it is possible to obtain a point of mean potential with three electrodes other than *RLF* in such a way, that this point has no potential difference with the central terminal This can be realized fairly approximately by experiment (personal communication by J B Kleyn) It can moreover be deduced from our geometrical considerations, that this can be obtained exactly and even in an infinite number of different ways For there are an infinite number of triangles in the image-space, of which the angular points are situated on the image-surface and of which the centre of gravity coincides with the image-point of the central terminal This, however, does not hold good for the image of the central terminal only, but for every point inside the image-surface

In the preceding it has always been supposed, that the dimensions of the heart are very small compared with those of the trunk In reality this is not the case so that the image-surface will depend on the position of that part of the heart muscle, of which the action is being studied Comparing diametrically situated parts of the heart-muscle (e g heart point and heart base) this difference is appreciable as revealed by measurements on a phantom But on the average the distances are much smaller so that in a first approximation this effect may be neglected This, however, holds good only if the electrodes are applied at a rather large distance from

the heart, as is the case for *R*, *L*, and *F* A præcordial electrode, however, will be situated too near to the heart The part of the heart muscle near the thoracic wall will contribute to the præcordial lead relatively more than the other parts It is true that this reduces the value of the preceding considerations But on the other hand it may enable one to find the place of disturbances in different parts of the heart muscle This is understood quite well by physicians and it is for this very purpose that the præcordial leads are recommended But the relation between the place of the defect and the electrocardiogram is determined in an empirical way only A more correct comprehension of this relation is only to be obtained by a generalization of the exact physical treatment of the problem

Summary

The relation between heart-vector and leads can be represented geometrically This representation is a generalization of Einthoven's triangle It is possible to elucidate the meaning of the central terminal, proposed by Wilson

References

Burger, H C, and van Milaan, J B (1943) *Acta med scand*, **114**, 584
——, —— (1946) *Brit Heart J*, **8**, 157
——, —— (1947) *Ibid*, **9**, 154
Fahr, G, and Weber, A (1915) *Dtsch Arch Klin Med*, 117
Schellong, F (1939) *Grundzüge einer klinischen Vektordiagraphie des Herzen*, Berlin, Springer
Storm, C J, (1936) *Thesis*, Batavia
Sulzer, R, and Duchosal, P W (1945) *Cardiologia*, IX, Fasc **1/2**, 106
Trocmé, Ch (1946) *Arch Mal Coeur*, **39**, 80
de Waart, A, and Storm, C J, (1935) *Arch Neerl Physiol* **20**, 255
Wilson, F N, Johnston, F D, Macleod, A G, and Barker, P S (1935) *Amer Heart J* **9**, 447
——, ——, and Kossmann, C F (1947) *Ibid*, **33**, 594

VENTRICULAR ESCAPE IN ACUTE RHEUMATISM

BY

ALAN C KIRBY

From the Alder Hey Hospital and the Department of Child Health, University of Liverpool

Received July 20, 1948

Ventricular escape can be produced by depression of the sino-auricular node as a result of digitalis therapy, marked sinus arrhythmia, sinus bradycardia, or pressure on a hyperirritable carotid sinus, or by hyperirritability of the auriculo-ventricular node The latter type is the one referred to here It is differentiated from auriculo-ventricular dissociation due to complete heart block by the fact that the ventricles beat at the same or a more rapid rate than the auricles There is no general agreement about the ultimate mechanism of its production The most likely and usually accepted cause is irritation of the node by adjacent pathological changes, such as transient œdema around a rheumatic nodule or cellular infiltration of the node with or without endarteritis in the small vessels supplying it (Gross and Fried, 1936, quoted by Stein and Bartlett, 1946) Stimulation of the sympathetic or paralysis of the vagus supply to the node consequent upon the same rheumatic process could have a similar effect There is also no agreement as to its significance in prognosis Dressler (1930) found that it occurs during the course of acute articular rheumatism Stein and Bartlett (1946) state that it must not be regarded as an expression of the natural cardiac mechanism, that it is transient, and that it probably bears no relation to the outcome of acute rheumatism They state, however, that once a complete heart block has been excluded it is reasonable to give a good prognosis Wendkos and Noll (1944) had previously arrived at the same conclusion Cutts (1937) does not concur but agrees with Richardson (1915) that auriculo-ventricular dissociation due to ventricular escape is not of itself serious but that it is frequently associated with severe infection or severe and chronic heart disease

Two cases of acute rheumatism have recently been seen at Alder Hey Hospital exhibiting ventricular escape

Case Notes

Case 1 This patient was a girl of 11 years who had suffered with recurrent attacks of tonsillitis until the age of 7, when her tonsils were removed From that time until six days before admission to hospital she had no further attacks She was sent home from school complaining of a sore throat and pain in the back and thighs On the day of admission the pain in the legs, particularly the knees, was severe enough to make her cry if moved

On examination the temperature was 99 4° F , and the pulse rate 128 a minute She was thin, pale, and apprehensive, there was no dyspnœa nor cyanosis The throat was slightly injected with no visible tonsillar tissue and no membrane The tonsillar glands were a little enlarged and tender Both knees were painful on movement, which was limited to 45°, and tender to touch There was no redness or swelling and rheumatic nodules were not found The pulse was generally regular with occasional periods of irregularity The heart apex beat was in the fifth left intercostal space, 6 cm from the midline, the heart sounds were all softened and there were no murmurs Auscultation revealed the same cardiac arrhythmia as the pulse, which was considered to be due to extrasystoles

The condition was diagnosed as acute rheumatism and treatment was begun with sodium salicylate, 15 grains, and sodium bicarbonate, 20 grains, four-hourly, this was continued for four weeks

On the day following admission pain in the knees was less, but she complained of a dull præcordial pain which was eased by cataplasma kaolin The cardiac rhythm was regular, no change had taken place in the heart sounds Two days after admission the pain in the legs and præcordium had gone, and her general condition had improved The cardiac rhythm, however, was usually irregular except for brief periods The rate was still 110 to 130 a minute, in spite of this rapid rate the irregularity was typical of extrasystoles A cardiogram showed auriculo-ventricular dissociation, auricular rate 83 a minute, ventricular rate 107 a minute

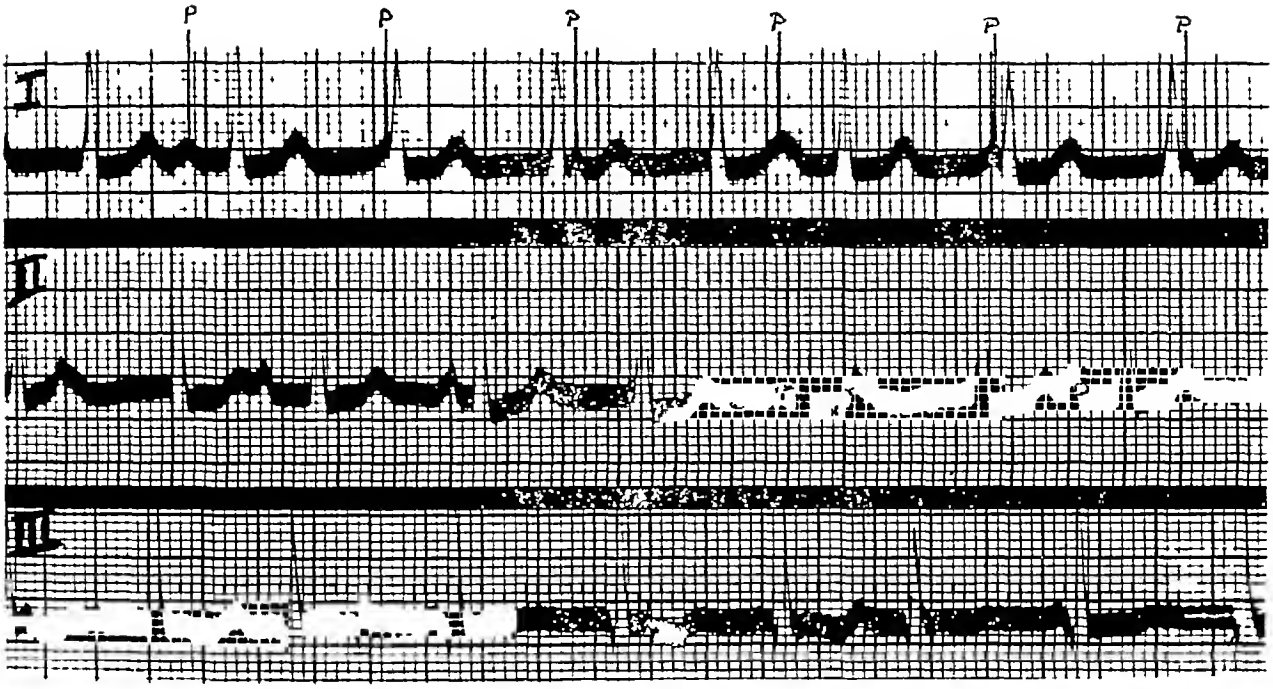

FIG 1 —Case 1 Ventricular escape Auricular rate 83 a minute, ventricular rate 107 a minute

(Fig 1) On the fourth day the cardiac rhythm was quite regular at a rate of 92 a minute The first apical sound was softened but the others were now clear and much louder The general condition continued to improve and by the end of another week the quality of all the heart sounds was good, but a soft localized apical systolic murmur had become evident Five weeks after admission, cardiac irregularity typical of extrasystoles was again noted, the rate being 75 a minute This was the only occasion on which irregularity had been found since the second day after admission A cardiogram showed sinus arrythmia and two dissimilar ventricular extrasystoles At the end of the sixth week in hospital she was regarded as convalescent and five weeks later she was discharged The heart sounds were normal but the apical systolic murmur, still soft and localized, persisted The cardiogram was normal The E S R , which had been 92 mm in the first hour (Westergren) on admission, was now 5 mm , and X-ray examination showed a normal cardiac outline

Case 2 A girl, aged 8 years Apart from scarlet fever at the age of five she had been well until 7 days before admission when she complained of severe pain behind both knees and was unable to walk The pain subsided after 24 hours For the next six days she complained of stiff knees on waking up in the mornings and occasional fleeting pains during the day She was feverish for two to three days before admission

On examination the temperature was 101° F , and the pulse rate 124 a minute She was flushed and the skin was hot and dry There was a fading erythema marginatum on the front of the chest and abdomen The tongue was furred but the throat appeared healthy The movements of the knee joints were full and there was no swelling or redness The pulse was regular, the heart apex beat in the fourth left intercostal space 6 cm from the midline, the pulmonary second sound accentuated, and there was a soft blowing apical and basal systolic murmur No abnormality was found in the lungs or abdomen, and there were no rheumatic nodules though a few were found late in the illness on the wrists and elbows A diagnosis of acute rheumatism with rheumatic carditis was made and treatment with calcium aspirin, 10 grains, t i d , was begun

The temperature settled after two days and the sleeping pulse rate fell to about 80 a minute X-ray examination showed the cardiac outline to be normal and the E S R was 79 mm (Westergren) Progress was good for 4 weeks but choreiform movements, which continued for 2 weeks, were then noticed, and an aortic diastolic murmur was heard The blood pressure in the arm was 100/70 mm Calcium aspirin was replaced by sodium salicylate, 15 grains, and sodium bicarbonate, 20 grains, four-hourly

Eight weeks after admission to hospital, the apex beat was located in the fifth left intercostal space 9 cm from the midline, and a late diastolic murmur of low rumbling quality was heard at the apex The child was pale and apathetic during the succeeding 2 weeks then the temperature which had been normal for 8 weeks rose to 102 4° F, but settled again after 3 days The pulse rate which had remained steady below 90 a minute increased to 120 to 130 a minute and the heart apex beat had become diffuse and tumultuous, 10 cm from the midline A fleeting scratchy pericardial friction rub was audible in the second left interspace adjacent to the sternum, this was heard on and off for the next 7 days The erythrocyte sedimentation rate was 83 mm and an X-ray examination now showed marked generalized cardiac enlargement The pulse rate continued between 120 and 130 a minute, and the blood pressure 105/20 mm Her general condition improved somewhat and remained so for another three weeks She then suddenly became dyspnœic and ashen grey in colour The pulse rate rose to around 150 a minute, the rhythm being grossly irregular Auricular fibrillation was diagnosed but a cardiogram showed A-V dissociation with regular auricular rhythm at a rate of 150 a minute The ventricular rate was approximately the same with occasional slowing At these times the sino-auricular node appeared to take charge of the ventricle, the P-R interval being 0 2 sec (Fig 2) Digoxin was administered for 48 hours On the next day slight pretibial œdema occurred and the liver had become enlarged to two fingers' breadth below the costal margin and was very tender The pulse rate had dropped to 100 a minute, the rhythm still being irregular, but the character of the irregularity had changed to one in which every sixth beat was dropped Auscultation revealed a similar rhythm but whereas every sixth beat was missing at the pulse the normal heart sound was replaced at these times by a solitary faint clicking sound, only audible at the base Later in the day the heart rate rose to between 130 and 140 a minute but otherwise no change occurred On the following day the heart rate was regular but a loud pericardial friction rub was heard at the base of the heart The liver was a little smaller and not so tender A cardiogram showed that the rhythm was normal at the rate of 136 a minute The P–R interval was prolonged to 0 2 sec (Fig 3) A week passed, her general condition was very poor but remained stationary The cardiac rhythm was found to be irregular again with every sixth beat missing, rate 140 to 150 a minute Auscultation revealed the same clicking sound

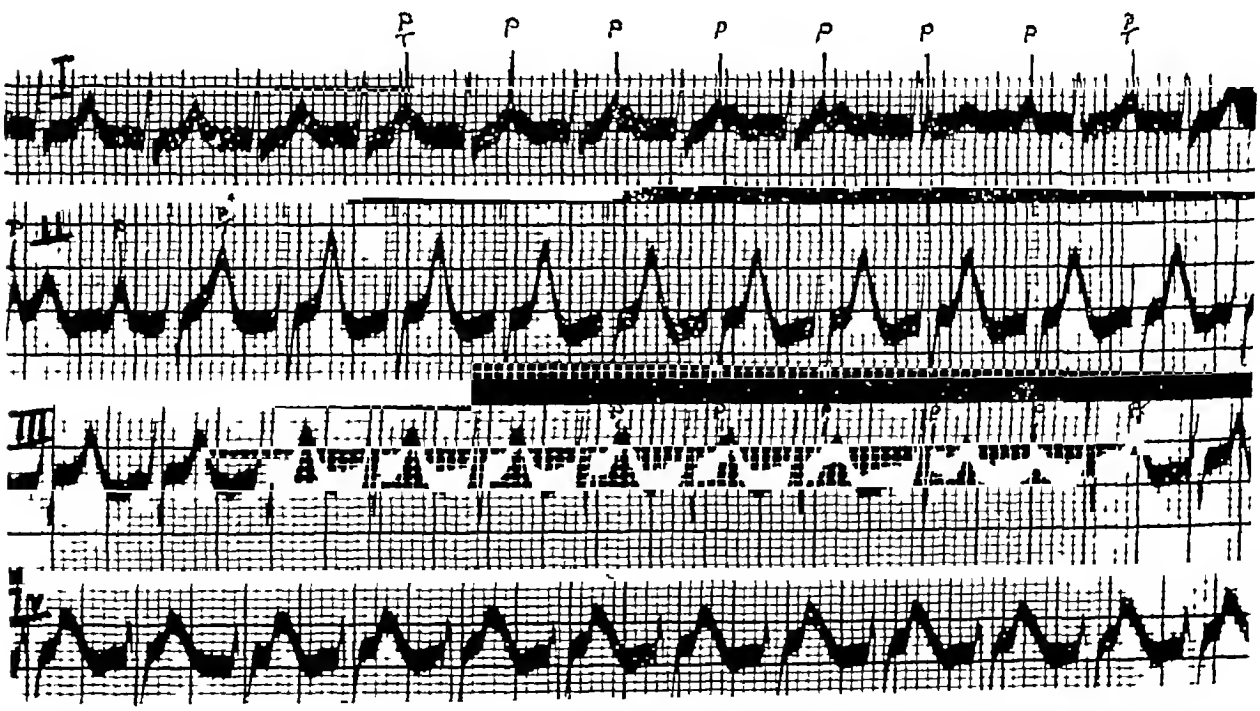

Fig 2 —Case 2 Ventricular escape Auricular rate 150 a minute, ventricular rate approximately the same with occasional slowing When this occurs an isolated complex results which originates in the sino auricular node the P–R interval being 0 2 sec

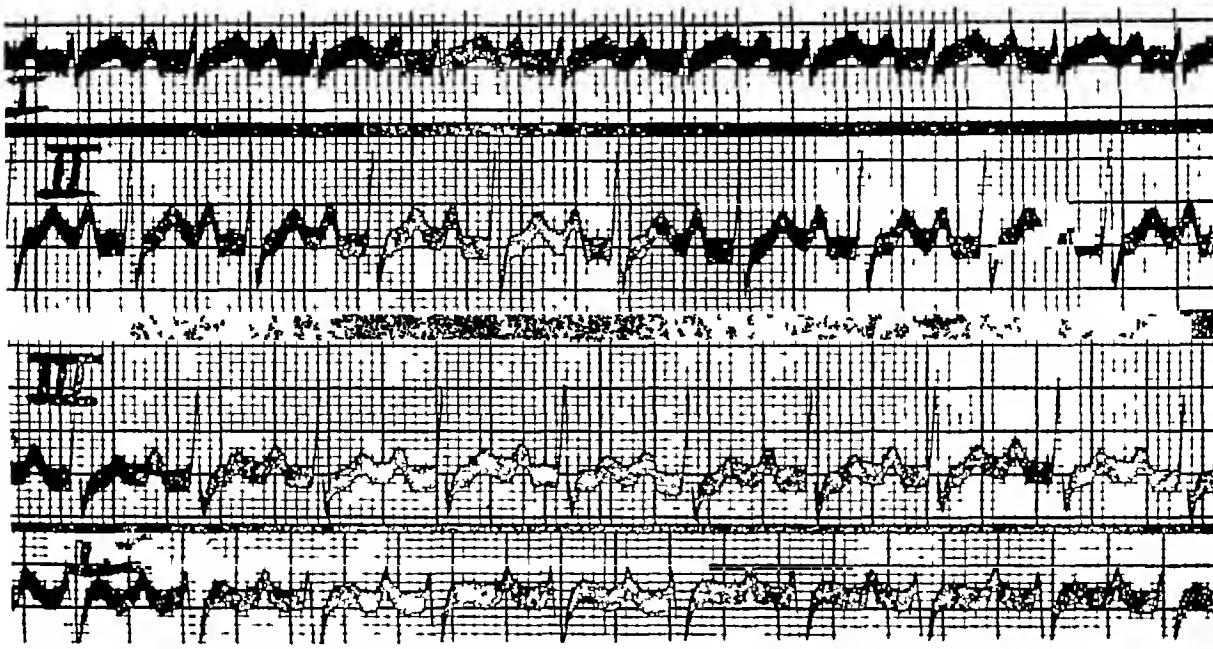

FIG 3 —Case 2 Normal sinus rhythm P–R interval 0 2 sec

replacing every sixth normal beat The pericardial friction rub could now be plainly heard all over the præcordium On the next morning she collapsed and died in 15 minutes

Necropsy Moderate wasting

Heart Marked fibrinous pericarditis with but a small amount of fluid present There was dilatation of both ventricles with softening of the myocardium The mitral valve showed typical rheumatic vegetations along the line of closure a " MacCallum patch " was present and a more generalized roughening of the endocardium of the left ventricle towards the apex The aortic valve was incompetent with recent rheumatic vegetations on the cusps Tricuspid and pulmonary valves appeared normal No evidence of previous rheumatic valvulitis

The *lungs* showed a few subpleural petechiæ only

The *liver* was enlarged and congested, the cut surface showed ' nutmeg " change

The *spleen* was enlarged by one and a half times normal size, the pulp firm with prominent follicles

The *kidneys* showed no gross abnormality

Other abdominal and pelvic viscera were normal

THE DIAGNOSIS OF VENTRICULAR ESCAPE

In the series of cases reported there would appear to be no specific signs or symptoms that could be attributed to ventricular escape alone White (1916) noted that one of his patients complained of palpitation and he found a cardiac irregularity that he ascribed to auricular extrasystoles Wilson (1915) had three patients who complained of intense palpitation during experimentally produced A-V dissociation Cutts (1937) mentions only one of his twelve cases as having subjective symptoms (" a jumping feeling in her chest ") but a number of them had unspecified cardiac irregularities Five of the twelve had a first heart sound that varied from being softened to loud and snapping Stein and Bartlett (1946) hold that a diagnosis cannot be made on clinical grounds, although auscultation may reveal an irregularity of rhythm similar to premature contractions or second degree heart block There may be no irregularity recognizable clinically Sudden rapid pulsation of the neck veins is said to be visible on occasion All the cases described in association with acute rheumatism would appear to have developed ventricular escape early in the course of the illness

The first described here had no symptoms and her arrhythmia was thought to be due to extrasystoles

The second case was most unusual because, firstly, the ventricular rate was much more rapid than in others described (generally it is between 80 and 110 a minute), and the irregularity was therefore taken to be due to auricular fibrillation, and, secondly, there was acute cardiac failure with dyspnœa, œdema, and a rapidly enlarging, tender liver

The discovery of an irregular rhythm with or without subjective symptoms, especially if associated

with a varying quality of the first heart sound and occurring in the course of acute rheumatism, usually early, should lead one to consider the possibility of ventricular escape and have an electrocardiogram recorded

The Significance of Ventricular Escape in Acute Rheumatism

It seems generally agreed that ventricular escape occurring early in the course of acute rheumatism is transient and not in itself serious, and as all the cases with rheumatic carditis in the series quoted seem to have recovered in two months or so, it would not seem to indicate severe rheumatic carditis Case 1 further supports this view The ventricular escape in Case 2, however, occurring late in the course of severe rheumatic pancarditis, may have been responsible for the onset of acute cardiac failure Furthermore although the second cardiogram taken when the rhythm was clinically regular showed no A-V dissociation, the subsequent clinical findings up to the time of death would suggest that it recurred It is therefore suggested that in this particular case death was almost certainly due to severe pancarditis, though the A-V dissociation due to the ventricular escape may possibly have hastened the end

Further electrocardiographic studies in cases of severe rheumatic carditis with cardiac failure, even when the rhythm is clinically regular might reveal that ventricular escape is more common and of more serious import than at present supposed

Summary

Two cases of ventricular escape occurring during the course of acute rheumatism are described One occurred early in the illness and is considered to be of little significance The other occurred late in the course of severe pancarditis and it may have been responsible for the onset of acute cardiac failure The auricular and ventricular rates in this case were unusually rapid

I wish to thank Professor N B Capon and Dr E Noble Chamberlain for their helpful advice and criticism during the preparation of this paper, also Dr W E Crosbie, Medical Superintendent of Alder Hey Children's Hospital for permission to publish these cases

References

Cutts, F B (1937) *Amer Heart J*, **13**, 453
Dressler, W (1930) *Wien Arch inn Med*, **19**, 611
Gross, L, and Fried, B M (1936) *Amer J Path*, **12**, 31
Richardson, H B (1915) *Arch intern Med*, **16**, 517
Wendkos, M H, and Noll, J (1944) *Med Clin North America*, **28**, 124
White, P D (1916) *Arch intern Med*, **18**, 244
Wilson, F N (1915) *Ibid*, **16**, 989
Stein, I, and Bartlett, A G (1946) *Amer J med Sci*, **211**, 686

DISSECTING ANEURYSM OF THE INTERVENTRICULAR SEPTUM*

BY

A A FITZGERALD PEEL

From the Cardiac Department, Victoria Infirmary, Glasgow

Received July 22, 1948

Bernheim (1910, 1915) first drew attention to the occurrence of right heart failure as a result of mechanical obstruction produced by bulging of a hypertrophied interventricular septum into the right ventricle A number of cases were later described by French and by Latin-American writers (Laubry, 1924, Martini and Joselwick, 1927, Bullrich, 1927 and 1928, Patiro-Mayer and Mazzei, 1928) Until recently, however, the condition has received little attention elsewhere Fishberg (1937) refers to it in his book on heart failure, Glushein and Geer (1944) report one case, and Russek and Zohman (1945) describe three, of which two were diagnosed during life The usual cause is hypertrophy of the septum occurring as an integral part of concentric left ventricular hypertrophy in cases of hypertension or aortic valvular disease The diagnosis can be made clinically where isolated right ventricular failure develops with a lesion that ordinarily causes left ventricular or combined failure

Rupture of the interventricular septum is an occasional sequel of coronary occlusion Wood (1944) found thirty-eight reported cases of which eight were diagnosed during life Rupture generally took place between the third and twelfth days The onset was associated with substernal pain and shock, followed by appearance of a murmur and thrill Cyanosis and dyspnœa were present in all reported cases except that of Wood herself, and death commonly resulted from right ventricular failure Only seven patients lived longer than four weeks, though one survived for four years and ten months

The present case differs from those in Wood's series in that the rupture of the interventricular septum was incomplete A dissecting aneurysm developed in the septum itself and produced bulging into the cavity of the right ventricle with obstruction of its outflow tract and signs of right ventricular failure

Case Report

Miss K, aged 59, had enjoyed good health save for one illness at the age of 49 when she had severe urticaria with vomiting for several weeks She had no cardiac symptoms prior to April 5, 1946, when she felt sick, vomited, and had pain in the back between the shoulder blades Pain persisted and she again vomited on April 9, on which day she first summoned Dr McNab, who found no abnormality of her heart or lungs She remained in bed for a week and during the next ten days she was up, going about slowly, her pain had subsided and she seemed convalescent On April 26, she suddenly became breathless but did not send for the doctor until the following day when he noted " extreme pallor, with systolic and diastolic murmurs that had not previously been present " From this time pallor persisted and breathlessness became more severe, but she had no further pain until the day of her death

She was first seen by me on May 6, 1946 She was of average nutrition with grey complexion, pale cyanosed lips, pale conjunctivæ, and breathlessness The jugular veins were distended and there was lumbar œdema The liver was enlarged, extending 4 cm below the costal margin The tongue was dry and furred, a faint smell of acetone was noted from the breath Coarse rales were present over a limited area at the base of each lung The pulse was of very poor quality, barely perceptible, and it was impossible to obtain a blood pressure reading The heart rate was 96 A feeble cardiac impulse could be felt, but there was no thrill, the apex was 11 cm from the midline, and the percussion dullness was increased both to right and to left The first heart sound was totally obscured by a loud blowing murmur which contrasted sharply with the feeble impulse and barely perceptible pulse, the murmur was heard over a very wide area both in the front and back of the chest, its intensity was maximal along a

* Communication to the III Inter-American Congress, June 1948

FIG 1 —Anterior surface of the heart, showing discoloured swollen area produced by the septal dissecting aneurysm Along the left border just above the apex, an area of slight bulging corresponding to an earlier myocardial infarct can be seen

FIG 2 —Interior of the left ventricle and septum viewed from the left, showing lamellated thrombus on the septum, perforation with everted upper lip, hypertrophy of left ventricle in its basal half, with fibrosis and thinning of the wall in the apical portion

line joining the fourth left chondro-sternal junction to the apex The second heart sound was inaudible and no diastolic murmur could be heard

The patient was admitted to hospital immediately Following admission she had several bouts of coughing with small hæmoptyses Her condition deteriorated and she died 33 hours later A cardiogram showed a Pardee curve of Q I, T I type with a small detached Q I, slightly elevated R–T I, small terminal inverted T I, and slightly negative R–T III A portable X-ray suggested enlargement of the heart both to left and to right, the superior vena caval shadow was prominent and there was moderate congestion of the lung fields

Post-mortem Examination (*Dr J Adler*) The pericardium contained 35 ml of straw-coloured fluid

The heart weighed 460 g On the anterior surface near the apex was an area of discolouration and swelling (Fig 1) measuring 55 × 45 mm, corresponding in position to the lower part of the interventricular septum and the apex of the right ventricle To the left of this, a second area showed slight bulging without discolouration, the myocardium here was thin, clearly representing an old infarct scar with aneurysmal dilatation Both areas were covered by a thin film of fibrin

The wall of the left ventricle was hypertrophied, being 23 mm thick at its base, as it approached the apex it became thin, its thickness being reduced to 1 5 mm at one point, and here the myocardium was largely replaced by a fibrous scar The apical half of the interventricular septum was covered by lamellated thrombus, the underlying septal myocardium was necrotic In the upper and anterior part of the septum there was a round perforation



FIG 3 —Interior of right auricle and ventricle, photographed from the right and below, so as to look into the pulmonary conus across which a glass rod has been placed The projecting portion of the septal aneurysm is seen on the right of the photograph, at the junction of the septum with the reflected anterior wall of the ventricle The photograph was made two years after the original examination of the specimen, at which time the aneurysm was opened, considerable shrinkage of the swelling occurred in the interval

10 mm in diameter, its upper lip was irregular, ragged, and everted so as to project into the cavity of the ventricle as a small flap (Fig 2) The perforation led into a dissecting aneurysm of the septum, after running forwards and towards the right till separated from the right ventricular cavity by a layer of tissue only 1 mm thick, it tracked downwards and forwards towards the apex and anterior wall of the right ventricle Where it emerged from the septum into the anterior wall of the ventricle, it produced the area of swelling and discolouration seen on the surface (see Fig 4)

The tissue separating the cavity of the aneurysm from that of the right ventricle consisted of endocardium with a thin layer of intact myocardium Viewed from the right ventricle, the aneurysm formed an irregularly oval swelling measuring 38 × 28 mm, and projecting into the cavity of the ventricle to a depth of 15 mm (Fig 3) This was situated at the junction of the septum with the anterior wall of the ventricle, being so placed as to project into the proximal half of the outflow tract On opening the aneurysm from the right side it was found to be partly filled by organizing thrombus The right ventricle was distended, but not much hypertrophied A small amount of adherent thrombus was present at its apex (Fig 4)

All valve cusps were healthy The right coronary artery was calcified along its entire length but was patent The anterior descending branch of the left coronary artery was the seat of extensive calcification, the vessel was much reduced in calibre throughout its length, and it was occluded by a thrombus at a point 2 cm from its origin The circumflex branch of the left coronary artery showed patchy atheromatous calcification

Calcification was present also in the arteries at the base of the brain The kidneys showed fibrosis and hyalinization of some glomeruli The lungs were chronically congested with several recent hæmorrhagic infarcts in each lower lobe Each pleural cavity contained 200 ml of fluid The remaining organs were congested

DISCUSSION AND SUMMARY

Post-mortem examination showed both old and recent myocardial infarcts The earlier infarct had

FIG 4—Interior of the right ventricle which has been opened along the junction of its anterior wall with the septum, in so doing the aneurysm has been cut through and a portion has been turned back with the anterior wall The cavity is approximately two-thirds filled with adherent thrombus, its relation to the area of surface discolouration is shown

affected the left ventricle near the apex producing aneurysmal dilatation of the affected area This lesion was certainly of some years' standing Despite the aneurysmal dilatation that followed the initial infarct in a woman who had clearly been hypertensive, there was no admission of incapacity or disability, and the patient's only previous illness did not suggest cardiac disease

The more recent coronary occlusion gave rise to infarction of the septum and appeared to correspond to the onset of her final illness on April 5, 1946 It was not associated with præcordial or substernal pain but with pain in the back Perforation into the septum occurred on the twenty-first day, it was associated with sudden breathlessness, pallor, and appearance of a bruit de Roger, there was no thrill The murmur, which clinically resembled that heard with a congenital ventricular septal defect, is difficult to explain in the absence of a "through and through" perforation Two possible mechanisms suggest themselves, the everted upper lip of the perforation might have produced such a murmur, alternatively, it may have arisen in the right ventricle from slackening of the chordæ tendineæ and tricuspid curtain, consequent on displacement of the papillary muscle by the aneurysm The subsequent features of the illness were those of progressive right ventricular failure, coupled with signs suggesting a low cardiac output, they are attributed in part to mechanical obstruction of the outflow tract of the right ventricle by protrusion of the septal aneurysm into it, and in part, to disease of the myocardium The clinical picture was further complicated by the occurrence of terminal lung infarcts Death took place on the twelfth day after the rupture

The fact that rupture in this case led to a dissecting aneurysm instead of a "through and through" perforation, seems to be related to the survival of a thin layer of myocardium immediately beneath the endocardium of the right ventricle, the aneurysm tracked along the line of demarcation between necrotic and intact muscle

References

Bernheim (1910) *Rev Medecine*, **30**, 785
—— (1915) *J de Practiciens*, Nov 13, quoted from Glushein and Geer (1944)
Bullrich, R A (1927) *Rev med lat -amer*, **12**, 31
—— (1928) *Ibid* **13**, 1839
Fishberg, A M (1937) *Heart Failure*, London, p 432
Glushein, A S, and Geer, J A (1944) *M Bull vet Admin*, **20**, 277
Laubry, C (1924) *Bull Mem Soc méd Hôp Paris*, **48**, 831
Martini, T, and Joselwick, M (1927) *Sem med*, **34** (11), 11
Patiro-Mayer, C, and Mazzei, E S (1928) *Rev med lat -amer*, **13**, 2015
Russek, H I, and Zohman, B L (1945) *Amer Heart J*, **30**, 427
Wood, Anne M (1944) *Brit Heart J*, **6**, 191

LONG SURVIVAL WITH A CARDIAC ANEURYSM

BY

A CODOUNIS

From the III Medical Clinic of the Hospital of the Greek Red Cross, Athens

Received July 24, 1948

Although rarely reported, cardiac aneurysms are not purely pathological curiosities that are discovered by chance at autopsy They can sometimes be recognized during life by correlation of clinical and radiographic findings Thus, a history of anginal pain, followed by pericarditis and recovery, should suggest the possible development of a parietal aneurysm of the heart, if the patient survives long enough Further, in spite of the usually accepted view, it is not true to assert that the prognosis of such chronic aneurysms is necessarily bad Thus, I have been able to follow the development of such a condition for some 13 years in a man who is still free from symptoms

There are not many reports of long survival after the development of a cardiac aneurysm, but Laubry *et al* (1930) mention two patients who lived 10 and 12 years respectively, while Clerc and Deschamps (1931) observed survival for 13 years

My case was that of an agricultural engineer, aged 45, whose illness started with a series of mild anginal attacks, with considerable intervals between them, over a period of about 5 years On October 25, 1935, after a more severe physical effort than usual, he developed extremely severe præcordial pain, which could not be alleviated completely by any drugs All the clinical features of coronary occlusion were present—fall of blood pressure, thready pulse, tachycardia, cyanosis, dyspnœa, sweating, anxiety, etc

Two days later, the temperature rose to 103, accompanied by rigors and signs of left-sided pleurisy Then, on the fourth day, pericarditis developed, dry at first, but with some effusion later

All the symptoms diminished in intensity from the twelfth day onwards, the temperature returning to normal, perhaps as the result of giving salicylates The patient left the hospital 48 days after the original attack

The radiographic changes are of particular importance, because they have been followed over a a period of 13 years

On the tenth day after the coronary occlusion, the heart was flask-shaped, and no pulsations could be detected, i e, the appearances were typical of pericardial effusion (Fig 1)

On the forty-second day of the stay in hospital, the cardiac shadow itself was within normal limits, but there was a small triangular prominence on the left border of the left ventricle, which, at that time, was wrongly interpreted as being due to a pericardial adhesion (Fig 2) This is now known to have been the early stage of a parietal aneurysm

Twenty months later, the aneurysm was obvious, the sac being relatively large (Fig 3) This appearance was detected fortuitously when the chest was being examined because of a suspicion of pulmonary tuberculosis , but it was not until September 18, 1940, five years after the original attack, that the real nature of the condition was recognized *

The teleradiograms taken at this time show clearly that the projection is continuous with the left ventricle, and, when screened in various positions, it was seen to dilate during systole of the left ventricle—the condition known as "paradoxical diastole" These appearances, considered in conjunction with the history, demonstrated clearly that the condition was a parietal aneurysm of the heart, not, as had tentatively been supposed, a tumour or a cyst, because these do not pulsate although these may show transmitted pulsation

Thus, for a period of five years after the attack of coronary occlusion, the diagnosis was uncertain, and had varied from tumour, myocardial cyst, and even a ordinary pericardial adhesion The present case bears out the old aphorism that, in order to diagnose a disease, it is necessary first to think of it If we had not considered the possibility of a parietal

* Translator's note Codounis makes no reference to the possibility that there may have been a pericardial adhesion, which played a part in causing the subsequent aneurysm

FIG 1 —31/10/35 Pericardial effusion after cardiac infarction

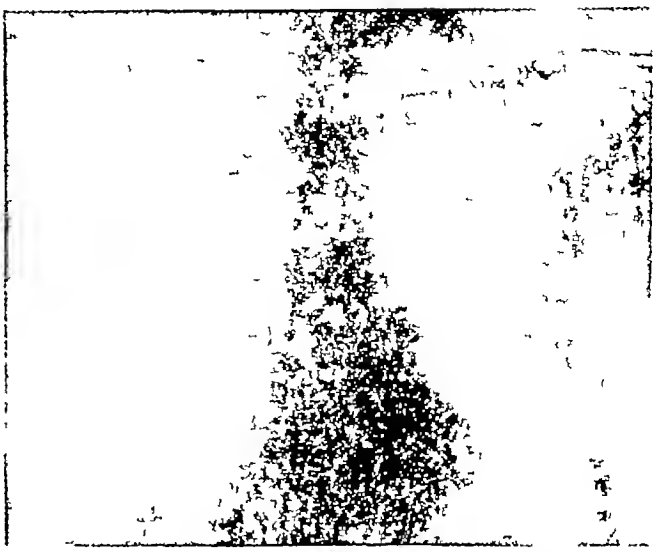

FIG 2 —3/12/35 (42 days after cardiac infarction) A small projection is seen on the left lateral wall of the left ventricle

FIG 3 —3/8/37 A large aneurysmal sac is visible



FIG 4 —18/7/40 The sac is still present, but shows a rather diffuse edge

aneurysm, we should not have attempted to demonstrate it by looking for paradoxical diastole a further proof, if one be needed, of the value of screening in cardiology

Fig 4, which was taken seven years after the attack of pericarditis, shows slight decrease in the size of the sac, which still shows the phenomenon of paradoxical diastole, although its density has changed a little, now being different from that of the ventricle Oddly enough, paradoxical diastole was even more striking than at earlier examinations

Towards the end of 1945, fifteen years after the beginning of the illness, the patient, who felt perfectly well, showed no clinical signs of heart disease except occasional slight anginal pain on exertion or after repeated bending From this time onwards, there has been little change in the radiographic appearances, except that the sac shows areas of increased density, which are, presumably, due to calcification a feature which was more easily recognized on screening than in films In spite of this, pulsation of the aneurysm was still distinctly visible

In our view orthodiagraphy is of less value than teleradiography and kymography, mainly because of the subjective element in the former, which leads to considerable differences between the orthodiagrams made by different radiologists, even on the same day

It seems clear that the radiographic history of the cardiac aneurysm recorded here has all the features that would be expected from our knowledge of myocardial infarction And the fact that the aneurysmal sac plays only a passive part during ventricular systole is consistent with the replacement of muscle fibres by scar-tissue

Differential diagnosis is not difficult in cases in which the phenomenon of paradoxical dilatation of the aneurysmal sac can be detected, but, if the contents become thrombosed or the wall becomes calcified, this may disappear Then, the possibility of such conditions as hydatid cyst, neoplasm, pericardial diverticulum, etc , will need to be considered

Again, large aneurysms of the heart may cause such great alteration in the cardiac outline as to cause possible confusion with pericardial effusion, but the invisibility of the heart-beat in that condition should prevent mistakes

Finally, coronary aneurysms present an identical radiographic appearance, but usually occur on the right, whereas parietal aneurysms are almost invariably left-sided Then also, coronary aneurysms are due to syphilis and develop insidiously, without any history of the type found in coronary thrombosis

Summary

A case illustrating the development of an aneurysm of the heart-wall during a period of 13 years is recorded in detail, and special attention is drawn to the occurrence of paradoxical diastole as an important diagnostic feature

References

Clerc, M A , Deschamps, N (1931) *Cœur et vaisseux in Précis de Pathologie Médicale*, Masson, Paris

Laubry, C *et al* (1930) *Maladies du cœur et des vaisseaux*, Doin, Paris

U WAVE INVERSION

BY

J H PALMER

From the Royal Victoria and the Queen Mary Veterans' Hospitals, Montreal

Received July 7 1948

The U wave, when first recognized by Einthoven (1906) in the earliest days of electrocardiography, was considered by him to be pathological Since then the normality of upright U waves, except perhaps in cases where they are unusually high (Katz, 1946), has been generally conceded Various hypotheses have been advanced to explain the U wave, of which the most satisfactory is that of Hoff and Nahum (1938) who concluded on experimental grounds that it undoubtedly forms part of the ventricular complex, and is coincident in time with the supernormal phase

The number of papers on the clinical significance of the U wave is small, and reflects the scant attention that seems to have been paid to it by most cardiologists Important articles however are those of Nahum and Hoff (1939), Papp (1940), and Solarz and Elek (1943), and to them the reader is referred for comprehensive reviews of the subject

Inversion of U has been considered pathological by most authors Nahum and Hoff found it in association with coronary, rheumatic, hypertensive, and pulmonary heart disease Papp reported it in coronary disease and in hypertension Solarz and Elek found 94 cases of U wave inversion in 1000 cases studied, they report on its association with the left heart strain pattern, intraventricular block, and anterior and posterior wall infarction

Negative U in Induced Angina

The writer's interest in negative U waves was stimulated by noticing their appearance in the after-exercise tracing of a patient with angina pectoris Subsequently six further such patients were found All were males, and in all of them pain was easily induced by effort None gave a history of a previous clinical attack of coronary occlusion Six of the seven had hypertension, all had cardiac X-ray silhouettes that were within the normal range In all except one (Case 7) test exercise was given to the point of just inducing pain, and the tracing was made as soon afterwards as possible Table I shows the degrees of U wave positivity and negativity both before and after exercise, in Table II are listed any other abnormal features of the electrocardiograms, as well as certain clinical data

TABLE I

THE U WAVE BEFORE AND AFTER EXERCISE IN ANGINA PECTORIS

Case		Lead I	Lead II	Lead III	Lead CF 2	Lead CF 4	Lead CF 5
1	Before	0	0	+	+	−	−
	After	−−	+	++	−−	−−−−	−−−−
2	Before	0	+	+		+	
	After	*	+	+		−−	
3	Before	+	+	0	+	+	+
	After	−	+	+	−	−−	−−
4	Before	0	0	+	++	+	−−
	After	−	0	+	+	−−	−−
5	Before	−	+	+	−	−−	−
	After	±	+	+	−−−	−−−−	−
6	Before	0	−	−	0	−−	0
	After	*	*	*	−	−−	−
7	Before	0	−−	−	++	+	0
	After **	±	−−	−−	++	+	0

0 = isoelectric + or − = less than 0 5 mm
+ = positive ++++ or −−−− = 1 5 to 2 0 mm
− = negative ± = diphasic
*Pulse rate 100 or more
**Exercise not carried to point of inducing pain.

In the control (or before-exercise) tracings, U was negative in one or more leads in five of the seven cases In two of this five U was inverted in the chest leads only, in two it was inverted in both chest and limb leads, and in one in limb leads only

It will be seen from Table I that in the six cases in which exercise was carried to the point of inducing pain, U became, after exercise, either (a) more negative if it was already inverted, (b) negative in additional leads in which it had previously been positive or isoelectric, or (c) both (a) and (b) Maximum negativity in these six was always in one

TABLE II

FINDINGS, IN SEVEN PATIENTS WITH ANGINA PECTORIS SHOWING U WAVE INVERSION

Case	Age	B P	Duration of Angina	Electrocardiogram: Before Exercise	Electrocardiogram: After Exercise
1	46	250/130	2 mth	Intraventricular conduction defect (QRS=0 11 sec), T negative in I, CF 2, CF 4, and CF 5	Depression RS–T in I, less negativity T in chest leads
2	65	190/95	1 yr	Diphasic T in CF 4	Depressed RS–T in II and III, positive T in CF 4
3	43	160/105	2 yr	None	Depression RS–T in CF 4, "coronary" type positive T waves in CF 4 which later became negative
4	61	170/190	10 yr	Diphasic T I and T II, negative T in CF 5	Depression RS–T in CF 4 "coronary" type positive T waves in CF 2 and CF 4
5	36	120/105	3 mth	Negative T in CF 2, CF 4, and CF 5	T positive and of "coronary type in CF 2 and CF 4
6	43	120/80	3 mth	Notching of S in CF 2, depressed RS–T (0 5 mm) in CF 4	Depression RS–T in CF 4
7	58	190/90	5 yr	None	None *

* Exercise not carried to point of inducing pain

or more of the chest leads In five of them it was possible to recognize a pattern consisting of inversion in lead I and in the chest leads, greatest in CF 4 with positivity of U in lead III (see Fig 1), in one case a positive U appeared in lead III where previously it had been isoelectric, and in another the positivity of U in lead III increased This pattern is reminiscent of the pattern of T wave inversion seen in anterior coronary occlusion In another case U was negative in leads II, III, and CF 4 before exercise, and after exercise became negative also in CF 2 and CF 5 In Case 7, where exercise was not carried to the point of inducing pain, U was negative in II and III, but positive in CF 2 and CF 4

In three cases there developed with exercise, in certain of the chest leads, an interesting pattern comprised of sharply pointed positive T waves with symmetrical shoulders which have previously been described as "coronary T waves" (Katz, 1946), and negative U waves (see Fig 2 and 3) This pattern has been seen by us only in patients with coronary insufficiency, whether or not it should be considered pathognomonic of this condition will depend upon further observations

A discordancy in the direction of the development of T wave and U wave potentials was seen in two patients In Case 5 (see Fig 3) the T wave had, in the control tracing, been negative, its change to positive with exercise was concurrent with the development of increased negativity of U Conversely, in Case 3 (see Fig 2) a negative U, which made its appearance immediately after exercise, was found to disappear five minutes later at the same time as T became negative

NEGATIVE U AS ISOLATED ABNORMALITY

Tracings in which U wave inversion constitutes the only cardiographic abnormality are probably uncommon Nahum and Hoff (1939) reported two cases, but the high T wave in lead IVR in one of them (their Fig 8) is probably abnormal In Papp's (1940) case there is a pathologically low take-off of the RS–T segment in IVR Solarz and Elek (1943) state that "no abnormal U waves were found in the absence of other abnormalities in the electrocardiogram," and that therefore "there is not much diagnostic value in the recognition of U wave patterns" It seems difficult however for them to justify this conclusion, in view of their having studied only tracings that had been chosen for their abnormality Katz (1946) observes that abnormalities of U rarely occur in the absence of abnormalities of S–T–T and believes that "little clinical weight would be given to an electrocardiogram in which the only deviation from the normal was in the U wave"

The writer has records of three cases in which no trace of abnormality other than U wave inversion could be made out The first patient (see Fig 4) suffered from Paget's disease and severe hypertension, and at the time that the tracing was made was actually in congestive failure The second had angina pectoris (Case 7 of present series) The third was a patient suffering from polycystic kidney disease with uræmia and severe hypertension

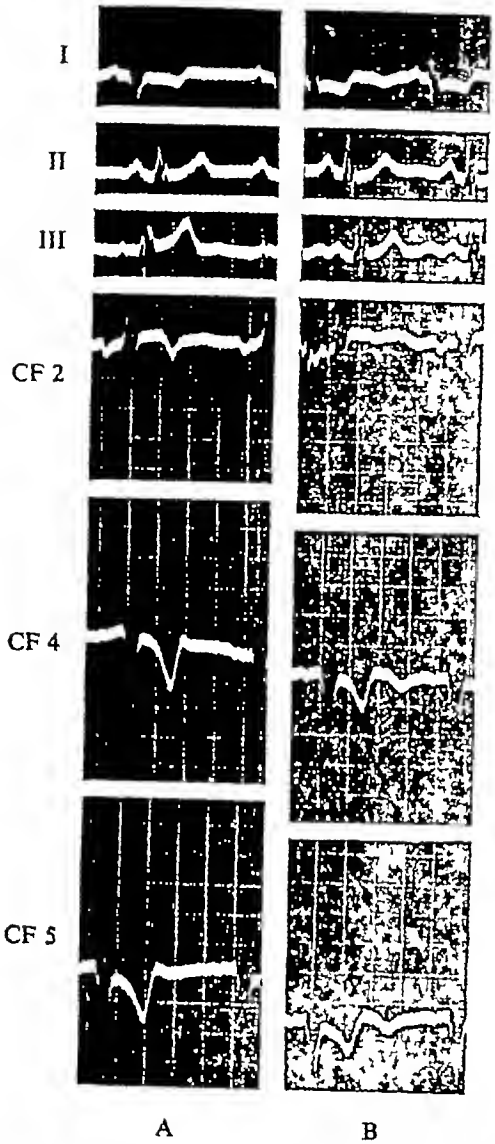

FIG 1—Case 1 Man, aged 46, with severe hypertension and angina pectoris Tracings (A) before and (B) immediately after pain-inducing exercise Note wide QRS With exercise negative U appears in leads I and CF 2, U becomes more negative in CF 4 and CF 5, and more positive in III Fig reduced by ⅓

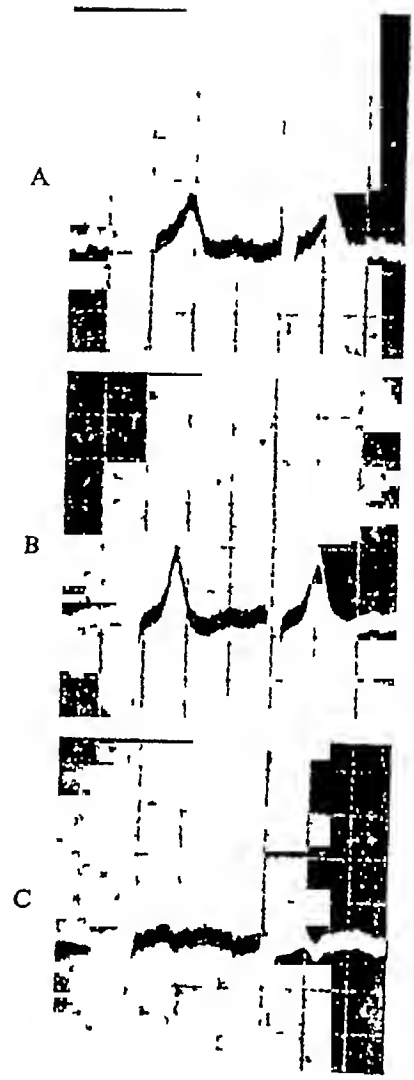

FIG 2—Case 3 Lead CF 4 (A) Before, (B) immediately after, and (C) five minutes after Note appearance of "coronary T" and negative U immediately after exercise Five minutes later T has become negative and U isoelectric

In another patient with mitral stenosis the only additional abnormalities were a large P wave in lead II and a prominent S in lead I, the U wave was only detected when the tracing was compared with a previous one taken when the patient had been digitalized (see Fig 5)

In none of the tracings made immediately after pain-evoking exercise was inversion of U the sole abnormality In two cases however the only other findings were a slight depression of the RS–T segment in lead CF 4, and the appearance of symmetrical T waves

NEGATIVE U IN INTRAVENTRICULAR BLOCK

U wave inversion in bundle branch block is described by Nahum and Hoff (1939) and by Papp (1940) Solarz and Elek (1943) failed to find it in 75 consecutive cases of intraventricular block of the S type, but saw it in 17 of 135 cases of the common type the general pattern was negativity in leads I

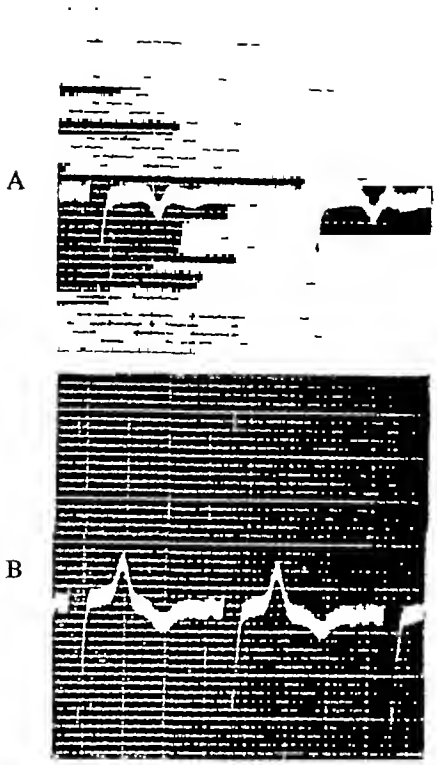

FIG 3—Case 5 Lead CF 4 (A) Before and (B) after exercise Note development with exercise of positive "coronary T" concurrently with increase in negativity of U

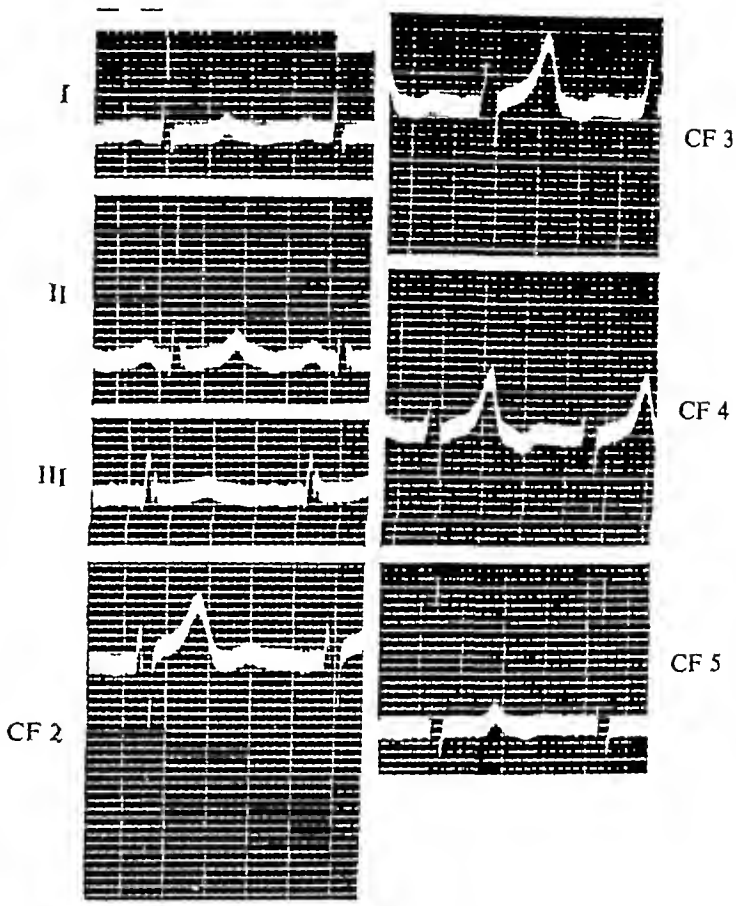

FIG 4—Case 8 See text Note U wave inversion as only abnormality negative U in I and II and in the left chest leads with diphasic transition U wave in CF 3

and CF 4, with upright or isoelectric U waves in leads II and III

In Case 1 of the present series QRS had a duration of 0 11 sec and its configuration was of indeterminate type The patient's pain was easily induced, and appeared when the heart rate had risen from 62 to only 75, the sole significant resulting cardiographic changes were pronounced alterations in the U wave (see legend, Fig 1) It is difficult not to conclude that the U wave changes here, and perhaps also those found in other cases where there was an associated intraventricular block, are actually related to myocardial alterations rather than to conduction defects as such

VARIATION OF R–U DURATION

We have not been able to corroborate Papp's (1940) observation that with exercise the R–U time remains relatively constant irrespective of the heart rate On the other hand we found in two of our cases that R–U was shortened by as much as 0 12 sec during exercise, even though the heart rate increased only from 62 to 80, and from 65 to 85 respectively

SUMMARY AND CONCLUSIONS

The appearance of temporary U wave inversion during anginal attacks induced by exercise is described

The pattern of U wave inversion seen most frequently is made up of negativity in lead I and in the left chest leads, and positivity in lead III

The association in individual chest leads of sharply pointed, symmetrical, positive T waves with inverted U waves in patients with angina pectoris during exercise is described

Discordancy in direction of development of T and U may occur in the chest leads during exercise

Four cases are described of inversion of U in one or more leads as an isolated electrocardiographic abnormality

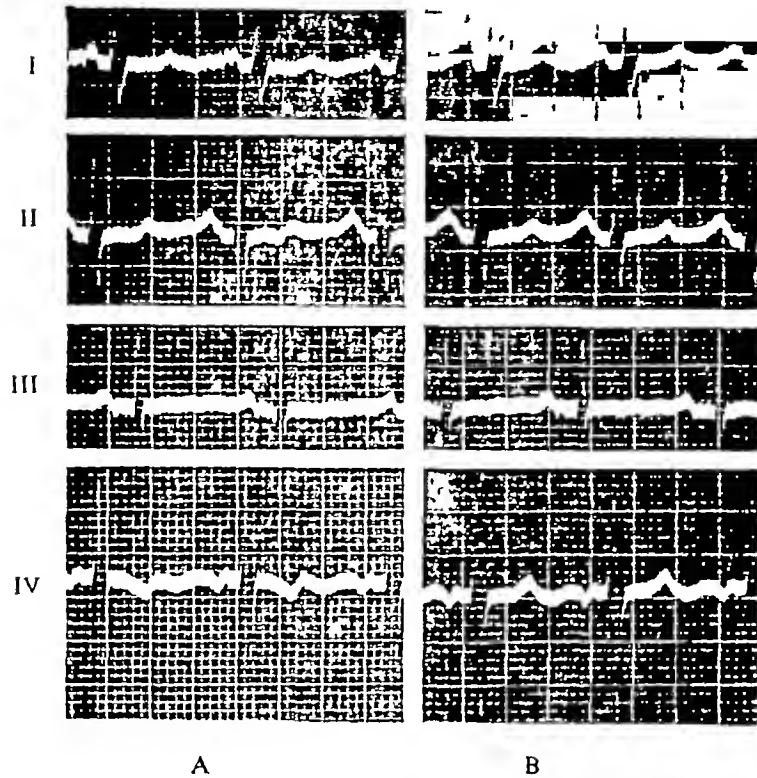

FIG 5—Case 9 Woman, aged 39, with mitral stenosis Tracings taken (A) during digitalis therapy and (B) ten days after cessation Note that T IV has become positive but that negative U waves in I and IV have persisted

Inversion of U when seen in tracings showing bundle branch lesions is probably the result of associated myocardial damage rather than of the conduction defect as such

The R–U time interval may decrease as the heart rate increases

Inversion of U in one or more leads should always be considered pathological

REFERENCES

Einthoven, W (1906) *Arch internat Physiol*, 4, 132
Hoff H E, and Nahum, L H (1938) *Amer J Physiol*, 124, 591
Katz, L (1946) *Electrocardiography*, 2nd ed, Philadelphia, p 121
Nahum, L H, and Hoff, H E (1939) *Amer Heart J*, 17, 585
Papp, C (1940) *Brit Heart J*, 2, 9
Solarz, S D, and Elek, S R (1943) *J Lab clin Med*, 28, 936

R

CARDIAC LESIONS IN THIAMIN DEFICIENCY

BY

J FRANK PANTRIDGE

From the Department of Pathology, Queen's University, and Royal Victoria Hospital, Belfast

Received July 22 1948

Experience of beriberi occurring among British and Australian prisoners of war indicated that heart block was not infrequent

There is no general agreement about the effect of thiamin deficiency on the heart, and in particular on cardiac conduction The only electrocardiographic abnormality noted by Aalsmeer and Wenckebach (1929) was a shortening of the P–R interval Keefer (1930) in 29 cases of beriberi noted no characteristic cardiographic change, though cardiac conduction was sometimes slightly altered 15 of the 29 cases had evidence of cardiac insufficiency, these showed enlargement of the right auricle, right ventricle, pulmonary conus, and pulmonary artery Jolliffe (1939) in experimental thiamin deficiency found cardiographic changes in 2 of 5 human volunteers in one, sinus arrhythmia, sinus arrest, and inversion of T III appeared after 11 days of deficiency, and in a second inversion of T III appeared after 8 days of deficiency The changes reported by Weiss and Wilkins (1937) and by Dustin *et al* (1939) included tachycardia, prolongation of electric systole, low voltage complexes, and flattening or inversion of T waves Dock (1940) recorded 5 cases of idiopathic cardiac hypertrophy with mural thrombi thought to result from thiamin deficiency, in 4 of whom there was disturbance of conduction—right bundle branch block in 3 and latent A-V block in 1 case Casanova (1946) observed flat bifid P waves, prolongation of the P–R interval, and auricular fibrillation (once) in beriberi

Most accounts of the pathology of the heart in beriberi have been limited to a description of the macroscopic abnormalities It is uncertain whether the enlargement of the right side of the heart is due to dilatation alone or to dilatation combined with hypertrophy

Weiss and Wilkins (1937) found that the weight of the heart was generally normal and that there was a moderate dilatation of the right ventricle Wenckebach (1934) and Weiss and Wilkins (1937) observed a hydropic degeneration of the muscle fibres

Disturbances of A-V conduction are not mentioned in most clinical accounts of beriberi and lesions affecting the specialized muscle of the conducting system have not been noted on histological examination Thus Blankenhorn (1945) gave as the first of the criteria for the diagnosis of beriberi heart disease " an enlarged heart with normal sino-auricular rhythm "

As there is no general recognition of the appearance of conduction defects in human thiamin deficiency it was thought advisable to record the clinical impression of its not infrequent occurrence In the light of our clinical experience it was considered that analysis of the effects upon cardiac conduction of prolonged severe thiamin deficiency in animals would be of value and should determine whether the changes present had a functional or organic basis

Experimental Methods

Pigs were used since they are known to be the animals most susceptible to thiamin deficiency The animals were obtained when five weeks old The dietetic method was largely that of Wintrobe (1942) This consists of feeding a basal vitamin-free diet The basal diet in this experiment consisted of sugar, crude casein and cooking fat, and provided approximately 150 calories per kg of body weight daily The daily supplements added to this diet were those used by Wintrobe (1943) With the exception of thiamin which was entirely omitted, these supplements contained synthetic vitamins and minerals in quantities known to be adequate to maintain the normal health and growth of the animals

Four pigs were kept on this diet Two additional pigs used as controls were given the same basal vitamin and mineral supplement, and in addition these control pigs were given 0 51 mg of thiamin hydrochloride per kg of body weight daily

Frequent electrocardiograms were obtained from all six animals Three standard leads and one chest lead CF 4 were used The normal variations in the

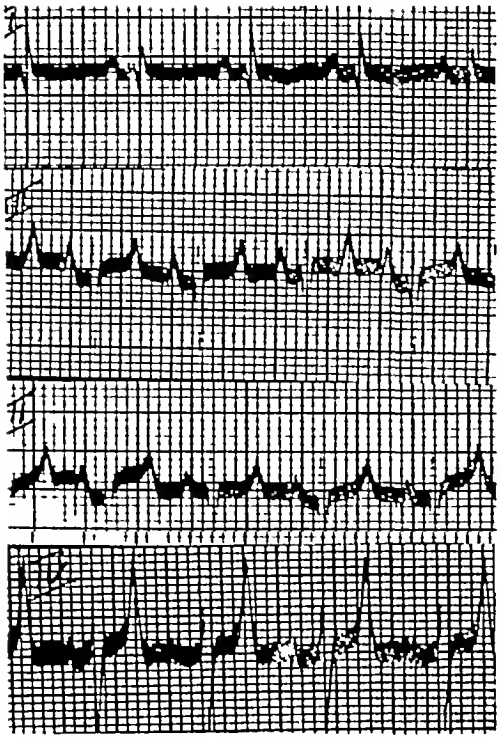

FIG 1 —Normal pig Standard limb leads and CF 4 The T wave in CF 4 is invariably upright

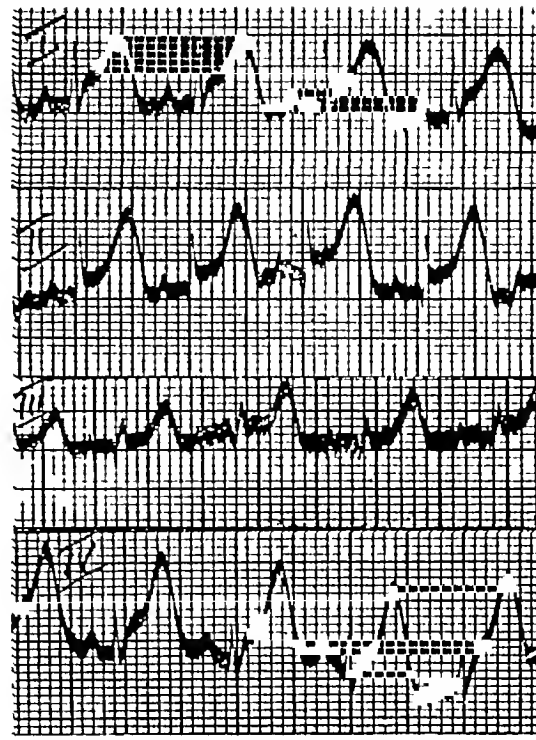

FIG 2 —Pig No 1 Standard leads and CF 4 on 73rd day of deficiency, 24 hours before death Huge T waves and elevation of S–T segment in all leads

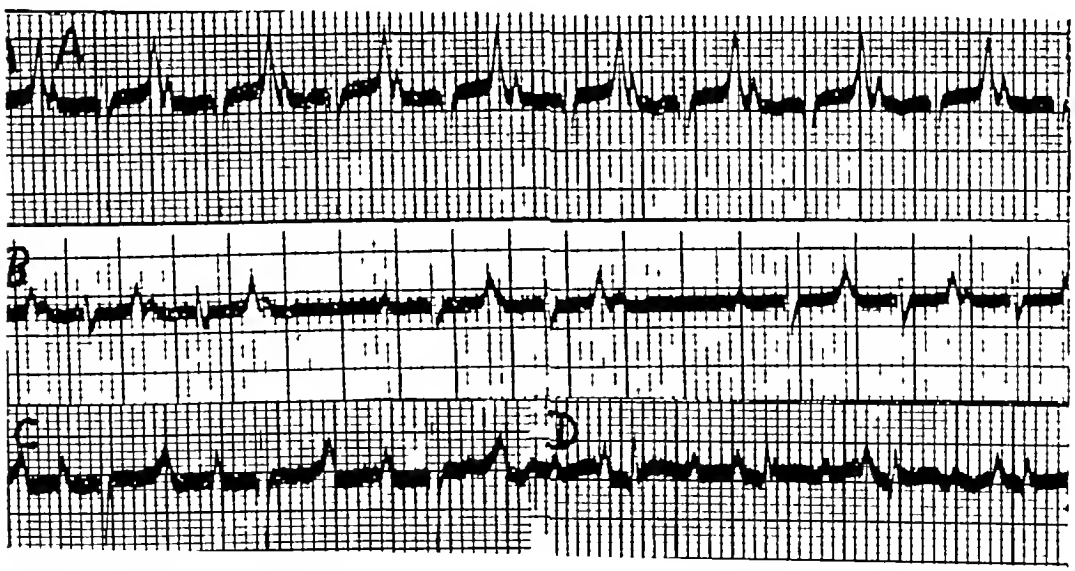

FIG 3 —Pig No 1 (A) Lead II 40th day of deficiency, showing first degree of A-V block P–R interval 0 18 sec (B) Lead I, recorded 4 hours later showing second degree A-V block (C) Lead II 41st day of deficiency, 24 hours after injection of 2 5 mg thiamin P–R interval 0 16 sec (D) Lead II 45th day of deficiency P–R interval has returned to within normal limits

pig were established at the beginning of the experiment The average heart rate was 143, and the lowest rate recorded was 130 The rhythm in the normal pig was invariably regular, and in no instance was sinus arrhythmia recorded The P–R interval varied from 0 06 to 0 10 sec usually 0 08 to 0 10 The QRS varied from 0 04 to 0 08 sec T I was frequently inverted and T II and III were usually upright Inversion of T in CF 4 was not seen in the normal pig (Fig 1)

Results

Control pigs maintained on this regime with adequate daily thiamin allowance remained healthy

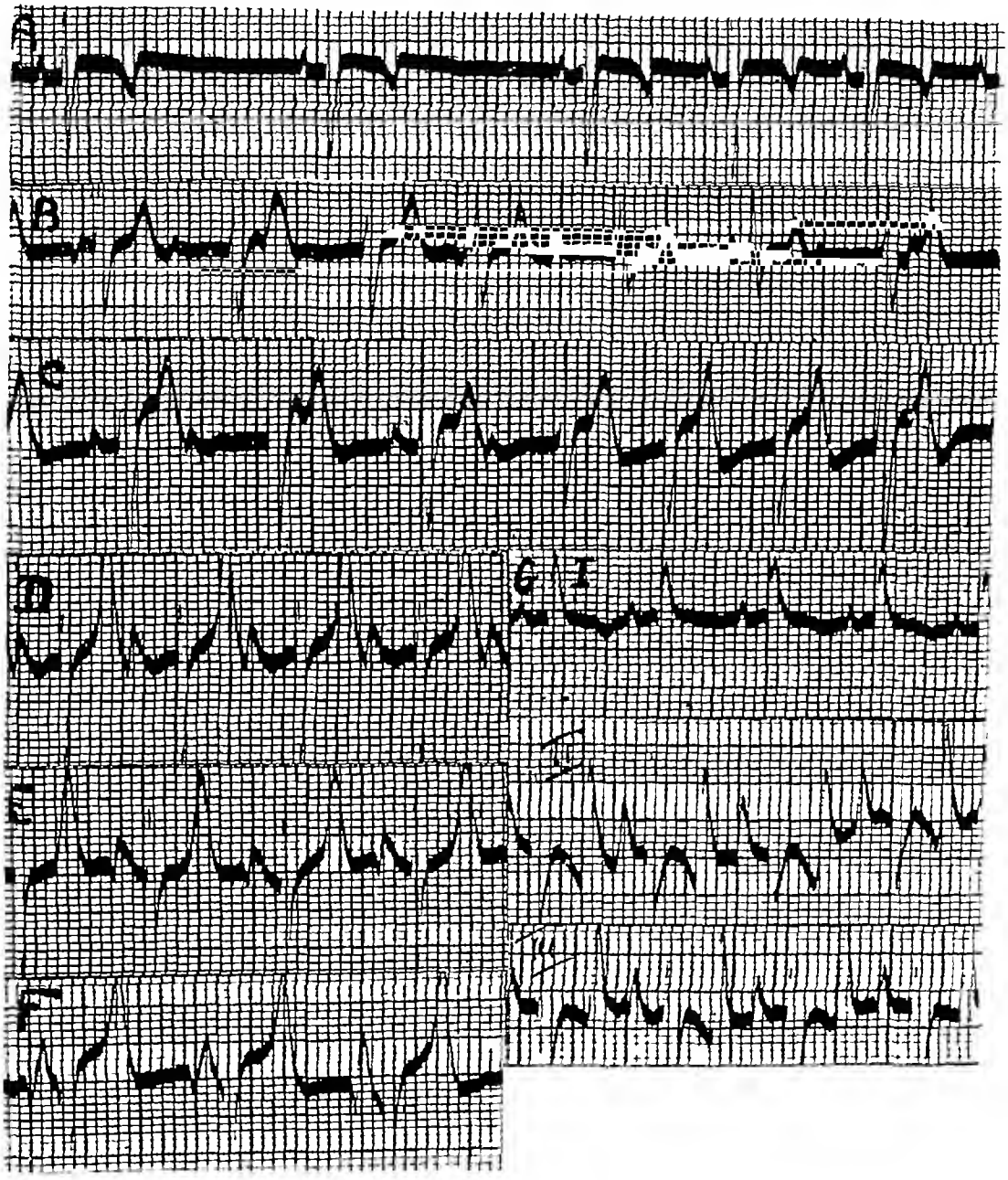

Fig 4 —Pig No 2 (A) Lead IV 49th day of deficiency showing sinus arrest and inversion of T IV (B) and (C) Leads I and IV 77th day of deficiency showing complete heart block and elevation of S–T segment in lead IV (D) Lead II 77th day, one hour after injection of 2 5 mg of B_1 *First degree block, P–R interval 0 18 sec (E) Lead II 78th day, 24 hours after* thiamin, P–R interval 0 16 sec (F) 80th day P–R interval within normal limits (G) Standard leads 99th day, *left bundle branch block, the QRS interval exceeds 0 08 sec*

Frequent electrocardiograms showed no deviation from the normal These control pigs were slaughtered on the 84th experimental day and their hearts subjected to detailed histological examination Numerous sections from all four chambers of the heart, and multiple sections from the interauricular and interventricular septa failed to show any histological abnormality

The four pigs deprived of thiamin developed anorexia and occasional vomiting between the 30th and 40th days, and thereafter at intervals Three of the animals died from thiamin deficiency One was sacrificed after 157 days All four developed disturbances of A-V conduction (Fig 3, 4, 5, and 6) The animals were acutely ill at the time of appearance of A-V block One animal (No 3) died with complete block

Death of the others showing block was prevented by a single intramuscular injection of 2 5 mg of thiamin hydrochloride The time of appearance of the conduction disturbance, the degree of block, the response of the block to thiamin, and the duration of survival on the thiamin deficient regime are indicated in the table From this it is seen that the administration of thiamin to three of the animals during the episode of block resulted in return of normal A-V induction within 48 hours Following thiamin treatment the animals were maintained on the deficient diet

With the exception of pig No 1 in which heart block occurred on the 40th day, the animals showed cardiographic changes prior to the development of block These consisted of marked bradycardia—rates as low as 65 were recorded—sinus arrhythmia, sinus arrest, and inversion of CF 4 (Fig 4, 5, and 6) These changes appeared between the 40th and 60th days Sinus block was not affected by atropine

Normal cardiograms were recorded for some time following the treatment of A-V block with thiamin Pig No 2 developed left bundle branch block 22 days after thiamin treatment of complete block The other two animals failed to develop a second episode of block but before death showed marked elevation of the S–T segments and huge T waves on all four leads (Fig 2)

Post-mortem examination of these animals showed no evidence of subcutaneous œdema Excess of fluid was found in the pericardial sacs In one animal (No 4) this amounted to 170 ml (6 oz) No excess of fluid was apparent in the other body cavities The hearts showed dilatation of the right auricle and of the right ventricle, particularly in the region of the pulmonary conus Apart from the heart of animal No 2 which showed numerous subendocardial hæmorrhages, considered incidental to the shock of killing, there was no macroscopic abnormality in the muscle, valves or endocardium The hearts formed 0 51 to 0 59 per cent of the body weight as opposed to the normal 0 3 to 0 4 per cent

Sections for histological examination were obtained from the anterior and posterior walls of each auricle, from the auricular appendages, the interauricular septa and from the anterior, lateral, and posterior walls of each ventricle The interventricular septa were blocked in series and multiple sections from each examined

Lesions were found in the auricles, the auricular

TABLE

DEVELOPMENT OF HEART BLOCK WITH THIAMIN DEFICIENCY

Animal	Day of deficiency at the appearance of block	Degree of block	P–R interval (*a*) 1 hr (*b*) 24 hrs (*c*) 48 hrs after injection of thiamin	Day of death
No 1	40th (1) Morning (2) Afternoon	Latent P–R, 0 2 sec 2nd degree	(*b*) 0 16 sec (*c*) 0 1 sec	74th
No 2	77th 99th	Complete Left bundle branch	(*a*) 0 18 sec (*b*) 0 16 sec (*c*) 0 1 sec	Sacrificed 157th
No 3	63rd 64th	2nd degree Complete		64th
No 4	58th to 63rd	Latent P–R, 0 14–0 15 sec	(*b*) 0 08 sec	116th

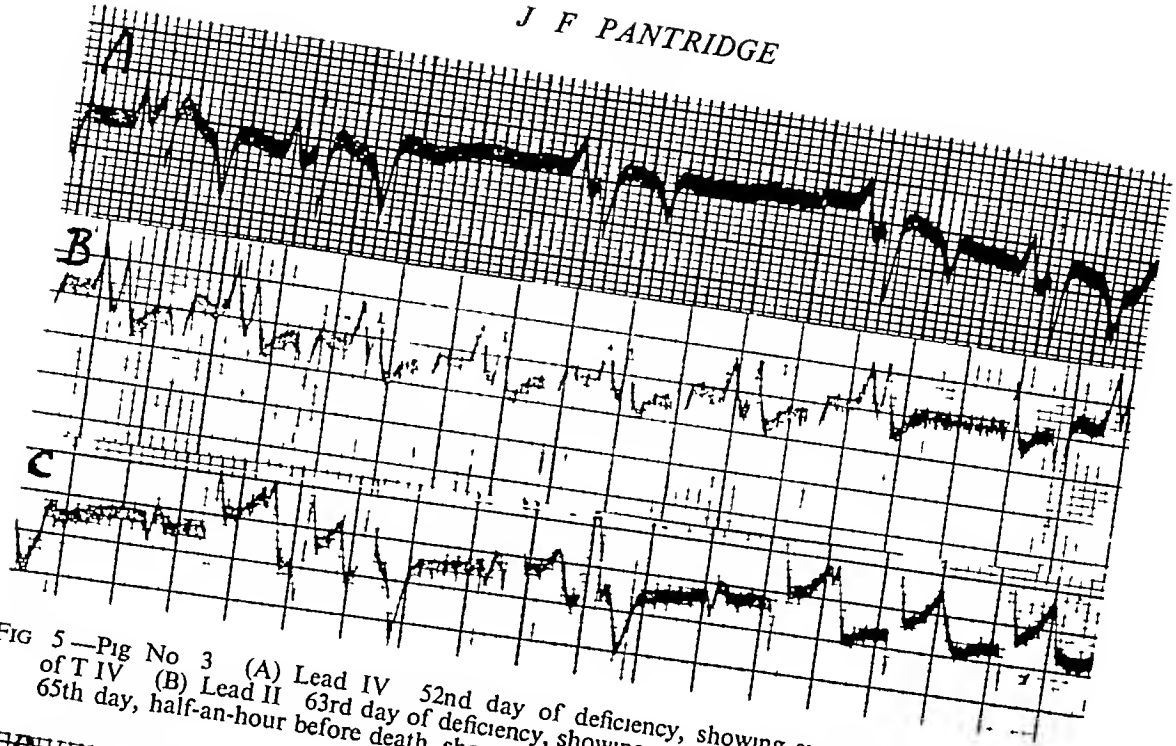

FIG 5—Pig No 3 (A) Lead IV 52nd day of deficiency, showing sinus block and inversion of T IV (B) Lead II 63rd day of deficiency, showing second degree A-V block (C) Lead I 65th day, half-an-hour before death, showing complete heart block

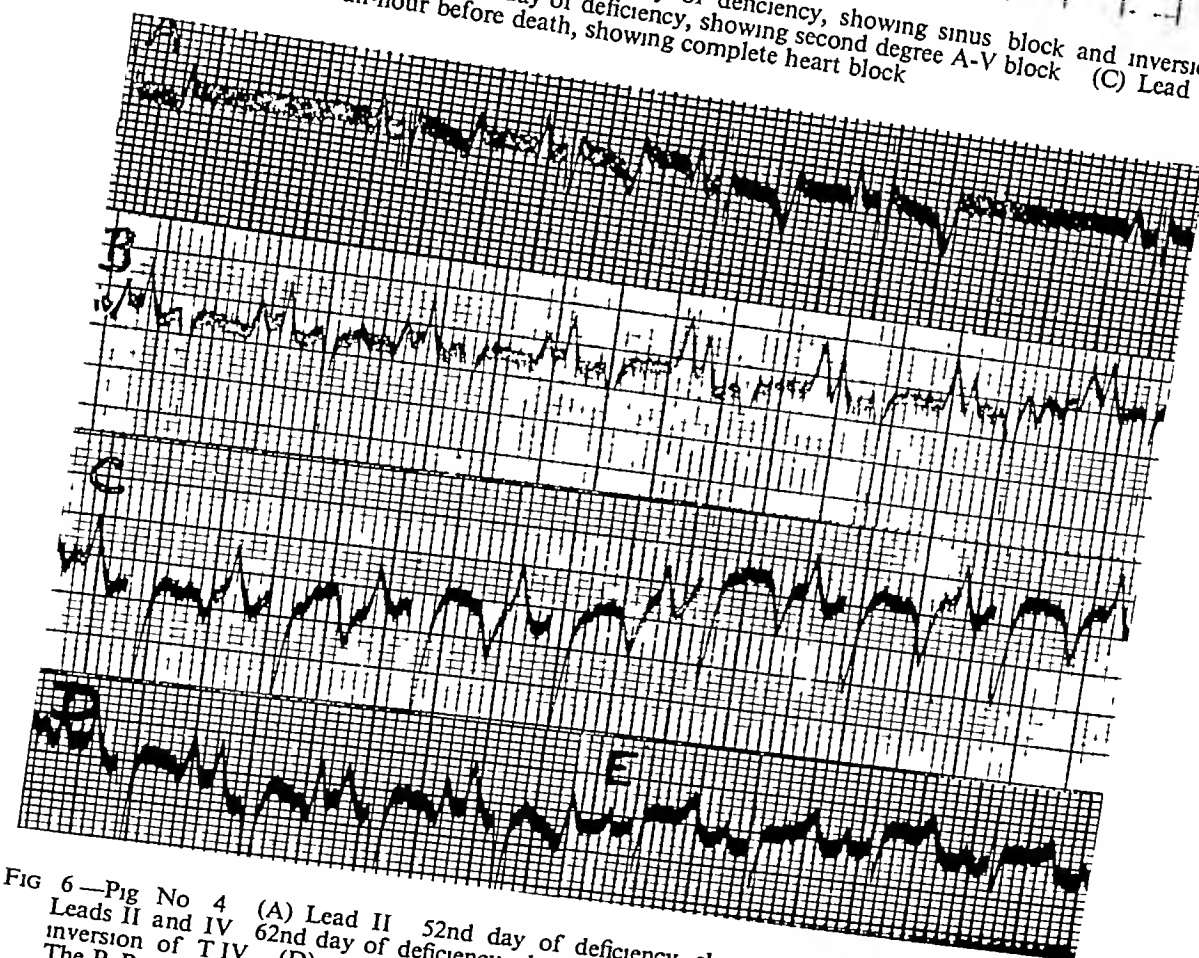

FIG 6—Pig No 4 (A) Lead II 52nd day of deficiency, showing sinus arrest (B) and (C) Leads II and IV 62nd day of deficiency, showing first degree A-V block (P–R 0 16 sec) and inversion of T IV (D) and (E) leads II and IV, following the administration of thiamin The P–R interval is within normal limits T IV is upright

appendages and the auricular septa in all four animals These consisted of areas where muscle fibres had disappeared leaving an œdematous reticulum the interstices of which frequently contained an eosinophilic and protein-like fluid A mononuclear cellular infiltration was seen in the areas of muscle damage and in the interstitial tissue in relation to them Changes of a more acute character appeared in the left auricle and auricular septum of animal No 4 Here were seen areas of active muscle necrosis associated with a leucocytic exudate and gross extravasation of red cells (Fig 7)

Healing and healed lesions in the auricles of three of the animals were minimal However in pig No 2 which survived 157 days, areas of replacement of muscle by granulation tissue or fibrous tissue were numerous Some sections from the left auricle of this animal showed replacement of the majority of the muscle fibres by fibrous tissue (Fig 8)

The microscopic auricular lesions old and recent, were in all the animals most marked in the left auricle and auricular septum In sections taken from the ventricular septum and ventricular walls it was possible to demonstrate the bundles of His, its main branches, and the terminal subendocardial and intra-myocardial ramifications of the conducting system

The conducting system in the pig differs markedly from that in man Glomset and Glomset (1940) have shown that in man Purkinje cells do not exist in the main bundle nor in the upper part of the right branch The cells that are described as Purkinje elements in the left branch and lower part of the right branch differ markedly from those found in ungulates They do not form a network, are found only subendocardially, and have never been recognized within the myocardium Cells closely resembling those described by Purkinje in the heart of the sheep are seen in the bundle of His, and its main branches in the pig Similar cells are seen forming a subendocardial network in the ventricles and penetrating deeply into the ventricular myocardium These cells are round, oval, or band-like in shape with distinct cell outline and measuring from 24μ to 66μ in diameter The cytoplasm is eosinophilic staining irregularly and shows a perinuclear clear zone The myofibrils of the cells are irregular in their arrangement The cells occasionally show a double nucleus, more commonly they have a single elongated nucleus which varies in its position in the cell In elongated cells the long axis of the nucleus tends to be arranged at right angles to the long axis of the cell

The ventricular lesions in these animals were confined almost entirely to the Purkinje system In animal No 3 which had at the time of death complete heart block, marked recent degenerative changes were found in many of the cells of the conducting system These degenerate cells had shrunken from their surrounding supporting reticulum, their

FIG 7 —Pig No 4 Interauricular septum There is an acute hæmorrhagic necrosis of muscle fibres Magnification × 210

FIG 8 —Pig No 2 Section from the right auricle showing the healed auricular lesions There is marked fibrous replacement of muscle Magnification × 90



FIG 9—Pig No 3 Subendocardial Purkinje cells (A) Normal cells The myofibrils are distinct (B) Necrotic cell The cell stains deeply The myofibrils are no longer apparent Magnification × 375

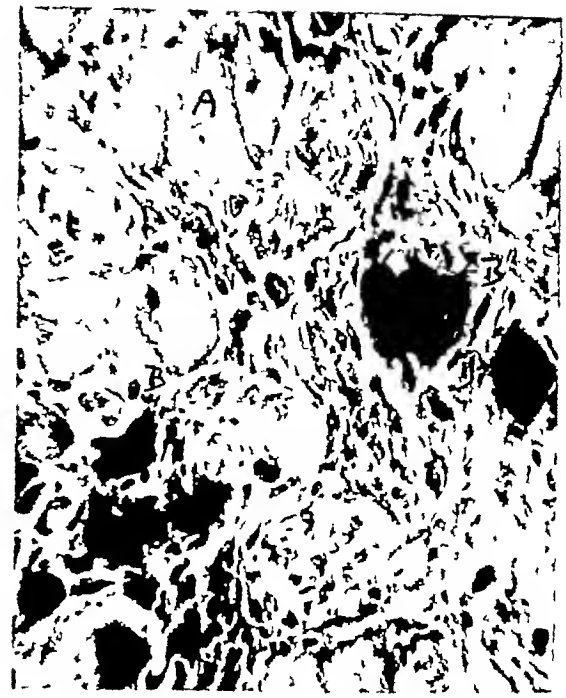

FIG 10—Pig No 3 Bundle of His from the animal dying with complete heart block There is an acute hyaline necrosis of many of the Purkinje cells (A) Normal cells (B) Necrotic cells Magnification × 375

cytoplasm had become deeply eosinophilic and of a structureless hyaline appearance The myofibrils were no longer distinguished (Fig 9) The nuclei showed pyknotic change

More than half the cells in the main bundle (Fig 10) and many of the cells in the main bundle branches were involved in this acute hyaline necrosis (Fig 11) One-third to one-half of the subendocardial and intra-myocardial Purkinje cells were affected A mononuclear cellular reaction was found surrounding many of these degenerate subendocardial and intra-myocardial cells Cellular reaction was much less evident in relation to the damaged cells in the bundle of His and its main branches

Sections from the main bundles of pigs No 1 and 4—these animals had survived episodes of heart block—showed in comparison with sections from the bundles of normal animals a complete disappearance of a considerable number of Purkinje cells and their replacement by connective tissue proliferation (Fig 12, 13, and 14) Many of the remaining Purkinje cells showed an acute hyaline necrosis These changes, disappearance of Purkinje cells and hyaline necrosis in a proportion of the remaining cells were also evident in the bundle branches (Fig 15) where in addition a mononuclear cellular reaction surrounded some of the damaged cells The terminal subendocardial and intramyocardial ramifications of the Purkinje system throughout the ventricles of these two animals were grossly involved in both old and recent lesions More than half the Purkinje cells showed recent necrosis with an associated marked mononuclear cellular reaction In some sections complete interruption of a Purkinje strand by a cellular exudate was seen (Fig 16)

Acute hyaline necrosis of the Purkinje cells was not found in the animal sacrificed after 157 days Extensive healed lesions consisting of fibrous replacement of Purkinje cells were however found throughout the conducting system, and were particularly marked in the bundle branches

DISCUSSION

Records of the cardiovascular changes in experimental thiamin deficiency in animals are numerous In thiamin deficient rats, Weiss *et al* (1938) found marked bradycardia and changes in the T waves and S–T segments, these changes usually disappeared within a few hours of giving thiamin, but were unaffected by atropine Carter and Drury (1929) noted bradycardia and heart block in thiamin deficient pigeons Swank and Bessey (1942) however, minimize the significance of bradycardia and heart block in pigeons since they found starvation

FIG 11 —Pig No 3 Left bundle branch showing acute hyaline necrosis of approximately one-third of the Purkinje cells with associated cellular reaction Magnification × 75

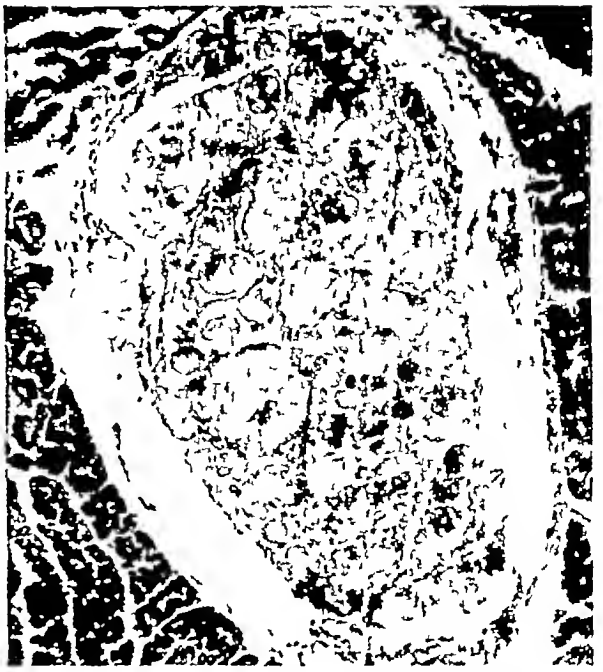

FIG 12 —Bundle of His in a normal pig Magnification × 60

FIG 13 —Pig No 1 Bundle of His from an animal surviving 34 days after the occurrence of heart block, showing loss of Purkinje cells and their replacement by connective tissue A number of the remaining cells show a hyaline necrosis Magnification × 60

FIG 14 —Pig No 4 Bundle of His from an animal surviving 53 days after the occurrence of block The changes are more marked than those in Fig 13 Magnification × 40

FIG 15—Pig No 1 Terminal part of the left bundle branch showing loss of Purkinje cells and fibrosis surrounding surviving cells Many of the remaining Purkinje cells show a hyaline necrosis Magnification × 100



FIG 16—Pig No 4 Subendocardial Purkinje strand anterior wall of left ventricle (A) Normal cells (B) Purkinje cells showing early hyaline necrosis associated with cellular infiltration This cellular infiltration is seen to produce complete interruption of the Purkinje strand Magnification × 165

alone would produce these effects histological examination of the hearts of pigeons dead from chronic thiamin deficiency showed necrosis of the myocardial fibres associated with an inflammatory cell infiltration De Soldati (1939) in thiamin deficient dogs noted high P waves and changes in the T waves and S–T segment

In thiamin deficient pigs Wintrobe *et al* (1943) recorded bradycardia, marked sinus arrhythmia, disturbances of A-V conduction and changes in the T waves Bradycardia was considered to be a more pronounced degree than could be accounted for by inanition Eight of the nine pigs showed prolongation of the P–R interval, two developed second degree block, and one complete heart block The most constant T wave change was inversion of T IV Atropine caused disappearance of a second degree heart block in one pig and in another shortening of the P–R interval and return to normal of the inverted T IV In both pigs atropine caused an increase in the heart rate The lesions found at autopsy in these animals included cardiac hypertrophy and dilatation, cellular infiltration, and scarring, as well as fresh necroses in the auricles and ventricles

King and Sebrell (1946) in experimental thiamin deficiency in rats noted marked bradycardia, progressive widening of the P–R interval and QRS complex and an increase in amplitude of QRS complex and of the T waves in leads II and III Auricular fibrillation and A-V nodal rhythm were noted in some animals during episodes of acute deficiency Fourteen of twenty-four experimental rats showed cardiac lesions at autopsy, in ten of these the lesions were predominantly auricular

Ashburn and Lowry (1944) in a detailed pathological study of thiamin deficient in rats found a moderate to marked dilatation of the right auricle, in some hearts the left auricle was dilated, but to a much less degree, and an occasional heart showed dilatation of the right ventricle Histological lesions in the auricles were found in 46 of the 58, but ventricular lesions in only 7 of the deficient animals The initial change consisted of a hyaline necrosis of the muscle cell associated with a cellular reaction consisting of neutrophils, lymphocytes, and mononuclear cells There was ultimately disappearance of muscle fibres Some of the acute lesions were followed by fibroblastic proliferation The inactive lesions showed absence of muscle fibres and marked thinning of the auricular wall with some fibrosis In a few instances there was a gross fibrosis of the

auricular wall Van Etten *et al* (1940) in thiamin deficient pigs described myocardial lesions consisting of scattered areas of atrophy and necrosis of muscle suggestive of infarction The lesions were particularly marked in the wall of the left ventricle

Porto and de Soldati (1940) found dilatation of the right auricle in four dogs maintained on a thiamin deficient diet Two also showed dilatation of the right ventricle Histological examination showed dissociation of the muscle fibres by interstitial œdema, lack of clarity of the transverse striations, hydropic degeneration of the muscle cells, most marked in the conducting system and areas of hyalinization of muscle fibres associated with cellular infiltration The lesions were found disseminated throughout the heart, but were most marked in the right auricle and right ventricle Follis *et al* (1943) studied the lesions in thiamin deficient pigs The hearts of six of nine animals were dilated and showed lesions consisting of focal or diffuse necrosis of the myocardial fibres associated with leucocytic infiltration In an animal dying, early lesions were found in the auricles, but none in the ventricles Animals that survived longer periods of deficiency showed lesions on both auricles and ventricles Scars marking healed necrotic lesions were found in the hearts of two animals

Swank *et al* (1941) in five dogs dead from thiamin deficiency found dilatation of the right auricle and right ventricle in one, the others showed marked dilatation of the left side of the heart Histological study showed some general shrinkage, and pale indistinct staining of the muscle fibres in all hearts In three hearts small scattered areas of myocardial necrosis were observed, many of which were infiltrated with polymorphonuclear leucocytes One heart showed older lesions consisting of small areas of loose connective tissue from which myocardial fibres were absent

From these accounts of animal experiments it is apparent that morphological lesions in the myocardium may result from thiamin deficiency There is, however, no complete agreement as to their character of distribution In the experiment recorded the finding of dilatation of the right side of the heart agrees with the observations of Porta and de Soldati (1940) and of Ashburn and Lowry (1944) The increase in heart-body weight ratio above the normal 0 3 to 0 4 per cent found in this experiment has been noted by Follis *et al* (1943) These authors point out however that it cannot be concluded from this, that the hearts were hypertrophied since in the presence of impaired growth from causes other than thiamin deficiency there is an alteration in the heart-body weight ratio

The preponderant involvement of the auricular myocardium in this study agrees with the findings of Follis *et al* (1942) in pigs, and those of Ashburn and Lowry (1944) and of King and Sebrell (1946) in rats It is probable that the sinus block observed in three of the animals was related to morphological lesions in the auricular wall since it was unaffected by atropine In the one animal in which it never appeared lesions in the right auricle were minimal

This predilection of the myocardial lesions of thiamin deficiency for the auricles suggests that the metabolism of the auricular and ventricular myocardium differs in some respects A difference in their metabolism has been suggested by Davies and Francis (1946) on the basis of a difference in their intrinsic rhythmic rates These authors write " In the hearts of cold blooded vertebrates in which there is neither specialized muscular tissue (nodal and Purkinje) nor any histological difference in the ordinary cardiac muscle which later nevertheless exhibit different intrinsic rhythms when separated from each other, their different rhythmicities must be dependent on factors other than purely morphological characters " Davies and Francis (1946) have attempted to discover whether substances known to be concerned in the chemistry of contraction of voluntary muscle are unevenly distributed throughout the heart They have shown that glycogen, phosphocreatine and adenosine compounds have such a differential distribution

It is notable that a morphological lesion is not suggested as the causative factor in those instances in which disturbances of auriculo-ventricular conduction have been found Thus Swank and Bessey (1942) minimize the significance of heart block in pigeons since they found that it might result from inanition alone, and Wintrobe *et al* (1943) found that heart block in thiamin deficient pigs responded to atropine

The experiment recorded shows conclusively that heart block and morphological changes in the cells of the conducting system may result from thiamin deficiency It would appear that initially the block is due to a reversible biochemical disturbance, and that this disturbance is capable of progression to an irreversible morphological change if acute deficiency is of sufficient duration The presence of histological lesions in a proportion of the cells of the bundle of His in animals No 1 and 4 suggest that cardiograms taken immediately before the death of these animals would have shown heart block

The selective involvement of Purkinje tissue found in this experiment suggests that these cells have also a metabolism which differs from that of the ventricular myocardium Consistent with this view are the observations of Shaner (1930) and of Davies and Francis (1941*a*) Shaner's studies in the ontogenetic

development of this system in the calf suggests that Purkinje fibres and ordinary cardiac muscle are separately developed from their respective undifferentiated mesodermal primordia Davies and Francis (1941*a* and 1946), have failed to demonstrate any nodal or Purkinje tissue in a number of fish, amphibia and reptiles, and express the opinion that the S–A, A-V nodes, the A-V bundle and the terminal network of Purkinje fibres are neomorphic developments in animals and birds associated with the more rapid rate of heart in these homiothermal vertebrates

The infrequency of heart block in human beriberi in contrast to the readiness with which it may be produced in experimental thiamin deficiency in pigs may be explained by the difference between the structure of the conducting system in man and that in ungulates This difference has been stressed by Glomset and Glomset (1940)

The biochemical or morphological changes are most likely to be found in those cells of the conducting system in man that most closely resemble in structure the Purkinje cells in ungulates The cells most closely resembling the Purkinje cells in ungulates are found in man at the terminal ramification of the conducting system beneath the endocardium of the ventricles As the conducting system is traced back toward the A-V node the similarity diminishes It has been noted that Glomset and Glomset found no cells resembling the Purkinje cells of sheep or pigs in the bundle of His in man

In thiamin deficiency of moderate degree abnormalities of the ventricular complex of the cardiogram probably result from changes in a proportion of the cells of the terminal ramifications of the conducting system

It further follows that disturbances affecting conduction in the main branches of the bundle of His in beriberi would be of commoner occurrence than A-V block It is, therefore, of interest that in one of the few reports of cardiac conduction defects in beriberi, that of Dock (1940), three of five cases showed bundle branch block and one latent A-V block

Summary

The clinical impression of the not infrequent occurrence of auriculo-ventricular block in beriberi is recorded

An experiment with the object of studying the effects of thiamin deficiency on cardiac conduction is described Four pigs deprived of thiamin developed heart block, in two this was complete

The histological lesions resulting from thiamin deficiency predominantly involve the auricular myocardium and the cells of the conducting system in the ventricles In pigs dying from thiamin deficiency an acute hyaline necrosis is seen in the Purkinje cells

I am indebted to Professor J H Biggart, C B E, and Dr S B Boyd Campbell for the facilities that made this investigation possible I wish to thank Professor Biggart for much advice and help in preparing this paper, and Dr J E Morison for this valuable advice on the interpretation of the histological lesions I am indebted to Mr J Harland for technical assistance and to Mr D McA Mehaffey, A R P S, for the photography

References

Aalsmeer, W C, and Wenchebach, K F (1929) *Wein Arch inn Med*, **45**, 1
Ashburn, L L, and Lowry, J V (1944) *Arch Pathol*, **37**, 27
Blankenhorn, M A (1945) *Ann intern Med*, **23**, 398
Carter, C W, and Drury, A N (1929) *J Physiol*, **68**, 1
Casanova, J (1946) *Algerie Med*, **3**, 203
Davies, F, and Francis, E T B (1946) *Biol Rev*, **21**, 173
——, ——, (1941*a*) *Philos Trans B*, **231**, 99
Dock, W (1940) *Trans Ass Amer Phys*, **55**, 61
Dustin, C C, Weyler, H, and Roberts, C P (1939) *New Engl J Med*, **220**, 15
Van Etten, C, Ellis, N R, and Madsen, L L (1940) *J Nutrit*, **20**, 607
Follis, R H, Jr, Miller, M H, Wintrobe, M M, and Stein, H J (1942) *Amer J Path*, **19**, 341
Glomset, D J, and Glomset, A T A (1940) *Amer Heart J*, **20**, 677
Jolliffe, N, Goodhart, R, Gennis, J, and Cline, J K (1939) *Amer J med Sci*, **198**, 198
Keefer, C S (1930) *Arch intern Med*, **45**, 1
King, W D, and Sebrell, W H (1946) *Pub Health Rep Wash*, **61**, 410
Porto, J, and de Soldati, L (1940) *Rev Soc Argent Biol*, **15**, 303
Shaner, R F (1930) *Anat Rec*, **44**, 85
de Soldati (1939) *Rev Soc Argent Biol*, **15** 142
Swank, R L, Bessey, O A (1942) *Arch intern Med*, **70**, 763
——, Porter, R R, and Yeomans, A (1941) *Amer Heart J*, **22**, 154
Weiss, S, Haynes, F W, and Zoll, P M (1938) *Amer Heart J*, **15**, 206
——, and Wilkins, R W (1937) *Ann Intern Med*, **11**, 104
Wenckebach, K F (1934) *Das Beriberi-Herz Morphologie, Klinik, Pathogenese Pathologie und Klinik in Eingeldarst*, Band VI (Springer)
Wintrobe, M M, Stein, H J, Miller, M H, Follis, R H, Jr, Najjar, V, and Humphreys, S (1942) *Bull Johns Hopkins Hosp*, **71**, 141
——, Alcayaga, R, Humphreys, S, and Follis, R H, Jr (1943) *Ibid*, **73**, 169

CARDIAC PAIN WITH RECOVERY OF THE T WAVE

BY

TERENCE EAST AND SAMUEL ORAM

From the Cardiological Department, King's College Hospital

Received September 6, 1948

Surprisingly little attention has been paid to the possibility of a return to normal of cardiograms that have been thought to show the presence of cardiac infarction when the clinical picture was consistent with that accident having occurred It is, of course, well known that very transient cardiographic changes, to be measured in minutes or hours, may accompany an anginal seizure But the authors are concerned not with these cases, but only with those in which the changes persisted for days, weeks, or even months, but ultimately disappeared The return to normal was so complete that from the inspection of the cardiogram alone, including unipolar exploration, it was impossible to tell that anything abnormal had ever occurred Careful search of papers published in the past twenty years and more has failed to reveal any such similar investigation, although recently, as a result of experiments on dogs, the possibility has been hinted at by Bayley and Monte (1943) that perhaps in man similar temporary changes might be found, which were not due to an actual infarct

In every case the account of the pain left no doubt that it was of cardiac origin, and only such cases as showed inversion of the T wave, in leads I or IV or both, or pathological inversion of the T wave in lead III, were included in the series In all cases standard leads and either IVR or CR 4, and IVF or CF 4, or both, were taken, and in all the patients encountered or followed up during the past two years unipolar leads were taken from the right arm (VR), left arm (VL), left foot (VF) and across the chest (V 1–6) The unipolar limb leads were augmented, using the Goldberger technique Whenever the unipolar deflections obtained from the præcordium appeared inconveniently large in amplitude the fibre sensitivity was reduced by one-half, (N/2), or even to one-third (N/3) Although in our records the amplitude of the T wave is only one-half or one-third of the size of the usual deflection, the proportion of the height of this wave to that of the QRS complex remains, of course, unaltered Some patients were further explored in a manner suggested by the results obtained from the above leads For example, when the lateral wall of the left ventricle was involved, leads were taken from intercostal spaces higher than those usually employed, and in some of the cases suggesting posterior cardiac infarction a deep epigastric lead was taken In all, the 28 cases were cardiographed on 140 occasions

Selection of Cases and Frequency

We had constantly in mind such other causes as might lead to temporary inversion of T waves, and we took care to exclude these as far as possible For example we excluded any patient in whom one might have suspected that digitalis was responsible for the T wave changes All records were taken with the patient recumbent There was no question of any patient having drunk cold water just before his test None was receiving adrenalin , and, although one was diabetic, it was thought that insulin did not influence the T wave One patient was myxœdematous, but the changes in the T wave were not characteristic of that disease we are of opinion that it was not responsible for subsequent cardiographic changes We excluded one patient with severe anæmia and two who were receiving desoxy-cortico-sterone acetate, for we did not consider that the changes in their T waves should find a place in this series If there was any doubt concerning the presence of attacks of paroxysmal tachycardia, that case also was omitted All the cases were adults, so the negative T waves of childhood were excluded There was no question of trauma to the chest wall or elsewhere

In the twelve-year period 1936–47 inclusive, cardiograms were taken from 5593 patients, and of those 367 yielded curves considered diagnostic of cardiac infarction Of the 367 cases, 232 were of the anterior type, 131 were posterior, and 4 were considered to show evidence of both Of the 232

anterior variety, 26 (11 per cent) were found that reverted to normal, but of the 131 posterior, only 2 (1 5 per cent) could be found whose curves had done so None of the 4 cases showing combined anterior and posterior infarction resumed a normal appearance

It is seen that of the total number of 367 cases of cardiac infarction, 28 (8 per cent) eventually became normal, and that of these there was a striking preponderance of the anterior type Of these 28 cases, 22 have cardiograms that have remained free from any pathological change whatever during the time we have kept them under observation

Clinical Details

Of our 28 cases, 22 were men and 6 were women The ages when the patients were first seen ranged from 39 to 77, more than half of them being over the age of 50, and three were over 70 The average age was 54 years

Although the period during which the patients were observed was in one case only two months, we were fortunate to have seven of our patients under observation for more than eight years On the average they were followed up for just over four years A study was made, from a consideration of the history and the type of the pain experienced, to see whether any clinical feature might emerge that would suggest the temporary nature of the abnormality in the cardiogram, but none did The diagnosis of angina pectoris or cardiac infarction had been made in every case before the cardiogram was taken, and the curve was thought at that time to be confirmatory In ten cases the pain was experienced only whilst the patient was at rest, while in seven pain was only present on exertion In the remaining eleven patients pain was present both at rest and on effort The pain recurred subsequent to the initial attack in 23 of the 28 patients It was a peculiar feature that in five patients, in spite of recurrent and apparently typical cardiac pain, which in each of the five cases lasted more than an hour, the cardiogram remained normal We could find no correlation between the severity or duration of the pain and the degree of inversion of the T wave A persistently high blood pressure, the systolic being more than 160 or the diastolic greater than 95 or both, was present in 18 patients In 9 it was normal and in one we have no record Unfortunately we have insufficient information concerning serial white cell counts and sedimentation rates in this series to discuss their diagnostic value, but sometimes there was a slight degree of pyrexia, and the white cells and sedimentation rate were increased somewhat, although for the most part these were unchanged

Cardiograms

Six facts emerged from inspection of the curves of this series First, the anterior lesion was very much commoner than the posterior, much more so than with established infarction Only 2 of the 28 cases were of the posterior type Secondly, in every cardiogram showing an anterior lesion the Q wave was either absent altogether, or, if present, was very small In no case was the Q wave in the lead or leads showing inversion of the T wave significantly prolonged (0 04 sec or more), in lead I it did not exceed 1 0 mm in depth, and in lead IV 1 5 mm As a rule there was no Q wave (see Table) Thirdly, in the posterior type, unlike in the anterior, a Q wave may appear which is pathologically deep and wide in leads II, III, and VF, and yet ultimately this may revert to normal dimensions or disappear (Fig 5) Fourthly, significant displacement of the RS–T segment by the current of injury was only present in two cases (Fig 8) and was actually less than 2 mm As the records were taken in several of our cases at all stages of the event, even during the paroxysm of pain, the absence of this current was surprising and will be commented on later Fifthly, it was noted that once the cardiogram had reverted to normal the tendency was for it to remain so, and only in an unexpectedly small number did it deteriorate again Thus, of the 28 cases that reverted to normal, 22 were still without pathological change when we last saw them Of the other 6, one showed digitalis effect only, one showed the picture of left ventricular predominance, and in three of the remaining four that subsequently deteriorated, the abnormal feature was nothing more than an isoelectric T wave in lead I The cardiogram of the fourth patient, after reverting to normal several times, finally persisted as a curve of cardiac infarction (Fig 10) Finally, on several occasions when our records were taken, the patient was experiencing a severe attack of pain, but they did not necessarily show inversion of the T wave at that moment, although this abnormality subsequently appeared

Prognosis

This is beyond doubt much better than that usually given for cardiac infarction Of the 28 cases only 3 are dead and one of these (Case 1) died of septicæmia Autopsy was performed and the findings are given below No details are known of the mode of death of the other two, but one lived for 8 years following the appearance of his abnormal record and was 70 at the time of his death, the other died at the age of 79, his abnormal record having appeared when he was 75

The exact length of time taken for the abnormal curve to revert to normal is difficult to assess

accurately unless records are taken at very frequent intervals The times estimated for the curves to become normal are thus necessarily maximal The shortest time was two days and the longest was three years and eight months, the average being 33 weeks Of the 28 cases, 20 were active when last seen and, of these, 15 were quite free from pain Three had experienced very slight pain which was inframammary in type and not of cardiac origin Two patients had slight cardiac pain, with but little limitation of activity Three others were free from pain but restricted by dyspnœa Two were considerably hampered by pain as already stated, three had died

Morbid Anatomy

As mentioned above, the outlook in these patients would appear to be so good that opportunities for autopsy are few The only one of this series (Case 1) that came to necropsy died as a result of obscure septicæmia There was some excess of fat in the epicardium and the heart was enlarged and dilated, particularly on the right side The myocardium was soft and flabby Two doubtful pale areas of scarring, superficial and just visible to the naked eye, were present a little distance from the tip of the anterior wall of the left ventricle In spite of careful search, section of the heart failed to reveal any other abnormal areas The main coronary vessels were quite patent and quite free from atheroma The valves and pericardium were normal Early changes of right-sided heart failure were present in the lungs, liver, spleen, and kidneys

Microscopically, the small sub-epicardial area sectioned consisted of a fairly well localized patch of fibrosis Microscopic branches of the coronary vessels seen were healthy (Fig 1)

Illustrative Cases

Unfortunately, space does not permit us to include full clinical and cardiographic details of all 28 cases, so we have listed the more important features (see Table) and chosen to illustrate from our series only such examples as show features worthy of particular comment This has necessitated the omission of a number of illustrations showing widespread and well-marked abnormalities, but of similar form Ten cases are presented the first is one in which autopsy was performed, the second is a typical anterior lesion, the third is also anterior and shows how widespread abnormalities in the unipolar præcordial leads can revert to normal, the fourth is one of our two posterior lesions in which the cardiogram recovered, the fifth is an example of anterior type where only T 4 was inverted and not T 1, the sixth showed inversion of T 1 but not of T 4, the seventh is presented because it is one of the two in which any RS–T segment displacement occurred, the eighth case, although presenting a seemingly established picture, showed that by inhalation of amyl nitrite it was possible to elevate an inverted T 1 and T 2, although these two waves became again inverted after five hours, the ninth case shows spontaneous inversion of T 1 and T 4, often but not always associated with attacks of cardiac pain, the tenth case is



A B

Fig 1 —Case 1 The larger of two very small pale areas just visible beneath the epicardium It consists of a well localized patch of replacement fibrosis The branches of the coronary vessels are quite healthy (A) Magnification × 35 (B) Magnification × 105

Case No Sex Age*	Period under observation	PAIN: No of attacks E = on effort R = at rest	PAIN: Severity Duration of longest attack	B P (Maximum)	CARDIOGRAM: Max depth of Q wave in mm	CARDIOGRAM: Max inversion of T wave in mm	CARDIOGRAM: Final appearance	CARDIOGRAM: Time taken for changes to disappear	Final state of the patient
1 M, 43	4 months	E R **	Moderate "Strangling" 20 min	160/100	Q 1 absent Q 4 absent	T 1 = −1 5 T 4 = −3 0	T 1 and T 4 isoelectric	3 months	Died of septicæmia Autopsy
2 M, 53	10 years	E R **	Severe "Violent" 10 min	150/130	Q 1 absent Q 4 absent	T 1 = −1 5 T 4 = −2 5	Normal	44 months	Active No pain
3 M, 47	1 year	E R 4	Extremely severe "Pulling together" 20 min	130/90	Q 1 absent Q 4 absent	T 1 = −1 5 T 4 —	Normal	1 month	Active No pain
4 M, 48	4 years	R 1	Very severe "Indigestion" 4 hours	128/80	Q 2 = 2 0 Q 3 = 3 0	T 2 = −3 0 T 3 = −5 0	Normal	2 months	Active No pain
5 M, 66	9½ years	E 3	Severe "Oppression" All day	195/100	Q 1 = 1 0 Q 4 absent	T 1 flat T 4 = −6 5	Normal	5 months	Active No pain
6 M, 43	3 years	R 2	Moderate "Sore trachea" Several hours	130/80	Q 1 = 0 5 Q 4 absent	T 1 = −2 0 T 4 = +1 0	Normal	3 months	Active No pain
7 F, 53	8 months	E R 4	Very severe "Suffocating constriction" Several hours	180/110	Q 1 = 0 5 Q 4 absent	T 1 = −1 0 T 4 = −2 5	Normal	2 months	Active Considerable pain
8 F, 54	6 months	E R **	Severe "Indigestion" 20 min	200/140	Q 1 absent Q 4 absent	T 1 = −2 0 T 4 = −4 5	L A D only	4 months	Restricted Considerable pain
9 M, 50	9½ years	E R **	Severe 2 hours 40 min	186/120	Q 1 = 0 5 Q 4 absent	T 1 = −1 5 T 4 = −5 0	Infarction	Few days	Restricted by dyspnœa No pain
10 M, 63	4 years	R 1	Very severe "Burning" Several hours	200/105	Q 1 absent Q 4 absent	T 1 = −1 0 T 4 = −2 5	Digitalis effect only	2 days	Restricted by dyspnœa No pain
11 M, 45	10 years	R 2	Extreme "Pressure or tightness" 1 hour	160/100	Q 1 absent Q 4 absent	T 1 = −3 0 T 4 = −6 0	Normal	5 months	Active No pain
12 F, 77	3 years	R **	Severe "Angina" 20 min	180/100	Q 1 absent Q 4 absent	T 1 = −1 5 T 4 = −2 0	Normal	38 months	Active No pain
13 F, 52	8 years	E R **	Severe "Painful tightness" Indefinite	150/100	Q 1 = 0 5 Q 4 absent	T 1 = −2 0 T 4 = −5 0	Normal	17 months	Active Occasional submammary stabbing pain only
14 M, 52	1 year	R 1	Severe — Unknown	*Unknown*	Q 1 absent Q 4 absent	T 1 = −1 0 T 4 = −2 0	Normal	3 months	Active No pain

Case No Sex Age*	Period under observation	PAIN: No of attacks E = on effort R = at rest	PAIN: Severity Duration of longest attack	B P (Maximum)	CARDIOGRAM: Max depth of Q wave in mm	CARDIOGRAM: Max inversion of T wave in mm	CARDIOGRAM: Final appearance	CARDIOGRAM: Time taken for changes to disappear	Final state of the patient
15 M, 62	8 years	E **	Severe "Tightness" 5 min	160/120	Q 1 absent Q 4=1 5	T 1= 0 T 4= −8 5	Normal	2 months	Died, aet 79
16 M, 59	3 months	E 1	Severe "Severe" Half hour	165/90	Q 1 absent Q 4 —	T 1 upright but TV 1–6 all inverted	Normal	29 days	Active No pain
17 F, 64	2 years	R 3	Severe "Gnawing" 4 hours	205/120	Q 1 absent Q 4 absent	T 1= −0 5 T 4= −2 0	Normal	17 days	Active Only inframammary pain
18 M, 55	6 months	R 2	Excruciating "Gripping compression" Half hour	135/90	Q 1 absent Q 4 —	T 1= −0 5 T 4 —	Normal	5 weeks	Active No pain
19 M, 39	1 year	E **	Moderate "Tightness" Few min	140/92	Q 1 absent Q 4=1 0	T 1= −1 0 T 4= −2 0	Normal	2 months	Active No pain
20 M, 42	4 years	E **	Moderate "Heaviness" ¼ hour	118/82	Q 1 absent Q 4 absent	T 1= −1 5 T 4= −12 (	T 1 isoelectric	5 months	Active Pain on exertion
21 M, 75	2 years	E R **	Moderate "Tight gripping" 1¼ hours	155/80	Q 1 absent Q 4 absent	S–T 1 seg = −1 S–T 4 seg = −2	Normal	1 month	Died, aet 79
22 M, 48	3½ years	E R **	Moderate "Aching" 20 min	160/110	Q 1 absent Q 4 —	T 1= −1 5 T 4 —	Normal	1 month	Active No pain
23 M, 42	4 years	E R **	Very severe "Crushing" 4 min	130/90	Q 1 absent Q 4 absent	T 1= +0 5 T 4= −2 5	Normal	5 months	Restricted Considerable pain
24 F, 55	6 years	E R **	Severe — 2 hours	210/120	Q 2 absent Q 3=2 0	T 2= −1 5 T 3= −4 5	Normal	17 months	Active Slight pain
25 M, 55	10½ years	E **	Moderate "Indigestion" Few min	140/100	Q 1 absent Q 4 absent	T 1= +0 5 T 4= −1 5	Normal	15 months	Active No pain
26 M, 39	2 months	E **	Severe "Tightness" 5 min	160/120	Q 1 absent Q 4=1 5	T 1=0 T 4= −8 5	Normal	2 months	Active No pain
27 M, 67	10 years	R 2	Severe — 20 min	180/95	Q 1 absent Q 4 absent	T 1= −2 5 T 4= −9 5	Normal	10 months	Active No pain
28 M, 75	1 year	R 1	Severe — 18 hours	164/95	Q 1 absent Q V4 absen	T 1= −2 0 T V4= −10 0	T 1= −0 5 T V4= +3 5	1 year	Restricted by dyspnœa No pain

* Age when patient first came under observation
** More than six distinct attacks of pain at rest, or persistence of exertional pain
All lesions were anterior excepting cases 4 and 24 which were posterior

included because it is the only example we have met where the T wave in lead CF 4 varied, alternately being upright and inverted from beat to beat

Case 1 (*Fig* 1 *and* 2) *Man, aged* 43 In July 1946 typical symptoms of failure of the left ventricle first appeared Dyspnœa on effort was soon followed by attacks of severe nocturnal dyspnœa A few weeks later he complained of a choking sensation, as though he were being strangled, accompanied by a dull pain in the left chest This pain was at first only brought on by exertion such as walking and always brought him to a standstill It lasted for fifteen to twenty minutes, never longer, and did not radiate

During his stay in hospital several of these attacks of pain occurred whilst he was asleep, and awakened him Auricular fibrillation was present intermittently, and, although on admission his blood pressure was 160/100, it fell during his stay to 130/90 and, just before death, to 80/48

Whilst in hospital he developed a fatal septicæmia, the origin of which was never discovered

On 29/10/46 his cardiogram confirmed that auricular fibrillation was present T 1 and T 2 were flat and T 4F was sharply inverted By 6/11/46, T 1 was inverted, and inversion of T 4 persisted No Q waves were present Further cardiograms taken on 15/11/46 and 2/12/46 showed some improvement, and by 28/1/47 normal rhythm was present, T 1 was flat and T 4 was almost so

Comment This case is presented in some detail as we were fortunate enough to obtain a necropsy owing to the patient's death from septicæmia Although the last cardiogram (28/1/47) before his death on 26/2/47 was not normal, it showed considerable improvement over the one taken on 6/11/46, which was suggestive of anterior cardiac infarction The inversion of T 1 and T 4 had practically disappeared within the last three months Naked eye and microscopical appearances have been described and illustrated above (Fig 1) Notwithstanding the cardiographic appearances, the degree of localized cardiac muscle destruction was minimal We feel here that, had the patient not succumbed to incidental disease, such a trivial lesion would hardly have impaired a very good chance of complete recovery, particularly in the absence of coronary atheroma

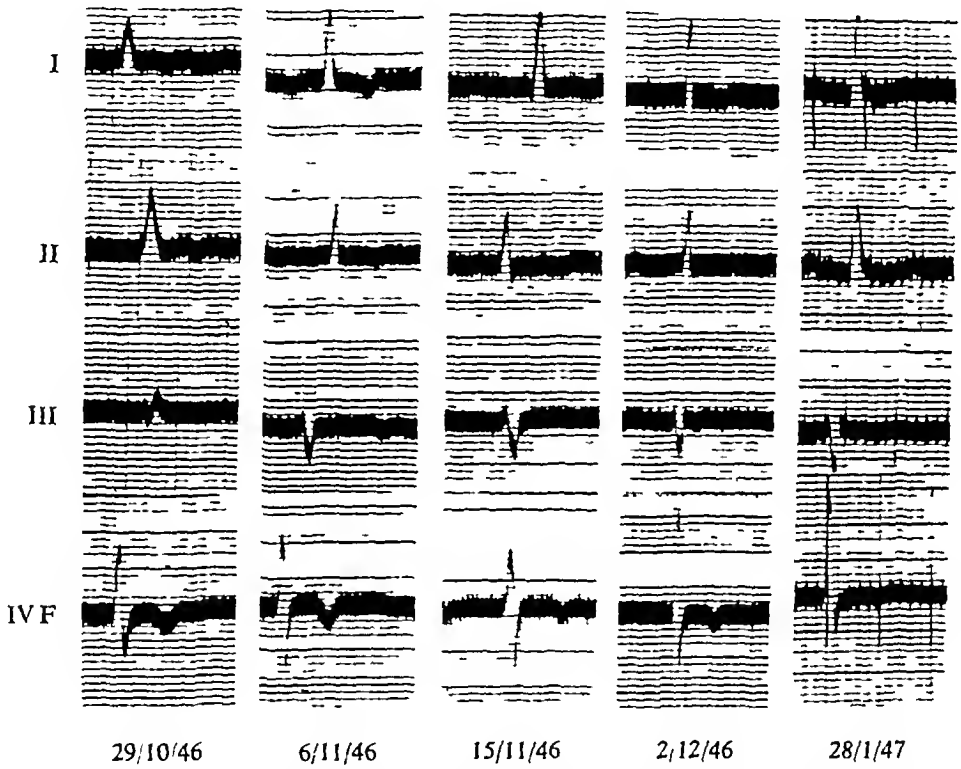

FIG 2 —Case 1 Cardiogram suggesting anterior cardiac infarction, and showing improvement prior to death from septicæmia Auricular fibrillation

Case 2 (*Fig* 3) *Man, aged* 53 The patient was quite well until 23/3/38 when he suddenly experi-

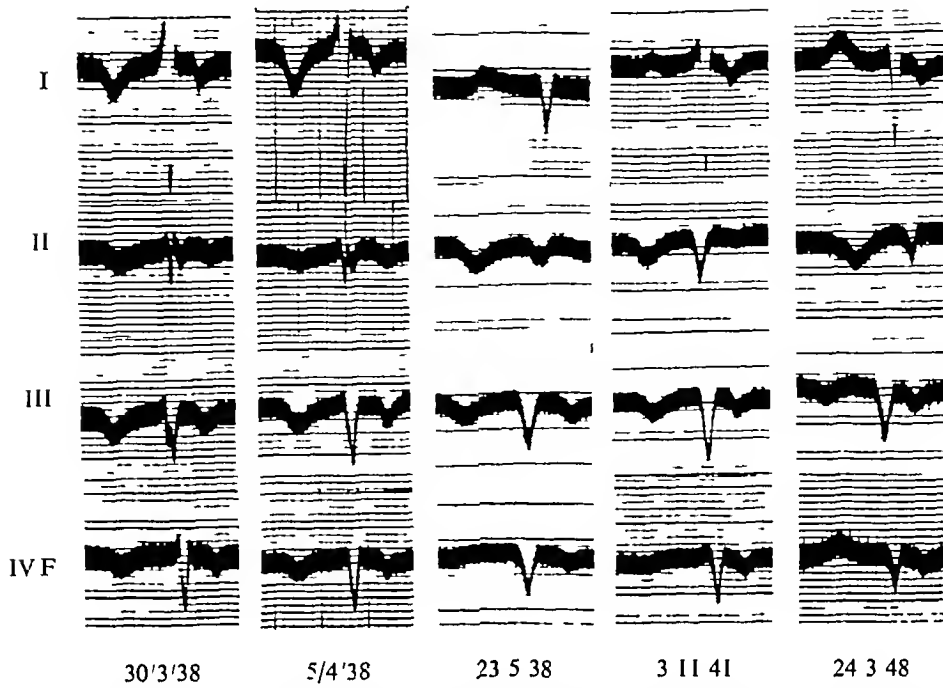

FIG 3 —Case 2 Recovery of abnormal cardiogram suggesting anterior infarction but with no Q waves

enced a violent substernal pain whilst he was at rest Subsequently this type of pain occurred on exertion, the attacks lasting five to ten minutes and being relieved by rest Whenever the pain was particularly severe it radiated down his left arm When seen six days after his first attack of pain, his blood pressure was 118/95, gallop rhythm was present, and he was found to have diabetes

His cardiogram on 30/3/38 was taken during an attack of pain and showed inversion of T 1 and T 4F and elevation of T 3 The R waves were of low voltage but no Q waves were present When repeated on 5/4/38 T 1 had become flat and T 4 had become 2 mm less inverted By 23/5/38 the gallop rhythm was still faintly audible His cardiogram was virtually the same

When seen on 13/6/38 he was still experiencing occasional pain, the gallop rhythm was gone, and he could walk a mile or so before becoming breathless His B P was 105/65 He was seen again on 3/11/41 and the cardiogram was taken just as an attack of pain had ceased To our surprise the record was quite normal and even the R wave amplitude had increased When seen on 29/5/46 he was experiencing rather vague neuritic " præcordial pains on walking, there were no abnormal physical signs, his diabetes was controlled by diet alone and his cardiogram was still normal

He was seen again on 24/3/48 and he had been keeping symptom-free, showed no abnormal physical signs, B P 140/90, and the cardiogram in the standard leads, unipolar limb and præcordial leads, was quite normal

Comment Typical cardiac pain was present coming on at first at rest and later on exertion also in a moderate diabetic His cardiogram was originally considered typical of anterior cardiac infarction becoming normal before the attacks of pain had ceased In fact, one taken immediately after a severe attack of pain was quite normal Ten years from the first attack, his cardiogram is still normal This case illustrates well how a normal cardiogram may be consistent with the presence of severe cardiac pain

Case 3 (*Fig* 4) *Man, aged* 48 At the beginning of April 1947 whilst the patient was at rest in a chair he had a sudden attack of pain and numbness which began in the left arm and radiated up to his left shoulder and across the upper part of the sternum, where it became of frightening intensity and was associated with considerable dyspnœa The chest pain was described as ' pulling together, as though the left arm were being torn out ' Much *angor animi* was present He sweated profusely during the attack and his wife commented on his extreme pallor The attack lasted twenty minutes and went off quite suddenly During the next two hours he had two

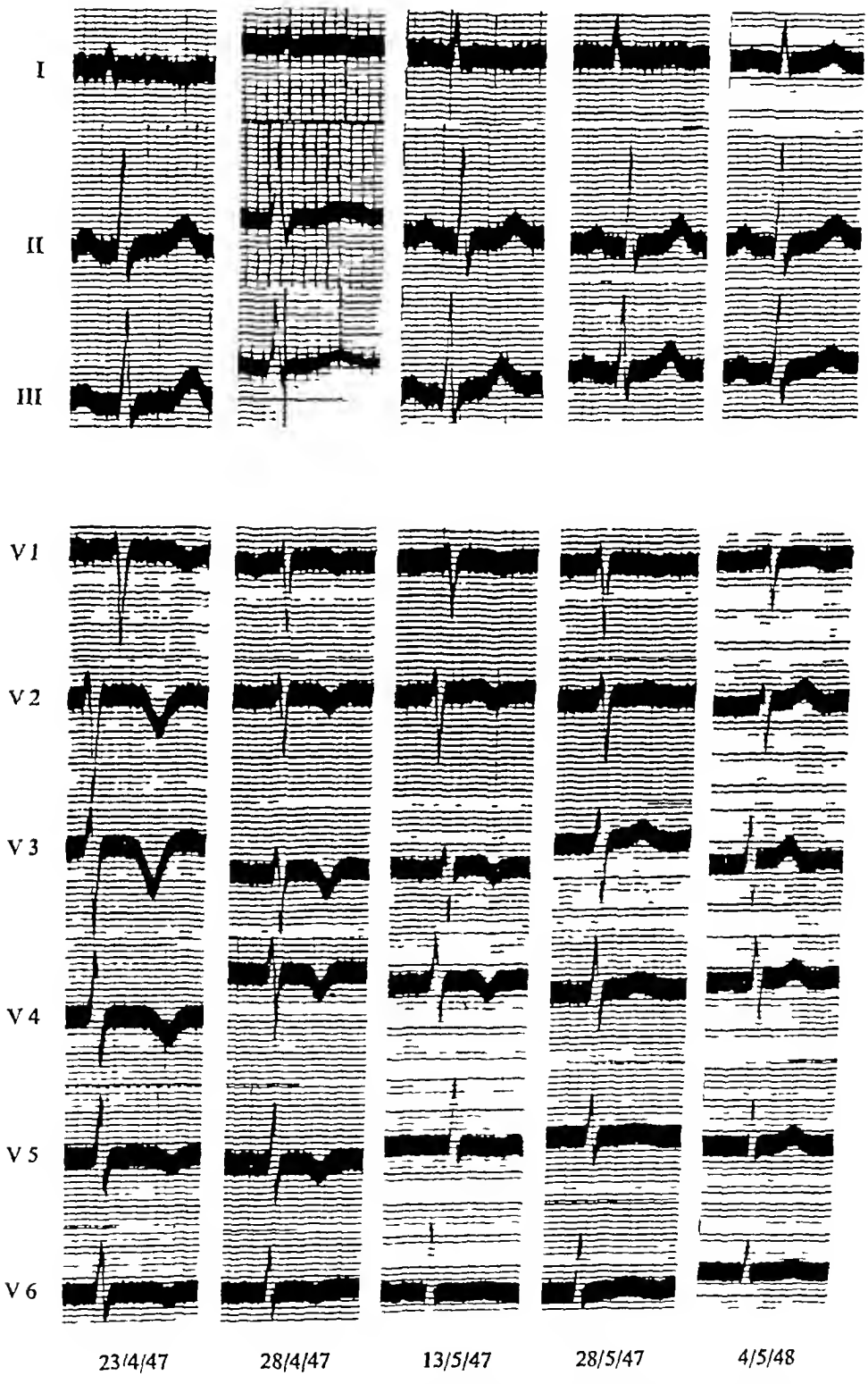

FIG 4 —Case 3 Cardiogram suggests widespread anterior lesion, but without the presence of Q waves The record became normal within five weeks, and a year later was still so V lead fibre-sensitivity = N/2

similar, but less severe, episodes whilst in bed A further attack came on whilst he was walking from work and the pain again started in the left arm, which felt heavy

Clinical examination on 23/4/47 revealed no abnormal physical signs, B P 130/90, but the cardiogram taken the same day showed, in addition to slight inversion of T 1 with a low voltage QRS, pathological T inversion of all the unipolar præcordial leads, especially V2, V3, and V4, although no Q waves were present The B S R taken the next day was 4 mm in the first hour (Westergren) and a white cell count taken on 25/4/47 was 12,000 per c mm It was considered that the patient had had a coronary artery occlusion, but that although the ischæmic area was of great extent, it was not transmural

He was treated with anti-coagulant therapy

No further pain occurred whilst he was in hospital and on the day of his discharge, 13/5/47, the cardiogram showed that his præcordial T waves had become less inverted, those of V5 and V6 being flat A fortnight later, on 28/5/47, T 1 was just upright and V2–6 inclusive had become upright He was last seen on 4/5/48 and he had been quite free from pain or disability of any sort for one year and his cardiogram, standard, unipolar limb and præcordial leads, was quite normal

Comment Cardiac pain of great severity was associated with cardiographic changes of extensive antero-lateral distribution without Q waves These changes, together with the pain, disappeared within five weeks, and a year later, both clinically and cardiographically, the patient was quite normal It is noteworthy that fever, leucocytosis, and increase in the sedimentation rate were inconspicuous

Case 4 (*Fig* 5) *Man, aged* 48 Whilst sitting at a desk at 10 30 p m on 14/7/44 the patient experienced sudden intense, continuous, retrosternal pain, which lasted four hours (" like very severe indigestion, although much worse ") He also felt it in both arms, from elbow to thumb, and it caused him to sweat His doctor found no abnormal physical signs, although he saw the patient a few hours later The patient felt absolutely fit within two days and he was sent to hospital where a cardiogram, taken on 20/7/44, only revealed a rather tall P wave in lead II, although there was slight inversion of T III However, in view of his story he was admitted to hospital, and further cardiograms were taken Although no further pain occurred, the second record taken on 31/7/44 showed the usual appearances of posterior cardiac infarction with deep inversion of T II and T III and prominent Q II and Q III The cardiogram improved and by 18/9/44 it was quite normal

When seen on 4/5/48, nearly four years after his attack, he had been keeping very well indeed and was leading an active life, without any pain or other disability whatsoever There were no abnormal physical signs, B P 120/75, and his cardiogram was still quite normal

Comment A single isolated attack of severe cardiac pain associated with a cardiographic appearance that, although at first was normal, showed a few days later the typical appearance of posterior infarction, including the presence of Q waves Even so, the cardiogram had recovered within two months

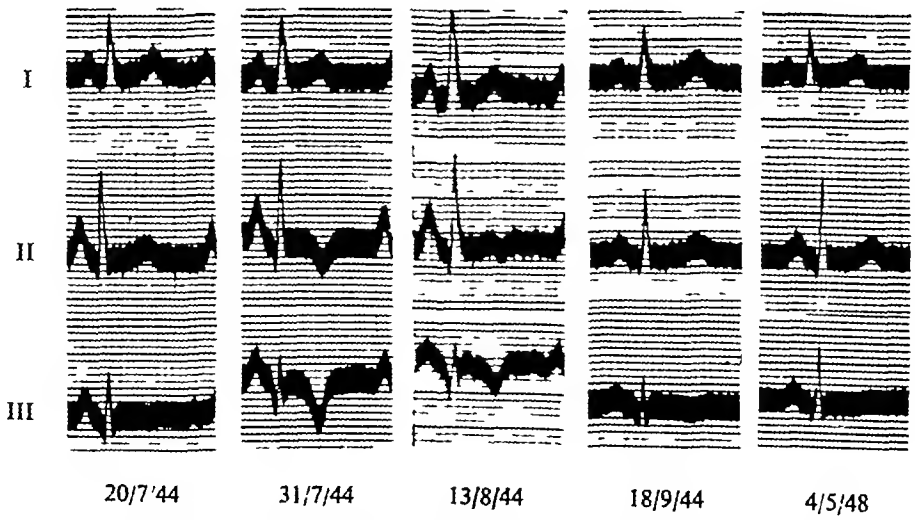

FIG 5 —Case 4 A type of posterior lesion The cardiogram recovered within two months, and both the patient and his record have remained normal for four years

The patient has remained quite fit and has had a normal record for four years This case also is an example of cardiac pain being accompanied for a few days by a normal cardiogram which only subsequently assumed the appearance typical of infarction

Case 5 (Fig 6) Man, aged 66 This active fisherman was first seen by us nearly ten years ago and complained of three distinct attacks of severe præcordial oppression which radiated down the left arm The first occurred on 8/8/38, while he was pushing his boat down to the beach The pain during the third attack lasted all day

He was first seen on 5/9/38 There were no abnormal physical signs apart from a very slight scoliosis and a trace of albumen in the urine, B P 130/78 The cardiogram on that date showed T 1 to be rather low but upright, but deep inversion of T 4F was present, although there were no Q waves A record taken on 24/10/38 showed normal standard leads, but T 4F was only just upright On 27/2/39 his cardiogram was quite normal with an upright T in 4F of good amplitude, and a Q wave had appeared The pressure had risen to 145/105

A cardiogram on 23/5/39 was identical in appearance with that of 27/2/39 The pressure had risen to 160/110

When last seen on 14/1/48 the blood pressure was 195/100 The cardiogram, standard leads, CR 4 CF 4, unipolar limb and præcordial leads, was quite normal and he was leading a normal symptom-free life , during the whole of the war his work had been particularly arduous

Comment This is an example of cardiac pain precipitated by severe exertion, accompanied by changes in lead 4F but without changes in lead 1 Within six months the curves had become normal and they have remained normal for nearly ten years and the patient has remained well Lenegre and Chevalier (1946) have recently recorded 32 patients with such T wave changes and concluded that provided the patient is more than twenty years of age isolated inversion of T 4 is pathological and most often of coronary origin

Case 6 (Fig 7A and B) Man, aged 43 When first seen on 3/5/45 his history was that ten days previously he had felt ill and feverish for a day but did not go to bed The next night he still felt unwell and woke at 11 p m with a nasty dull pain in the upper chest, which he described as being like a ' sore trachea He was restless during the pain, which lasted for several hours The pain recurred, though less severely, at odd times during the next few days

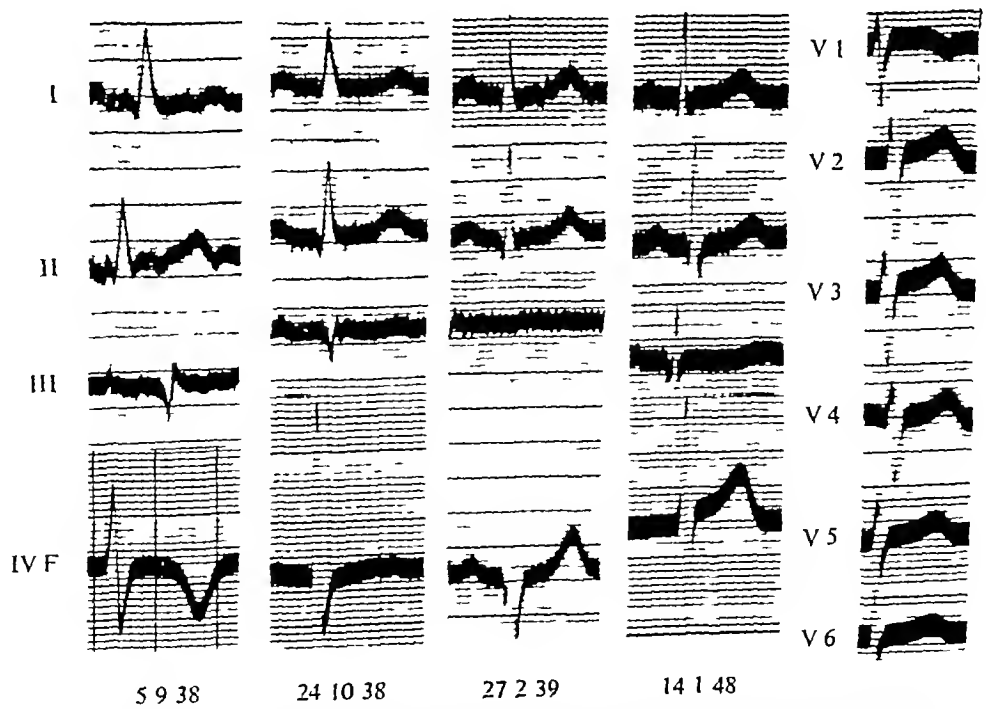

Fig 6 —Case 5 An example of inversion of T 4F but with T 1 remaining upright Cardiographic recovery occurred within six months and has persisted for nearly ten years V lead fibre sensitivity = N/2

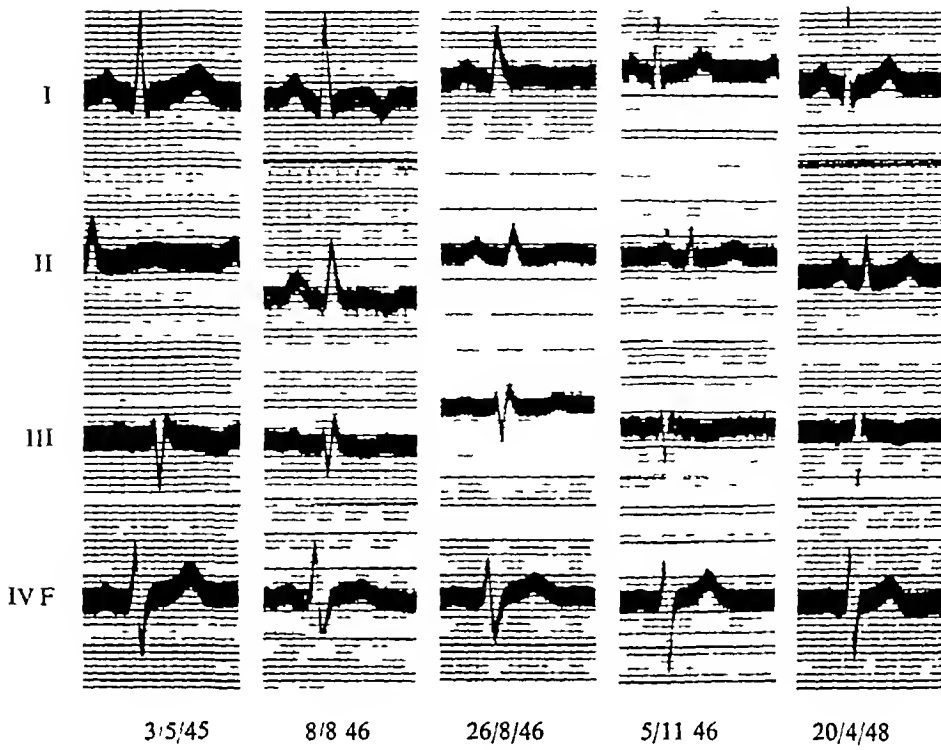

A

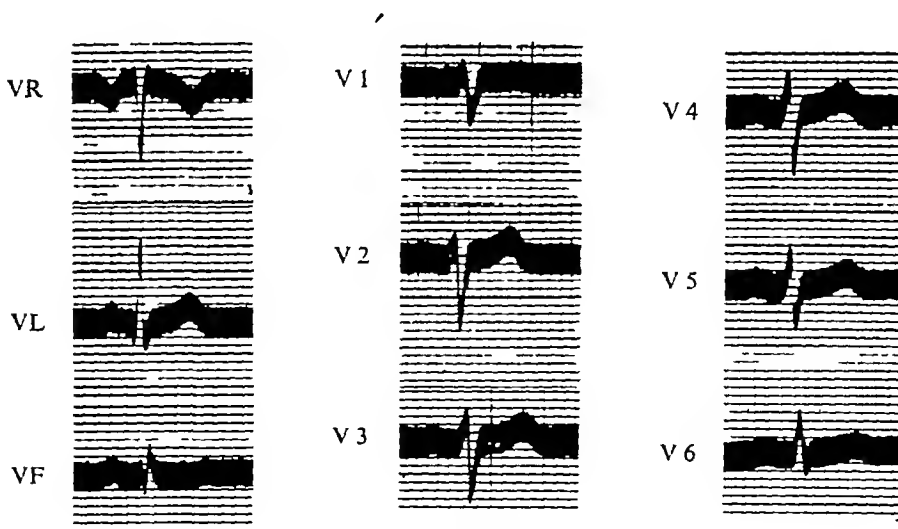

20 4 48

B

FIG 7 —Case 6 An example of inversion of T 1, and T 2, but with T 4F remaining upright The record reverted to normal within three months (A) Standard leads and lead 4F showing deterioration and recovery (B) Final unipolar leads (N/2)

and was then described as constricted breathing," more a discomfort than pain

There were no abnormal physical signs, B P 130/80, and cardioscopy was normal His cardiogram taken the same day showed only a little left axis deviation He remained well until 4/8/46 when a second similar attack occurred suddenly at 2 a m and lasted for several hours

A record taken on 8/8/46 revealed that now T 1 and T 2 were both inverted, and although T 4F was not of good amplitude it was still upright Within eighteen days T 1 had improved and become flat and T 2 was upright By 5/11/46 the curves were normal, and when the patient was last seen on 20/4/48 he was keeping quite free from pain and leading an active life His cardiogram was still quite normal in standard leads, 4F, unipolar limb, and præcordial leads

Comment An example of cardiac pain at rest, at first accompanied by a normal cardiogram and later by one in which T 1 and T 2 became inverted and yet T 4F remained upright Within three months of the first abnormal cardiogram, his record had become normal Here again, it would have been erroneous to assume that his normal cardiogram ruled out the possibility of his pain being cardiac in origin

Case 7 (*Fig* 8) *Woman, aged* 53 This woman had four quite severe attacks of cardiac pain, all coming on whilst she was at rest The first attack woke her during the night of 8/9/47 and there was such severe substernal pain and dyspnœa that she thought she was going to die The pain radiated down the left arm into the left middle finger When seen next day the only abnormal sign was her blood pressure of 180/110 The second attack occurred at 6 a m on 11/9/47, was similar to the first and accompanied by much sweating, a pulse rate of 156, and a temperature of 99 The next day, 12/9/47, her cardiogram was taken (standard leads, V1, V4, VF, and VL) and was normal White cell count on 13/9/47 was 5000 per c mm with a normal differential B S R on 16/9/47 was 12 mm in the first hour (Westergren)

On 25/9/47 a third attack occurred She had a little pain in her chest during the day and this suddenly increased and became intense and radiated down the left arm to the wrist She felt hot and frightened During the attack her blood pressure was 160/100 but next day had fallen to 120/98 A record taken on 26/9/47, the day following the third attack of pain, showed that the RS–T junction and segment in leads 1, 2, and V4 was raised and in leads 1 and 2 it incorporated the T waves In V4 the T wave was inverted The segment elevation was about 1 mm in leads 1 and 2 and was considered consistent with anterior infarction, notwithstanding the facts that her white cell count taken the day after the attack was normal, 8 4 thousand, and her B S R taken on 29/9/47 was 7 mm in the first hour (Westergren)

By 15/10/47 no further attacks had occurred and the RS–T segment had gone back to the isoelectric level and, as we expected, T 1 and T 2 had become inverted in addition to T in V4 T 3 had also

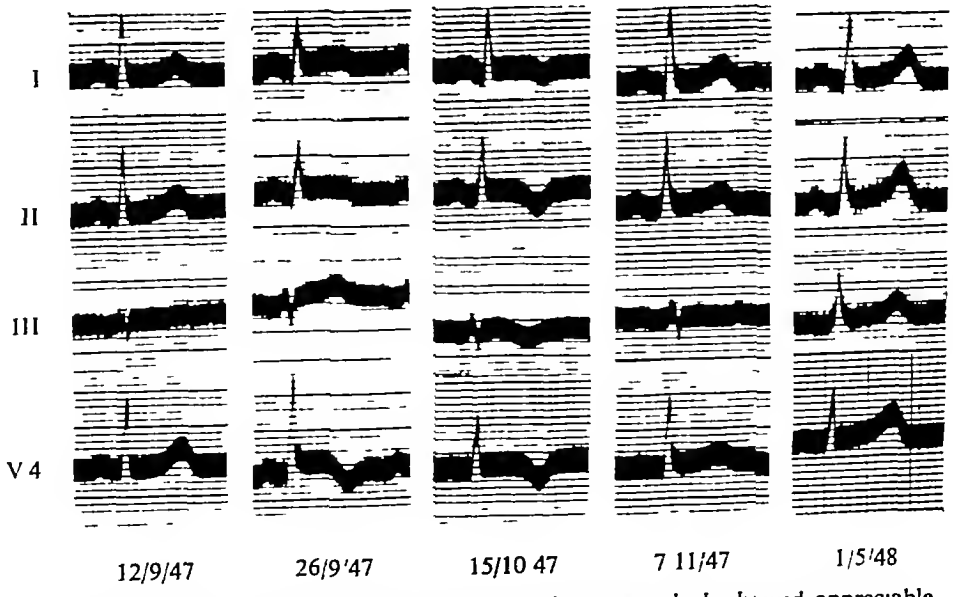

FIG 8 —Case 7 One of the two records in the series which showed appreciable RS–T segment displacement (26/9/47) It disappeared in less than three weeks

become inverted and this was thought to indicate an extension of the lesion By 21/10/47 the curves had become quite normal and were repeated on 7/11/47 when they were still normal A fourth attack of pain, felt as a constriction beneath the upper part of the sternum and radiating down the left arm to the elbow, occurred on 21/4/48, but a cardiogram taken on 1/5/48 which included standard leads, unipolar limb and præcordial leads, was still quite normal

Comment There are several reasons for presenting this case It is one of only two cases in which we have been able to detect segment displacement, although this was only slight Secondly, it again illustrates how it was not until three attacks of cardiac pain had occurred that any alteration in the cardiogram was detected In spite of apparent extension of the lesion the cardiogram became normal within three weeks, and in spite of the fourth attack of pain, it remained normal

Case 8 (*Fig* 9) *Woman, aged* 54 This patient had a six weeks history of " indigestion " when first seen, which during the latter five weeks had been felt as a " terrible dull boring pain " beneath the lower sternum, going up into both jaws and down to both elbows Without trinitrin the pain lasted twenty minutes It came on with exertion and caused her to stop walking, an exercise of which she was previously very fond, and it also awakened her

On examination on 5/12/47 her B P was 200/140 and a very clear presystolic gallop rhythm was visible, palpable and audible A cardiogram taken the same day showed negative T waves in leads I, V1, V3, V4, V5, V6, and CF 4 T 2 was flat No Q waves were present These changes were consistent with antero-lateral infarction and hypertensive heart disease Whilst she was in bed several more attacks of pain occurred and repeated B S R estimations and white cell counts were made during and between these attacks The highest B S R was 10 mm in one hour and the highest white cell count was 11 7 thousand per c mm with a normal differential count

Cautiously, the effect on the cardiogram of exercise, of chewing trinitrin tablets, injections of tetraethyl ammonium bromide, and finally of inhaling 5 minims of amyl nitrite was observed All except the last were without appreciable effect on her cardiogram The result of amyl nitrite on 30/12/47 was striking The previously inverted T 1 and T 2 became upright and T CF 4 was appreciably less inverted Five hours later the cardiogram had regained its former pathological appearance

By 2/4/48 all signs of infarction change had disappeared and only those due to left ventricular preponderance remained, the inverted T waves in

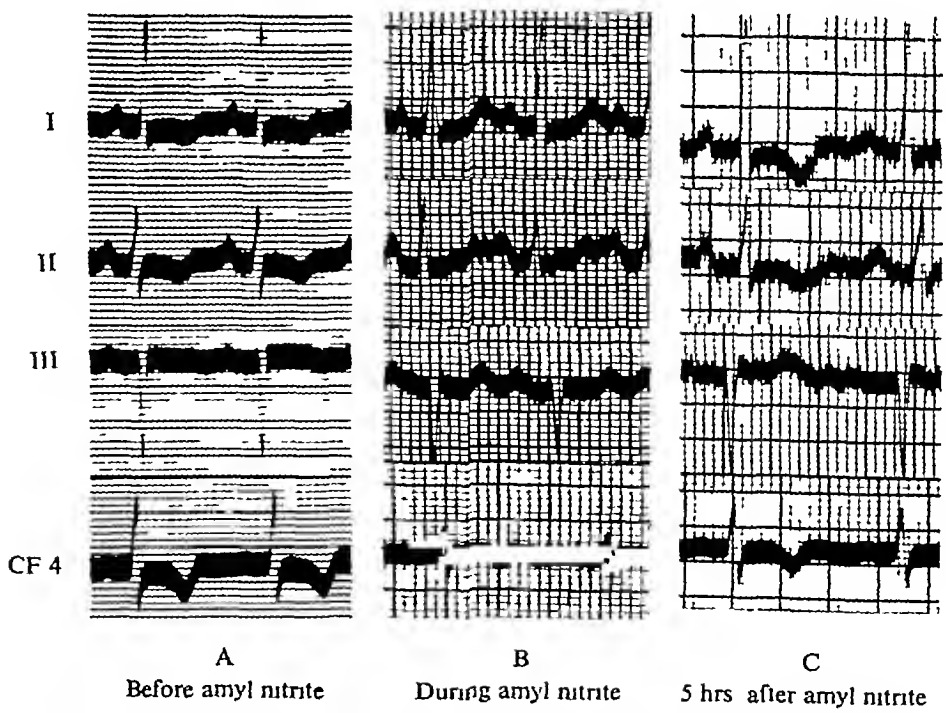

FIG 9 —Case 8 Showing how by inhalation of amyl nitrite it was possible temporarily to elevate inverted T waves in leads I and II

lead II having become upright and the deeply inverted T waves in V2–6 inclusive having all disappeared

Comment Severely incapacitating cardiac pain, both on effort and at rest, at first was accompanied by cardiographic changes of hypertensive heart disease and later by changes suggesting an extensive area of infarction, but without Q waves By inhalation of amyl nitrite it was possible temporarily to cause elevation of the T waves in the standard leads During the inhalation of amyl nitrite there was an increase in the heart rate, but this was no greater than had previously been produced by exercise without causing any alteration in the T waves

Case 9 (*Fig* 10) *Man, aged* 50 About the middle of February 1939 the patient began to experience attacks of severe pain just to the left of the sternum, passing down both arms It came both on exercise and whilst he was asleep in bed During each attack he became pale and a little cyanosed and was obviously in pain The duration of each attack varied from half an hour to two hours forty minutes and the pain was best relieved by amyl nitrite Between attacks he felt perfectly well, there was no dyspnœa, and his B P ranged from 130/86 to 140/96, on several occasions it was found to be raised immediately preceding an attack of pain, 160/110 to 186/120

A teleradiogram revealed slight enlargement of the left ventricle with some elongation of the aorta The first cardiogram taken on 10/3/39, two days after a very severe and prolonged attack of pain, showed T 4R to be sharply inverted, although no Q waves were present T 1 was possibly a little low though T 2 was of good amplitude A second record taken on 13/3/39, the patient having remained free from pain since his attack on 8/3/39, showed that T 4R had become quite upright Records repeated on 14/3/39 and 27/3/39 showed T 1 and T 4 to be still upright

Further attacks of pain occurred on 8/4/39, 11/4/39, and 13/4/39, and a record taken on 14/4/39 revealed that T 4 had again become deeply inverted and that T 1 had now become inverted for the first time

He remained free from pain until 20/4/39, on which day a very severe attack occurred lasting two hours forty minutes and accompanied by pallor, sweating, and tic-tac rhythm We obtained a record within a quarter of an hour of the start of this attack and it was normal, T 1 and T 4 having become upright since the previous record We repeated his cardiogram on the day following the attack and T 1

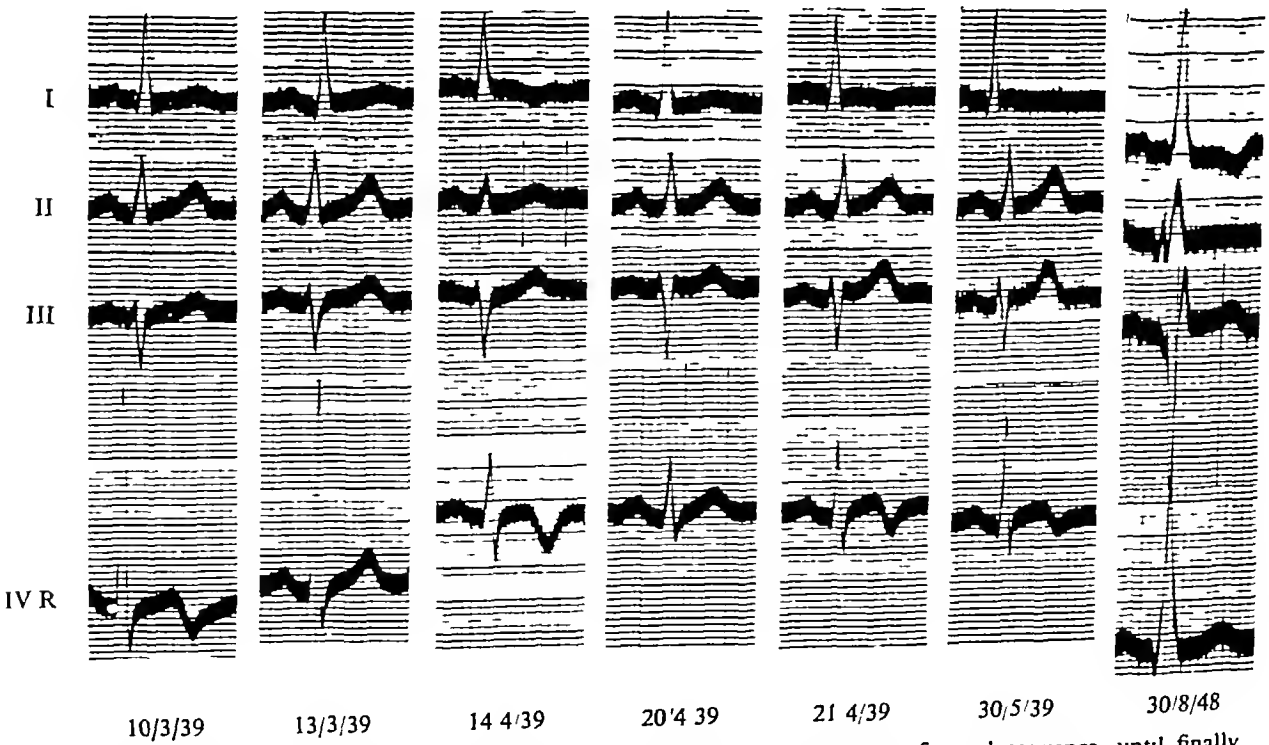

FIG 10 —Case 9 Showing deterioration and improvement of cardiogram, of rapid sequence, until finally deterioration persists This suggests that a transient myocardial defect, at first reversible, finally became established

and T 4 were then found to have become inverted once more, and the appearance of the RS–T segment in 4R was strongly reminiscent of a recent current of injury curve From that time on the curves remained abnormal For example, a record was taken each day from 22/4/39 to 28/4/39, and on various dates until 30/5/39 On 23/4/39 half-hourly records were taken from 7 a m to 12 30 p m, covering a period in which the patient was in pain and during which the pain wore off, but all records show the same inversion of the T waves

It was at that time considered that the change had probably become permanent although the Q waves were insignificant When seen again on 30/8/48 he stated he had remained free from pain since the middle of 1939, but that his breathlessness on exertion had lately become worse, and attacks of nocturnal dyspnœa were now occurring His B P had fallen to 130/80, and although T in IVR had become upright a wide Q of 2 mm depth had appeared in this lead, and T 2 had become flat (Fig 10)

Comment The records strongly suggest that a transient myocardial lesion, at first reversible, finally became established Again the cardiographic deterioration lagged considerably behind the patient s pain

Case 10 (Fig 11) *Man, aged 63* This was a case of hypertensive heart disease On admission to hospital his B P was 195/115 and his rhythm, confirmed by cardiogram on 30/12/47, was normal, the curve showing only signs of left ventricular hypertrophy Transurethral resection of the prostate was performed on 2/1/48, and the following day the patient complained of extremely severe burning pain in the chest and back He was pale and sweating, and auricular fibrillation was present The blood pressure had fallen to 110/80 and many pulmonary crepitations were audible The pain lasted several hours and we obtained a cardiogram during the attack This confirmed the presence of auricular fibrillation and lead CF 4 showed the T wave to be upright in some beats and inverted, occasionally sharply so, in others At times an upright T wave alternated with an inverted one The QRS deflection did not show this alternation

He was immediately given digitalis and also oxygen and papaverine By the next day he had regained normal rhythm and this persisted A record taken on 5/1/48 confirmed the presence of normal rhythm, and by that time the T waves in CF 4 showed the effect of digitalis only and were all of similar form and amplitude At the time of his discharge from hospital his B P was 200/105

Comment Sudden severe pain associated with much shock and transient fibrillation occurred on the day following prostatectomy During this severe pain the T waves in CF 4 showed alternation which had disappeared two days later when normal rhythm had reappeared No Q waves were present The only other case we could find illustrated with alternation of the T wave from upright to inverted, in that case in lead III only, is the one recorded by Hamburger, Katz, and Saphir (1936) Their patient, a woman aged 48, suffered from anginal attacks and at autopsy small multiple recent and organizing infarcts were present

Discussion

The problem is to determine the nature of the underlying pathological state that gives rise to the cardiographic changes described Any attempt to solve it must be largely conjectural, as the condition is of such good prognosis that it rarely presents an opportunity for autopsy

Inversion of the T wave can occur in the apparently normal subject, as White (1945) has pointed out We therefore first considered whether perhaps some of our cases might be accounted for in this way, although the presence of cardiac pain, and the frequently associated hypertension, can scarcely be considered as incidental findings Graybiel *et al* (1944) in an analysis of 1000 healthy young aviators, could find no example of inversion of T in leads I or IV However, Johnson (1940) during periodic

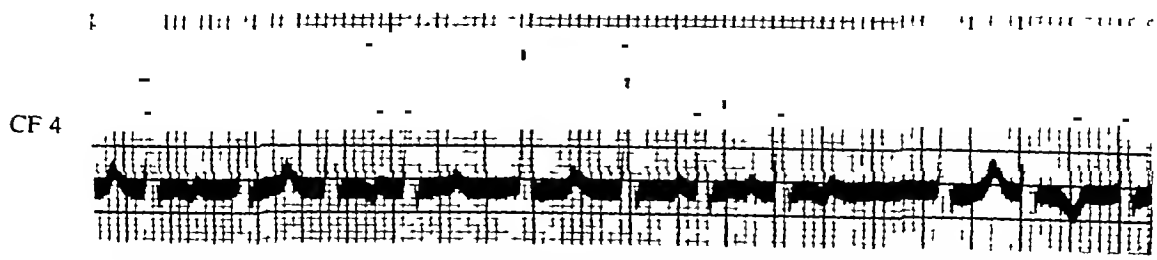

Fig 11 —Case 10 Lead CF 4 recorded during an attack of cardiac pain The T wave shows at times alternation, and varies from being sharply upright to being deeply inverted from beat to beat No Q waves are seen Auricular fibrillation is present

routine examinations of 2400 apparently healthy males of average age 48 years, found that 1 per cent had an inverted or diphasic T 1 and T 2, but only standard leads were employed and the degree of inversion is not stated Hall *et al* (1942) using the three standard leads discovered among the cardiograms of 2000 members of the Royal Canadian Air Force who were fit for air crew, only two records (0 1 per cent) in which T 1 was negative and considered abnormal In a study of 4810 soldiers, mostly psycho-neurotic, Stein (1946) could find only four (0 1 per cent) of them with inversion of T 1 and T 4 and in three of these the T inversion disappeared after exercise Plooij (1946) states emphatically, as a result of his investigation of functional variations of the T wave, that T 1 is never inverted in health The conclusions of Graybiel and White (1935) are similar It would therefore seem reasonable to conclude that the T wave changes in our cases were all of pathological origin

Considerable evidence has accumulated that reflexes originating elsewhere than in the heart, in particular in the alimentary tract, can cause cardiographic changes strongly reminiscent of cardiac infarction It is well known that, clinically, disease of the gall bladder, peptic ulcer, and hiatus hernia of the stomach can all produce symptoms that simulate angina pectoris It has been suggested that such diseases can be responsible *per se* for changes in the cardiogram that resemble those of myocardial infarction Clarke (1945) has shewn that the cardiogram may return to normal after the cure of a duodenal ulcer or of cholecystitis, and Brown (1946) and Fitz-Hugh and Wolferth (1935) quote similar cases Morrison and Swalm (1940) showed how, by dilating the œsophagus and stomach of a patient suffering from angina pectoris, changes in the cardiogram could be produced, but this included depression of the RS–T segment in lead 1 But the cardiographic changes as illustrated are minimal and could scarcely be confused with our records In addition, to the best of our knowledge none of our patients had disease of the alimentary tract The conclusion is that there is no reason on clinical grounds to suppose that the abnormal changes in our cases are due to derangement in the coronary circulation as a result of reflexes originating from lesions in the alimentary tract or elsewhere

Of recent years the term " coronary insufficiency " is used to explain abnormality in the cardiogram that may be associated with cardiac pain The pain can be induced by creating artificially a state of general cardiac anoxia, and the associated changes in the form of the cardiogram are used by Master (1946) and by Levy and his associates (1938, 1940, 1941, 1942) as an index of the functional efficiency of the heart Levy insists on the importance of deviation of the RS–T segment In a later paper, Patterson, Clarke, and Levy (1942) emphasized how the incidence of significant changes in the T wave increases with the degree of total RS–T deviation The records so obtained do not resemble ours

It would seem then that our records are not a normal variant, neither are they the result of reflexes arising from disease outside the heart, nor are they due to general cardiac anoxia Some local abnormality in the myocardium, of a temporary and reversible nature, is likely to be present Recently we have encountered two cases that throw some light on the problem

The first patient, a woman aged 41, under the care of Dr Clifford Hoyle, suffering from polyarteritis nodosa, complained of retrosternal pain during the night and her cardiogram next day showed that T 1, T 2 and T V4 were inverted and yet no Q waves were present (Fig 12) At autopsy there was no infarct, but three small nodules were found at the tip of the front of the left ventricle On microscopy these were confirmed to be due to polyarteritis nodosa, and many of the larger branches of the coronary arteries were also involved in that disease The second case was a man, aged 56, with a blood pressure of 180/100, who had been suffering from very severe cardiac pain, both at rest and on exertion and only of three months' duration The attacks of pain never lasted more than four minutes His cardiogram, less than two days before he died, showed inversion of T 1, T 2 and T VL and T V2–6 inclusive, but with no Q waves present (Fig 13) Yet at autopsy not only were his coronary arteries quite free from atheroma, but the muscle of the heart was quite normal to close naked eye scrutiny and to minute section of it There was nothing pathological in the microscopical section, from the right and left ventricle and the septum

It is possible therefore to have cardiac pain accompanied by cardiographic changes suggesting infarction, but without Q waves, where, in fact, local pathological changes other than infarction are present Sometimes with these curves no naked eye disease whatsoever is present, and yet the patient may succumb For many years the occasional absence of pathological changes in the myocardium in some patients who have died of angina pectoris has attracted the attention of clinicians, even to the extent of giving rise to Allbutt's theory that the pain was the " cry of a diseased aorta " The abnormal curves in this type of case show that the myocardium may be at fault even though no sign of disease can be detected at autopsy

It has, of course, been known for twenty years that a cardiogram taken during and shortly after

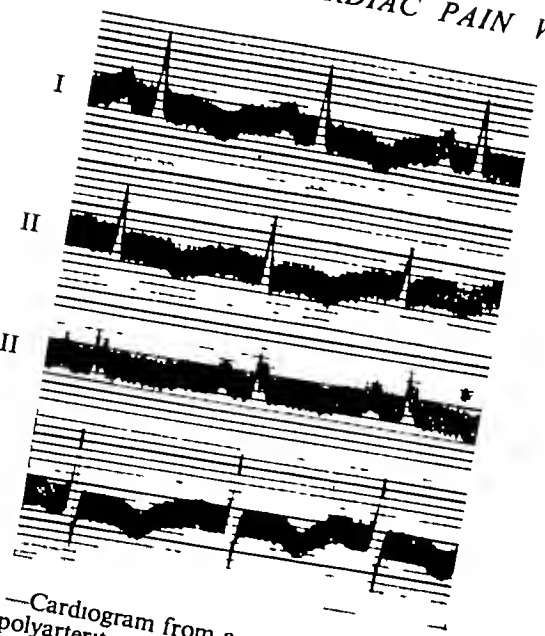

FIG 12 —Cardiogram from a woman aged 41 who died of polyarteritis nodosa At the front of the tip of the left ventricle there were several small nodules present which section revealed to be due to polyarteritis nodosa No infarct was present

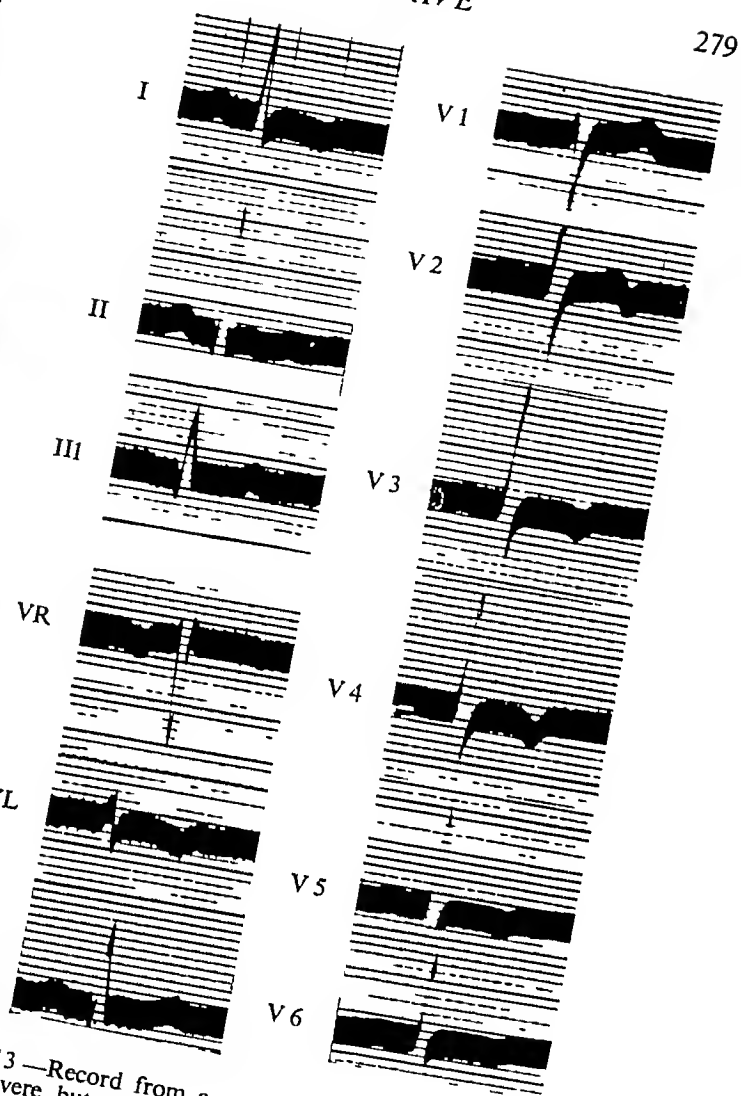

FIG 13 —Record from a man aged 56 suffering from severe, but very short, attacks of cardiac pain The cardiogram was taken less than two days before he suddenly died during a paroxysm of pain At autopsy the heart and coronary vessels were quite normal, both to naked eye and microscopical examination

anginal attacks, may show certain transient changes Feil and Siegel (1928) presented such records in four cases where cardiac infarction could be excluded, and in three of these they recorded a depression of the RS–T segment in leads 1 and 2 during the pain and a return to normal after the pain had ceased Shortly afterwards, Parkinson and Bedford (1931), employing standard leads, investigated five patients in none of whom was there any question of cardiac infarction at the time the records were taken, and in all five, during the pain the RS–T segment elevation or depression was noted In four, the cardiogram had reverted to normal within forty minutes, and although the time taken for the fifth one to revert is not stated, it was normal by the time the attack of pain had ceased On the other hand, Kahn (1931) studied the cardiograms of 330 cases of angina pectoris and observed that 8 of the 23 fatal cases died with no abnormality in the cardiogram, while they were suffering from repeated severe attacks Emphasis on the characteristic RS–T segment shift was reiterated by Riseman *et al* (1940) In a paper devoted to the study of 20 patients with angina, before, during, and after the attacks, they stated that the changes were most frequent and most striking in the præcordial leads, for in these, in all 20 cases, the RS–T segment was deviated They were of the opinion that only later, towards the end of an attack and also after the disappearance of the pain, did the T wave changes become pronounced Wilson and Johnson (1941) studied in detail cardiographic changes obtained during the paroxysms of substernal distress, either spontaneous or induced by exercise or cigarette smoking, in five cases of angina pectoris, and in all five there was displacement of the RS–T segment

It would seem then that the abnormal features shown by our cases are not simply those of the late stages of angina pectoris, as the segment shift was absent or negligible, the duration of the cardiographic changes was much longer, and many of our cases had prolonged pain at rest

Coming nearer to infarction itself, Feil (1937) thought that he could distinguish a type of pain that precedes coronary thrombosis, but this pain

does not resemble that experienced by our patients and neither do the cardiograms he obtained whilst they had this pain resemble ours Although Sampson and Eliaser (1937) also considered that it is possible to diagnose impending acute coronary occlusion, they gave no cardiographic details

Once an infarct has occurred, provided that enough cardiac muscle has died, there is good experimental evidence, as produced by Wilson *et al* (1933) in dogs, to show that a Q wave will be present This suggests that in our cases not much muscle, if any, could have died Certainly, in Case 10 of our series (Fig 11) in which the T wave in CF 4 varied so much from beat to beat, it is difficult to see how this could result from other than temporary metabolic disturbances Perhaps the clue to the lesion lies in the work of Bayley and his associates As a result of experimental work on dogs, Bayley and La Due (1944) state that the electrical phenomena resulting from occlusion of the anterior descending branch of the left coronary artery are entirely independent of *demonstrable* pathological changes, and that the ischæmia injury changes, though often associated with infarction in man, are not to be regarded as necessarily diagnostic of infarction In another paper, Bayley, La Due, and York (1944) used a unipolar lead in contact with the anterior surface of the pericardial sac and caused sudden complete occlusion of a dog's coronary artery, short of producing an infarct They concluded that, contrary to the common belief, the first stage in the cardiographic evolution of myocardial infarct is the appearance of primary T wave changes which are ascribed to local ventricular ischæmia In man, Bayley and Monte (1943) encountered a unique case A hypertensive man experienced cardiac pain while at rest and was considered, by estimating the areas under curve QRS and under curve T and calculating Â QRS, Â T, and Â QRS–T, to show a severe degree of ischæmia in the distribution of the right coronary artery This area diminished later and at autopsy the acute ischæmia was seen to have resulted from a dissecting aneurysm involving this artery No cardiac lesion, naked eye or microscopic, was present They concluded that " acute left ventricular ischæmia of sufficient intensity to produce striking T wave changes of a kind similar to those that occur in man with myocardial infarction, and lasting for days or even weeks, may be accompanied by no structural changes in the myocardium " They also call attention to the independent variation in magnitude and duration of acute local ischæmia, on the one hand, and pain on the other It is not yet known how long local ischæmia, associated with only primary T wave changes, must exist in order to be followed by local myocardial fibrosis

We conclude, therefore, that in our cases the presence of what we regard as primary T wave changes are the result of ischæmia of the myocardium caused by spasm of the coronary arteries We have noted also the absence of displacement of the RS–T segment and the absence of Q waves The reduction in the calibre of the vessel is not sufficient in degree or duration to lead to death of the myocardial fibres and subsequent fibrosis, or, if it does so, to anything but the slightest extent The essential thing is coronary spasm, coronary atheroma is not a necessary feature We do not know what causes such spasm nor why the left coronary artery should be involved so much more frequently than the right Lisa and McPeak (1940) believe that coronary spasm without atheroma can lead to what they term " acute miliary infarction," and that infection is the precipitating cause of the spasm Although their histological findings bear a striking resemblance to those seen in our Case 1, infection was not a feature of our cases, except possibly in Case 6

Summary

When patients thought to be suffering from cardiac infarction were followed up, a small proportion of them were found in whom the cardiogram returned to normal and remained so Most of these patients were hypertensive, and in more than half of them the attacks of pain ceased though the hypertension persisted

If the cardiogram of such patients is compared with that of indisputable infarction, it will be found that almost all of them are anterior in distribution, that the Q waves are absent or insignificant, and that with very few exceptions, there is no current of injury however early the record is taken On the other hand, we do not claim that a patient yielding such a curve as we have described, but not returning to normal, has necessarily a good prognosis , and we give an example where such a patient died suddenly, autopsy revealing no abnormality whatsoever The term " recovery of the T wave " does not necessarily imply recovery of the patient, although the prognosis in the group as a whole is surprisingly good

It is of course, well known that the majority of patients who experience cardiac pain that comes on at rest and lasts for, say, more than half an hour, will have an abnormal cardiogram But we would draw attention to the error of assuming that a patient with such pain, but with a normal cardiogram, cannot be suffering from cardiac pain Several of our cases had pain that was at first, and on more than one occasion, accompanied by a normal

record, which only later showed the expected pathological changes We suggest that prolonged spasm of the coronary artery is responsible for the cardiographic appearance, and only if the spasm is of sufficiently long duration does any fibrosis result, and this is minimal

Since submitting this paper we have encountered six further cases, five were anterior and one posterior

References

Bayley, R H, and La Due, J S (1944) *Amer Heart J*, **28**, 54
——, ——, and York, D J (1944) *Ibid*, **27**, 657
——, and Monte, L A (1943) *Ibid*, **25**, 262
Brown, H (1946) *Clin Proc*, **5**, 447
Clarke, N E (1945) *Amer Heart J*, **29**, 628
Feil, H (1937) *Amer J med Sci*, **193**, 42
——, and Siegel, M L (1928) *Ibid*, **175**, 255
Fitz-Hugh, T, and Wolferth, C C (1935) *Ann Surg*, **101**, 478
Graybiel, A, McFarland, R A, Gates, D C, and Webster, F A (1944) *Amer Heart J*, **27**, 524
——, and White, P D (1935) *Ibid*, **10**, 345
Hall, G E, Stewart, C B, and Manning, G W (1942) *Canad med Ass J*, **46**, 226
Hamburger, W W, Katz, L N, and Saphir, O (1936) *J Amer med Ass*, **106**, 902
Johnson, H J (1940) *Ibid*, **114**, 561
Kahn, M H (1931) *Ann intern Med*, **4**, 1499
Lenègre, J, and Chevalier, H (1946) *Arch Mal Coeur*, **39**, 37
Levy, R L (1938) *Amer Heart J*, **15**, 187
Levy, R L (1941) *Bull N Y Acad Med*, **17**, 898
——, Bruenn, H G, and Williams, N E (1940) *Amer Heart J*, **19**, 639
Lisa J R, and McPeak, E (1940) *Arch intern Med*, **65**, 919
Master, A M (1946) *New York Med*, **2**, 19
Morrison, L M, and Swalm, W A (1940) *J Amer med Ass*, **114**, 217
Parkinson, J, and Bedford, D E (1931) *Lancet*, **1**, 15
Patterson, J E, Clark, T W, and Levy, R L (1942) *Amer Heart J*, **23**, 837
Plooij, M (1946) *Arch Mal Coeur*, 39, 126
Riseman, J E F, Waller, J V, and Brown, M G (1940) *Amer Heart J*, **19**, 683
Sampson, J J, and Eliaser, M (1937) *Ibid*, **13**, 675
Stein, I (1946) *J Lab clin Med*, **31**, 837
Wilson, F N, and Johnston, F D (1941) *Amer Heart J*, **22**, 64
——, ——, Hill, I G W, and Grout, G C (1933) *Trans Ass Amer Phys*, **48**, 154
White, P D (1945) *Heart Disease*, 3rd ed, New York, p 207

THE HEART IN THE PNEUMOCONIOSIS OF COALMINERS

BY

ARTHUR J THOMAS

From Llandough Hospital, Cardiff

Received September 6, 1948

The pneumoconiosis of coalminers is a primary disorder of the lungs that can cause pulmonary heart disease, a condition also called cor pulmonale

The occurrence of right heart changes in pneumoconiosis was noted by Pancoast and Pendergrass (1931) Dyson (1933 and 1934) described the radiological recognition of heart disease in pneumoconiosis, and in a review of 127 cases found 18 with evidence of pulmonary heart disease Discussing the pathology of pneumoconiosis, Jaffe (1934) concluded that the replacement of large parts of the lungs by poorly vascularized scar tissue, and the occurrence of obliterative changes in the branches of the pulmonary artery, interfered greatly with the pulmonary circulation Right ventricular hypertrophy followed and failure of the right heart was a common cause of death in advanced pneumoconiosis

Coggins *et al* (1938) found that hypertrophy of the right ventricle was a common finding in the autopsy records of 102 proven cases of pneumoconiosis Other studies of the pathology of pulmonary heart disease record right ventricular hypertrophy with anthraco-silicosis (Scott and Garvin, 1941, Spain and Handler, 1946) In the South Wales anthracite coalfield, Gooding (1946) has reviewed a series of 227 post-mortem examinations on miners certified as having pneumoconiosis, 37 per cent are described as having died from cardiac failure, usually right-sided

Emphysema is a common cause of pulmonary heart failure Gough (1940, 1946, 1947) has described the occurrence of emphysema in coalminers' pneumoconiosis and has differentiated the focal emphysema from the bullous emphysema that occurs in later stages of the disease Geever (1947) has confirmed the occurrence of pulmonary vascular changes

The clinical course of a pulmonary disease may be divided into two phases, the pulmonary phase and the cardiac phase (Brill, 1939) The clinical features of the cardiac phase in pneumoconiosis have been described by several writers, some of whom have indicated the difficulties in assessing the degree of involvement of the right heart (Coggins *et al*, 1938, Giering and Charr, 1939, and Ketterer, 1941)

McMichael and Sharpey Schafer (1944) have drawn attention to the fact that cases of cor pulmonale may have a high cardiac output They have found this in patients with emphysema, gross venous congestion, and a low arterial oxygen saturation In the terminal stages the left heart may fail and pulmonary œdema occur

The pneumoconiosis of coalminers has been presented in detail by Fletcher (1948)

Selection of Cases

The subjects of this investigation have been inpatients under the care of the Pneumoconiosis Research Unit (M R C) at Llandough Hospital A certain measure of selection has been exercised in this series because of the exclusion of patients with any signs of cardiovascular disease other than that resulting from the pulmonary disorder There are 96 cases of coalminers' pneumoconiosis ranging from the earliest detectable stage to the final stage of advanced disease and right heart failure Their ages vary from 28 to 65 years, but the severity of the disease is not proportional to the age For ease of description a clinical grading has been adopted, based on the history, the degree of dyspnœa, and the capability for exertion

The Clinical Examination

The symptoms of the pulmonary phase were dyspnœa, fatigue, cough, and intermittent attacks of pain in the chest The dyspnœa was exertional and slight at first, but usually increasing in severity Paroxysmal dyspnœa was not uncommon and was not cardiac in origin A complaint of being easily fatigued was often an early symptom Cough was present at some stage, sometimes productive in type The pain in the chest was the result of the pulmonary

TABLE I

CLASSIFICATION OF CASES

		No of cases
Grade I	Those not definitely disabled	14
Grade II	Those with slight disability	35
Grade III	Those with moderate disability	15
Grade IV	Those with serious or complete disability	32

disease although sometimes simulating pain of cardiac origin The site of the pain in the chest varied from time to time, and its onset was not always related to exertion The physical signs of the pulmonary phase were similar to those of emphysema and chronic bronchitis without heart disease

The symptoms of the cardiac phase were severe dyspnœa, gross disability, œdema of the feet and ankles, and upper abdominal discomfort The patients would often complain only of marked exacerbation of their previous condition

The physical signs of the cardiac phase were orthopnœa, cyanosis, engorgement of the neck veins, warm hands, œdema of the ankles, tenderness of the palpable liver, a full peripheral pulse of regular rhythm, and triple heart rhythm

Orthopnœa might be the earliest sign of imminent heart failure and might be related to the history of an exacerbation of the pulmonary phase Cyanosis was occasionally present with the advanced pulmonary phase but was often a sign of right heart failure Engorgement of the neck veins was present only when the heart failed, it has not been seen in this series as a result of the pulmonary disorder alone Warm hands were noted when failure occurred but the sign was less distinctive as failure persisted Œdema of the feet or ankles appeared as a very early finding and quickly increased to a severe degree The liver might be palpable in the pulmonary phase owing to the low diaphragm but tenderness was limited to the cardiac phase The pulse was full and usually of regular rhythm The blood pressure in all these cases was between 100 and 150 mm systolic, and 50 and 90 mm diastolic The majority had a blood pressure of the order of 110 systolic and 70 diastolic The heart size and position were difficult to assess The cardiac impulse was felt in the epigastrium The heart sounds were distant except at the sternal margins and in the epigastrium Triple heart rhythm (protodiastolic gallop) was heard to the left of the lower sternum in 75 per cent of the cases when the right heart failed There was accentuation or splitting of the second sound in the pulmonary area A systolic murmur of moderate intensity was heard in the mitral area in two cases Slight sinus tachycardia was evident at complete rest and the rate accelerated with the slightest exertion One patient was exceptional in having auricular flutter, there were no records of auricular fibrillation The hæmoglobin levels were within normal limits except in two cases where the readings were below normal Severe jaundice was noted in one case of severe failure and milder jaundice in another

Right heart failure was present in 11 cases in 9 of them it was fatal

The stage at which right heart involvement first occurred was difficult to detect One half of those in the pulmonary phase showed a maximal impulse at the lower end of the sternum and had accentuation or splitting of the pulmonary second sound The splitting of the second sound was often audible down the left border of the sternum In one instance a short diastolic murmur was audible at the pulmonary area with the breath held in inspiration The signs found in the pulmonary area can be classed as suggestive of right heart strain The clinical examination is not very helpful in detecting early right heart involvement

THE RADIOLOGICAL EXAMINATION

The clinical worth of radiology in the study of heart disease has been stressed by Parkinson (1936) The pathological studies of Kirch (1930) on the right ventricle and its inflow and outflow tracts are applicable to this work Kerley (1931), Schwedell (1946), and many others have described the radioscopic features of right ventricular enlargement

Enlargement of the right ventricle takes place first in the outflow tract and is seen as a prominence of the pulmonary conus-artery segment There is straightening of the upper left cardiac border in the anterior view and an anterior bulge reducing the retrosternal space in the right anterior oblique view Right ventricular inflow tract enlargement is manifested by increasing width and depth of the right ventricle in the anterior and the left anterior oblique views, particularly in the latter Tomography of the



B

A

FIG 1 —(A) July 1941 (B) The same patient in July 1947, aged 45 years The heart shape has changed The right ventricular outflow tract is enlarged in 1947 (Fig 4)

B

A

FIG 2 —(A) October 1938 (B) The same patient in June 1947, aged 55 years The left cardiac border has lengthened and now shows the prominence of the pulmonary artery and below the artery the pulmonary conus"

heart shadow in the right anterior oblique view has been found of value in recording enlargement of the right ventricular outflow tract

Two noteworthy changes occur in the shape of the heart in pneumoconiosis, one is elongation and assumption of a vertical position, the other is enlargement of the outflow tract of the right ventricle

The general heart shape is analysed in Table II In ten instances, where previous records are available, analysis proves that marked elongation of the heart shape has occurred, radioscopy now shows that the original heart shape cannot be reformed by any respiratory movement (Fig 1 and 2) The diaphragm has been depressed to produce the elongation, and in some a further real or apparent elongation is produced by the elevation of the lung hila (see Fig 5)

Five patients in right heart failure had heart shadows rather wider than is expected (Fig 3) The belief that widening has occurred due to right ventricular inflow tract enlargement is supported by the demonstration of this enlargement in two cases on radioscopy, and by the measuring of actual widening of the shadow in successive teleradiograms of a third case Even so, the radiological and pathological size of the hearts of those in failure is small, relative to those with the same degree of heart failure from other cardiovascular diseases

Enlargement of the pulmonary artery and of the outflow tract is a finding of a major importance Their detection is not easy when much elongation is present and is even more difficult when there is gross distortion The incidence of this finding is given in Table II

Further changes may not be detected in some cases for many years During this interval the heart usually elongates vertically The final stage is reached when the inflow tract dilates and right heart failure follows very quickly

The period of prominence of the outflow tract only is presumably that of increase in pulmonary artery pressure and may be called the stage of right heart strain

The Electrocardiographic Examination

The electrocardiographic pattern of right ventricular hypertrophy has been described by Wilson *et al* (1930, 1944, 1947) and Myers *et al*, (1948) The three standard leads are affected by the position of the heart and the examination of præcordial lead tracings is essential in studying the right heart The presence of right axis deviation in the standard leads accompanied by inversion of T II and T III is not diagnostic of right ventricular hypertrophy, (Myers *et al*, 1948) In pronounced right ventricular hypertrophy abnormally large R waves with a late peak, frequently Q waves and inverted T waves, are found in leads from the right side of the præcordium In leads from the left side of the præcordium R is often smaller than usual and an S wave persists The QRS deflections are not usually large, nor is the QRS interval wider than normal

The standard limb leads have been recorded in all cases in this series An analysis of the axis deviation is shown in Table III

The common pattern in the standard lead tracings is that associated with the long vertical heart—QRS of small amplitude in lead I, R wave of good amplitude in leads II and III, and frequently a small Q wave in leads II and III Inversion of the T wave in leads II and III occurs in records from 8 patients, 6 of whom were in clinical grade IV

A high P wave in lead II has been described in pulmonary heart disease by Winternitz (1935) and others, but there is still doubt as to its true significance Thirty-two records show a P wave in lead II of an amplitude between 2 and 3 mm , fourteen

TABLE II

Radiological Changes in the Heart

Clinical grades	No of cases	Long vertical heart shape	Right ventricular outflow tract enlargement
I	14	1	Nil
II	35	8	2
III	15	7	9
IV	32	21	24

Prominence of the pulmonary conus-artery segment has been detected in 4 cases without elongation of the heart shape or heart failure The remaining 31 with enlargement of the outflow tract include 11 cases that had signs of right heart failure (Fig 3, 4, and 6)

Pulmonary conus-artery enlargement has taken place at a comparatively early stage in 2 cases, and has been found with moderate disability in 9 others

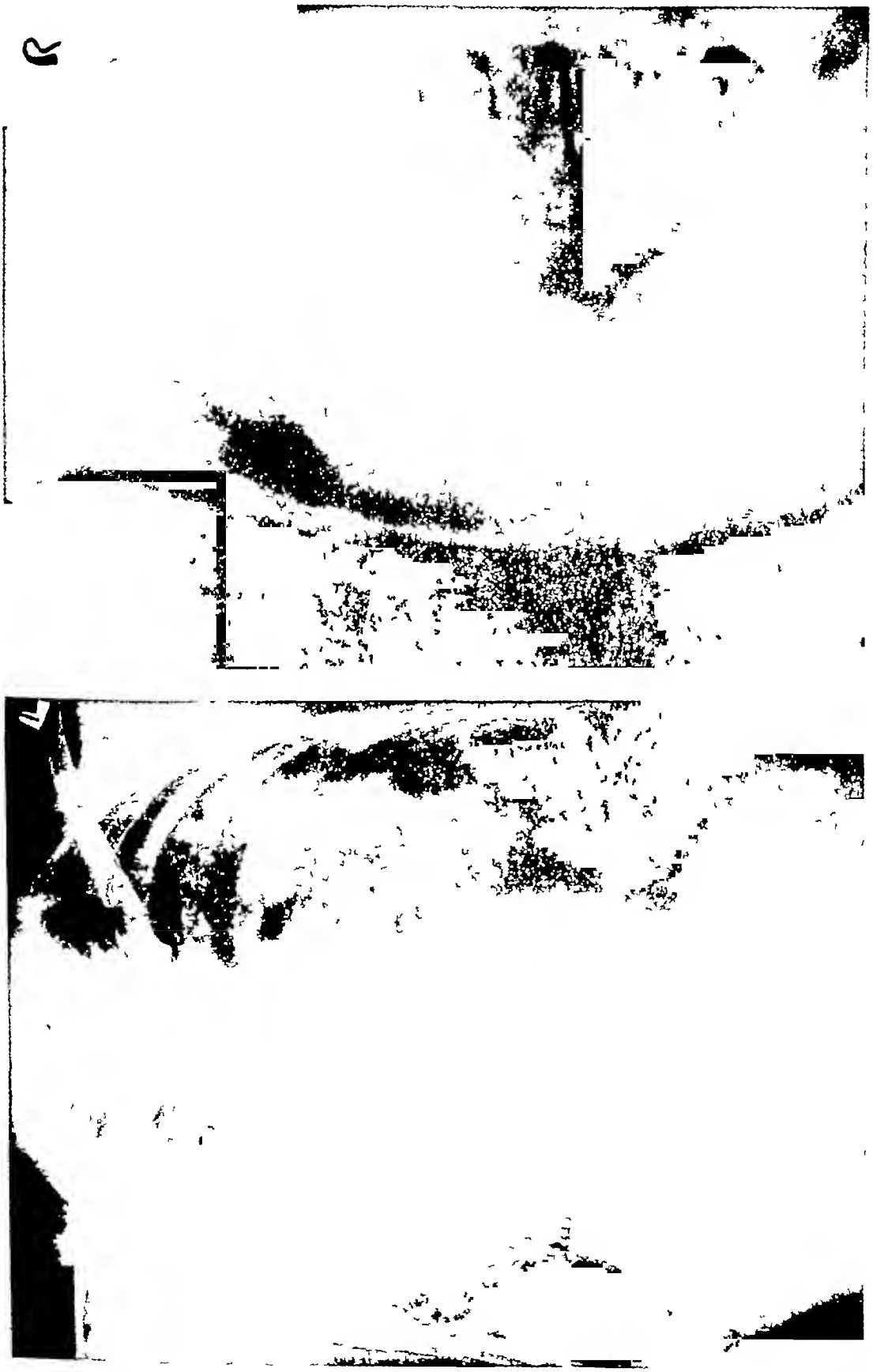

A B

FIG. 3.—(A) Anterior view. (B) Lateral view. From a patient, aged 47. In the lateral view the anterior prominence and high curvature of the enlarged right ventricle is seen. This patient was in right heart failure. The right ventricular hypertrophy was confirmed post-mortem. (See also Fig. 7B.)



FIG 5

FIG 4

FIG 4 —Right anterior oblique view of the heart shown in Fig 1B Enlargement of the outflow tract of the right ventricle is seen as a prominence of the upper portion of the anterior border

FIG 5 —Bronchogram May 1947 This shows the effect on the heart shape of the distortion depression of the diaphragm and elevation of the hila



A B

FIG 6—(A) and (B) Tomograms of two patients taken in the right anterior oblique view to record the enlargement of the right ventricular outflow tract which had been seen on radioscopy

TABLE III

AXIS DEVIATION IN ELECTROCARDIOGRAMS

Axis	0° to + 29°	+ 30° to + 59°	+ 60° to + 89°	+ 90° to + 120°	Over + 120°
Cases	12	13	40	28	3

have a P wave over 3 mm amplitude in lead II The P wave is abnormally high in these fourteen cases, ten of whom are in clinical grade IV It only coincides with other detectable signs of right heart involvement in nine cases The possibility that rotation of the heart is responsible for the high P wave of lead II cannot be excluded (Fig 7)

The unipolar limb leads have been recorded in twenty cases VL has a QS deflection in fifteen, which is indicative of the vertical heart position VR in five tracings has an R wave suggestive of right ventricular hypertrophy

Chest leads have been recorded in all cases, CR leads in the first 30 and V leads in the other 66 cases In eight tracings the pattern of pronounced right ventricular hypertrophy was seen (Fig 7) All had radiological evidence of right ventricular prominence and post-mortem confirmation of the hypertrophy of the right ventricle has been obtained in three of them

There is a second group of eight tracings with a distinctive pattern The QRS complex in leads from the right side (V4R, V3R, V1) is of low amplitude and has a RSR′ form, leads from the left side of the præcordium show a persistent S wave This pattern is suggestive, but not evidence, of right ventricular hypertrophy (Fig 7D) Three of these patients had right heart failure and the right heart hypertrophy has been confirmed post-mortem, three others had radiological evidence of right ventricular prominence

A third group of ten tracings shows a predominantly S wave pattern from the right side of the chest with a small S wave persisting through V4 to V6 (Fig 7E) The R wave is of normal character in the leads from the left chest This pattern is not evidence of right ventricular hypertrophy but is of interest because six of these cases were considered to have right heart strain and the right ventricular hypertrophy has been confirmed at autopsy in two of them It is apparent that rotation has played a part in producing this pattern and the taking of leads from other positions may be of value in confirming the change in the heart

Twenty-six records thus show abnormality but the classical pattern of ventricular right preponderance is found only in eight The second chest lead pattern described above deserves to be classed as suggestive of right heart involvement It is clear that the position of the heart, changed as it may often be in this disease, can modify the chest lead pattern and it is important therefore to take leads from positions further to the right than lead V1 and from as far left as V6

In thirty cases unipolar leads from the right upper abdominal quadrant and from the left upper scapular region have been taken (Goldberger, 1944) The results were not conclusive and heart position again seemed to cause variation The majority had an upright complex in the abdominal lead, and a downward complex in the scapular lead, a few were diphasic in nature and of very low amplitude

CONCLUSIONS

Right heart failure occurs in the late stage of pneumoconiosis of coalminers as a result of the pulmonary lesions When this happens, the clinical picture is the same as that found in heart failure due to other pulmonary diseases, it is true pulmonary heart disease There is radiological evidence of the right ventricular enlargement and in some cases there is electrocardiographic evidence of right ventricular hypertrophy Other factors such as rotation of the heart or distortion may mask the typical cardiographic or radiological features

In the early stages of pneumoconiosis, no evidence of right heart involvement can be detected by the methods used in this investigation

There are cases in the intermediate stages in whom evidence of right heart strain has been found Accentuation and splitting of the pulmonary second sound are early signs suggestive of an increase in the tension in the pulmonary artery Later in the disease it has been possible to demonstrate a prominence of the pulmonary artery and of the outflow tract of the right ventricle The electrocardiograph has not been as helpful in this group, but has sometimes provided supporting evidence of right ventricular hypertrophy This right heart strain can persist for a long period, amounting to some years, before the final stage of right heart failure appears Clearly not more than 50 per cent of the total will develop right heart failure

The order and frequency of appearance of the signs of right heart strain are only to be expected

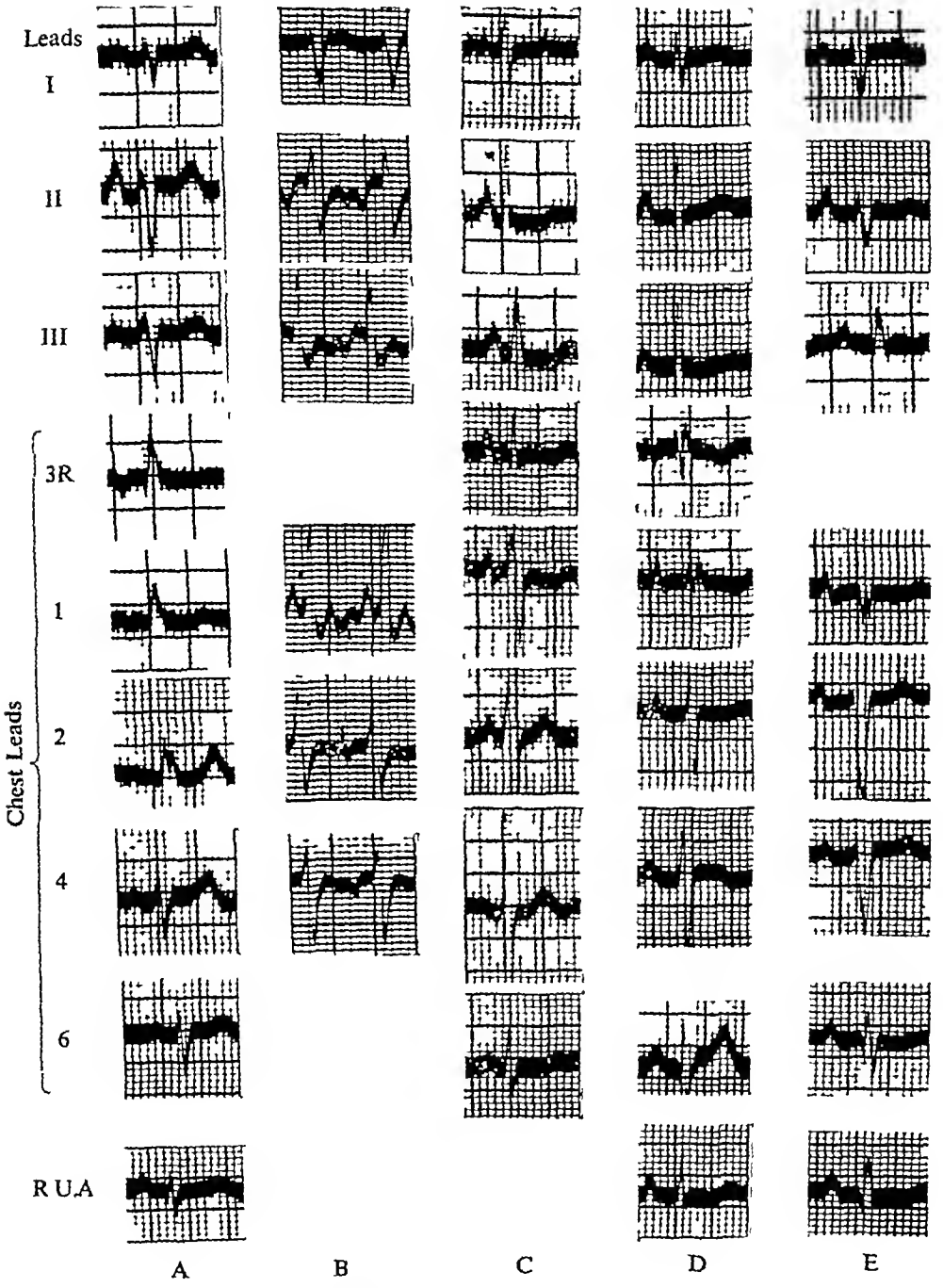

FIG 7—Cardiograms of five patients with right heart involvement The chest leads in (B) are CR leads, all others are V leads

(A) Clinical grade IV The pattern is that of right ventricular hypertrophy This agreed with the other findings

(B) The pattern is that of right ventricular hypertrophy but auricular flutter is also present The same case as in Fig 3

(C) Right ventricular hypertrophy which was confirmed later, post-mortem

(D) Clinical and radiological evidence of right heart strain, the pattern is placed in the second group described in the text as suggestive of right heart strain

(E) The "S" wave chest lead pattern placed in group three in the text, and not taken as evidence of right heart strain It is probably caused by rotation of the heart The presence of right ventricular hypertrophy was confirmed later in this case

R U A is the unipolar lead taken from the right upper abdominal quadrant

when it is realized that the initial causation is the change in the dynamics of the pulmonary circulation Increase in the pulmonary arterial pressure first affects the pulmonary second sound, then dynamic enlargement of the pulmonary artery appears There follows a dynamic enlargement of the right ventricular outflow tract and it is only when hypertrophy takes place in this tract that the electrocardiographic changes can be expected The progression is slow but super-added respiratory infections can precipitate the process

The relating of the signs of right ventricular strain to the pulmonary changes is difficult Cournand (1947) has drawn attention to the presence of pulmonary hypertension in patients with pulmonary fibrosis and moderate emphysema, when pulmonary hypertension has not been found in those with moderate emphysema alone Right heart strain is present in cases in this series without severe bullous emphysema but, as shown by Gough, focal emphysema, fine radiating fibrosis, and pulmonary vascular changes may be present The clinical disability of such cases is only moderate in degree, but the findings in this investigation suggest that pulmonary hypertension is already present A closer investigation of the respiratory functions of patients with early right ventricular strain may help to elucidate the factors involved in the causation of pulmonary hypertension

Summary

A clinical study of the cardiovascular system has been made in 96 patients with pneumoconiosis of coalminers Eleven patients had right heart failure and another twenty-four had evidence of enlargement of the right ventricular outflow tract Radiological examination has been of most value in detecting early right heart involvement Electrocardiographic examination has been helpful in some cases, and the cardiographic patterns are described

I wish to thank Dr C M Fletcher, Director of the Pneumoconiosis Research Unit (M R C) for permission to study the cases under his care and for access to the records of these cases A part of this work was incorporated in a Thesis accepted by the University of Wales in 1947

References

Brill, I C (1939) *Ann intern Med*, **13**, 513
Coggin, C B, Griggs, D E, and Stilson, W L (1938) *Amer Heart J*, **16**, 411
Cournand, A (1947) *Bull N Y Acad Med*, **23**, 48
Dyson, J M (1933) *Amer J med Sci*, **186**, 165
—— (1934) *Amer Heart J*, **9**, 764
Fletcher, C M (1948) *Brit med J*, **1**, 1015, 1065
Geever, E F (1947) *Amer J med Sci*, **214**, 292
Giering, J F, and Charr, R (1939) *J Amer med Ass*, **113**, 574
Goldberger, E (1944) *Amer Heart J*, **28**, 621
Gooding, C G (1946) *Lancet*, **2**, 891
Gough, J (1940) *J Path Bact*, **51**, 277
—— (1946) *Lancet*, **1**, 462
—— (1947) *Occup Med*, **4**, 86
Jaffe, R H (1934) *Illinois med J*, **66**, 431
Kerley, P (1931) *Recent Advances in Radiology*, London
Ketterer, C H (1941) *Med Bull Veterans' Adm*, **18**, 98
Kirch, E (1930) *Klin Wschr Berl*, **9**, 769
McMichael, J, and Sharpey Schafer, E P (1944) *Quart J Med*, **13**, 123
Myers, G B, Klein, H A, and Stofer, B E (1948) *Amer Heart J*, **35**, 1
Pancoast, H K, and Pendergrass, E P (1931) *Amer J Roentgenol*, **26**, 556
Parkinson, J (1936) *Lancet*, **1**, 1337, 1391
Schwedell, J B (1946) *Clinical Roentgenology of the Heart*, p 103, *Ann Roentgenol*, New York
Scott, R W, and Garvin, C F (1941) *Amer Heart J*, **22**, 56
Spain, D M, and Handler, B J (1946) *Arch intern Med*, **77**, 37
Wilson F N, Macleod A G, and Barker P S (1930) *Amer Heart J*, **6**, 637
——, ——, Johnston, F D, and Barker, P S (1933) *Ibid*, **9**, 447
——, *et al* (1944) *Ibid*, **27**, 19
——, Rosenbaun, F F, and Johnston, F D (1947) *Advances in Internal Medicine*, **2**, 37
Winternitz, M (1935) *Med Klin*, **31**, 1575

PROCEEDINGS OF THE BRITISH CARDIAC SOCIETY

The TWELTH ANNUAL GENERAL MEETING of the British Cardiac Society was held at the Liverpool Medical Institution on Thursday, May 13, 1948 Chairman John Hay The Chairman took the chair at 9 30 a m , 82 members and 12 visitors were present

PRIVATE BUSINESS

1 The minutes of the last Annual Meeting, having been published in the Journal (9, 304, 1947) were taken as read and confirmed

2 The balance sheet for 1947–48 was presented, having been audited by Hay and Wyn Jones The credit balance on April 21, 1948, was £88 13*s*. 4*d*

3 The meeting confirmed the action of the Council (under Minute 7 of the last meeting) in conferring Honorary Membership on

Dr Helen Taussig, Baltimore
Dr Alfred Blalock, Baltimore
Dr Harold Pardee, New York
Dr Andre Cournand, New York
Dr Camille Lian, Paris

4 Cotton was elected as a member of the Council in place of Wallace-Jones (resigned) Cookson and I G W Hill were elected in place of Peel and Parsons-Smith (terms of office expired)

5 Athelstone Hill was elected as an *Extra-Ordinary Member*

6 The following Associate Members were elected as *Ordinary Members*

Arnott, Lendrum, Hunter, O Donovan, Kerley

7 The following new *Associate Members* were elected

G Aitken, Glasgow
C G Baker, London
R E Bonham Carter, London
E M Buzzard, Oxford
W E Clarke, London
D H Davies, Bristol
Frances Gardner, London
J Gibson Graham, Glasgow
T E Gumpert, Sheffield
G Hayward, London
S Oram, London

8 The following *Associate Members* were elected for a further period of three years

R J Duthie	E Graham Jones
J G M Hamilton	B B Morgan
F M Hilliard	W R Snodgrass
J C Hoyle	A J Wilson

9 The following addition was made to Rule 6

"In addition there may be 10 Ordinary Members who may be elected for their interest in cardiovascular surgery"

It was agreed that the Council should decide from time to time whether Rule 12 should be enforced as regards these members

After discussion it was agreed that surgeons specializing in surgery of the sympathetic should be included under this addition to Rule 6 and it was also agreed that the operation of this rule should not hinder election of new Ordinary Members from the list of Associate Members

10 The following Surgeons were elected as Ordinary Members under the new addition to Rule 6

R C Brock	C Price Thomas
P R Allison	O S Tubbs
T Holmes Sellors	Vernon C Thompson

11 Resignations were received and accepted from

A G Biggam, I de Burgh Daly, M Kremer

12 After discussion it was agreed that an Autumn Meeting should be held this year as an experiment, some time in October, and that the place of the Meeting should be left to the Council for decision

DISCUSSION ON SYMPATHECTOMY IN HYPERTENSION

Opened by ROBERT PLATT, RAE GILCHRIST, CLIFFORD WILSON, and W T COOKE

ROBERT PLATT (*introduced*) Although sympathectomy may be described as dangerous, unphysiological, and undesirable, it must be admitted that in a certain number of cases—probably 30 to 40 per cent—it achieves results that are clearly worth while and cannot be achieved by any other method in use at the present time In some of these the blood pressure is brought from dangerous levels into a range of comparative or complete safety It is not proposed to discuss how sympathectomy acts but it is important to be sure that the patients are better for the reduction in blood pressure Undoubtedly they are, for symptoms disappear, the heart size diminishes, electrocardiograms improve, and retinopathy may disappear, and there is no evidence of deterioration in renal function as a result of the operation

The question of selection is difficult and makes it

usually impossible to compare one series with another If the procedure were harmless and reliable obviously it should be used in an early stage of the disease As it is neither, the speaker has reserved operation for cases in which the prognosis is otherwise judged to be bad These are usually patients under 50 years of age with diastolic pressures remaining at 125 or more after adequate rest, provided that renal and cardiac function are not badly affected, or arteriosclerotic changes advanced Early signs of impending cardiac failure or a transient cerebral incident have been regarded as indications for operation as soon as possible Such a selection is hard on the surgeon and liable to increase the mortality

Pentothal and other depressor tests show a general correlation with the results of sympathectomy in that the patients who do not respond to the one rarely respond to the other, but there are exceptions and a poor response to depressor tests has not been regarded as ruling out treatment by operation

In Manchester an extensive operation has been done by Boyd in two, three, and sometimes four stages, the sympathetic chain being removed from the 4th dorsal to the 3rd lumbar, since G A G Mitchell (*Edin med J*, 1947, **54**, 545) has shown that this is necessary in order to be reasonably certain that the sphlanchnic area is denervated

Table I shows the results to date in 54 cases These are not classified with regard to ætiology but successes have included essential hypertension, chronic pyelonephritis, and hypertension resulting from pregnancy kidney The cases described as of malignant type have all shown papillœdema with very high diastolic pressures

TABLE I

RESULTS OF SYMPATHECTOMY, MAY 1948

	Total	Malignant type
Still incomplete or too recent	10	4
Failed to complete operation	4	3
Deaths	10	3
Failures after complete operation	14	3
Worth while result	5	3
Good result	11	1
Total	54	17

Table II shows the change in diastolic pressure after operation, and it will be noted that in the 11 cases classified as " good results " the average post-operative blood pressure is at a very satisfactory level Cases recorded as " worth while " would appear to have had their pressures reduced to much safer (though still not satisfactory) levels

TABLE II

SYMPATHECTOMY CASES, MAY 1948

Group	Average age	Average pre-op pressure	Average post-op pressure (lying)	Change in diastolic
Good results	36	210/130	140/90	− 40
Worth while results	38	230/145	180/110	− 35
Failed	37	230/140	230/140	0

A H Radcliffe, in Professor Boyd's department, has been using a sensitive method of charting electrical skin resistance and finds that in the failures the area of skin which has been efficiently sympathectomized is much smaller than in the successful cases The correlation is not exact but the investigation suggests that in many cases failure is due to the fact that efficient sympathectomy has not been achieved This may be due to anatomical anomalies

Owing to a number of deaths having occurred as a result of the operation a physician was detailed to watch some of the operations The sudden falls of pressure which may occur as the result of anæsthesia, movement of the patient, and the operation itself, are extremely alarming, and it is felt that some of the fatalities could have been avoided if the anæsthetists had had a clearer appreciation of the dangers A sudden fall in pressure can usually be combated by methedrine

RAE GILCHRIST As the leading cause of death and with complications more widespread and more devastating than the ravages of malignant disease, the degenerative process labelled " hypertension " remains our greatest medical problem The pressing need at the present time is the development of methods for the prevention of vascular damage at the sites that take the brunt of the burden, namely the retinal, renal, cerebral, and coronary systems Until such time as a rational specific therapy is available, as in diabetes or pernicious anæmia, treatment necessarily falls short of the ideal and symptomatic measures, whether medical or surgical, must be employed in a palliative sense We recognize their inadequacy

It might well be thought that the evaluation of a precise method of treatment such as sympathetic surgery offers for a state of affairs so common and so easily recognized as essential hypertension should not present any great difficulty The reverse, however, is the case An adequate knowledge of the

course and complications of hypertension is unfortunately lacking In consequence it is difficult to compare the results obtained by medical and surgical methods There are so many interacting factors such as age, sex, duration, severity, renal function, retinal grouping, and, above all, vascular vulnerability, that it is difficult to present for study exactly comparable groups—the one treated surgically and the other medically Recognizing the limitations and admitting the crude method of analysis employed, a comparison of the results obtained, based on a study of 126 cases of hypertension, has led to the following tentative conclusions Our data have not yet been submitted to specialized statistical methods and are therefore open to criticism Our results are largely impressions

Eighty patients suffering from benign hypertension received medical care exclusively and forty-six received in addition surgical attention All were subjected to detailed investigations according to a predetermined routine and have been followed for periods up to 5 and 8½ years, respectively

Symptoms as a test of cure are misleading in that their intensity cannot be gauged with accuracy, and the spontaneous fluctuations and natural remissions, which are a feature of the disease process, make accurate deductions all the more difficult Nevertheless, in the medical group symptomatic improvement was observed, though the changes were relatively slight In the surgical group, in whom symptoms were distinctly more severe, symptomatic improvement was striking For instance, in the medical group, at the end of 3 years, 20 per cent were symptom free, and in the surgical group approximately 50 per cent We do not have sufficient facts to warrant the conclusion that sympathectomy postpones the date of death from vascular disease

Progress has also been assessed on the response of the diastolic blood pressure This sign is also admittedly fallacious, for if there is one finding more misleading than another, more liable to unpredictable fluctuations, it is the blood pressure level The diastolic pressure has a smaller range than the systolic and we have therefore attempted to make use of it for comparative purposes by recording the figures in the horizontal position after at least half-an-hour's rest, the subject being thoroughly accustomed to the surroundings, the technique, and the observer In the medical group the tendency is for the diastolic pressure to rise with the passage of time Comparing the findings at the end of 3 years, there is an increase in the number of patients with a diastolic pressure over 120, just as there is a decrease in the number of those with a diastolic pressure 100 or less There is therefore a tendency for the diastolic pressure to rise, despite a reduction in the severity of the symptoms In the surgical group at the end of 3 years there is an increase in the number of patients with diastolic pressures under 100 and some reduction in the number of those in the middle ranges, without much alteration in the proportion of patients with diastolic pressures over 120 It therefore appears that 3 years after sympathectomy a significant fall of diastolic pressure remains evident in approximately 20 per cent of the patients submitted to surgery There were 5 fatal cases in the 46 submitted to surgery All died from vascular causes

Thirty patients suffering from malignant hypertension have been under observation, 10 of whom had sympathectomies done—a number too few to justify statistical analysis, but the facts observed are worth recording The 20 patients treated medically without exception died within six months of coming under observation Of the 10 receiving surgical treatment, 3 obtained no benefit and in the light of further experience would not now be submitted to surgery Moderate benefit, enabling a return to work for a year or two, in 2 patients was encouraging The remaining 5 have made remarkable improvement, all showing a regression in the retinitis and a subsidence of the papillœdema, without, however, any significant change in the level of the diastolic pressure Our most remarkable case is a man aged 47, well and in steady employment 4 years after sympathectomy He came under observation on account of hæmoptysis with papillœdema

It is in this group that sympathetic surgery can claim its greatest achievements Provided renal function is reasonably good and heart failure does not threaten, a bilateral sympathectomy can arrest the degenerative process, restore vision, relieve symptoms, and apparently prolong life

Surgery is not the ideal treatment of hypertension As a palliative measure it is capable of relieving symptoms, even when these are severe, in about 50 per cent of patients, carefully chosen for this procedure It has little effect on the diastolic blood pressure level in only about 20 per cent is the diastolic pressure restored to normal These results are far from ideal, but they are better than those obtained by purely medical means

The contra-indications to surgical intervention are arteriosclerosis, angina, congestive failure, and impaired renal function Minor cerebral episodes, even transient hemiplegias, do not necessarily contra-indicate surgery In the desperate condition labelled "malignant hypertension" surgery can postpone the fatal outcome, restore vision, relieve symptoms, and enable the sufferer to return to work—an achievement that has hitherto not resulted from any medical measures so far employed

CLIFFORD WILSON (*introduced*) presented the results

of lumbo-dorsal sympathectomy in 46 cases of hypertension followed for six months to five years Twenty-five cases were diagnosed malignant hypertension, eleven severe benign hypertension in young subjects, and ten primary renal disease The effect of cerebral and cardiac complications, and of renal impairment on the surgical risk was discussed In general the malignant hypertension syndrome carried a greater risk than any of these complications taken singly but cardiac asthma or renal failure with blood urea up to 100 mg usually contra-indicated operation

Analysis of results showed that during the five-year period 18 of the 46 cases had died, 14 of these were diagnosed malignant hypertension Mortality was greater and survival periods shorter in males than in females Examining the diagnostic groups separately in *malignant hypertension* where the need for some form of therapy is most urgent, the operative risks are grave and the results disappointing In selected cases the operation may increase the expectation of life by two or three years In the present series, the longest survival period was 4¾ years, in almost all cases there was symptomatic relief particularly from headaches, and retinal changes, including papillœdema, improved or disappeared *Severe benign hypertension* in young subjects would seem to provide the most favourable indication for sympathectomy but unfortunately improvement is largely subjective and the ultimate effect on prognosis is difficult to assess In our group of 10 cases there were no deaths, but sustained fall in blood pressure was observed in only 3 patients

In *primary renal disease* (bilateral) with severe hypertension but with good renal function, the results of operation were encouraging and it seems possible that in these patients progressive renal deterioration may be retarded

In conclusion, more emphasis should be placed on diagnosis, renal biopsy should be performed at operation in order to confirm the clinical diagnosis In benign hypertension the natural history of the disease should be more carefully studied so as to provide a control group against which the operative results would be more reliably assessed

W T Cooke In Birmingham, a Smithwick operation has been performed upon 50 patients more than 12 months ago by Mr W H Sweet, Brodie Hughes, and J M Small The main features are summarized in Table III

In the absence of a large control group, blood pressure changes and survival rates are of little value in assessing the merits of the operation The procedure appears to have been beneficial for certain subjective reasons—the disappearance of severe headaches and lassitude, and increased capacity for work Thus of the whole group, approximately 25 per cent, including 5 of Grade IV severity, are working full time in factory or the home, approximately one-third are dead or invalids, whilst the remainder are improved and not prevented from working, though still incapacitated to some extent Objectively 2 out of 30 of the patients showed decrease in heart size, the remainder no change Hæmorrhages and papillœdema cleared up in all those in whom they were present Of 25 patients with abnormal cardiograms, 10 became normal after operation and 4 showed only left axis deviation

In 25 cases, renal plasma flow and glomerular filtration rate was determined, and in 20 cases, effective kidney mass These determinations though revealing all stages of kidney impairment, gave no indication as to whether an operation might be successful Renal biopsy on 16 patients also revealed the great diversity of kidney pathology, which was

TABLE III

	Grade I and II	Grade III	Grade IV	Total
Men	5	3	11	19
Women	16	6	9	31
Average age	42	41 8	40	41 (10–58)
Average blood pressure	236/143	233/137	240/144	237/142
Average fall	47/25	70/35	43/34	
Normal blood pressure	—	2	2	4
Deaths	1	0	8	9
Untraced	2	—	2	4
Average survival	Living (18) 30 months	Living (9) 31 months	Living (10) 35 8 months	
Average survival whole group living and dead		28 7 months		
Average time since operation		32 5 months		

often completely unsuspected clinically For these reasons, it is of utmost importance that renal biopsies should be taken as a routine if any accurate assessment of results is to be obtained in the future

Cerebral catastrophes which had occurred in 15 patients did not prove a contra-indication Six are working full time Four have normal blood pressures including two who have each two normal pregnancies Four are dead Of four patients with congestive cardiac failure, one responded dramatically and is now working

In this series, there were patients in whom the operation appeared life-saving, and others to indicate that there was a place for surgery in the treatment of hypertension and papillœdema below the age of 50, for progressive hypertension in the young age groups with signs of incipient failure of cerebrum, kidneys, or heart, or at any age for the relief of the intractable type of headache occurring in hypertension Contra-indications are advanced kidney failure, generalized arteriosclerosis, recent cerebral hæmorrhage, or any case with marked functional overlay

Short Communications

Measurement of Pulse Volume

By E B Colegrave and T G Richards (*introduced*)

A method is described by which true pulse volume may be measured at any external pressure A triple armlet is used and volume is directly measured by a liquid lens of negligible inertia

It was shown that the orthodox graph of pulse volume against external pressure cannot give a derived curve of arterial collapse The instability in collapse which makes this impossible is found to be related to the total arterial rigidity, which may then be calculated The internal pressure valves are given by subtracting the valve of internal rigidity from the clinical blood pressure figures

Arterial resistances to collapse in normal subjects are found to be of the same order Much higher figures are found in arteriosclerosis In true hypertension the figure depends upon the severity and duration of the disease Arterial rigidity may occur before electrocardiographic changes are evident

Complete Heart Block Associated with Amœbic Hepatitis

M D Rawkins and G L S Konstam (*introduced*)

An ex-army officer, aged 28, complained of fainting attacks over a period of three days and pain over the lower sternum aggravated by breathing In 1942 whilst serving in the Western Desert he had periodic attacks of mild diarrhœa, for which he did not receive treatment, and since then occasional diarrhœa, but none for nine months

There was no history of rheumatic fever nor diphtheria but he had had scarlet fever, when 19, and since then occasional pains in the limbs

On examination (1/1/48) he was well nourished Resting pulse 40 and regular B P 145/70 Heart not enlarged, no murmurs Liver dullness extended upwards in the mid-axillary line to fourth space, edge not felt

Cardiogram showed C H.B and X-ray examination showed that the right dome of the diaphragm was considerably raised, immobile, and its outline blurred The transverse diameter of the heart was slightly increased to the left and right The appearances were typical of amœbic hepatitis but stool examinations were negative for *E histolytica* and sigmoidoscopy showed normal appearances

A course of eleven emetine HCl (gr 1) injections was started and after the third injection the pulse rate increased to 80, with a P–R interval of 0 2 sec, the chest pain disappeared, and the Stokes-Adams attacks ceased

A further X-ray examination showed free movement of the diaphragm and the right dome had returned to its normal level and was regular in outline

Heart block associated with amœbiasis is a rarity We have found in the last twenty-three years three other cases of A-V dissociation (Petzetakis, *Arch Mal Coeur*, 1925, **18**, 70, Gerbasi, *La Pediatria*, 1931, **39**, 513, Heilig and Visveswar, *Indian Med Gaz*, 1943, **78**, 419) In each this complication occurred during active dysentery and response to emetine seemed certain in only one

In the course of prolonged diarrhœa other factors that could influence the conducting tissue are anæmia, toxæmia, thiamin and nicotinic acid deficiency, peripheral circulatory failure, uræmia, and possibly abnormal blood and tissue chemistry

The case here described had not had diarrhœa for nine months and both the hepatitis and heart block appeared to respond promptly to emetine An amœbic metastasis in the heart therefore seemed more probable than an indirect toxic effect on the conducting tissues

Stokes-Adams Attack in Latent Heart Block

By G Bourne

Two cases of Stokes-Adams attacks were described in which the underlying disease of the bundle was not suspected to be cause of the attacks, one had been examined by a cardiologist and the other by a general physician In each the history of the attacks aroused suspicion as to their possible cause The first patient was a man of 70 who for seven months previously at intervals of a month or less had had constant attacks of syncope These were abrupt in onset, lasted three to five seconds, and were not followed by any headache, drowsiness, or any other sequelæ He was just as well after the attacks as before The heart showed moderate enlargement on cardioscopy There was a harsh systolic murmur at the apex base The heart rate was 56 and was regular The blood pressure was 116/72 The cardiogram showed a P–R interval of 0 2 sec and a prolonged QRS complex He was given ephedrine 0 5 grains t i d , and from that day, a period of 21 months, has remained free from attacks

The second patient was a woman of 61 with a two years history of from four to eight weeks interval between attacks, but the frequency of the attacks had increased for a month or two previous to examination The attacks were abrupt and were followed by no sequelæ, nor were they preceded by any warning They lasted ten seconds, for the husband was in the habit of counting ten seconds by which time he knew that his wife would recover She had been thoroughly investigated for epilepsy There was an aortic systolic murmur The blood pressure was 150/90 The cardiogram showed an increased P–R interval of 0 23 sec Cardioscopy showed moderate enlargement Further tracings taken to exclude a previous infarct were done and in two of these a true heart block was shown The purpose of showing the cases was to stress the importance of an exact history in suspecting examples of Stokes-Adams attack in patients hitherto unsuspected of heart block

Heart Block in Osteitis Deformans

By C V Harrison and B Lennox (*introduced*)

The authors reported two cases The first was a woman of 71 who, while in hospital with advanced Paget's disease, developed Stokes-Adams attacks with temporary complete heart block At autopsy there was calcification along the base of the mitral valve which had spread on to the interventricular septum to involve the bundle of His The second was a man of 74 with advanced Paget's disease who was admitted with recent dyspnœa and found to have complete heart block He died soon after admission and at autopsy there was calcification along the bases of the mitral and aortic valves and spread on to the septum involving the bundle of His

The authors believe that this association between Paget's disease and cardiac calcification is not fortuitous An analysis of 30 published post-mortem records on cases of Paget's disease revealed that 11 of them had cardiac calcification Similarly, 13 cases of Paget's disease in their own departmental records included 6 cases with cardiac calcification

From a comparison of these figures with those from a control series of routine autopsies, the authors concluded that cardiac calcification was five times as common in Paget's disease as in controls and that the heart block observed clinically in their two cases is to be regarded as a true complication of Paget's disease

Two Newer Murmurs in Diastole

By William Evans

The first was a trivial or incidental murmur in early diastole, exocardial in origin, and found in cases of sternal depression, the murmur was not evidence of aortic incompetence

The second was a continuous murmur in systole and diastole which is the outcome of a small and unimportant A-V fistula and should be distinguished from the murmur of patent ductus arteriosus in order to save patients from unnecessary operation The phonocardiogram will decide both clinical problems

Phonocardiography in Heart Disease

By E D H Cowen (*introduced*)

A phonocardiographic investigation of systolic murmurs (1) in valvular and congenital heart disease (63 cases) and (2) in subjects without other evidence of cardiac disability (40 cases), revealed no significant difference in time of onset of the murmur in relation to the S line of lead II of the electrocardiogram in the two groups This analysis was undertaken following the work of W Evans (*Brit Heart J*, 9, 1 and 225, 1947)

A new phonocardiograph evolved by the Cambridge Instrument Company in collaboration with the author was used, consisting of a piezo-electric crystal microphone, andion tube amplifier, and double fibre string galvanometer A frequency response curve of this instrument was shown in a discussion on the calibration of phonocardiography

Phonocardiograms taken by the new instrument were shown, in which it was demonstrated, confirming many previous workers, that there is no exact correspondence between the mechanical and electrical events of the cardiac cycle

Angiocardiography as a Diagnostic Aid

By Frances Gardner

The angiocardiographic work described in this report is confined to congenital heart disease The technique employed is that described by Robb and Steinberg in 1938 with the addition of a preliminary intravenous sensitivity test

The film cassettes are changed by hand and only one exposure every three seconds is possible The arm-lung circulation time is a reliable guide to the exposure time for the right heart The arm-tongue circulation time is extremely unreliable as a guide to similar times for the left heart and aorta Good contrast films of these structures are therefore difficult to obtain unless large quantities of radio-opaque material are used

The slides demonstrate the angiocardiographic appearances in the following conditions

1 Congenital dilatation of the pulmonary artery with stenosis and incompetence of the pulmonary valve
2 Isolated pulmonary stenosis
3 Patent ductus arteriosus
4 Fallot's tetralogy
5 Pulmonary atresia with patent ductus arteriosus
6 Coarctation of the aorta

There are probably few congenital heart lesions where angiocardiography is essential for accurate diagnosis It is, however, valuable as a method of visualizing the precise anatomy of the pulmonary circulation and the site and extent of aortic coarctation

A Clinical Comparison of CR, CF, and Unipolar Chest Leads

By Aubrey Leatham (*introduced*)

Leaving aside theoretical considerations of the relative advantages of certain chest leads now in common use, an investigation has been made of the clinical value of these leads Standard limb leads, unipolar limb leads, and chest leads CR, CF, and V1 to 7 have been taken in over 300 cases so far, and the following conclusions have been reached

In rare cases of cardiac pain the CF lead has shown changes in the T wave that were not found in either CR or V leads Since such an event is so rare, and since the lead commonly shows similar changes in healthy subjects, and must then be read in conjunction with the unipolar limb leads, the practice of recording CF as the only chest lead should be condemned

In CR leads, T wave positivity tends to be exaggerated which is an advantage in health, but in very rare cases may conceal small changes in the T wave that are indicative of disease, however, only once did the V chest leads show a change in a patient with cardiac pain that was not present in the CR leads

A disadvantage of V leads is the fact that in health the T wave in V1 is often inverted, and the T waves in V6 and V7 are customarily low and may be flat, or even inverted in V7

Tuberculous Pericarditis

By A A F Peel

Published in full, Brit Heart J, **10**, 195, 1948

Cardiac Infarction Complicated by Bundle Branch Block

By W Somerville (*introduced*)

An attempt has been made to estimate the frequency with which an electrocardiographic diagnosis of cardiac infarction can be made in the presence of bundle branch block

A series of 58 cases each with a clear history of cardiac infarction and a cardiogram showing bundle branch block was examined The cases fell into two groups, in one, the pathological signs of infarction were present in the cardiogram in addition to those of bundle branch block (37 cases), in the other group, the signs of infarction were suppressed (21 cases) There were 34 cases of left bundle branch block, in 15 of which the signs of infarction were present, and 24 cases of right bundle branch block, in 22 of which the signs of infarction were present

The distribution of the abnormal Q and T waves, and RS–T segment deviations, diagnostic of cardiac infarction is set down in Table IV The term chest leads refers to unipolar leads V1 to V6 or V7, in a few cases, only V1, V3, and V5 were taken Unipolar limb leads refers to the Wilson leads VL, VR, and VF

TABLE IV

Pathological Signs of Cardiac Infarction in Presence of Bundle Branch Block.

Right Bundle Branch Block

	Abnormal Q	*RS–T deviation*	*Abnormal T*
Anterior infarction (11 cases)			
Limb leads (11 cases)	6/11	2/11	1/11
Chest leads (9 cases)	9/9	8/9	7/9
Unipolar limb leads (6 cases)	4/6	2/6	0/6
Posterior infarction (11 cases)			
Limb leads (11 cases)	10/11	10/11	9/11
Chest leads (8 cases)	1/8	0/8	1/8
Unipolar limb leads (2 cases)	2/2	1/2	1/2

LEFT BUNDLE BRANCH BLOCK

	Abnormal Q	*RS–T deviation*	*Abnormal T*
Anterior infarction (11 cases)			
Limb leads (11 cases)	10/11	2/11	11/11
Chest leads (9 cases)	7/9	7/9	6/9
Unipolar limb leads (5 cases)	4/5	1/5	4/5
Posterior infarction (4 cases)			
Limb leads (4 cases)	4/4	4/4	4/4
Chest leads (4 cases)	1/4	2/4	1/4
Unipolar limb leads (2 cases)	2/2	1/2	2/2

When dealing with such restricted numbers, it is not possible to draw firm conclusions regarding the frequency with which a diagnosis of cardiac infarction and bundle branch block can be made from the electrocardiogram The findings in the present series indicate that when right bundle branch block complicates cardiac infarction, signs of infarction may be expected to be found in the majority (22 of 24 cases, or 92 per cent)

When left bundle branch block complicates cardiac infarction, the signs of infarction may be found in about half the cases (15 of 34, or 45 per cent) Emphasis should be placed on the fact that there is approximately an even chance that the electrocardiographic signs of a cardiac infarct will be suppressed if left bundle branch block is a complication

ABSTRACTS OF CARDIOLOGY

Therapy Directed at the Somatic Component of Cardiac Pain S H Rinzler and J Travell *Amer Heart J* 35, 248–268, Feb, 1948

Observations were made on 31 patients with the symptoms of angina pectoris who presented "trigger areas" in the muscles of the præcordium When the trigger areas were either infiltrated with procaine (0 25 to 0 5%) or sprayed with ethyl chloride relief of pain lasting for days was experienced by those patients whose angina had followed a coronary thrombosis, but not by those without such a history

H E Holling

Electrocardiogram in Chronic Cor Pulmonale. R Zuckermann, E Cabrera, B L Fishleder, and D Sodi-Pallares *Amer Heart J* 35, 421–437, March, 1948

The authors are convinced that the electrocardiogram is a real aid in the diagnosis of chronic cor pulmonale and that often a diagnosis of this condition can be made by the electrocardiogram before it can be arrived at by clinical methods They describe their electrocardiographic findings in detail and list 10 principal diagnostic signs

R T Grant

Septal Anastomoses C Laubry, P Soulié, and H Thys *Arch Mal Cœur*, **41**, 1–24, Jan –Feb, 1948

A study of the coronary artery anastomoses in the interventricular septum was made in 50 hearts by injecting "lipiodol" at low pressure (50 mm Hg or less) into the coronary arteries, the septum being isolated The injected specimens were examined radiographically The authors conclude that (1) in normal hearts, specially in those from young subjects, septal anastomoses are so frequent as to be considered the rule, (2) anastomoses are rare in elderly subjects

R T Grant

Complete Transposition of the Aorta and the Pulmonary Artery Experimental Observations on Venous Shunts as Corrective Procedures. C R Hanlon and A Blalock *Ann Surg*, **127**, 385–397, March, 1948

Transposition of the aorta and pulmonary artery is a rare deformity, in the presence of which survival is only possible through the persistence of fœtal passages such as ventricular or auricular septal defects, patent ductus arteriosus, or entry of pulmonary veins into the right auricle Length of survival depends on the amount of mixing of pulmonary and systemic blood that can take place The average in 123 reported cases is 19 months, but one patient lived a normal life for 56 years Experiments were performed on dogs to discover whether venous shunts would permit survival in the presence of aortic and pulmonary artery transposition. The shunts were performed first, and consisted of anastomosis of the veins from the two upper lobes of the right lung into either the right auricle or the superior vena cava The latter gave the better results, as there was less disparity in thickness between the vessels anastomosed These shunts were shown to be patent some months after operation but in no case in which experimental transposition was subsequently effected has survival been possible for more than a few minutes This is presumably because the shunt allowed insufficient mixing Further attempts are being made

J B Kinmonth

The Determination of the Prognosis of Pregnancy in Rheumatic Heart Disease J J Bunim and J Rubricius *Amer Heart J* 35, 282–297, Feb, 1948

Observations were made on 142 pregnant women with rheumatic heart disease through pregnancy and the puerperium, the literature on the subject was studied It is concluded that pregnancy itself has little effect on the prognosis in rheumatic heart disease

H E Holling

Effect of Exercise on Cardiac Output and Pulmonary Arterial Pressure in Normal Persons and in Patients with Cardiovascular Disease and Pulmonary Emphysema H B Hickam and W H Cargill *J clin Invest*, **27**, 10–23, Jan, 1948

The changes in the circulation of 28 persons (8 normal subjects, 8 with congestive failure, 7 with mitral stenosis, and 5 with emphysema) were studied by means of cardiac catheterization at rest and during exercises in a supine position in which the patients pushed with their feet against weighted pedals In the controls cardiac output and the arterio-venous oxygen difference both increased, though the increase in cardiac output was the greater In congestive heart failure there was little change in cardiac output but a large increase in arterio-venous oxygen difference The normal pulmonary vascular bed can accommodate the amount of blood associated with a large increase in the rate of blood flow, with little or no increase in mean pulmonary arterial pressure With left ventricular failure mean pulmonary arterial pressure, already elevated at rest, rises much further on exercise Similar changes were noted in well-marked mitral stenosis, but in some patients the increase appeared larger than could be accounted for by a fixed obstruction at the mitral orifice In advanced pulmonary emphysema the elevated pulmonary arterial pressures noted at rest and on exercise were believed to result from destruction of small vessels in the lung

W T Cooke

Treatment of Thromboangiitis Obliterans and Thrombophlebitis with Tetraethylammonium Chloride. R Buxton and E C Eickhoff *Sth Med Surg* **110**, 69–71, March, 1948

The action of tetra-ethyl-ammonium chloride in establishing a temporary sympathetic block was used in the treatment of 6 cases of thrombo-angiitis obliterans and of 5 cases of thrombophlebitis, 2 to 3 ml being injected up to 3 times daily for varying periods of time [the actual dosage is not given] Among the cases of Buerger's disease, 1 is included in which the condition followed a fracture of the first lumbar vertebra This patient and 2 others of this series were markedly improved by the treatment, although a lumbar sympathectomy preceded improvement in 1 of them In 3 other cases treatment failed In the 5 cases of thrombophlebitis pain ceased within 2 days of starting treatment, and the average time taken to effect a cure was 7 days *G Schoenewald*

The Effect of Tetra-ethyl-ammonium Chloride on Blood Pressure Before and After Sympathectomy for Hypertension. H S Brown, E V Allen, and W McK Craig *Proc Mayo Clin*, **23**, 94–99, Feb 18, 1948

Tetra-ethyl-ammonium chloride blocks the transmission of impulses from preganglionic to postganglionic fibre of the autonomic nervous system. The effect is transient and includes a fall in blood pressure of hypertensive patients in the recumbent position, orthostatic hypotension, tachycardia, mydriasis, and increase in the skin temperature of the toes In the present observations the drug has been found to reduce greatly the blood pressure of recumbent hypertensive patients who have undergone sympathectomy by the Smithwick operation Compared with the pre-operative action of the drug, 25 to 30% of the dose has post-operatively two or three times the effect Observations on 6 subjects are recorded The significance of the effect is considered The authors discard the possibility that it may be due to the drugs' acting in more concentrated manner on the relatively few remaining effective ganglia They suggest that the fact that the residual post-sympathectomy hypertension can be reduced to normal indicates that organic changes in the arterioles are not an important factor in the persistent hypertension *C L Cope*

Pathology and Clinical Features of Idiopathic Isolated Myocarditis Y G Etinger and N L Vilk *Klin. Med, Mosk*, **26**, No 3, 3–13, 1948

The authors have been able to study 7 cases of idiopathic myocarditis both clinically and at necropsy, and consider that the condition may be diagnosed during the patient's life The ætiology is obscure Heart failure came on suddenly, sometimes after such conditions as physical exertion, pregnancy, or acute infection (influenza) In 4 cases the aorta was hypoplastic Five patients were females, ages ranged from 20 to 60 years The clinical picture was one of severe and rapidly progressive congestive heart failure with cyanosis and dyspnoea The heart was enlarged, arrhythmias were common The blood pressure was low, the pulse soft Occasional bouts of pyrexia occurred The electrocardiogram pointed to a diffuse lesion, voltage was low, Diagnosis was made by exclusion in 5 cases during life At necropsy, coagulative necrosis and myolysis of the myocardium were sometimes the chief features, while in other cases exudative and proliferative changes predominated *S S B Gilder*

The Diagnostic Value of Electrocardiographic Patterns, Based on an Assay of 261 Additional Autopsied Cases. L N Katz, D Feldman, and R Langendorf *Acta cardiol, Brux*, **2**, 291–317, 1947

This study is a continuation of previous work on the same subject It is based on a series of 261 consecutive cases in which electrocardiograms (including chest leads) were made within 2 months of necropsy The authors conclude that in general the electrocardiogram is a good index of whether or not the heart is structurally normal An abnormal electrocardiogram is excellent evidence that the heart is abnormal On the other hand, a normal electrocardiogram is occasionally found with an abnormal heart In 41 cases of the series a discrepancy existed between the electrocardiographic diagnosis and the necropsy findings, these cases are discussed and separately tabulated *R T Grant*

Studies of Fluorocardiography in Normal Subjects F G Fleischner, F J Romano, and A A Luisada *Proc Soc exp Biol, N Y*, **67**, 535–539, April, 1948

Fluorocardiography (electrokymography) is a newly developed procedure for recording on a continuous film the pulsations of various areas of the cardiovascular silhouette and the opacity changes of the lung fields on X-ray examination Simultaneous phonocardiographic records are taken, which permit exact timing of the fluoroscopic pulsations This paper is a further contribution to the study of fluorocardiography in normal subjects Records of tracings of the ascending aorta, pulmonary veins, and pulmonary parenchyma are presented and their significance is discussed The tracing of pulsations in the pulmonary parenchyma is comparable to a plethysmogram and is influenced by both arterial and venous changes in the blood content of the lung From the tracings the velocity and duration of pulmonary arterial waves have been measured, the speed of the pulse in the lesser circulation has been found to be roughly one-third of the speed of pulse waves in the greater circuit This is due to a lower pulmonary pressure and greater extensibility of the pulmonary vessels [Those interested in fluorocardiography should become acquainted with previous work by the same authors on the subject and the appended references will be useful] *A I Suchett-Kaye*

Kymographic Studies of the Function of the Auricle. B Fabricius *Acta radiol, Stockh*, **29**, 152–158, Feb 28, 1948

By studying the movements along the left border of the heart between the pulmonary conus and left ventricle with simultaneous kymograms and electro-cardiograms the author has concluded that the kymographic waves at the

level of the left auricular appendix have little significance Previous workers have described systolic contraction waves arising in the appendix itself and impulses transmitted from the left ventricle and from the pulmonary artery But owing to the superimposed left hilar shadow and to the small undulations of the auricular appendix the interpretation of these waves has always been difficult It is probable that the auricular appendix has no independent regular muscular function and therefore no important influence on the circulation It appears to serve as a complementary space during ventricular systole to preserve the smooth contour of the heart within the pericardial sac *J L Lovibond*

Portacaval Shunts in the Treatment of Portal Hypertension With Special Reference to Patients Previously Operated Upon R R LINTON *New Engl J Med*, 238, 723–727, May 20, 1948

In the 4 cases reported, portal hypertension was manifested by repeated severe hæmorrhages, for which a variety of previous operations (splenectomy and direct attacks on the varices or their efferent venous trunks) had proved unavailing A portacaval shunt was then carried out with complete relief in 3 of the patients for the duration of the follow-up periods (14, 14, and 22 months) The most satisfactory portacaval shunt is one in which, after splenectomy, the stump of the splenic vein is anastomosed to the side of the left renal vein The left kidney should be preserved, since the operation is a severe one and may be followed by oliguria and a rise in the blood non-protein nitrogen even in the presence of both kidneys Anastomosis of the portal vein to the inferior vena cava may be impossible because of cavernomatous transformation of the portal vein This operation is also fraught with risk to the bile ducts The veins of the portal system are devoid of valves, and therefore a shunt downstream from the main trunk may decompress the whole system

The author emphasizes that previous splenectomy may result in obliteration of the stump of the splenic vein and preclude the establishment of a spleno-renal anastomosis Therefore the surgeon undertaking a splenectomy for portal hypertension should be prepared to proceed at once to effect a spleno-renal shunt *Francis F Rundle*

Dissecting Aneurysms A Presentation of Ten Case Reports and a Correlation of Clinical and Pathological Findings. A S WARREN and A L MCQUOWN *Amer J med Sci*, 215, 209–219, Feb, 1948

The authors describe briefly the pathology of dissecting aneurysm, and discuss the relative importance of atherosclerosis, syphilis, and idiopathic cystic medial necrosis as ætiological factors They stress the extremely varied symptomatology, and suggest that the clinical manifestations may conveniently be divided into 8 groups, according to whether the symptoms and signs are produced by disturbance of the circulation to the heart, lungs, brain, arm, spinal cord, gastro-intestinal tract, genito-urinary tract, or leg respectively Histories and necropsy findings in 10 cases are given The correct diagnosis was made during life in 3 cases, 1 of them at laparotomy The incidence of dissecting aneurysm during the past 10 years at the authors' hospital (The Charity Hospital of Louisiana) was 1 in 454 necropsies All the cases recorded in this paper were in males *A R Kelsall*

The Reliability of Percussion of the Left Heart Border H E LEVIN and H NAGEL *Bull Sch Med Maryland*, 32, 221–223, April, 1948

The authors carried out percussion of the left cardiac border in 25 subjects and compared the position of the outermost point of dullness with the position of the outermost point of the left cardiac silhouette as seen in radiographs taken at 6 feet They conclude that the heart size was overestimated in about as many cases as it was underestimated, and that the margin of error was not more than 1 cm in 56% of cases, and not more than 1 5 cm in 80% They consider that cardiac percussion of the left border should not be discarded as unreliable [Two criticisms of this paper are first, the patients were lean male subjects, and secondly, the majority of these had hearts within normal limits of size It would have been more convincing if the authors could have shown the value of percussion in cases where the apex beat is not palpable] *S Oram*

Effect of Potassium on the Ventricular Deflections of the Electrocardiogram in Hypertensive Cardiovascular Disease. J M BRYANT *Proc Soc exp Biol, N Y*, 67, 557–558, April, 1948

The author investigated the effect of potassium salts on the electrocardiogram in patients with hypertensive disease and in normal subjects, in doses varying between 10 and 24 g daily In the hypertensive group there was a reduction in voltage of the QRS deflections, frequently reduction in length, and shift to the right of the mean axis An originally inverted T wave became less inverted or upright, it became taller when it was originally upright In a few instances the T wave became more deeply inverted, though the voltage of the QRS deflection was reduced All these changes persisted several hours after the administration of the potassium salts The changes in normal subjects were the same as those in the hypertensive group, but much less pronounced It is interesting to note that the same type of changes in hypertensive patients can be brought about by a diet with sodium restriction or by sympathectomy *A I Suchett-Kaye*

Cardiovascular System as the Effector Organ in Psychosomatic Phenomena G BURCH and T RAY *J Amer med Ass*, 136, 1011–1017, April, 17, 1948

The disturbances which emotional stress may produce in the function of the gastro-intestinal and genito-urinary tracts and respiratory and cardiovascular systems is reviewed

The cardiovascular system is particularly susceptible to psychic disturbances The effects may be central or peripheral The central effects include (1) increased cardiac output, (2) disturbances of cardiac mechanism,

(3) electrocardiographic changes, (4) angina pectoris, and (5) even sudden death These effects are illustrated by 2 cases in which emotional disturbances produced pain like angina pectoris with transitory electrocardiographic changes (depression of the S–T segment and inversion of the T wave during the attack) The peripheral effects of psychic disturbances are illustrated by 2 cases A negro showed a typical Raynaud syndrome under emotional strain, and in a medical student erotic thoughts raised the systolic blood pressure from a normal level to 250 mm Hg and the diastolic pressure to 140 mm Hg This rise in blood pressure was associated with a peripheral vasoconstriction, as shown by plethysmographic studies of the index finger

The use of the plethysmograph in investigating the reactions of the peripheral blood vessels to emotional states and in studying types of personality is discussed Tension and lack of relaxation in persons may be identified by the plethysmogram Such methods of investigating the peripheral circulation are considered to offer an objective and quantitative approach to psychiatric problems The need for psychiatric evaluation and the use of psychotherapy in the proper management of patients with cardiovascular disorders is emphasized

F A Langley

The Behavior of the Venous Pressure during Various Stages of Chronic Congestive Heart Failure. T B GIBBONS *Amer Heart J* 35, 553–566, April, 1948

Twenty-three patients were studied in whom a state of congestive failure was either induced or improved Significant changes of degree of congestive heart failure were encountered 34 times, there were 26 instances of recovery and 8 of deterioration The changes in body weight were taken as an index of the amount of œdema, and serial determinations of venous pressure were made by a direct method For the most part changes in body weight and in venous pressure ran parallel, but in a few cases venous pressure altered without a change in body weight, and vice versa When a patient with ascites was improving, the change in body weight might precede the fall in venous pressure In such cases the venous pressure in the legs was originally higher than that in the arms, but as the ascites disappeared the pressures approached each other The author concludes that in "all phases of the syndrome of congestive failure changes in the venous pressure and in the degree of congestion are concordant Any initial discordance in the time relation change in the venous pressure to change in weight associated with œdema can be explained by the state of those tissues affected by œdema"

H E Holling

Clinical Electrocardiography Third Edition By DAVID SCHERF, and LINN J BOYD

It is due perhaps not so much to recent advances in electrocardiography that, since 1940, a third edition has already appeared, as to the increasing demand for a reliable descriptive account of its principles and practice The new enlarged edition has called for much revision of the former text, nevertheless its authors continue to maintain the critical balance between the theory, physiology and practical application of their subject which remains a feature of their book The importance of chest leads now meets fuller recognition More space and greater detail is given to their discussion, particularly in regard to their diagnostic value in myocardial infarction, ventricular hypertrophy and bundle branch lesions On the other hand unipolar leads are dealt with rather summarily, which is to be regretted in view of their increasing clinical significance The reproduction of electrocardiograms is technically unpleasing, the majority suffer from over reduction, their definition is indistinct and their full description is often only to be found in the text on another page and not in the abbreviated captions beneath the illustrations Sometimes the records are presented vertically below each other, but sometimes across the page which is confusing because the leads are not numbered An adequate bibliography is included at the end of each chapter but unfortunately many references in the text are ambiguous through the omission of dates after authors' names Attention to these details in the next edition will greatly enhance its merit as a book of easy reference The text is amply cross-referenced with few misprints and good use is made of emphasis by italics Some of the chapters, particularly those on extrasystoles, fibrillation and flutter, and the tachycardias are notably lucid

J L. Lovibond

Cardiovascular Diseases Second Edition By DAVID SCHERF, and LINN J BOYD

The original edition of this work consisted of a series of clinical essays on selected cardiac problems written largely from the practical view point in relation to diagnosis and treatment It has now been rewritten and becomes a complete and eminently readable textbook, retaining many of its former virtues In the ætiology of certain cardiac symptoms the authors continue to emphasize the importance of the inflammatory myocarditis that occurs after rheumatic fever, tonsillitis, and many other infections, distinguishing it from the primarily degenerative myocarditis of diphtheria and typhoid One observes that they discard the term "coronary insufficiency" as a false ætiological nomenclature and that they reserve "angina pectoris" to describe a symptom and not a disease entity The section on Cor Pulmonale could have been accorded more space and the explanations of the "Third Heart Sound" and "Gallop Rhythm" are not too clear There is a full bibliography after each chapter, but references to authors in the text are mostly made by numbers and not by names, a method now obsolete in this country and one that renders the bibliography less selective Some unaccustomed terms are used such as "adnexitis," "hypocapnia" (for tachypnœa), and "pathophysiology" though their meaning is usually clear enough, Description of radiology of the heart is limited and the plates that appear are not representative, notably the poor quality illustrations of cardiac aneurysm and atrial septal defect It would be an advantage if the figures of the cardiographic strips were numbered plainly by leads, and if in the index which is otherwise complete, the main references were emphasized in heavy type This book should be read in conjunction with the work on Clinical Electrocardiography by the same authors

J L Lovibond

INDEX OF AUTHORS

A

Abrahams, D Gordon Incipient symmetrical peripheral gangrene complicating paroxysmal tachycardia 191
Ashton, Norman (and Mary Munro) Coronary artery aneurysm with occlusion due to a calcified thrombus 165

B

Bain, C W Curtis (and E McV Redfern) Clinical value of unipolar chest and limb leads 9
Benson, Robert (and William Evans) Mass thrombus of the left auricle 39
Blalock, Alfred The surgery of congenital heart diseases 68
Bramwell, Crighton The surgery of congenital heart diseases 78
Brooks, W D W Pulmonary heart disease 83
Brown, J W The surgery of congenital heart diseases 70
Burger, H C (and J B van Milaan) 229

C

Codounis, A Long survival with a cardiac aneurysm 244
Cole, Leslie Two cases of temporal arteritis, one with angina of effort 26
Crafoord, C The surgery of congenital heart diseases 71

D

Dick, Peter Relative value of digitaline preparations in heart failure with auricular fibrillation 122
—— (and William Evans and Byron Evans) Rapid digitalization 103
Dock, William Erosion of ribs in coarctation of the aorta 148

E

East, Terence (and Samuel Oram) Cardiac pain with recovery of the T wave 263
—— Clinical value of chest leads 88
Evans, Byron (and William Evans and Peter Dick) Rapid digitalization 103
Evans, M E Ball thrombus of the heart 34
Evans, William (and Robert Benson) Mass thrombus of the left auricle 39
—— The use of phonocardiograph in clinical cardiology 92
—— (and Peter Dick and Byron Evans) Rapid digitalization 103

F

Fischmann, E J (and F J Gwynne) Heart in rheumatoid arthritis 125

G

Gilchrist, Rae The surgery of congenital heart disease 75
Gwynne, F J (and E J Fischmann) Heart in rheumatoid arthritis 125

H

Harrison, C V (and Bernard Lennox) Heart block in osteitis deformans 167
Hume, W E John Cowan 1

K

Kauntze, Ralph (and Gerald Parsons-Smith) Cardiovascular changes following electro-convulsive therapy 57
Kay, H B Ventricular complexes in heart block 177
Kilpatrick, J A Variation of casual, basal and supplemental blood pressures in health and in essential hypertension 48
Kirby, Alan C Ventricular escape in acute rheumatism 234

L

Lenègre J (and P Maurice) Pulmonary heart disease 81
Levine, Samuel Auscultation of the heart 213

M

Maurice P (and J Lenègre) Pulmonary heart disease 81
McMichael, J Pulmonary heart disease acute and chronic 80
Moe, Torjus (and Håkon Rasmussen) Pathogenesis of left bundle branch block 141
Munro, Mary (and Norman Ashton) Coronary artery aneurysm with occlusion due to calcified thrombus 165

N

Newman, Maurice Coarctation of the aorta 150

O

Oram, Samuel (and Terence East) Cardiac pain with recovery of the T wave 263

P

Palmer, J H U wave inversion 247
Parsons-Smith, Gerald (and Ralph Kauntze) Cardiovascular changes following electro-convulsive therapy 57
Peel, A A Fitzgerald Dissecting aneurysm of the interventricular septum 239
—— Tuberculous pericarditis 195
Price, R Kemball (and R Skelton) Hypertension due to syphilitic occlusion of the main renal arteries 29

R

Rasmussen, Håkon (and Torjus Moe) Pathogenesis of left bundle branch block 141
Redfern, E McV (and C W Curtis Bain) Clinical value of unipolar chest and limb leads 9

S

Sellors, Holmes The surgery of congenital heart disease 76
Shorr, Benjamin (and Harry Vesell) The right præcordial lead 158
Skelton, R (and R Kemball Price) Hypertension due to syphilitic occlusion of the main renal arteries 29
Summers, V K Angina in Women 4

T

Taussig, Helen Surgery of congenital heart diseases 65
Thomas, Arthur J The heart in pneumoconiosis of coalminers 282
Tubbs, O S The surgery of congenital heart disease 77

V

van Milaan, J B (and H C Burger) Heart-vector and leads 229
Vesell, Harry (and Benjamin Shorr) The right præcordial lead 158

W

Walls, E W Regenerative capacity of mammalian heart muscle 188
Wilson, Frank N Clinical value of chest leads 88
Wood, Paul Pulmonary heart disease 87